

ISSN 1682-8356
ansinet.org/ijps



INTERNATIONAL JOURNAL OF
POULTRY SCIENCE

ANSI*net*

308 Lasani Town, Sargodha Road, Faisalabad - Pakistan
Mob: +92 300 3008585, Fax: +92 41 8815544
E-mail: editorijps@gmail.com

Sequential Pathological and Immunohistochemical Study of Pullorum Disease in Experimentally Infected Chicks

A.B.M. Shahinuzzaman¹, A.K. Saha¹, A.C. Mazumder¹, S. Das²,
M.A. Sufian¹, M.A. Baki¹ and M.M. Hossain¹

¹Department of Pathology, Faculty of Veterinary Science,
Bangladesh Agricultural University, Mymensingh-2202, Bangladesh

²Department of Pathology and Parasitology, Faculty of Veterinary Science,
Chittagong Veterinary and Animal Sciences University, Chittagong, Bangladesh

Abstract: The research work was conducted to study the sequential pathological changes of Pullorum Disease (PD) and immunohistochemical detection of its causal agent (*Salmonella pullorum*) in various tissues of experimentally infected chicks. Total 40 day old (D0) chicks were divided into experimental and control groups. The chicks were infected at day 15 (D15) of age by oral route with 1 ml of 2×10^8 CFU of *S. pullorum*. Chicks were sacrificed at day 1 (D1), day 3 (D3), day 5 (D5), day 7 (D7) and day 9 (D9) of Post Infection (PI) and observed the remarkable gross lesions in liver, lung, heart and cecum. Grossly, liver found fragile (40%) at D7 and D9. Cheesy materials in cecum (20%) showed at D9. The highest reisolation of *S. pullorum* demonstrated in cecum (68%). Histopathologically, nodular lesion in liver developed at D7 (20%) and D9 (40%). Hepatitis from D1 (20%) and continued upto D9 (60%). Pneumonia and bronchopneumonia along with inflammatory cells in lung were observed at D1 (20%) that continued upto D9 (80%). Spleen showed depletion of lymphocytes at D7 (40%) and D9 (60%). Typhlitis in cecum noticed at D5 (20%) and remained up to at D9 (40%). Congestion and hemorrhage was common in organs at early times and gradually reduced both in grossly and histopathologically thereafter. Immunohistochemistry revealed *S. pullorum* bacteria in the cytoplasm of hepatocytes of liver, in the cytoplasm of epithelia of cecum (D3, D7) and in the cytoplasm of epithelia of crop (D3).

Key words: CFU, experimentally infected, immunohistochemical detection, sequential pathological changes

INTRODUCTION

Pullorum disease (caused by *S. pullorum*, recently used nomenclature) is one of the major constraints of poultry industries in Bangladesh (Hossain *et al.*, 2006). It is an acute, infectious and fatal disease of chicks causing much loss during the first 2-3 weeks of life (Haider *et al.*, 2003). Pathogenesis and sequential pathology of Pullorum Disease (PD) is an important factor to understand the disease mechanism. For the detection of *Salmonella* organism many of technologies have been developed. Immunohistochemistry is a latest technique for that purpose (Christine *et al.*, 1999). A few researches have been completed on *Salmonella pullorum* infections using the conventional methods like necropsy, histopathology and isolation of bacteria by culture, stain and sugar fermentation tests (Islam *et al.*, 2006; Haider *et al.*, 2003). In Bangladesh, experimental pathogenesis and pathology of PD by local isolates are very scanty (Haider, 2009). Therefore, the present investigation had been designed with a view (a) to study the sequential pathological changes in chicks at different time intervals using a local isolate of *S. pullorum* and (b) to localize *S. pullorum* organism in various tissues at different time intervals.

MATERIALS AND METHODS

***Salmonella pullorum* bacteria:** *Salmonella enterica* sub. *enterica* serovar Pullorum was obtained from Department of Pathology, Faculty of Veterinary Science, Bangladesh Agricultural University, Mymensingh and it was previously confirmed by PCR and biochemical test (Haider, 2009). The colony forming unit (CFU) was counted according to ISO, 1995. The overall research activities were performed at the Department of Pathology, Faculty of Veterinary Science, Bangladesh Agricultural University, Mymensingh during the period from January, 2010 to November, 2010.

Collection and grouping of experimental chicks: Total 40 experimental day old (D0) chicks were purchased from Aftab hatchery Ltd. Vhagalpur, Bajitpur, Kishorgonj, Bangladesh assuring that *Salmonella* free and they were reared in poultry shed of Department of Pathology by using deep litter system. All necessary requirements like brooding, lighting, suitable temperature, feed and water for the chicks were allocated at optimum level. Chicks were divided into experimental and control groups. Each experimental group consisted of 5 birds while each control group comprised of 3 birds.

Experimental infection in chicks: The chicks were infected at D15 of age by oral route with a dose of 2×10^8 CFU (Roy *et al.*, 2001) of *Salmonella enterica* sub. *enterica* serovar Pullorum (Isolate No.5). Total 1 ml bacterial inoculums (0.5 ml of nutrient broth culture + 0.5 ml of phosphate buffer saline, pH 7.2) administered to infected chicks and 1 ml broth (0.5 ml of nutrient broth + 0.5 ml of PBS, pH 7.2) administered to the control groups by using sterile syringe.

Sacrifice of the chicks and gross pathological study: 5 Chicks from each group were sacrificed at D1, D3, D5, D7 and D9 of Post Infection (PI). At necropsy, gross tissue changes of various organs (liver, lungs, heart, spleen and cecum) were observed and recorded carefully.

Sample collection for reisolation of *S. pullorum*: Swab from various organs (liver, lungs, heart, spleen, crop and cecum) were collected for bacteriological reisolation in Tetrathionate Broth (TTB). The reisolation was performed by using culture method in Brilliant Green Agar (BGA), *Salmonella-Shigella* Agar (SSA) and Triple Sugar Iron (TSI) agar, Gram's staining, carbohydrate fermentation test of basic sugars and biochemical tests. Liver, lungs, spleen, heart, crop and cecum were collected in 10% buffered formalin for histopathological study as well as for immunohistochemical detection of *S. pullorum* organism in tissues.

Histopathology and histopathological study: Histopathology was performed according to the method as described by Luna (1968). Histopathological examinations of the tissues were studied under light microscope. Photomicrography was taken at the Department of Pathology, BAU, Mymensingh using the compound microscope and photomicrographic camera (Olympus PM-C 35 Model). The lesions were graded as mild (+) and moderate (++). The thumb rule bases were extent of lesions in organs and increase number of infiltration of inflammatory cells.

Staining procedure for immunohistochemistry: Staining was performed stated as Invitrogen immunohistochemistry kit (USA). The total procedure was given as below:

(1) At first deperaffinization and rehydration of tissues were done. For this purpose same protocol was followed as described by Luna (1968). In case of immunohistochemistry after final washing in distilled water for 10 min, the tissues were allowed for retrieval of antigen. (2) After washing with distilled water the slides were taken in a coplin jar containing retrieval solution. Then the coplin jar placed in hot water bath. The tissues were cooked in the water bath at 96°C for 30 min. Antigen Retrieval (AR) was done by using Heat Induced

Epitop Retrieval (HIER) method (Noujaim *et al.*, 2008). (3) After completing the antigen retrieval, slides were placed in a sequenzer. Slides were submerged in peroxidase quenching solution (1 part 30% H₂O₂ + 9 part absolute methanol) for 10 min. Then slides were washed with PBS 3 times for 2 min. (4) After washing 2 drops (100 µl) of serum blocking solution (Reagent-A) was added covering the full slides for 10 min. About 10 min later the blocking solution was drained off for 5 min but rinsing was avoided. (5) Completing the drained off of reagent-A 2 drops of (100 µl) diluted primary rabbit polyclonal antibody was added to the tissue containing slides. Then it was incubated at moist chamber for 1 h. The slides were rinsed in PBS 3 times for 2 min. (6) After PBS washing 2 drops (100 µl) of reagent-B applied to the slides containing tissues. It was incubated for 10 min and rinsed with PBS 3 times for 2 min. (7) 2 drops (100 µl) of reagent-C added to the slides. After incubating 10 min slides were rinsed with PBS 3 times for 2 min. (8) AEC single solution applied to the slides and incubated for 15 min at room temperature. Then these were rinsed well with distilled water. (9) The slides were stained with 2 drops of hematoxylin staining reagent. The slides were incubated for 3 min and then rinsed well by distilled water. (10) Aqueous mounting medium used to the cover slip but before application of mounting medium, PBS was used to cause blue of the nuclei. (11) Finally the tissues were studied and photomicrography was taken at the Department of Pathology, BAU, Mymensingh using compound microscope and photomicrographic camera (Olympus PM-C 35 Model).

RESULTS AND DISCUSSION

Gross pathology: For sequential gross pathological study from each group, 5 chicks were sacrificed at D1, D3, D5, D7 and D9 of PI. Liver showed congestion at D1 of PI. The rate of lesion gradually reduced at D3 and continued upto D9 (20%). The salient lesion of PD was fragile liver that was found at D7 and D9 of post infection. Fragility of liver was not observed at D1, D3 and D5. The lesion congested liver at D7 of PI was corresponded with other report (Pinheiro *et al.*, 2001). Lungs found congested from D1 of PI and continuously reduced from D3 to D9. The rate of congested lung (60%) was prominent at D1 of PI. In heart, congestion was observed at D1 and D3 of PI. Congestion was also identified in spleen at D1 to D5 of PI and it was absent at the last 2 days.

Congestion in spleen at D5 was the early finding in comparison to other, where such lesion was reported also at D7 (Pinheiro *et al.*, 2001). Cheesy material in cecum (20%) was found only at D9 of PI. The time interval of this lesion was apparently similar with other authors and reported at D7 of PI (Pinheiro *et al.*, 2001). From D1 to D9 of PI, congestion was the most

Table 1: Gross pathology found in various organs at different time intervals

Organ	Lesion	Day					Total average (%)
		D1 (n = 5)	D3 (n = 5)	D5 (n = 5)	D7 (n = 5)	D9 (n = 5)	
Liver	Congestion	3(60%)	2(40%)	1(20%)	1(20%)	1(20%)	32
	Fragile liver	0(0%)	0(0%)	0(0%)	2(40%)	2(40%)	16
Lung	Congestion	3(60%)	2(40%)	2(40%)	1(20%)	1(20%)	36
Heart	Congestion	2(40%)	1(40%)	0(0%)	0(0%)	0(0%)	16
Spleen	Congestion	2(40%)	1(20%)	1(20%)	0(0%)	0(0%)	16
Cecum	Cheesy material in cecum	0(0%)	0(0%)	0(0%)	0(0%)	1(20%)	4

D1 = Day1, D3 = Day3, D5 = Day5, D7 = Day7, D9 = Day9, n = Sample size, % = Percentage

Table 2: Reisolation of *Salmonella pullorum* from various organs of experimentally infected chicks at different time intervals

Day	Number of culture positive <i>S. pullorum</i> isolates from different organs					
	Liver	Lungs	Heart	Spleen	Crop	Cecum
D1 (n = 5)	2	2	0	0	3	4
D3 (n = 5)	2	2	1	1	2	4
D5 (n = 5)	3	2	0	2	2	3
D7 (n = 5)	3	2	0	0	2	3
D9 (n = 5)	3	3	0	0	2	3
Total positive (%)	13(52%)	12(48%)	01(4%)	03(12%)	11(44%)	17(68%)

n = Sample size, % = Percentage, S = *Salmonella*

prominent lesion in liver, lung, heart and spleen. Highest congestion was observed in lung (36%) and subsequently liver (32%), spleen (16%) and heart (16%) respectively. Except spleen these ratios were apparently similar to the findings of Haider (2009). The author reported congestion in lung (30%), liver (30%) and spleen (46%) from 1-4 wks of PI. No striking lesions were detected in control groups. Table 1 represented the sequential gross pathological changes.

Reisolation of *Salmonella pullorum*: This study was emphasized on sequential pathological lesions in different organs of chicks. To get the complete information caused by inoculated *Salmonella pullorum* bacteria, reisolation procedures were performed by some routine methods. Table 2 represented that cecum (68%) was the prominent organ for reisolation of *Salmonella pullorum* and then liver (52%), lung (48%), crop (44%), spleen (12%) and heart (4%) respectively from D1 to D9. It was confirmed by observing the colony characters of *Salmonella pullorum* on Brilliant Green Agar (BGA), *Salmonella-Shigella* (SS) agar and Triple Sugar Iron (TSI) agar. Out of 150 samples 57 gave positive colony characters of *Salmonella pullorum*. For more confirmation of *Salmonella pullorum* reisolation, carbohydrate fermentation test of some basic sugars and biochemical test was performed. 5 Isolates were selected for this purpose. All isolates were ensured of *Salmonella pullorum* organism. Control groups did not exhibit any sorts of bacterial reisolation. The colony characters of reisolated *Salmonella pullorum* were whitish or slight grayish colonies on SS agar, black color colonies on TSI and pink white color colony on BGA which was corresponded with other reports (Hossain *et al.*, 2006; Perez *et al.*, 2004; Haider *et al.*, 2003; Sharma

and Katock, 1996; Old, 1990). In Gram's staining, morphologically the reisolated bacteria were rod shaped, gram negative and single or paired in arrangement that was supported by others (Haider *et al.*, 2003; Freeman, 1985). The results of carbohydrate fermentation and biochemical test of reisolated *Salmonella pullorum* were similar to the other authors (Haider *et al.*, 2003; Khan *et al.*, 1998; Crichton and Old, 1990).

Histopathology: Table 3 showed the histopathological changes found in various organs at different time intervals. Tissues (liver, lung, heart, spleen and cecum) were processed to study the sequential histopathological changes at different time intervals (D1, D3, D5, D7 and D9). Congestion and hemorrhage was found in liver from D1 of PI. The rate of lesion gradually decreased from D3 to D9 respectively. D1 was the time point where highest level of liver (80%) showed congestion and hemorrhagic lesions. Hepatitis began from the D1 of PI. From D5, it began to increase and continued upto next D7 and D9 of PI. In these days highest number of liver (60%) showed hepatic lesions. Aggregation of inflammatory cells or nodule formation in liver was a striking lesion of PD. This type of lesion began to develop at D7 (Fig. 1) of PI and found as growing rate (40%) at D9 (Fig. 2) of PI. Nodulation at D7 in liver was reported by Haider (2009). The cause can not be explained in case of absence of nodular lesion at the initial stage of infection. It can be summarized that the salient nodular lesion in liver was observed at D7 and D9 of PI.

In lungs congestions and hemorrhage found at D1 and continuously began to reduce from D3 to D9. At D9 lowest number of lungs (20%) showed congestion and

Table 3: Histopathological changes found in various organs at different time intervals

Organ	Lesion	Day					Total average rate (%)
		D1 (n = 5)	D3 (n = 5)	D5 (n = 5)	D7 (n = 5)	D9 (n = 5)	
Liver	Congestion and hemorrhage	4 (80%)	3 (60%)	2 (40%)	1 (20%)	1 (20%)	44
	Hepatitis	1 (20%)	1 (20%)	2 (40%)	3 (60%)	3 (60%)	40
	Aggregation of inflammatory cells/nodule formation	0 (0%)	0 (0%)	0 (0%)	1 (20%)	2 (40%)	12
Lung	Congestion and hemorrhage	4 (80%)	3 (60%)	2 (40%)	2 (40%)	1 (20%)	48
	Infiltration of inflammatory cells	1 (20%)	1 (20%)	2 (40%)	3 (60%)	3 (60%)	40
	Pneumonia and bronchopneumonia	1 (20%)	1 (20%)	2 (40%)	3 (60%)	4 (80%)	44
Heart	Congestion and hemorrhage	2 (40%)	1 (20%)	1 (20%)	0 (0%)	0 (0%)	16
Spleen	Congestion and hemorrhage	2 (40%)	2 (40%)	1 (20%)	0 (0%)	0 (0%)	20
	Depletion of lymphocytes	0 (0%)	0 (0%)	0 (0%)	2 (40%)	3 (60%)	20
Cecum	Typhlitis	0 (0%)	0 (0%)	1 (20%)	1 (20%)	2 (40%)	16
	Desquamation of lining epithelium	0 (0%)	0 (0%)	0 (0%)	1 (20%)	2 (40%)	12

D1 = Day1, D3 = Day3, D5 = Day5, D7 = Day7, D9 = Day9, n = Sample size, % = Percent

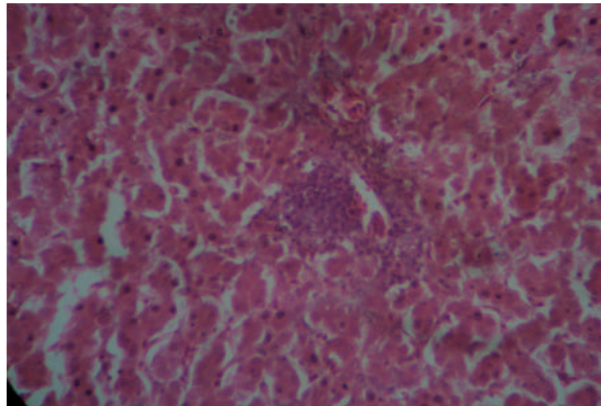


Fig. 1: Aggregation of inflammatory cells in liver, D7 of post infection (H and E stain, 40x object)

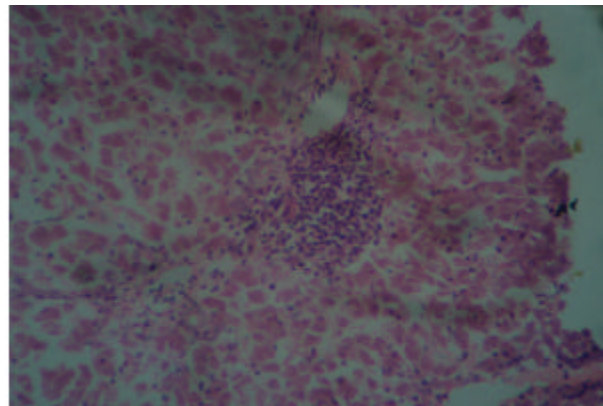


Fig. 2: Aggregation of inflammatory cells in liver, D9 of post infection (H and E stain, 40x object)

hemorrhagic lesion. Cellular infiltration was observed at D1 which gradually increased up to last day of infection. Lungs (60%) of D7 (Fig. 3) and D9 found mostly identified lesion of cellular infiltration. Pneumonia and bronchopneumonia was the salient feature of salmonellosis. Such type of lesion was found at preliminary stage of infection. From D5 (Fig. 4) the lesion began to increase and continued upto D9. Most of the lungs (80%) of D9 showed pneumonia and bronchopneumonia. These sorts of gradual changes also supported by Haider (2009). It can be notified that the proficient lesions of lung, pneumonia and bronchopneumonia were detected from D1 and

increased upto D9. Congestion and hemorrhage were prominent in heart at D1 (40%). The lesions found to reduce at D3 and D5. Congestion and hemorrhage were not recorded at D7 and D9. No other lesions were observed from D1 to D9 in heart. Depletion of lymphocytes is an important lesion of spleen (Khan *et al.*, 1998). This lesion was observed D7 (Fig. 5) of PI and found as upgraded rate (60%) at D9 of PI. Besides this lesion, congestion and hemorrhage was also found at D1 to D5. D5 was the time point of less congestion rate in spleen (20%). Depletion of lymphocytes was a notified lesion of PD in spleen. In cecum, typhlitis was found at D5 of PI. With the increase of the day, lesion began to

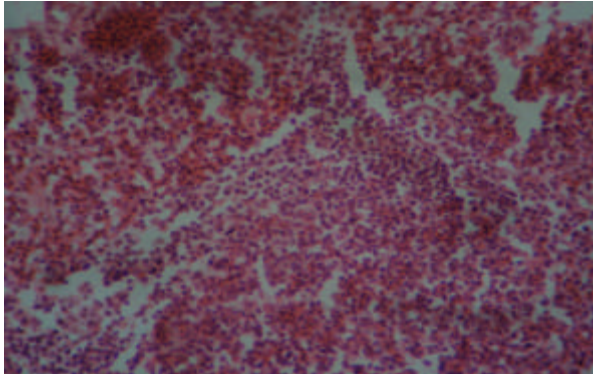


Fig. 3: Thickened alveolar septa with infiltration of inflammatory cells, D7 (H and E stain, 40x object)

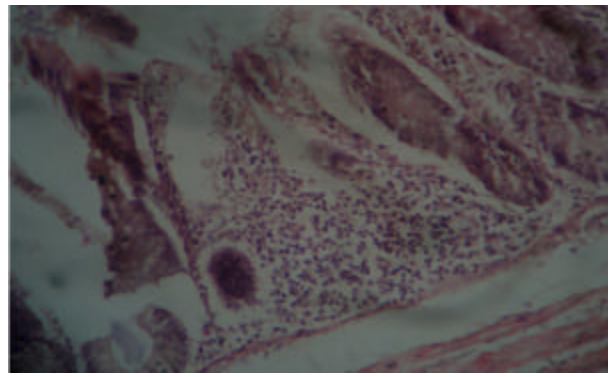


Fig. 6: Infiltration of inflammatory cells (typhlitis) with desquamation of epithelial lining of cecum, D9 of PI (H and E stain, 40x object)

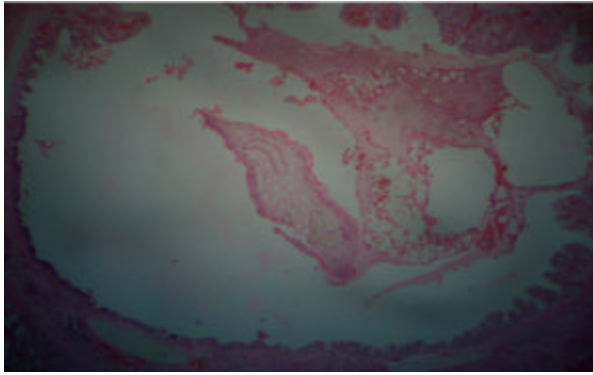


Fig. 4: Exudates in lumen of bronchus of lung (pneumonia), D5 of PI (H and E stain, 10x object)

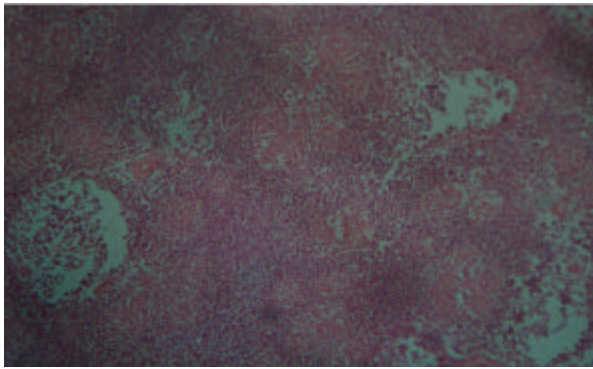


Fig. 5: Depletion of lymphocytes of spleen, D7 of post infection (H and E stain, 10x object)

become prominent in cecum (40%) at D9 (Fig. 6) of PI. Typhlitis at D5 was apparently similar to others where this lesion was reported at D3 of PI in mice (Mrutyunjay *et al.*, 2006). Desquamation of lining epithelium stated at D7 (Dhillon *et al.*, 2001) and continuously found with a growing feature. The salient lesion typhlitis was not detected at the early stage of infection. There were no notified lesions observed in control groups.

Table 4: Immunohistochemical detection of *Salmonella pullorum* organism in various tissues at different time intervals

Day	Organ	Finding (Positive case/Total number)
D1	Liver (n = 2)	Negative
	Lung (n = 3)	Negative
	Cecum (n = 3)	Negative
	Crop (n = 3)	Negative
D3	Liver (n = 2)	+ (1/2)
	Heart (n = 1)	Negative
	Spleen (n = 1)	Negative
	Crop (n = 2)	+ (1/3)
D5	Cecum (n = 3)	+ (1/3)
	Liver (n = 3)	Negative
	Lung (n = 2)	Negative
	Crop (n = 2)	Negative
D7	Cecum (n = 3)	Negative
	Liver (n = 3)	+ (1/3)
	Lung (n = 2)	Negative
	Crop (n = 2)	Negative
D9	Cecum (n = 3)	+ (1/3)
	Liver (n = 3)	Negative
	Lung (n = 2)	Negative
	Crop (n = 2)	Negative
Total samples = 50		Total positive = 5

Immunohistochemistry: The positive isolated tissues in culture were selected and processed for this purpose. Out of 50 samples, 5 showed positive result. The localization of *S. pullorum* was characterized by rod shaped reddish brown colored organism in the cytoplasm of hepatocytes (Fig. 7 and 8), cytoplasm of lining epithelium of crop (Fig. 9) and cecum. Liver, crop and cecum of D3 as well as the liver and cecum of D7 gave positive result. The localization of bacteria was prominent in D3 than the other points of time intervals. The result of immunohistochemistry showed in Table 4. No localization was observed in control group. Detection of *S. pullorum* in liver and cecum also reported by others (Christine *et al.*, 1999; Henderson *et al.*, 1999). Pullorum organism was detected in crop, where the other authors reported detection of *Salmonella typhimurium* in crop (Sara *et al.*, 2004). Liver, crop and cecum of D3 as well

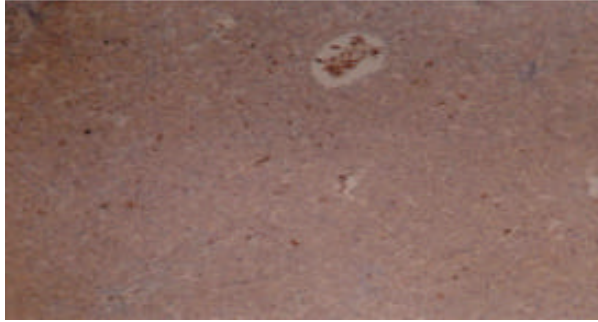


Fig. 7: *Salmonella pullorum* organism in liver at D3 of post infection (10x object). Characterized by reddish brown colored rod shaped organism in the cytoplasm of hepatic cells

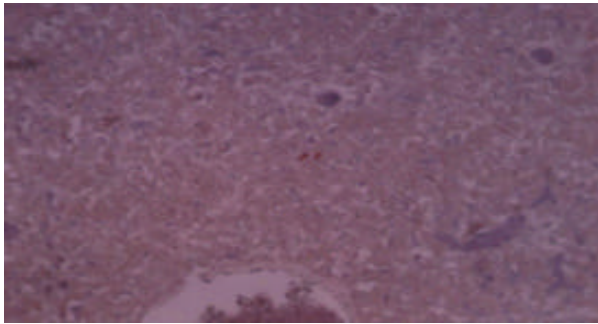


Fig. 8: *Salmonella pullorum* organism in liver at D7 of post infection (10x object). Characterized by reddish brown colored rod shaped organism in the cytoplasm of hepatic cells

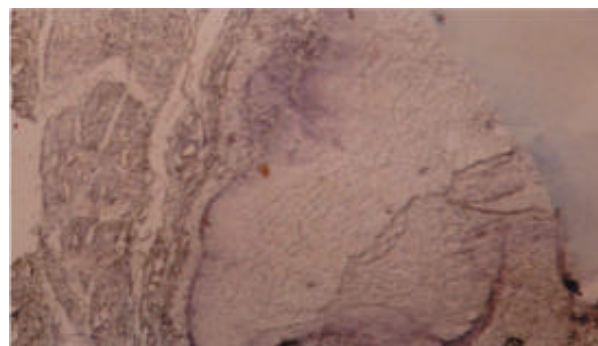


Fig. 9: *Salmonella pullorum* organism in crop at D3 of post infection (40x object). Characterized by reddish brown colored rod shaped organism in the cytoplasm of crop epithelium

as the liver and cecum of D7 gave positive result. The localization of bacteria in cecum and liver at D3 supported by other reports (Christine *et al.*, 1999). It can be notified that the bacterial localization was prominent

in D3 than D7 and the cause of this event can not be explained well.

ACKNOWLEDGEMENT

The authors are grateful to ATT (Agricultural Technology Transfer) project of BARC (Bangladesh Agricultural Research Council) for the financial support of this research work.

REFERENCES

- Christine, S., Henderson, I. Denise, Bounous and D.L. Margie, 1999. Early events in the pathogenesis of avian salmonellosis. *Infect. Immun.*, 67: 3580-3586.
- Crichton, P.B. and D.C. Old, 1990. Salmonellae of serotypes Gallinarum and Pullorum grouped by biotyping and fimbrial-gene probing. *J. Med. Microbiol.*, 32: 145-152.
- Dhillon, A.S., H.L. Shivaprasad, P. Roy, B. Alisantosa, D. Schaber, D. Bandli and S. Johnson, 2001. Pathogenicity of environmental origin salmonellas in specific pathogen-free chicks. *Poult. Sci.*, 80: 1323-1328.
- Freeman, B.A., 1985. *Barrow's Text Book of Microbiology*. 22nd Edn., W.B. Saunders Company, London UK, pp: 372-472.
- Haider, M.G., 2009. Pathogenesis of Pullorum disease in chickens. Ph.D thesis, submitted to the Department of Pathology, Bangladesh Agricultural University, Mymensingh., pp: 74-78.
- Haider, M.G., M.G. Hossain, M.S. Hossain, E.H. Chowdhury, P.M. Das and M.M. Hossain, 2003. Isolation and characterization of enterobacteria associated with health and disease in Sonali chickens. *Bangl. J. Vet. Med.*, 2: 15-21.
- Henderson, S.C., D.I. Bounous and D.M. Lee, 1999. Early events in the pathogenesis of avian salmonellosis. *Infect. Immun.*, 67: 3580-3586.
- Hossain, M.S., E.H. Chowdhury, M.M. Islam, M.G. Haider and M.M. Hossain, 2006. Avian salmonellosis Infection: Isolation and identification of organisms and histopathological study. *Bangl. J. Vet. Med.*, 4: 07-12.
- Islam, M.M., M.G. Haider, E.H. Chowdhury, M. Kamruzzaman and M.M. Hossain, 2006. Seroprevalence and pathological study of *Salmonella* infections in layer chickens and isolation and identification of causal agents. *Bangl. J. Vet. Med.*, 4: 79-85.
- ISO, 1995. International Organisation for Standardisation. Recommendation of meeting of the International Organisation for standardisation of meat and meat Products ISO/TC-34/Sc.6. The Netherlands., 10-18 Nov.
- Khan, A.H.M.N.A., A.S.M. Bari, M.R. Islam, P.M. Das and M.Y. Ali, 1998. Pullorum disease in semi mature chickens and its experimental pathology. *Bang. Vet. J.*, 32: 124-128.

- Luna, L.G., 1968. Manual of Histologic Staining Methods of the Armed Forces Institute of Pathology. 3rd Edn., McGraw Hill Book Co. New York, USA.
- Mrutyunjay, S., J. Jonathan, H. Siegfried, K. Marcus, S. Thomas, A.B. Paul and D.H. Wolf, 2006. Virulence of Broad- and narrow-host-range *Salmonella enterica* Serovars in the streptomycin-pretreated mouse model. Infect. Immun., 74: 632-644.
- Noujaim, J.C., R.L.A. Filho, E.T. Lima, A.S. Okamoto, R.L. Amorim and R.T. Neto, 2008. Detection of T lymphocytes in intestine of broiler chicks treated with *Lactobacillus* sp. and challenged with *Salmonella enterica* Serovar Enteritidis. Poult. Sci., 87: 927-933.
- Old, D.C., 1990. *Salmonella*. In: Topley and Wilson's Principles of Bacteriology, Virology and Immunology. 8th Edn., Parker, M.T and Duerden, B.I. (Ed). Vol:2. Systemic Bacteriology. Edward Arnold. A division of Hodder and Stoughton, London, UK, pp: 470-475.
- Perez, C., S. Rivera, A. Pirela, H. Rincon, Y. Mavarez and R. Roman, 2004. Isolation of *Salmonella* in poultry carcasses and evaluation of the effectiveness of different enrichment and selective media. Revist. Cientific Facult. Genti. V. Univers. Del Zulia., 14: 177-185.
- Pinheiro, L.A.S., O.G.H. De and J.A. Berchieri, 2001. Experimental *Salmonella enterica serovar pullorum* infection in two commercial varieties of laying hens. Avian Pathol., 30: 129-133.
- Roy, H., A.S. Dhillion, H.L. Shivaprasad, D.M. Schaberg, D. Bandil and S. Johnson, 2001. Pathology of different serogroups of avian salmonellae in specific-pathogen-free chickens. Avian. Dis., 45: 922-937.
- Sara, A.J., W.G. Ronald, V.W. Irene and G.S. Colin, 2004. *Salmonella enterica Serovar typhimurium* colonization of the crop in the domestic turkey: Influence of probiotic and prebiotic treatment (*Lactobacillus acidophilus* and Lactose). Avian. Dis., 48: 279-286.
- Sharma, M. and R.C. Katock, 1996. Deadly outbreak in the chicks owing to *Salmonella typhimurium*. Ind. J. Poult. Sci., 31: 60-62.