

ISSN 1682-8356
ansinet.org/ijps



INTERNATIONAL JOURNAL OF
POULTRY SCIENCE

ANSI*net*

308 Lasani Town, Sargodha Road, Faisalabad - Pakistan
Mob: +92 300 3008585, Fax: +92 41 8815544
E-mail: editorijps@gmail.com

Hepatoprotective Activity of Superliv Liquid and Repchol in CCl₄ Induced FLKS Syndrome in Broilers

P. Sonkusale¹, A.G. Bhandarker¹, N.V. Kurkare¹, K. Ravikanth², S. Maini² and D. Sood²

¹Department of Veterinary Pathology, NVC, MAFSU, Nagpur, India

²R and D Team, Ayurved Limited, Baddi (H.P.), India

Abstract: A 6 week long experimental trial was conducted to study whether the supplementation of herbal products Superliv liq. and Repchol (supplied by M/S Ayurved Limited, Baddi, India) are efficacious in treatment of liver and kidney due to CCl₄. A total of 75 Cobb day old broilers were divided into three equal groups (n = 25). Group A served as negative control, group B (positive control) and C (treatment group) were induced with FLKS with CCL₄ @1 ml/kg body weight orally, administered every 3rd day during 15-28 days of trial. Treated group C were given Superliv Liq. @5 ml/100 chicks/day for first 2 weeks and @ 10 ml/100 chicks/day for 3-6 weeks along with drinking water in combination with Repchol@500 gm/ton of feed from 0-6 weeks. Fatty liver and kidney syndrome lead to depression in growth rate, lowered feed efficiency and disturbances in immunopathological and biochemical parameters. Final mean body weight of group C was significantly (p<0.01) higher than group A and B. A significant (p<0.01) decrease in feed conversion ratio was observed in group C as compared to group B. A significant (p<0.01) decrease in level of cholesterol, triglycerides, HDL, VLDL, creatinine, liver enzymes (SGOT and SGPT) and increase in serum protein level was recorded in group C as compared to group B on 28th and 42nd day of experiment, which was in confirmation with the values of negative control group A, falling into normal range. Gross and histopathology of liver and kidney revealed that there was mild congestion and negligible degenerative changes in group C in contrast to severe changes of FLKS syndrome in group B. It can be concluded that liver tonic Superliv liquid along with phytoadditive Repchol (supplement for choline and biotin) efficaciously ameliorated the CCl₄ induced toxicity, when administered prophylactically in broilers.

Key words: CCL₄, fatty liver, polyheral, hepatoprotective, immunostimulant

INTRODUCTION

Liver, an important organ actively involved in many metabolic functions and is the frequent target for a number of toxicants (Meyer and Kulkarni, 2001). Hepatic damage is generally coupled with alteration of a range of metabolic functions (Wolf, 1999). Liver disease is still a worldwide health problem. Fatty Liver and Kidney Syndrome (FLKS) is a metabolic disease in poultry that may occur either due to metabolic or nutritional disturbances or chemical intoxication. FLKS is characterized by disproportionate infiltration of lipid in the liver and kidney, enlarged friable liver, hypercholesterolemia, decreased performance and poor egg production in poultry (Simpson and Harms, 1983). It is a consequence of imbalance in energy metabolism leading to altered fat metabolism and hence the fatty infiltration in liver and other vital organs (Whitehead *et al.*, 1978). Among chemical agents, CCl₄, a hepatotoxic chemical agent is by and large used to produce experimental model to study hepatic cirrhosis and fibrosis in experimental animals (Tsukamoto *et al.*, 1990). It is well established that CCl₄ induces

hepatotoxicity by metabolic activation; therefore it selectively causes toxicity in liver cells maintaining semi-normal metabolic function (Mujumddar *et al.*, 1998). Exposure to CCl₄ results in hepatic steatosis, centrilobular necrosis and ultimately cirrhosis in liver and acute tubular necrosis in kidney (Karmia, 2007). Hepatoprotection by conventional or synthetic drugs used in the treatment of liver diseases are inadequate and sometimes can have serious side effects (Guntupalli *et al.*, 2006). In the absence of a reliable liver protective drug in modern medicine there are a number of medicinal preparations in Ayurveda recommended for the treatment of liver disorders (Chatterjee, 2000). In view of severe undesirable side effects of synthetic agents, there is an emerging focus to follow systematic research methodology and to evaluate scientific basis for the traditional herbal medicines that are claimed to possess hepatoprotective activity. Therefore, the present investigation was undertaken to assess the prophylactic activity of polyherbal formulations Superliv liquid in combination with Repchol (supplied by M/S Ayurved Limited, Baddi, India) in CCl₄ induced FLKS in broilers.

MATERIALS AND METHODS

An experimental study on 75 day old broiler (Cobb) chicks was conducted at Dept. of Veterinary Pathology, Nagpur Veterinary College, Nagpur, Maharashtra, India. Chicks were randomly divided into three groups each comprising of 25 chicks. Group A served as negative control, Group B (positive control) and C (treatment group). Group B and C were induced with FLKS with CCl₄ @1 ml/kg body weight orally, administered every 3rd day during 15-28 days of trial. Treated group C was given Superliv Liq. @ 5ml/100 chicks/day for first 2 weeks and @10 ml/100 chicks/day for 3-6 weeks in combination with Repchol@ 500 gm/ton of feed (supplied by M/S Ayurvet Limited, Baddi, India) from 0-6 weeks. Superliv Liquid is a polyherbal containing extracts of herbal ingredients that help to improve liver functions thus ensuring better feed utilization and improved productivity and Repchol is having natural analogues of choline and biotin for the replacement of similar synthetic entities in feed. All the birds were routinely vaccinated with Lasota on day 5th and 21st of age, while IBD on 14th day of age. All the groups were offered similar commercial broiler feed throughout the experimental period (0-42 days) without any additional supplementation of methionine, choline and biotin in order to induce hepatic syndrome and were kept under standard managemental conditions.

Parameters evaluated: weekly body weight and mean weight gain in birds of the three groups was recorded during complete experimental study. Also, feed offered to birds and the feed that was left uneaten, was recorded weekly in order to calculate the Feed Conversion Ratio (FCR). The blood samples were collected from 10 representative birds per group twice during 6 week long experimental period, i.e. on 28th day of age (at termination of CCl₄ dosing) and on 42nd day of age (at termination of all treatments), in order to evaluate the various biochemical and immunopathological parameters namely Aspartate amino Transferase (SGOT), Alkaline Amino Transferase (SGPT), protein,

albumin, globulin, cholesterol, Triglycerides, High Density Lipid (HDL), Very Low Density Lipid (VLDL), Low Density Lipid (LDL) and creatinine. These parameters were estimated using diagnostic kits (Qualigens Pvt. Ltd, Mumbai) by employing UV/Vis spectrophotometer. The histopathology was conducted on 28th and 42nd day of age on representative 5 birds/group. Samples of liver and kidney were collected and fixed in 10% formalin. The tissues were processed by usual method for paraffin embedding and stained with haematoxylin and eosin (H and E). The statistical analysis of the data was done by applying the Randomized Block Design (RBD).

RESULTS AND DISCUSSION

Growth parameters: The findings on weekly body weight, body weight gain and FCR are depicted in Table 1, 2 and 3 respectively. Final mean body weight of the prophylactically treated birds with Superliv and Repchol (group C) was significantly ($p < 0.01$) higher than fatty liver induced positive control group B and the healthy birds (group A). The mean FCR value of prophylactically treated group C was significantly lower than positive control group B indicating efficacy of liver stimulants in improving gut function, metabolism, nutrient assimilation and utilization. Similar findings have been reported by Singh *et al.*, 2002, in broilers.

Biochemical parameters

SGOT and SGPT: The activities of SGOT and SGPT are the most commonly used biomarkers of liver damage (Sturtgill and Lambart, 1997). The hepatotoxic action of CCl₄ is due to its toxic metabolite trichloromethyl radicals (He *et al.*, 2006; Lee *et al.*, 2007). The SGOT and SGPT values were found to be elevated significantly ($p < 0.01$) in CCl₄ intoxicated group B as compared to healthy control group A on 28th and 42nd day of experiment (Table 4 and 5). The results in present study for group B are in concurrence with those reported by Kanter *et al.* (2005) and Dahiru *et al.* (2005) who reported a significant increase in SGOT and SGPT in

Table 1: Weekly gain in body weight in groups A-C during experimental period

Group	Weekly body weight gain (g)					
	1 st	2 nd	3 rd	4 th	5 th	6 th
Group A	95.92 ^a	210.60 ^a	291.76 ^a	301.52 ^b	438.70 ^a	440.50 ^a
Group B	98.48 ^a	212.84 ^a	271.84 ^b	279.68 ^b	446.85 ^a	408.80 ^a
Group C	106.04 ^b	214.08 ^a	291.64 ^a	308.96 ^b	470.05 ^b	475.30 ^b

Mean with different superscripts in a column differ significantly ($p < 0.01$ or 1%)

Table 2: Weekly body weight of groups A-C during experimental period (0-42 days)

Group	0 day	1 st week	2 nd week	3 rd week	4 th week	5 th week	6 th week
A	41.80	137.68 ^a	353.28 ^a	640.04 ^a	941.56 ^a	1379.25 ^a	1819.75 ^a
B	42.00	140.40 ^a	353.24 ^a	625.08 ^a	904.76 ^a	1351.95 ^a	1760.50 ^a
C	42.00	148.08 ^b	362.16 ^b	653.80 ^b	962.76 ^b	1424.70 ^b	1900.00 ^b

Mean with different superscripts in a column differ significantly ($p < 0.01$ or 1%)

Table 3: Mean Feed Conversion Ratio (FCR) of the birds of group A-C during experimental period

Week	Group A	Group B	Group C
1 st	1.12	1.13	1.00
2 nd	1.30	1.32	1.28
3 rd	1.45	1.54	1.49
4 th	1.67	1.69	1.66
5 th	1.80	1.82	1.77
6 th	2.08	2.10	1.91
Mean FCR	1.57 ^a	1.6 ^b	1.52 ^a

Mean with different superscripts in a column differ significantly ($p < 0.01$ or 1%)

CCl₄ induced fatty liver in rats. However, the values of these enzymes were recorded to get normalized in prophylactically treated group C with a combination of hepatoprotectants Superliv Liq. and herbal supplement to meet the choline requirement; the values were well comparable to that of healthy control group A. This indicates efficacy of active ingredients (alkaloids, myristic and oxalic acids) of constituent herbs of Superliv Liq. viz. *Boerhavia diffusa*, *Andrographis paniculata* that are scientifically well proven to reduce SGPT and SGOT levels, increase liver ATPase activity; thus having protective effect on liver. In addition to this, supplementation of Repchol might have also contributed to normalization of liver enzyme as reported by (Jadhav *et al.*, 2009) in broilers.

Hypoproteinaemia and albuminuria: In case of hepatotoxicity or liver damage there is hypoproteinaemia and albuminuria as evident by a significant ($p < 0.01$) decrease in serum protein and albumin level in case of CCl₄ intoxicated birds of group B on 28th day of experiment when compared to negative healthy control (group A). Samudram *et al.* (2008) also reported a significant decrease in serum proteins in CCl₄ induced hepatic damage in rats. The values of these parameters were recorded to get normalized in prophylactically treated group C well comparable to healthy control group A (Table 4). However, the values were non-significantly ($p > 0.05$) different among three groups on day 42nd. The findings are well corroborated with those of Verma and Lal (1997), according to whom, supplementation of Superliv lead to increase in total serum proteins, normalization of other haematobiochemical parameters thus improving overall productivity in White Plymouth Rock layers and with those reported by (Jadhav *et al.*, 2009) that supplementation of Repchol in broilers might have also lead to increase in levels of total serum proteins.

Lipid profile: In case of nutritional or metabolic or chemical toxicity complicating into fatty liver and the damage of hepatic tissue thereby; the fat metabolism in

Table 4: Biochemical estimates of serum sample collected from broilers of group A-C on day 28th day of experiment

Parameters	Group A	Group B	Group C
SGOT	268.38 ^a	290.79 ^b	261.94 ^a
SGPT	20.16 ^a	34.35 ^b	21.86 ^a
Protein	4.67 ^a	4.20 ^b	4.60 ^a
Albumin	1.63 ^a	1.57 ^a	1.69 ^a
Globulin*	3.04 ^b	2.66 ^a	2.90 ^b
Cholesterol	118.31 ^a	138.28 ^b	120.72 ^a
Triglycerides	65.59 ^a	74.78 ^b	63.06 ^a
HDL*	74.25 ^a	89.52 ^b	77.64 ^a
VLDL	13.11 ^a	14.95 ^b	12.61 ^a
LDL	30.93 ^a	33.80 ^a	30.46 ^a
Creatinine	0.780 ^a	0.868 ^b	0.824 ^a

Mean with different superscripts in a row differ significantly ($p < 0.01$ or 1%). *Indicate the mean with different superscripts in a row differ significantly ($p < 0.05$ or 5%)

Table 5: Biochemical estimates of serum sample collected from broilers of group A-C on day 42nd of experiment

Parameters	Group A	Group B	Group C
SGOT*	261.91 ^a	266.47 ^a	237.64 ^b
SGPT	29.16 ^a	19.60 ^b	10.28 ^a
Protein	4.21 ^a	4.11 ^a	4.43 ^a
Albumin	1.11 ^a	1.10 ^a	1.23 ^a
Globulin	3.09 ^a	3.00 ^a	3.20 ^a
Cholesterol*	123.86 ^a	127.30 ^b	108.44 ^a
Triglycerides	75.42 ^a	79.73 ^b	62.17 ^a
HDL	71.52 ^a	73.16 ^b	65.9 ^a
VLDL	15.082 ^a	15.94 ^a	12.43 ^b
LDL	37.26 ^a	38.19 ^a	30.07 ^b
Creatinine	0.89 ^a	0.91 ^a	0.75 ^b

Mean with different superscripts in a row differ significantly ($p < 0.01$ or 1%). *Indicate the mean with different superscripts in a row differ significantly ($p < 0.05$ or 5%)

the liver is affected leading to hypercholesterolemia and increased levels of serum triglycerides, HDL and VLDL in affected birds (Karmia, 2007). At day 28th day, the levels of serum cholesterol, triglycerides, HDL and VLDL were found to be significantly ($p < 0.01$) increased in CCl₄ intoxicated group B as compared to negative control group A. However, the values of these biochemical parameters were recorded to get normalized in prophylactically treated group C well comparable to that of group A and significantly ($p < 0.01$) lower than group B on day 28th and 42nd of experiment (Table 4 and 5). This may be attributed the individual constituent herbs of Superliv liq. namely *Phyllanthus emblica*, *Picrorrhiza kurroa* etc., which are scientifically well established to possess hypocholesterolemic activity (Khanna *et al.*, 1994). In addition to above, the constituent herbs of Repchol namely; *Citrullus colocynthis*, *Achyranthus aspera* are also popularly being used for the treatment of fatty liver and hepatopathies (Wafsi, 1994; Gokhale *et al.*, 2002). Jadhav *et al.* (2009), also reported similar findings of hypocholesterolemic activity of Repchol supplementation in broilers.

Serum creatinine: It is a marker of kidney damage (Adelman *et al.*, 1981). Serum creatinine levels were significantly ($p \leq 0.05$) higher in CCl₄ intoxicated group B (Table 5). However, values were found to be normalized in prophylactically treated group C on 42nd day of experiment which was well comparable to group A, indicating the efficacy of constituent herbs of polyherbal products in ameliorating CCl₄ induced liver and kidney damage.

Serum globulins: A significant ($p < 0.05$) decrease in level of serum globulins was evident CCl₄ intoxicated group B as compared to negative control (group A) on day 28th. In contrast, prophylactic treatment with Superliv and Repchol lead to potential increase in the serum globulin level suggesting the role of constituent herbs of polyherbal liver tonic and Repchol in potentiating humoral immune response in broilers (Table 4). However, the values of serum globulins were non-significantly ($p > 0.05$) different as recorded on 42nd day of experiment (Table 5). This might be correlated with the fact that CCl₄ administration was discontinued on day 28th and the birds might have recouped with their immune system. The improvement in humoral immune response in treated group might be correlated with the immunostimulating and immunopotentiating activities of constituent herbs namely *Phyllanthus emblica*, *Andrographis paniculata*, *Boerhaavia diffusa*, *Picrorrhiza kurroa* etc as reported by (Puri *et al.*, 1993; Suresh and Vasudevan, 1994; Mungantiwar *et al.*, 1999).

Gross and histopathological observations: A severe congestion in liver and kidney was evident in CCl₄ intoxicated birds of group B as compared to very mild congestion in prophylactically treated group C on day 28th and 42nd of experiment (Fig. 1-3). On histopathological examination, the liver of positive control (group B) birds showed severe granular and vacuolar degenerative changes with focal necrotic areas (Fig. 5 and 8) as compared to mild degenerative and necrotic changes in prophylactically treated group C birds on 28th and 42nd day of experiment (Fig. 6 and 9). The findings in present study are in confirmation with those reported by Girish *et al.* (2009), that CCl₄ induced fatty liver in mice lead to necrosis, decrease in sinusoidal spaces, fatty degeneration and congestion of liver. Adhesion of glomerular tuft to bowman's capsule along with interstitial hemorrhages including vacuolar and granular degenerative changes were evident in the kidney of CCl₄ intoxicated birds (group B) as observed on day 28th (Fig. 11), this progressed to severe tubular degenerative and hyalinized changes in glomerular tufts including detachment of basement membrane by day

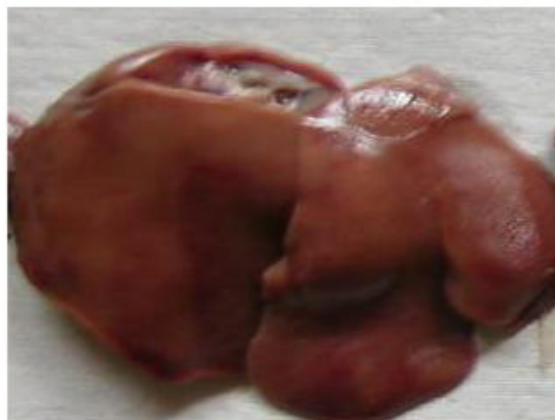

Fig. 1: Group - A Liver showing pale areas congestion on 28th day of experiment

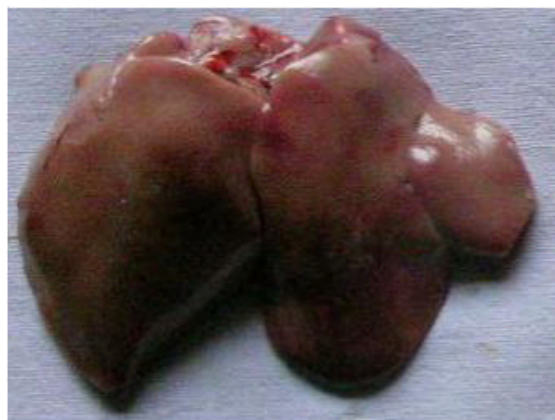

Fig. 2: Group - B Liver showing severe congestion on 28th day of experiment

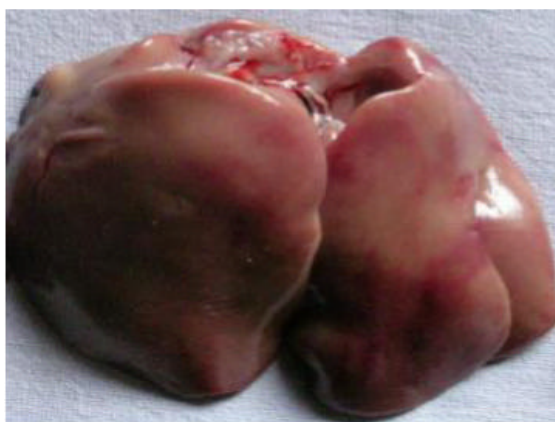

Fig. 3: Group - C Liver showing mild congestion on 28th day of experiment

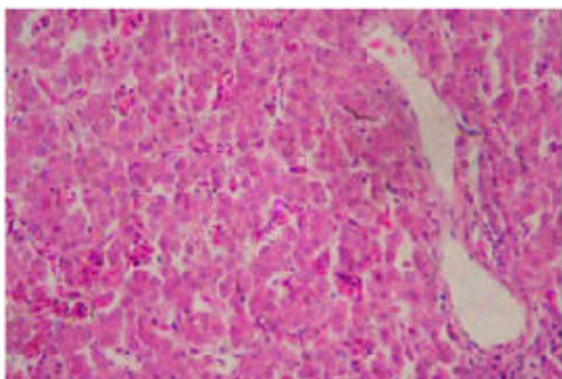


Fig. 4: Group - A Liver showing haemorrhages on 28th day of experiment

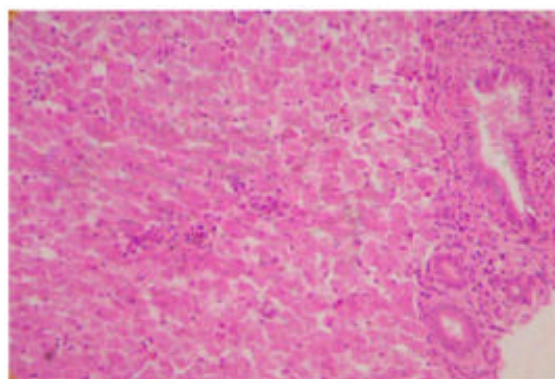


Fig. 7: Group - A Liver showing bile duct hyperplasia on 42nd day of experiment

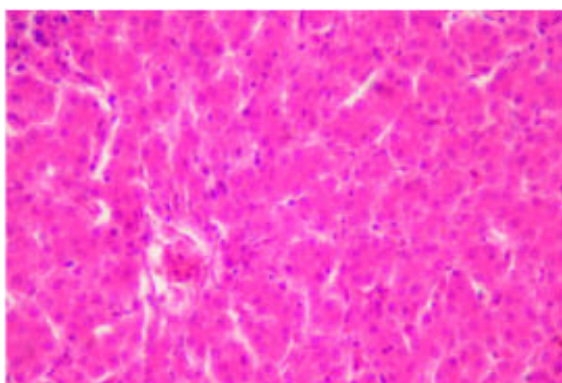


Fig. 5: Group - B Liver showing severe granular degenerative changes resulting decrease in sinusoidal space on 28th day of experiment

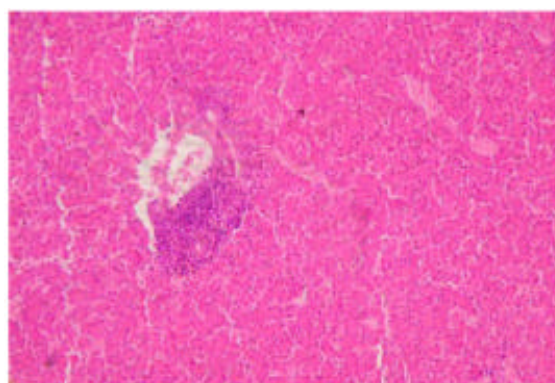


Fig. 8: Group - B Liver showing focal necrosis on 42nd day of experiment

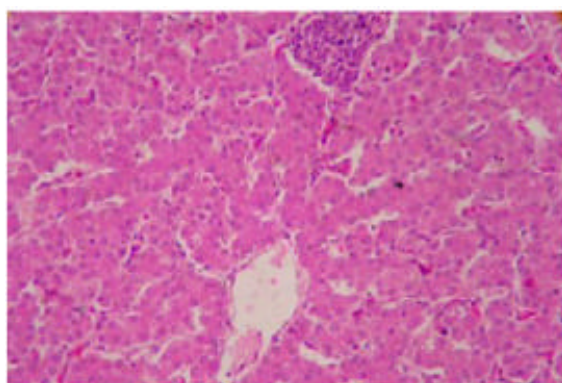


Fig. 6: Group - C Liver showing mild necrotic changes on 28th day of experiment

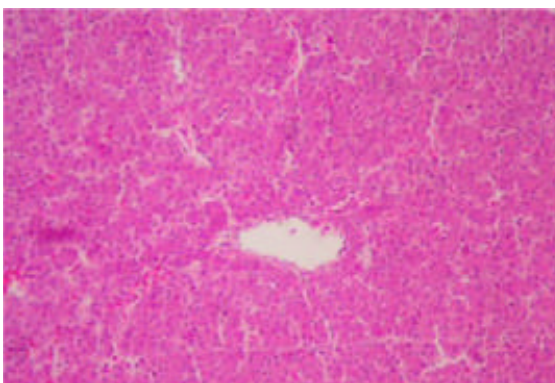


Fig. 9: Group - C Liver returning to normalcy on 42nd day of experiment

42nd indicating the worsening effects of CCl₄ administration on tissues. However, in prophylactically treated group C there were mild hemorrhages and tubular degenerative changes in renal epithelium

(Fig. 12). Due to deficiency of choline and biotin in the diet, the liver (Fig. 4 and 7) and kidney of untreated group A also showed congested areas, hemorrhages, necrotic changes and other histopathological alterations in liver and kidney (Fig. 10).

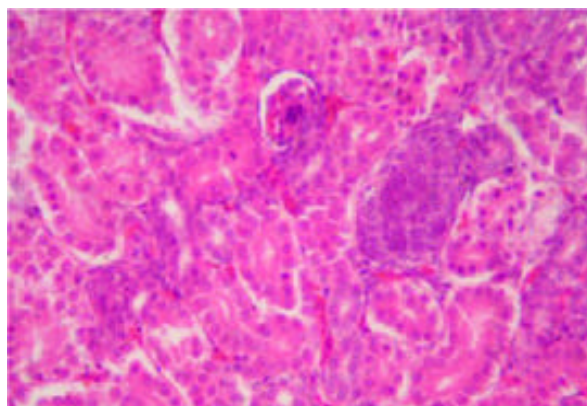


Fig. 10: Group - A Kidney showing haemorrhages and glomerular nephropathies on 28th day of experiment

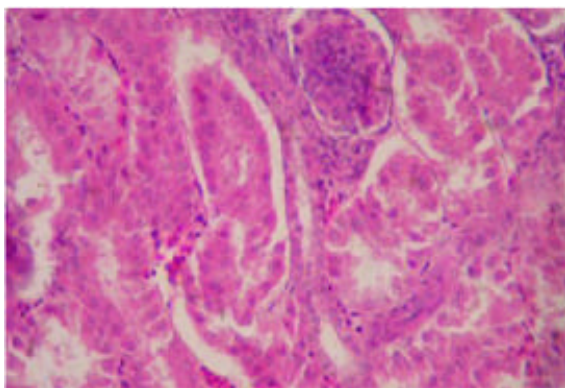


Fig. 11: Group - B Kidney showing severe vacuolar degenerative changes in tubular epithelium and glomerular nephropathies on 28th day of experiment

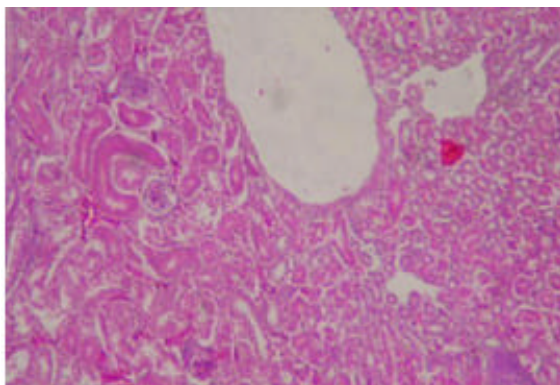


Fig. 12: Group - C Kidney showing degenerative changes and necrotic areas on 28th day of experiment

However, such changes were almost negligible in Repchol and Superliv supplemented group C.

Conclusion: Based on our findings in present study it can be concluded that polyherbal liver tonic product Superliv Liquid alongwith phytoadditive Repchol as a supplement of choline and biotin, can be recommended as a prophylaxis to alleviate the CCl₄ induced liver and kidney damage or hepatotoxicity or nephrotoxicity or FLKS syndrome in poultry.

ACKNOWLEDGEMENT

The authors are thankful to Dean, Nagpur Veterinary College, MAFSU, Nagpur, Maharashtra, India for providing infrastructure facilities and Ayurved limited, Baddi for research protocol and providing samples to conduct the research.

REFERENCES

- Adelman, R.D., W.L. Spangler, F. Beasom, G. Ishizaki and G.M. Conzelman, 1981. Frusemide enhancement of neltimicin nephrotoxicity in dogs. *The J. Antimicrobial Chemotherapy*, 7: 431-440.
- Chatterjee, T.K., 2000. Medicinal plants with hepatoprotective properties. In: *Herbal Options*. 3rd Edn., Calcutta Books and Allied (P) Ltd., pp: 135.
- Dahiru, D., E.T. William and M.S. Nadro, 2005. Protective effect of *Ziziphus mauritiana* leaf extract on carbon tetrachloride-induced liver injury. *Afr. J. Biotechnol.*, 4: 1177-1179.
- Girish, C., B.C. Koner, S. Jayanthi, K.R. Rao, B. Rajesh and S.C. Pradhan, 2009. Hepatoprotective activity of six polyherbal formulations in CCl₄ induced liver toxicity in mice. In: *J. Exp. Biol.*, 47: 257-263.
- Gokhale, A.B., A.S. Damre, K.R. and M.N. Saraf, 2002. Preliminary evaluation of anti-inflammatory and anti-arthritic activity of *S. lappa*, *A. speciosa* and *A. aspera*. *Phytomedicine.*, 9: 433-437.
- Guntupalli, M., V. Chandana, Palpu Pushpangadan and Annie Shirwaikar, 2006. Hepatoprotective effects of rubiadin, a major constituent of *Rubia cordifolia* Linn. *J. Ethnopharmacol.*, 103: 484-490.
- He, S.X., J.Y. Luo, Y.P. Wang, Y.I. Wang, H. Fu, J.L. Xu, G. Zhao and E.Q. Liu, 2006. Effects of extract from *Ginkgo biloba* on carbon tetrachloride-induced liver injury in rats. *World J. Gastroenterol.*, 28:3924-3928.
- Jadhav, N.V., S. Maini and K. Ravikanth, 2009. Comparative efficacy studies of herbal and synthetic choline supplementation on broiler growth and performance. *The Internet J. Vet. Med.*, 5 (2); (online printed matter).
- Kanter, M., O. Coskun and M. Budancamanak, 2005. Hepatoprotective effects of *Nigella sativa* L and *Urtica dioica* L on lipid peroxidation, antioxidant enzyme systems and liver enzymes in carbon tetrachloride-treated rats. *World J. Gastroenterol.*, 11: 6684-6688.
- Karmia Moawad, M., 2007. Possible prophylactic effects of vitamin E or Lycopene treatment on renal toxicity induced by CCl₄ administration in albino rats. *World J. Zool.*, 2: 19-28.

- Khanna, A.K., R. Chander, N.K. Kapoor and B.N. Dhawan, 1994. Hypolipidemic activity of Picroliv in albino rats. *Phytother. Res.*, 8: 403-407.
- Lee, H.S., K.Y. Keum and S.K. Ku, 2007. Effects of *Picrorrhiza* rhizome water extracts on the subacute liver damages induced by carbon tetrachloride. *J. Med. Food*, 10: 110-117.
- McDowell, L.R., 2000. *Vitamins in Animal and Human Nutrition*. Iowa, Iowa State University Press.
- Meyer, S.A. and A.P. Kulkarni, 2001. Hepatotoxicity. In: *Introduction to biochemical toxicology*. 3rd Edn., New York: John Wiley and Sons, pp: 487.
- Mujumddar, A.K., A.S. Upadhyay and A.M. Pradhan, 1998. Effect of *Azadirachta indica* leaf extract on CCl₄ induced hepatic damage in albino rats. *Ind. J. Pharm. Sci.*, 60: 363.
- Mungantiwar, A.A., A.M. Nair, U.A. Shinde, V.J. Dikshit, M.N. Saraf, V.S. Thakur and K.B. Saini, 1999. Studies on the immunomodulatory effects of *Boerhaavia diffusa* alkaloidal fraction. *J. Ethnopharmacol.*, 65: 125-3.
- Puri, A., R. Saxena, R.P. Saxena, K.C. Saxena, V. Srivastava and A. Tandon, 1993. Immunostimulant agents from *Andrographis paniculata*. *J. Nat. Prod.*, 56: 995-999.
- Samudram, P., H. Rajeshwari, R. Vasuki, A. Geetha and P. Sathiyar, 2008. Hepatoprotective activity of Bi - herbal ethanolic extraction CCl₄ induced hepatic damage in rats. *Afr. J. Biochem. Res.*, 2: 061-065.
- Singh, K., N.S. Singh, D.N. Verma and D.S. Singh, 2002. Influence of supplementation of different levels of livfit vet premix in diet on performance of broiler birds. In. *Vet. Med. J.*, 26: 65-66.
- Simpson, C.F. and R.H. Harms, 1983. Aortic atherosclerosis in non laying hens with fatty liver syndrome. *Avian Dis.*, 27: 652-659.
- Sturtgill, M.G. and G.H. Lambart, 1997. Xenobiotic induced hepatotoxicity: Mechanisms of liver injury and methods of monitoring hepatic function. *Clin. Chem.*, 43: 1512-1526.
- Suresh, K. and D.M. Vasudevan, 1994. Augmentation of murine natural killer cell and antibody dependent cellular cytotoxicity activities by *Phyllanthus emblica*, a new immunomodulator. *J. Ethnopharmacol.*, 44: 55-60.
- Tsukamoto, H., M. Matsuoka and S.W. French, 1990. Experimental models of hepatic fibrosis: A review. *Seminar in Liver Dis.*, 10: 56-65.
- Verma, D.N. and S.N. Lal, 1997. Effect of feeding Livfit vet premix on egg production; certain biochemical and hematological parameters in white plymouth rock bird. *Proc. Nat. Symp. held at IVRI., Izatnagar, 14-15, Feb.*
- Wafsi, I.A., 1994. Some pharmacological studies on *Citrullus colocynthis* Z. *J. Herbs, Spices Med. Plants*, 2: 55-69.
- Whitehead, C.C., D.W. Bannister and M.E. Cleland, 1978. Metabolic changes associated with the occurrence of fatty liver and kidney syndrome in chicks. *Br. J. Nutr.*, 40: 221-234.
- Wolf, P.L., 1999. Biochemical diagnosis of liver disease. In. *J. Clin. Biochem.*, 14: 59-64.