

ISSN 1682-8356
ansinet.org/ijps



INTERNATIONAL JOURNAL OF
POULTRY SCIENCE

ANSI*net*

308 Lasani Town, Sargodha Road, Faisalabad - Pakistan
Mob: +92 300 3008585, Fax: +92 41 8815544
E-mail: editorijps@gmail.com

Comparison of the Virulence of Pathogenic Newcastle Disease Viruses Belonging to the Same or Different Genotypes

Ruben Merino¹, Hilda Villegas², Jose A. Quintana¹ and Norma Calderon¹

¹Departamento de Medicina y Zootecnia de Aves, Facultad de Medicina Veterinaria y Zootecnia, Universidad Nacional Autonoma de Mexico. DF, Mexico, 04510

²Departamento de Morfologia Celular y Molecular, Instituto Nacional de Rehabilitacion, Secretaria de Salud, Mexico. DF, Mexico, 14389

Abstract: Virulent Newcastle disease has threatened the Mexican poultry industry since 1946. Two Mexican virulent strains belonging to the Chimalhuacan (Quail2006) and Torreon (Chicken2000) lineages of genetic group V, as well as the ancient Mexican strain named Queretaro and a Beaudette C-like US strain (genotype II) were tested by pathogenesis analysis in commercial 5 weeks old broiler chickens, comparing the lesions severity on primary and secondary lymphoid organs after 24, 36, 48, 60, 72, 84 and 96 h postinoculation (hpi). Organ samples were analyzed by light and electron microscope and by virus isolation. The Quail2006 isolate caused more severe clinical signs and microscopic lesions ($p < 0.05$) in bursa of Fabricius, thymus, spleen and bone marrow of 5 weeks old broiler chickens. Ultra-structural changes were seen as early as 24 hpi and the highest lesion score in different organs was reached between 72 and 96 hpi in some cases. Ultra-structural observation and virus isolation confirmed the virus presence in all evaluated organs. Quail2006 strain was more virulent than Chicken2000, though they belong to the same genotype and is also more virulent than Queretaro and Beaudette C-like strains (genotype II). The virus effect on lymphoid organs enhances its importance in countries where vaccinated commercial poultry is protected against the death, but not against infection or virus replication in lymphoid organs, which can lead to reduced productivity and susceptibility to other infections. Full characterization of NDV should include virulence tests in susceptible animals, besides the standard indices and sequence analysis.

Key words: Newcastle disease virus, pathogenic characterization, virulence

INTRODUCTION

Avian paramyxovirus-1 (APMV-1) is synonymous with Newcastle Disease Virus (NDV), it belongs to the genus Avulavirus, within the family Paramyxoviridae (Mayo, 2002). NDV is a single-stranded negative-strand RNA virus. Its genome codes for six structural proteins: Nucleoprotein (NP), Phosphoprotein (P), Matrix protein (M), Fusion protein (F), Haemagglutinin-neuraminidase protein (HN) and Large protein (L). The strain-dependent differences in tropism and virulence observed with NDV relies upon the presence of cellular proteases required for the activation of the viral Fusion (F) glycoprotein precursor F0 (Glickman *et al.*, 1988; Nagai and Klenk, 1977; Nagai, 1995). The F0 protein of virulent strains is cleaved into subunits F1 and F2 by ubiquitous host proteases found in most tissues. These enable virulent strains to spread faster and widely within the host, whereas the F protein of avirulent strains is cleaved only in cells containing trypsin-like enzymes and hence is limited to digestive or respiratory mucosa (Nagai and Klenk, 1977; Kant *et al.*, 1997). This variation between virulent and avirulent strains is caused by differences in

amino acid sequences at the cleavage site of the fusion protein (Nagai *et al.*, 1976).

NDV strains are further grouped into five pathotypes depending on tissue tropism and hence clinical signs seen in infected chickens (Beard and Hanson, 1984). These include (a) viscerotropic or (b) neurotropic velogenic with high mortality and intestinal lesions or central nervous signs; (c) mesogenic with low mortality, respiratory and nervous signs; (d) lentogenic with clinically mild or unapparent infections of the respiratory tract and (e) asymptomatic with unapparent intestinal infections. However, the clinical signs and gross or microscopic lesions observed in birds infected with NDV are not specific for ND. The clinical disease might range from subclinical infection to 100% mortality in a short period of time. Many factors related to the host (species, age and immune status), virus strain (pathotype, dosage and route of infection) and environmental or social stress can influence the severity and the course of the disease as well as the occurrence and distribution of the lesions (Kaleta and Baldauf, 1988; Alexander and Senne, 2008a, 2008b).

Table 1: Information about the Newcastle disease viruses used in this study

Virus strain	Avian species	Year of isolation	Genotype	ICPI	GenBank accession number
Quail2006 a	Quail	2006	V	1.94	EU518684 C
Queretaro b	Chicken	1950	II	1.73	EU518676 C
Chicken2000 a	Chicken	2000	V	1.83	EU518677 C
Beaudette C-like	NA	NA	II	NA	NA
LaSota d	-	-	II	-	AF077761

ICPI = Intra Cerebral Pathogenicity Index; a Merino *et al.* 2009; b Thompson and Osteen, 1952; c Perozo *et al.*, 2008; d Commercially available vaccine; NA = Not Available

Vaccination using live and killed vaccines is a common practice in areas where the velogenic strains are endemic in the commercial poultry; however, NDV is still responsible for direct and indirect economic losses. Lymphoid, vascular, respiratory, neural and reproductive lesions are seen in chickens as pathological features of Newcastle disease (Alexander and Senne, 2008b); however, these lymphoid and vascular lesions have not been characterized over time after broiler chicken experimental infection, neither have been compared when chickens are inoculated with pathogenic viruses from the same or different genotypes. The objective of this study was to determine the severity of damage caused by virulent strains of NDV belonging to genotypes II and V on primary and secondary lymphoid organs after intranasal inoculation in susceptible commercial broiler chickens.

MATERIALS AND METHODS

Virus strains: Four pathogenic NDV strains were used: two viruses isolated in Mexico in last decade, previously described for pathogenicity and phylogeny, belonging to two lineages of genotype V (Perozo *et al.*, 2008) identified as Chicken2000 (GenBank access number EU518677) and Quail2006 (GenBank access number EU518684), the strain's name includes the avian species and year of isolation (Merino *et al.*, 2009); as well as two genotype II virulent strains: the Mexican strain named Queretaro (GenBank access number EU518676) and a Beaudette C-like US strain kept at the virus repository of the Departamento de Medicina y Zootecnia de Animal, UNAM. Chicken2000 strain is phylogenetically related to the Torreon strain which was responsible for the last major outbreak occurred in 2000 in the Mexican area known as La Laguna, Quail2006 strain is phylogenetically related to the Chimalhuacan strain isolated in 1973, which is still threatening the Mexican poultry industry. The Mexican Queretaro strain was isolated in 1950 and is used, together with the Chimalhuacan strain, as the official standard challenge viruses. Vaccine strain LaSota was used as lentogen control (Table 1).

Pathogenesis study for effect of vNDV on lymphoid organs: A challenge test was designed to study the pathogenesis of the above mentioned strains of NDV on lymphoid organs of non-immune reared mixed broiler

chickens. Twenty one chickens were inoculated intranasally at 5-w-o with 10^6 ELD₅₀/0.2 mL of Newcastle disease viruses. Three chickens per virus strain were left unchallenged as negative control. Absence of NDV antibodies was confirmed by HI test. Chickens were observed for 4 days after challenge for clinical signs. Groups of three birds were euthanatized at 12 h intervals from 24-96 h post inoculation (hpi) and the Harderian gland, thymus, spleen, bursa, cecal tonsil and bone marrow were sampled and prepared for light microscopy as follows: samples were fixed in 10% buffered formalin, embedded in paraffin and sectioned with a rotary microtome at 3 μ . Tissue sections were stained with hematoxylin and eosin and examined microscopically. Lesion score was determined according to the following criteria:

Thymus: 0 = normal; 1 = a few empty spaces in the cortex; 2 = higher number of empty spaces in the cortex plus heterophil infiltration; 3 = cortex with numerous round aggregations of cell debris and pyknotic nuclei, marked reduction of the cortex; 4 = severe atrophy of the thymus cortex. Lesion score 4 was added to that previously described (Henry *et al.*, 1980).

Bursa of Fabricius: 0 = Normal; 1 = seldom follicles with mild necrosis; 2 = moderate and generalized lymphoid depletion or some follicles with severe lymphoid depletion; 3 = severe lymphoid depletion in more than 50% of follicles; 4 = cystic follicles and with scattered lymphocytes, increased connective tissue, thickened and folded epithelium; 5 = total disruption of the follicular architecture and increased fibroplasia.

Spleen: 0 = Normal; 1 = mild hyperplasia - hypertrophy in ellipsoids, 1 - 2 proliferative lymphoid follicles; 2 = mild focus degeneration, several active lymphoid follicles; 3 = disseminated focal necrosis and moderately active lymphoid follicles; 4 = diffuse and disseminated necrosis, very active lymphoid follicles.

Cecal tonsil: 0 = Normal; 1 = 1-2 proliferative lymphoid follicles per section; 2 = several active lymphoid follicles; 3 = active lymphoid follicles widely disseminated or focal necrosis.

Harderian gland: 0 = Normal; 1 = lymphocytes infiltration; 2 = development of lymphoid follicles.

Bone marrow: 0 = Normal; 1 = degeneration of endothelial cells; 1 = moderate degeneration and necrosis of lymphoid and granulocytic cells, lymphoid depletion and hemorrhage; 3 = severe degeneration and necrosis of lymphoid and granulocytic cells.

Lesion score of affected organs was compared by Kruskal-Wallis and multiple comparison method of Dunn (alpha = 0.05).

Ultra-structural study: The same tissues used histopathology analysis where fixed in 2.5% glutaraldehyde buffered in Sørensen solution, pH 7.4, for 1.5 h; after washing in Sørensen buffer, tissues were post-fixed in 1% osmium tetroxide for two hours, alcohol dehydrated and included in epoxy resin. Embedded tissues, sectioned at 200 nm approximately and stained with aqueous toluidine blue solution, were examined under light microscope. Tissue sections of 60 nm were uranyl acetate - Reynold's lead citrate contrasted and examined in a Zeiss EM 109 transmission electron microscope.

Unchallenged control chickens were euthanatized at 96 hpi and sampled as challenged birds.

Virus isolation: Tissue samples were placed in sterile PBS and 10% suspensions were prepared, centrifuged at 1000 x g for 15 min at 4°C and filtered with a 0.22 µm membrane. Three 9-day-old chicken embryos were inoculated per sample via the allantoic cavity, with 0.2 mL of supernatant. Amnioallantoic Fluid (AAF) harvested from embryos that died more than 24 h after inoculation, was tested for Haemagglutination (HA) activity with 1% chicken red blood cells. Identification was carried out by inhibiting the HA activity of AAF with NDV specific antiserum in a Haemagglutination Inhibition (HI) test (Alexander and Senne, 2008a,b).

RESULTS

Major clinical signs of challenged chickens are shown in Table 2. Quail2006 strain caused the most severe clinical signs and was the only one that produced green diarrhea. Clinical signs were moderate in chickens inoculated with Queretaro, Chicken2000 or Beaudette-like strains. Chickens inoculated with LaSota strain showed only mild periocular edema.

Microscopic lesions: The higher lesion score in thymus was caused at 36 hpi (score 2.7) by the Quail2006

strain; at 60 hpi by Quail2006 and Beaudette-like (score 3.0); at 72 hpi by Quail2006, Chicken2000 and Beaudette-like (score 3-3.3); at 84 hpi by Chicken2000 and Beaudette-Like (score 3-3.3) and at 96 hpi by Quail2006 and Chicken2000 (score 3.3-3.7). In the spleen, the higher lesion score (3.3) at 24, 36 and 48 hpi was caused by Beaudette-like strain; at 60 and 72 hpi by Chicken2000 and Quail2006 (score 3.3-3.7) and at 96 hpi by Quail2006 and Beaudette-like strains (score 4). The highest lesion score (3.7) in bursa of Fabricius at 84 hpi was caused by Beaudette-like strain and by Quail2006 and Chicken2000 (score 5) and Beaudette-like (4.7) at 96 hpi (Table 3). In cecal tonsil, the highest lesion score (3) was caused by Quail2006, Chicken2000 and Beaudette-like strains at 96 hpi. There was no significant difference in the Harderian gland lesions caused by the velogenic or lentogenic strains of NDV (score 1.0-1.7). Finally, in bone marrow, the highest lesion score (score 2.0) at 48 hpi was caused by Chicken2000 strain; at 84 hpi by Chicken2000 and Queretaro (score 2.7) and at 96 hpi by Quail2006 and Beaudette-like strains (score 2.7-3.0) Table 4. No pathologic alterations were seen in samples from unchallenged chickens (data not showed).

Semi-thin sections: Starting at 36 hpi, lesions in thymus were more severe in chickens inoculated with the Quail2006 strain; from 60 hpi and forward all virulent strains, except Beaudette-C like, caused similar lesions, including diffuse necrosis in the thymus medulla, there were also degeneration and vacuoles in the endothelial cells of blood vessels. Lesions reaching the scores 3 and 4 were seen in the bursa at 84 hpi and Quail2006 and Chicken2000 strains caused score 5 lesions, severe atrophy, in the lymphoid follicles. The Beaudette C-like strain produced score 3 lesions as early as 24 hpi and along with Quail2006 strain, reached the score 4 at 96 hpi. There was disseminated necrosis and hemorrhages in the white pulp and around the arterioles of the spleen.

In chickens inoculated with Queretaro and Chicken2000 strains, there was decrease in the granulocytic cell line of bone marrow at 24 hpi; besides, this cell line showed degeneration and there was cell debris. Some granulocytic cells showed membrane projections and some endothelial cells had swollen nuclei. At 36 hpi cell debris was more abundant and both, endothelial and granulocytic cells had vacuolated cytoplasm caused by

Table 2: Intensity of the major clinical signs observed at 96 hpi in broiler chickens experimentally infected with different NDV strains

Virus strain	Listlessness	Ruffled feathers	Prostration	Periocular edema	Green diarrhea
Quail2006	+++	+++	+++	+++	+++
Queretaro	++	+	++	++	-
Chicken2000	++	++	+	++	-
Beaudette-like	++	++	++	++	-
LaSota	-	-	-	+	-

(-) = absent; (+) = mild; (++) = moderate; (+++) = severe

Table 3: Microscopic lesion score in primary and secondary lymphoid organs of 5-w-o broiler chickens inoculated with different NDV strains

Hpi	Thymus					Spleen					Bursa				
	LS	QI	Ck	Qr	BC	LS	QI	Ck	Qr	BC	LS	QI	Ck	Qr	BC
24	1.0	1.7	1.0	1.3	1.7	1.3A	1.0A	2.0AB	1.3A	3.3B	2.0	2.0	2.3	1.7	2.3
36	1.3A	2.7B	1.3A	1.7AB	1.7AB	1.3A	1.3A	3.0AB	1.3A	3.3B	1.7	2.0	3.0	2.7	2.7
48	2.0	2.0	2.0	2.3	2.3	1.7A	1.7A	2.7AB	1.7A	3.3B	2.3	3.3	3.0	3.0	3.3
60	1.7A	3.0B	2.7AB	2.7AB	3.0B	1.3A	1.7AB	3.3B	1.3A	2.7AB	2.3	2.7	2.3	2.7	3.0
72	1.3A	3.0B	3.3B	2.7AB	3.0B	1.7A	2.3AB	3.7B	1.7A	3.0AB	3.0	2.7	3.7	2.7	2.7
84	1.7A	2.7AB	3.3B	2.7AB	3.0B	1.7A	3.7BC	4.0C	2.0AB	3.7BC	2.3A	3.3AB	3.7AB	2.3A	3.7B
96	1.3A	3.7B	3.3AB	3.3B	3.3AB	1.3A	4.0B	3.7AB	3.0AB	4.0B	2.3A	5.0C	5.0C	3.3AB	4.7BC

Hpi = Hours post inoculation; LS = LaSota; QI = Quail2006; Ck = Chicken2000; Qr = Queretaro; BC = Beaudette C-like. Different letter in the same organ and row denotes statistical difference (p<0.05)

Table 4: Microscopic lesion score in secondary lymphoid organs of 5-w-o broiler chickens inoculated with different NDV strains

Hpi	Tonsil					Harderian gland					Bone marrow				
	LS	QI	Ck	Qr	BC	LS	QI	Ck	Qr	BC	LS	QI	Ck	Qr	BC
24	2.3	3.0	2.7	2.7	3.0	1.3	1.3	1.0	1.3	1.3	0.0	0.3	0.7	0.7	0.3
36	2.3	3.0	3.0	2.0	3.0	1.3	1.3	1.0	1.0	1.3	0.0	0.7	1.0	1.3	0.3
48	2.7	3.0	3.0	2.7	2.7	1.3	1.3	1.0	1.7	1.0	0.33A	1.0A	2.0B	1.3A	0.7A
60	2.3	2.0	3.0	2.0	2.3	1.3	1.3	1.0	1.0	1.3	0.33	1.7	1.7	1.7	1.3
72	2.7	3.0	2.0	2.7	3.0	1.3	1.3	1.3	1.0	1.0	1.0	1.7	2.0	1.3	2.3
84	2.0	2.0	2.7	2.7	3.0	1.3	1.7	1.3	1.7	1.7	1.0A	2.7B	2.0AB	2.7B	2.0AB
96	1.7A	3.0B	3.0B	2.3AB	3.0B	1.3	1.7	1.7	1.7	1.3	1.0A	3.0B	2.3AB	2.3AB	2.7B

Hpi = Hours post inoculation; LS = LaSota; QI = Quail2006; Ck = Chicken2000; Qr = Queretaro; BC = Beaudette C-like. Different letter in the same organ and row denotes statistical difference (p<0.05)

Quail2006, Chicken2000 and Queretaro strains. Changes in granulocytic cells evolved to necrosis, which was more evident at 48 hpi. At 60 hpi, there was marked depletion of granulocytic cells along with necrosis and blood vessels destruction; some endothelial cells had swollen nuclei (vesicle-like), perinuclear edema, besides vacuolation, cytoplasm fragmentation and structure loss. The intense degeneration of granulocytic cells continued at 72 hpi and a higher proportion of erythropoietic cell line was seen. At 84 and 96 hpi there were endothelial cells with projections of the cell membrane, destruction of blood vessels, severe depletion of granulocytic cells and arise of blastic cells, the most severe lesions were caused by Quail2006 and Beaudette C-like strains.

Electron microscopy: Ultra structural findings in the bone marrow. In one of the bone marrow sections there were granulocytes, immature heterophils and eosinophils, which can be differentiated from each other because the heterophil myelocytes have a heterogenous granules population, abundant endoplasmic reticulum with ribosomes and enlarged Golgi apparatus. On the other hand, the granules of the eosinophil myelocytes are homogeneous, rounded and their size and content are relatively similar. There were also plasmatic cells, lymphocytes, pericapillar cells, macrophages and promyelocytes. Granulocytic cells with cytoplasm degeneration along with edema and vacuoles were seen as early as 24 hpi. Some of these cells showed vesicle-like nuclei with disperse chromatin and

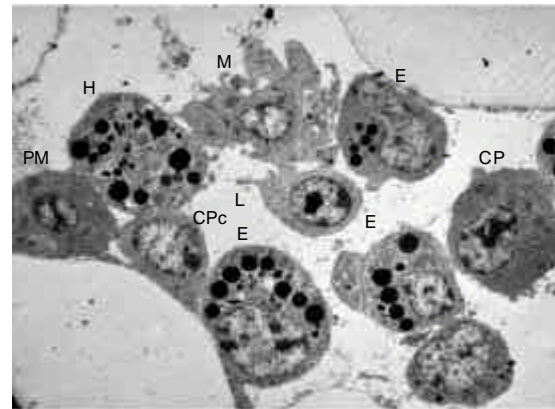


Fig. 1: Bone marrow; chicken infected with Quail2006 NDV strain, 24 hpi. Heterophil (H) and Eosinophil (E) with cytoplasm vacuoles (arrows) and the Macrophage (M) shows projections, rupture of cell membrane and nuclei degeneration. Transmission electron microphotograph, lead citrate and uranyl acetate contrast. 2,550x

cytoplasm fragmentation; there were also macrophages with vesicles in the cytoplasm and cell membrane degeneration and cell debris that became more abundant over the time (Fig. 1).

Starting at 24 hpi, in the mature heterophils, which are characterized by their oval granules, there were cell membrane projections. From that time, electron-dense particles around 200 nm, compatible with virus particles,

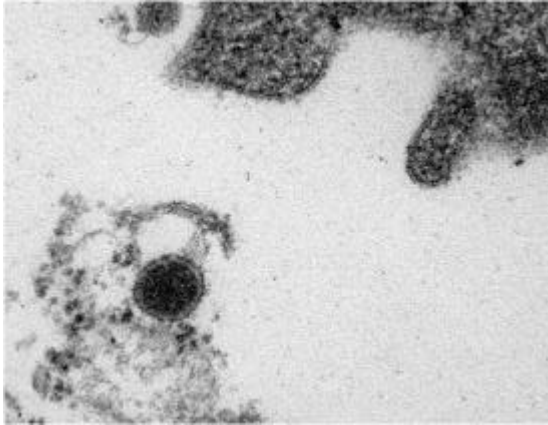


Fig. 2: Bone marrow, chicken infected with Quail2006 NDV strain, 48 hpi. Electron-dense particle of approximately 200 nm diameter, compatible with NDV, in cell debris. Transmission electron micrograph, lead citrate and uranyl acetate contrast. 135,000x

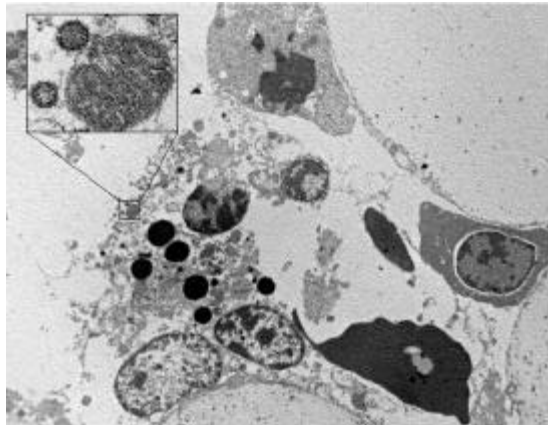


Fig. 3: Bone marrow, chicken infected with Quail2006 NDV strain, 48 hpi. Necrotic eosinophil, cell membrane has disappeared, cytoplasm is dispersed and nucleus membrane is broken and allows the content to disperse, close up box shows two particles virus-like of approximately 200 nm diameters (65,000x) near to a mitochondrion. Transmission electron micrograph, lead citrate and uranyl acetate contrast. 3,700x

were seen in the cell debris (Fig. 2). Those particles were also found attached to the cell membrane and in vesicles inside the cytoplasm. From 48 to 96 hpi, there was marked depletion of different cell lines, mainly granulocytes. Necrosis and apoptosis of granulocytes increased over the time. Virus particles were seen from 24 hpi and forward in the extracellular space, cytoplasm vesicles and debris of necrotic cells (Fig. 3).

Virus isolation: Chicken2000 strain was isolated from spleen, cecal tonsil and bursa sampled at 24 hpi, thymus turned positive at 36 hpi; all samples were positive from 48 to 96 hpi. Quail2006 and Beaudette-like strains were isolated from thymus, spleen, cecal tonsil and bursa at 36 hpi. From 48 to 96 hpi, all samples were positive for virus isolation. Queretaro strain was first isolated from bursa at 48 hpi and all samples were positive from 60 hpi. LaSota strain was isolated from Harderian gland and cecal tonsil at 48 hpi, from 60 to 96 hpi the virus was also isolated from bursa.

DISCUSSION

Microscopic lesion scores in lymphoid organs caused by the Quail2006 strain in broiler chickens were more severe than those caused by the Chicken2000 strain, though both strains belong to genotype V, but different lineages (Perozo *et al.*, 2008; Merino *et al.*, 2009), these viruses are currently circulating in some areas of Mexico. The Intra Cerebral Pathogenicity Index (ICPI) is higher in the virus related to the Mexican standard challenge strain Chimalhuacan (Quail2006, 1.94) than in isolate phylogenetically related to the Mexican Torreon strain, responsible for the last major outbreak (Chicken2000, 1.83). In the other hand, ICPI of isolates belonging to genotype V (1.94 and 1.83) was higher than that of the genotype II isolate (Queretaro, 1.73). Comparatively, the mean ICPI from several Chinese isolates belonging to genotypes VIIa and VIII were 1.7 (1.48-1.83 range) and 1.81 (1.74-1.93 range), respectively (Liang *et al.*, 2002). These results suggest that virulence of notifiable NDV can be different in isolates belonging to different genotypes and even within the same genotype.

Microscopic lesions found in thymus and bursa, caused by the Chicken2000 strain, are similar to those reported for virulent strains (Okoye *et al.*, 2000; Wakamatsu *et al.*, 2006), which were characterized by severe lymphoid depletion along with lympho-cellular necrosis and apoptosis; the main difference in our study is that lesions and organ atrophy appeared earlier than in those studies where the lymphoid depletion was seen first at 2-3 days pos inoculation, it was severe at 6 dpi and atrophy was evident at 7 dpi. Lymphoid necrosis was also observed in the spleen, mild to moderate and depletion from 3rd dpi, which became severe from 4th dpi, the increase in the number of germinal centers was seen at 10 dpi. Thymus and cecal tonsils showed lymphoid necrosis starting at 3 dpi and becoming severe by the 4th dpi, those cecal tonsil lesions have been described (Sun *et al.*, 2008). Thymus lesions are similar to those reported in another study (Lam *et al.*, 1995) where abundant apoptotic cells and a number of apoptotic body forms were seen in chicken embryos experimentally infected with the GB strain. The atrophy and lymphoid depletion from thymus, cecal tonsil and spleen were more severe than those commonly found in infectious bursal disease, what is different from other reports (Hamid *et al.*, 1991; Okoye *et al.*, 2000); where

lesions in bursa caused by NDV are considered to be less severe than those caused by the infectious bursal disease virus.

Histological and ultra-structural findings by electron microscopy in bone marrow are very interesting. Following the virus infection, macrophages can produce virus progeny and then suffer apoptosis and necrosis (Lam, 1996). On the other side, NDV cytopathic effect on cell culture is caused by apoptosis induced by different mechanisms over the time (Ravindra *et al.*, 2009a, 2009b). The observation of virus particles inside cytoplasm vesicles from some granulocytic cells confirm that NDV can penetrate and infect the cells through different routes and that, besides the direct fusion with the plasmatic membrane, some virions can be endocyted in endosomes, where the fusion takes place between the virus envelope and cell membrane (Cantín *et al.*, 2007).

Bone marrow lesions were similar to those previously reported (Galindo *et al.*, 2001; Calderon *et al.*, 2005), including the electron dense particles in debris from destroyed cells and cytoplasm vesicles in mononuclear cells. The morphology of these particles is compatible with NDV, which appears as pleomorphic spheres of 100-500 nm diameters, with a dense membrane and covered by an envelope at electron microscopy (Alexander and Senne, 2008b). Virus isolation from bone marrow samples confirmed that those particles are compatible with NDV. In other study, severe damage was found in bone marrow, characterized by hematopoietic island necrosis, the presence of NDV was confirmed by immunohistochemistry (Ojok and Brown, 1996). Endothelial cells, which also phagocyte microorganism, are affected by viruses with endothelial tropism. In bone marrow evaluation, these cells became degenerated and necrotic since 24 hpi, what can be the cause of hemorrhage and necrosis of the adjacent tissue (Ojok and Brown, 1996; Calderon *et al.*, 2005).

Lentogenic strain LaSota caused lesions similar to those reported as moderate lymphoid depletion and degeneration in the medulla of bursa follicles, which was atrophic at 3 dpi; the spleen showed mild lymphoid pyknosis and depletion from 3rd to 5th dpi; meanwhile, the thymus and cecal tonsil had slight lymphoid depletion between 3rd and 5th dpi (Ezema *et al.*, 2009). Results from this study may help to better understand the causes of ND outbreaks in commercial ND-vaccinated poultry flocks. Vaccination programs have proven their efficacy to protect the chickens against mortality; however, it is necessary to evaluate the consequences of the damage that pathogenic field viruses cause on lymphoid organs and hematopoietic bone marrow. As shown in this study, virulent NDV strains cause severe lymphoid lesions in non immunized broiler chickens, these lesions have been reported also in vaccinated birds, so the economic losses are not too high because of the mortality rate, but

surviving birds will have a reduced immune response. Outbreaks of ND in vaccinated broiler chicken flocks cause microscopic lesions in lymphoid organs, including bursal lymphoid depletion and virus presence has been demonstrated in the organ by immunoperoxidase (Nakamura *et al.*, 2008). In vaccinated and challenged birds, focal and transitory necrosis of B cells in bursa, atrophy of lymphoid organs, as well as severe bursal atrophy that last for 20 days were found (Hamid *et al.*, 1991). So, these lesions must be evaluated, especially when outbreaks happen in young birds.

Results from this work, besides the previous ones where phylogenetic and pathological characteristics of these viruses were described (Perozo *et al.*, 2008; Merino *et al.*, 2009), are important in order to fully characterize the strains that are circulating in Mexico and Central America, since some isolates phylogenetically related to Chicken2000 strain were also related to viruses isolated from Honduras in 2000 (Seal *et al.*, 2002) and from California in 2002-2003 (Pedersen *et al.*, 2004). According with these results, viruses from the same genotype can have differences in virulence and also, different virulence can be achieved by viruses belonging to different genotypes. So, animal experiments are helpful to assess the variation in NDV pathogenicity (Susta *et al.*, 2011). To our knowledge, this is the first time that a lesion score for bone marrow and Harderian gland has been established to study the virulence of NDV. This information, along with standard indices and sequence analysis of NDV isolates can be the base to devise appropriate prevention and control measures.

Ethical standards: The experiments carried out in this study comply with the current Mexican laws and the 2007 AVMA guidelines on euthanasia.

Abbreviations: AAF, amnioallantoic fluid; RNA, ribonucleic acid; ELD50, embryo lethal dose 50% of eggs; HA, haemagglutination; HI, haemagglutination inhibition; hpi, hours post inoculation; ICPI, intracerebral pathogenicity index; ND, Newcastle disease; NDV, Newcastle disease virus; vNDV, virulent Newcastle disease virus; w-o, weeks old.

Conflict of interest: The authors declare that they have no conflict of interest.

ACKNOWLEDGEMENTS

We want to acknowledge the transmission electron microscopy technical support provided by the biologists Alberto Carlos Martinez and Alma Delia Hernandez Perez, from the Departamento de Morfología Celular y Molecular, Instituto Nacional de Rehabilitación; as well as the financial support from the PFAMU PI200606 budget.

REFERENCES

- Alexander, D.J. and D.A., Senne, 2008a. Newcastle disease virus and other paramyxoviruses. In: Dufour-Zavala, L., Swayne, D.E., Glisson, J.R., Pearson, J.E., Reed, W.M., Jackwood M.W. and Woolcock P.R. (Eds.), A laboratory manual for the isolation, identification and characterization of avian pathogens. 5th Edn., Athens: The American Association of Avian Pathologists, pp: 135-141.
- Alexander, D.J. and D.A. Senne, 2008b. Newcastle disease, other avian paramyxoviruses and pneumovirus infections. In: Saif, Y.M., Fadly, A.M., Glisson, J.R., McDougald, L.R., Nolan, L.K. and Swayne D.E. (Eds.), Diseases of Poultry. 12th Edn., Ames: Blackwell Publishing, pp: 75-100.
- Beard, C.W. and R.P. Hanson, 1984. Newcastle disease. In: Hofstad, M.S., Barnes, H.J., Calnek, B.W., Reid, W.M. and Yoder, H.W. (Eds), Diseases of Poultry, 8th Edn., Ames: Iowa State University Press, pp: 452-470.
- Calderon, A.L., M.F. Galindo, M. Ortiz, B. Lomniczi, T. F  h  rvari and L.H. Paasch, 2005. Thrombocytopenia in Newcastle disease: Hematological evaluation and histological study of bone marrow. *Acta Vet. Hung.*, 53: 507-513.
- Cantin, C., J. Holguera, L. Ferreira, E. Villar and B.I. Munoz, 2007. Newcastle disease virus may enter cells by caveolae-mediated endocytosis. *J. Gen. Virol.*, 88: 559-569.
- Ezema, W.S., J.O.A. Okoye and J.A. Nwanta, 2009. LaSota vaccination may not protect against the lesions of velogenic Newcastle disease in chickens. *Trop. Anim. Health Pro.*, 41: 477-484.
- Galindo, M.F., N.L. Calderon, N.M. Charles, I.G. Tellez and T.I. Fortoul, 2001. Haematological and histological findings in experimental Newcastle disease. *Acta Vet. Brno.*, 70: 185-189.
- Glickman, R.L., R.J. Syddall, R.M. Iorio, J.P. Sheehan and M.A. Bratt, 1988. Quantitative basic residue requirements in the cleavage-activation site of the fusion glycoprotein as a determinant of virulence for Newcastle disease virus. *J. Virol.*, 62: 354-356.
- Hamid, H., R.S.T. Campbell and L. Parede, 1991. Studies of the pathology of velogenic Newcastle disease virus: Virus infection in immune and non-immune birds. *Avian Pathol.*, 20: 561-575.
- Henry, C., R. Brewer, S. Edgar and B. Gray, 1980. Studies on infectious bursal disease in chickens. 2. Scoring microscopic lesions in the bursa of Fabricius, thymus, spleen and kidney in gnotobiotic and battery reared white leghorns experimentally infected with infectious bursal disease virus. *Poult. Sci.*, 59: 1006-1017.
- Kaleta, E.F. and C. Baldauf, 1988. Newcastle disease in free-living and pet birds. In: Alexander, D.J. (Ed). Newcastle disease. Boston: Kluwer Academic Publishers, pp: 197-246.
- Kant, A., G. Koch, D.J. Van Roozelaar, F. Balk and A. Ter Huurne, 1997. Differentiation of virulent and non-virulent strains of Newcastle disease virus within 24 hours by polymerase chain reaction. *Avian Pathol.*, 26: 837-849.
- Lam, K.M., A.C. Vasconcelos and A.A. Bickford, 1995. Apoptosis as a cause of death in chicken embryos inoculated with Newcastle disease virus. *Microb. Pathogenesis*, 19: 169-174.
- Lam, K.M., 1996. Growth of Newcastle disease virus in chicken macrophages. *J. Comp. Pathol.*, 115: 253-263.
- Liang, R., D.J. Cao, J.Q. Li, J. Chen, X. Guo, F.F. Zhuang and M.X. Duan, 2002. Newcastle disease outbreaks in western China were caused by the genotypes VIIa and VIII. *Vet. Microbiol.*, 87: 193-203.
- Mayo, M.A., 2002. A summary of the changes recently approved by ICTV. *Arch. Virol.*, 147: 1655-1656.
- Merino, R., H. Villegas, J.A. Quintana and N. Calderon, 2009. Characterization of Newcastle disease viruses isolated from chicken, gamefowl, pigeon and quail in Mexico. *Vet. Res. Comm.*, 33: 1023-1030.
- Nagai, Y., H.D. Klenk and R. Rott, 1976. Proteolytic cleavage of the viral glycoproteins and its significance for the virulence of Newcastle disease virus. *Virology*, 72: 494-508.
- Nagai, Y. and H.D. Klenk, 1977. Activation of precursors to both glycoproteins of Newcastle disease virus by proteolytic cleavage. *Virology*, 77: 125-134.
- Nagai, Y., 1995. Virus activation by host proteinases. A pivotal role in the spread of infection, tissue tropism and pathogenicity. *Microbiol. Immunol.*, 39: 1-9.
- Nakamura, K., N. Ohtsu, T. Nakamura, Y. Yamamoto, M. Yamada, M. Mase and K. Imai, 2008. Pathologic and immunohistochemical studies of Newcastle disease (ND) in broiler chickens vaccinated with ND: Severe nonpurulent encephalitis and necrotizing pancreatitis. *Vet. Pathol.*, 45: 928-933.
- Okoye, J.O.A., A.O. Agu, C.N. Chineme and G.O.N. Echeonwu, 2000. Pathological characterization in chicken of a velogenic Newcastle disease virus isolated from Guinea fowl. *Rev. Elev. Med. Vet. Pay.*, 53: 325-330.
- Ojok, L. and C. Brown, 1996. An immunohistochemical study of the pathogenesis of virulent viscerotropic Newcastle disease in chickens. *J. Comp. Pathol.*, 115: 221-227.
- Pedersen, J.C., D.A. Senne, P.R. Woolcock, H. Kinde, D.J. King, M.G. Wise, B. Panigrahy and B.S. Seal, 2004. Phylogenetic relationships among virulent Newcastle disease virus isolates from the 2002-2003 outbreak in California and other recent outbreaks in North America. *J. Clin. Microbiol.*, 42: 2329-2334.

- Perozo, F., R. Merino, C.L. Afonso, P. Villegas and N. Calderon, 2008. Biological and phylogenetic characterization of virulent Newcastle disease virus circulating in Mexico. *Avian Dis.*, 52: 472-479.
- Ravindra, P.V., A.K. Tiwari, B. Ratta, U. Chaturvedi, S.K. Palia and R.S. Chauhan, 2009a. Newcastle disease virus-induced cytopathic effect in infected cells is caused by apoptosis. *Virus Res.*, 141: 13-20.
- Ravindra, P.V., A.K. Tiwari, B. Ratta, M.V. Baisa, U. Chaturvedi, S.K. Palia, B. Sharma and R.S. Chauhan, 2009b. Time course of Newcastle disease virus-induced apoptotic pathways. *Virus Res.*, 144: 350-354.
- Seal, B.S., J.M. Crawford, H.S. Sellers, D.P. Locke and D.J. King, 2002. Nucleotide sequence analysis of the Newcastle disease virus nucleocapsid protein gene and phylogenetic relationships among the Paramyxoviridae. *Virus Res.*, 83: 119-129.
- Sun, Q., D. Wang, R. She, W. Li, S. Liu, D. Han, Y. Wang and Y. Ding, 2008. Increased mast cell density during the infection with velogenic Newcastle disease virus in chickens. *Avian Pathol.*, 37: 579-585.
- Susta, L., P.J. Miller, C.L. Afonso and C.C. Brown, 2011. Clinicopathological characterization in poultry of three strains of Newcastle disease virus isolated from recent outbreaks. *Vet. Pathol.*, 48: 349-60.
- Thompson, C.H. and O.L. Osteen, 1952. Immunological and pathological findings on a highly virulent strain of Newcastle disease virus from Mexico. *Am. J. Vet. Res.*, 13: 407-416.
- Wakamatsu, N., D.J. King, B.S. Seal, S.K. Samal and C.C. Brown, 2006. The pathogenesis of Newcastle disease: A comparison of selected Newcastle disease virus wild-type strains and their infectious clones. *Virology*, 353: 333-343.