

ISSN 1682-8356  
ansinet.org/ijps



INTERNATIONAL JOURNAL OF  
**POULTRY SCIENCE**

**ANSI***net*

308 Lasani Town, Sargodha Road, Faisalabad - Pakistan  
Mob: +92 300 3008585, Fax: +92 41 8815544  
E-mail: editorijps@gmail.com

## Toxicologic Pathology of Piperazine Hydrate in Male Wild Pigeon at Basrah City/Southern Iraq

A. Al-Sereah Bahaa<sup>1</sup>, A. Al-Azizz Suzan<sup>2</sup> and K. Majeed Saleh<sup>3</sup>

<sup>1</sup>Department of Pathology and Poultry Diseases, <sup>2</sup>Department of Microbiology, College of Veterinary Medicine, University of Basrah, Basrah, Iraq

<sup>3</sup>55 Desborough Road, Hartford-Huntingdom, Cambridgeshire, PE 29 1 SN, England

**Abstract:** A three months Toxicologic pathology study of piperazine hydrate in male wild pigeons by oral intubation were done. The study was done at three dosage levels as low (0.25 ml), intermediate (0.50 ml) and high (1 ml) with untreated control as fourth group. Clinical observation of treated pigeons did not show significant changes only the birds appeared to be quite after dosing for short time. Macroscopically no obvious changes could be detected. Microscopically, minimal diffuse vacuolation of hepatocytes and varying number of parenchymal foci of inflammatory cells, mostly mononuclear cells. In treated birds a renal lesions were characterized by dilated cortical tubules mostly the proximal convoluted tubules with different levels. Heart showed foci/areas of infiltrating mononuclear cells between myocardial muscle cells with occasional vacuolated myocardial muscles cells. The pancreas showed a histopathological changes which were restricted to endocrine islets of langerhans, which showed evidence of degeneration characterized by vacuolation. The nervous system, there was no histopathological changes could be seen in cerebrum, but, vacuolation of perking cells was noticed in cerebellum in some of treated birds, while, the most significant histopathological changes were in spinal cord as varying numbers of degenerate/vacuolated nerve fibers at all dosage levels but most severe at high dose levels, the other changes but to less extents were in sciatic nerve as there were only few to occasional degenerate/vacuolated nerve fibers with less severity as they were on the way of recovery.

**Key words:** Toxicologic pathology, piperazine, wild pigeons, inflammatory cells, vacuolation

### INTRODUCTION

Pigeons fall into three groups i.e. poultry pigeons, carrier and racing pigeons, fancy and feral pigeons. The gastrointestinal tract of pigeons harbor a wide variety of helminthes, of which nematodes are the most deleterious parasites and are responsible for clinical and sub-clinical parasitism. During heavy infestation, these nematodes adversely affect the health of birds with loss in the body weight, retarded growth, unthriftiness, damage to the gut epithelium, fertility disturbances, emaciation and death especially in young birds (Urquhart, 1996).

Many highly effective anthelmintic are available but such drugs must be used correctly to obtain favorable clinical response. The ideal anthelmintic should have a wide margin of safety, considerable activity against immature stages, easy to administer, inhibit re-infection and be compatible with other compound not require long residual effect periods because of residue and be cost effective. To overcome the problem of hookworm infestation, the anthelmintic with good efficacy and least toxic effects is desired (Obiukwu and Onyali, 2006). Piperazine (diethyldiamine) as it's dihydrochloride and

citrate salts is used in veterinary medicine as an anthelmintic in pigs and poultry including laying hens because of it's activity against nematodes especially *Ascaris* sp., other salts of piperazine are also used in veterinary medicine (EMEA, 1999).

Piperazine and its salts as an-aminobutyric acid (GABA)-like substance, induce a reversible flaccid paralysis in the nematodes parasites. This is provoked by a hyperpolarisation of the cell membrane followed by suppression of spontaneous spike potentials, the paralyzed nematodes are expelled from the gut lumen by normal parasitic actions (EMEA, 1999; 2006).

Piperazine was rapidly absorbed following administration to four lying hens (300 mg/kg bw. 14C-piperazine dihydrochloride equivalent to 154.5 mg/kg bw. Piperazine base) (EMEA, 2006).

Although piperazine is a drug with a wide margin of safety, occasionally an animal may show nausea, vomiting or muscular tremors. Such side effects are usually associated with over dosage. Therefore, recommended dosages should be followed carefully (<http://www.Piperazine,2010>). Acute toxicity studies have been performed using piperazine and several of its

salts, the salts which are rapidly hydrolyzed to generate piperazine show a correlation of decreased toxicity with decreased solubility (EMEA, 2006).

There are no previously published reports in the medical literature relating to the toxicity of piperazine when taken alone and it's suggest that piperazine has limited effects when taken on its own (Drug-Forum, 2008) but in animal models it has been shown to produce aversive effects rather than causing self-administration when used a combined of piperazine and benzylpiperazine (Fantegrossi *et al.*, 2005).

Piperazine base was identify as the marker in both chicken's eggs and pig tissues and that the marker residue represents 77% of the total residues in chicken's eggs 96 hours after treatment and respectively 15%, 14%, 13% and 35% of the total residues in porcine muscle, skin fat, liver and kidney at 48 hours after treatment respectively (EMEA, 2006).

There was no studies about the toxicity of piperazine in pigeons in Iraq and the world, so, this study designed to detect the toxologic pathology of this drug in wild pigeons as an experimental model at Basrah city/ southern Iraq.

## MATERIALS AND METHODS

**Experimental Model:** Adult wild male pigeons were purchased from local market in Basrah city with average body weight (200-350 gm) and reared in a clean cages (200 x 100 x 80 cm) in poultry unite/college of veterinary medicine/Basrah university, all pigeons were acclimatized for 10 days before start the experiment.

**Chemicals:** Piperazine hydrate (ascalix syrup) from Wallace manufacturing chemicals Ltd. England, then, it was further diluted in distilled water to obtain the desired concentration. The solution was prepared and used immediately, by oral gavage using disposable syringe after removing the needle, the doses of piperazine were determine by testing the compound on few pigeons, also the maximum toxic dose which was used according to the active ingredients of the substance.

**Treatments:** To study the toxologic pathology of piperazine on pigeons a total of fourty birds were randomly divided into four groups (10 pigeons each group); group one as low dose of 0.25 mg/day. Piperazine, group two as intermediate dose of 0.5 mg/ day. Piperazine, group three as high dose 1 mg/day piperazine, fourth group was given 1 ml distilled water as untreated control group. The experiment was done for three months, after that all pigeons were killed by cervical dislocation, selected visceral organs were fixed in 10% neutral buffered formalin for further histopathological study.

**Histopathological examinations:** Five µm thick paraffin sections were prepared as follows: a visceral organs

tissues of liver, kidney, spleen, lung, pancreas, heart, testes, epididemus, brain, spinal cord and sciatic nerve from each pigeon were fixed in 10% formalin, then samples were cut and paraffin blocks were made, slide were cut and stained with Haematoxyline-Eosin (HE), selected histopathological changes were photographed from treatment related histopathological changes in comparison to untreated controls, according to the method of (Annpreece, 1972).

## RESULTS

The toxologic pathological changes which were considered to be related to treatment with piperazine on pigeons were founded as follows:

**Heart:** Areas of vacuolation of myocardial muscle cells were found associated with occasional foci of mononuclear cells and infiltration of fat cells between myocardial muscle cells, those were founded in all treated groups with piperazine (Fig. 1, 2, 3) as compared with control (Fig. 4).

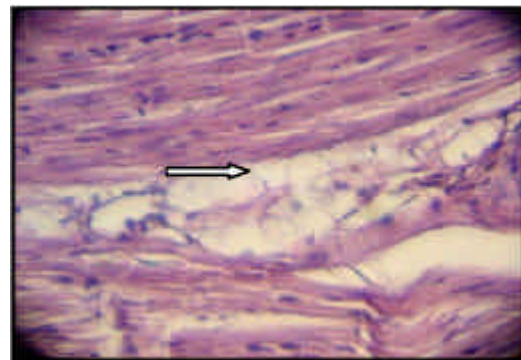


Fig. 1: Heart of pigeon with low dose of piperazine, vacuolation of myocardial muscle cells and infiltration of fat cells between myocardial muscle cells. H&E (500x)

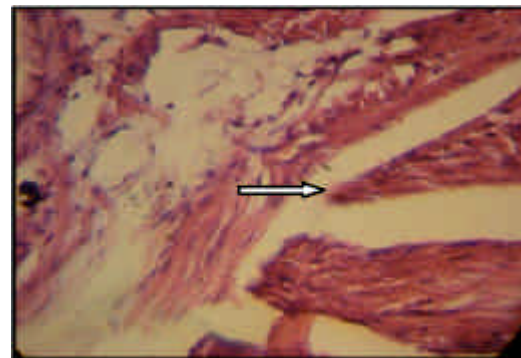


Fig. 2: Heart of pigeon with intermediate dose of piperazine, vacuolation of myocardial muscle cells and infiltration of fat cells between myocardial muscle cells. H&E (500x)

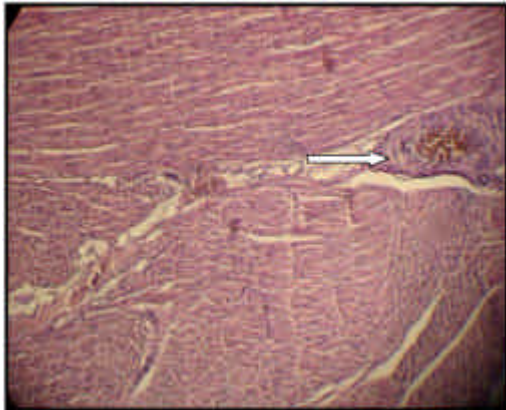

Fig. 3: Heart of pigeon with high dose of piperazine, vacuolation of myocardial muscle cells and infiltration of fat cells between myocardial muscle cells. H&E (125x)

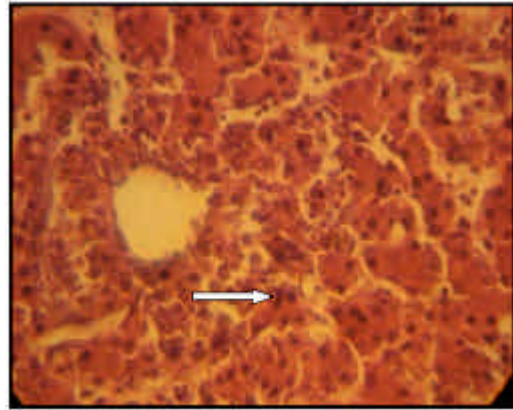


Fig. 6: Liver of pigeon with low dose of piperazine a few parenchymal foci of inflammatory cells with evidence of hepatitis, low dose. H&E (500x)

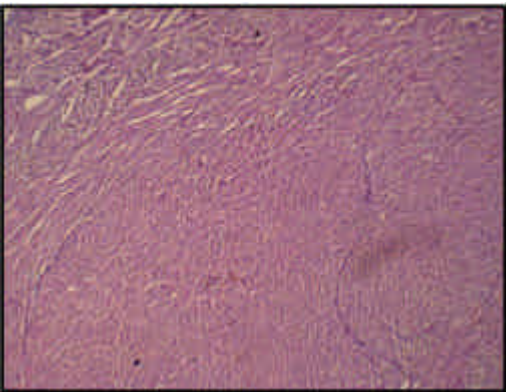


Fig. 4: Heart of pigeon as control group H&E (125x)

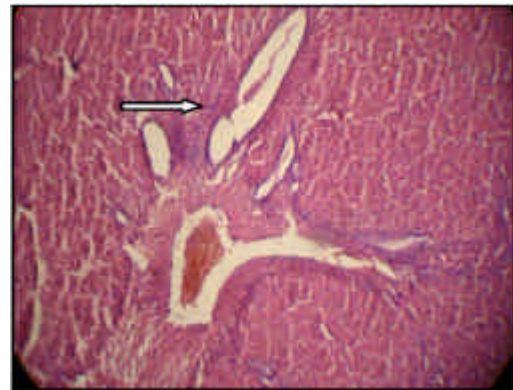

Fig. 7: Liver, periportal fibrosis and infiltrating of inflammatory cells, intermediate dose. H&E (500x)

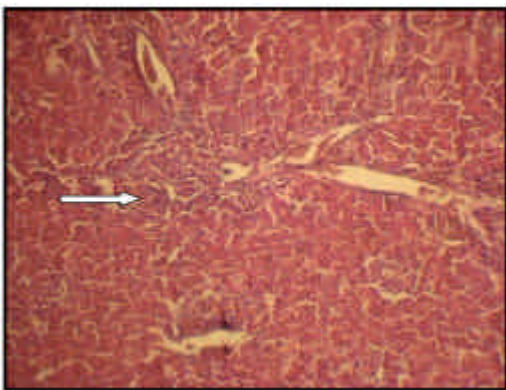


Fig. 5: Liver of pigeon with low dose of piperazine a minimal vacuolation of hepatocytes, parenchymal foci of inflammatory cells and periportal fibrosis. Low dose, H&E (125x)

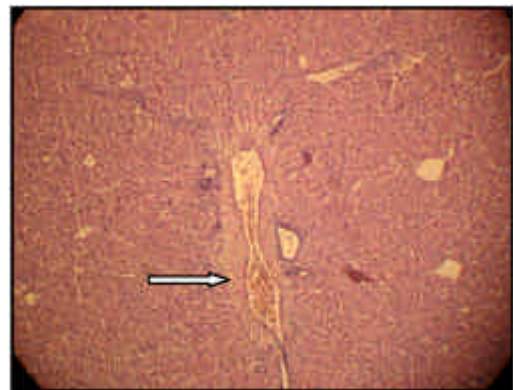

Fig. 8: Liver, centre lobular vacuolation of hepatocytes, intermediate dose, H&E (125x)

**Liver:** Minimal vacuolation of hepatocytes associated with occasional parenchymal foci of inflammatory cells,

some with minimal periportal fibrosis with few mononuclear cells in low dose group, also periportal fibrosis and bile duct proliferation and few parenchymal

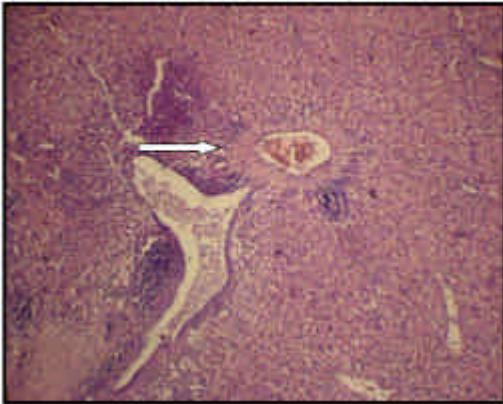


Fig. 9: Liver, periportal focal infiltration of mononuclear cells and aggregates of lymphocytes, sub capsular vacillation of hepatocytes, congestion, high dose. H&E (125x)

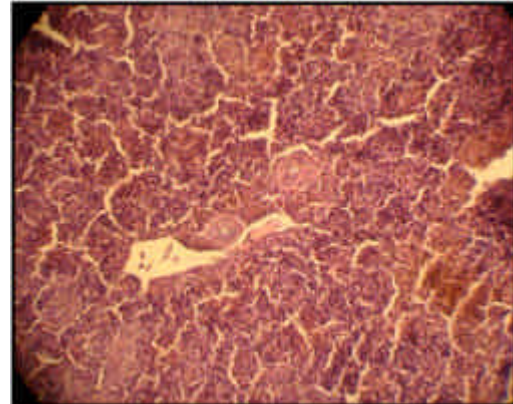


Fig. 12: Spleen, atrophy of white pulp lymphoid tissue, low dose, H&E (500x)

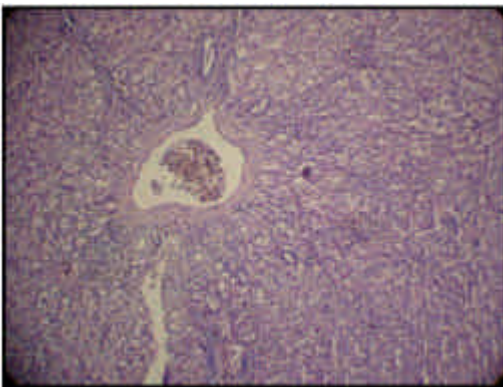


Fig. 10: Liver, diffuse vacillation of hepatocytes, high dose, H&E (125x)

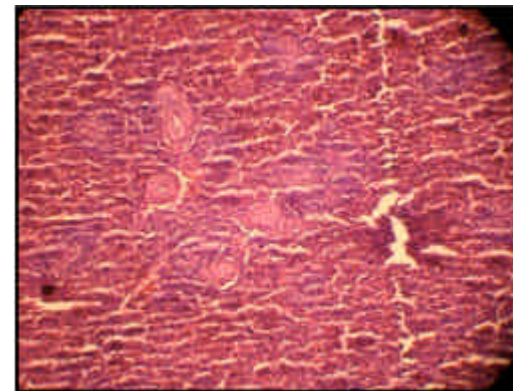


Fig. 13: Spleen, atrophy of white pulp lymphoid tissue, intermediate dose, H&E (500x)

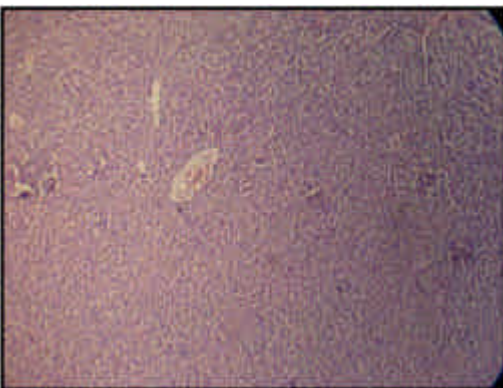


Fig. 11: Liver, control. H&E (125x)

foci of inflammatory cells with evidence of hepatitis and septal fibrosis (Fig. 5, 6). While, in intermediate and high dose group a moderate vacillation of hepatocytes and periportal fibrosis with congestion of

sinusoid and mononuclear cells, centrelobular vacillation of hepatocytes with periportal fibrosis were noticed (Fig. 7, 8, 9, 10) as compared with control (Fig. 11).

**Spleen:** Atrophy of lymphoid tissue were found in both low and intermediate dose (Fig. 12, 13), while, in high dose a reduce cellurity of the white palp lymphoid tissue (Fig. 14) as compared with control (Fig. 15).

**Pancreas:** The low and intermediate dose of piperazine treated pigeons didn't show any evidence of pancreatic changes, while, the high dose showed vacuolated cells of the islets of langerhans (Fig. 16, 17).

**Lung:** Lunges of pigeons with low and intermediate dose showed congestion and emphysema (Fig. 18, 19) and minimal pulmonary interstitial fibrosis and peri bronchial aggregates of lymphocytes associated with bronchular epithelial hypertrophy in intermediate dose (Fig. 20), while, in high dose congestion and

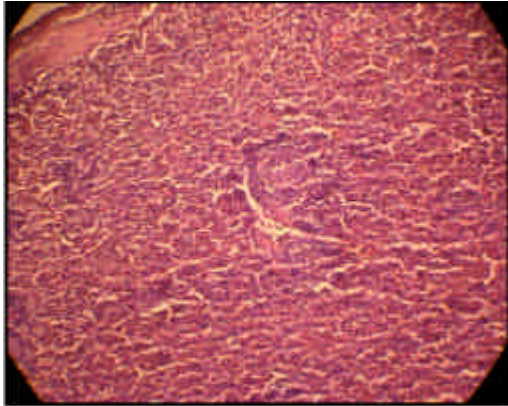


Fig. 14: Spleen, reduce cellurity of the white pulp lymphoid tissue, high dose, H&E (125x)

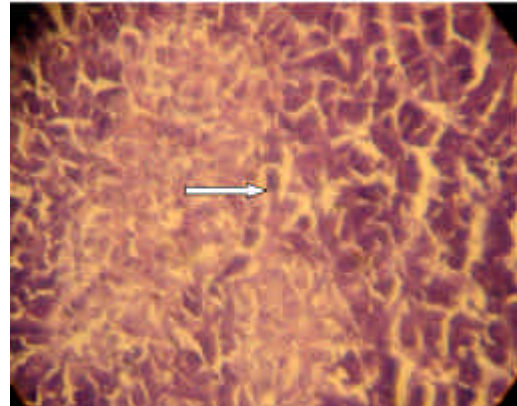


Fig. 17: Pancreas, vacuolated cells of the islets of langerhans, high dose. E&H (500x)

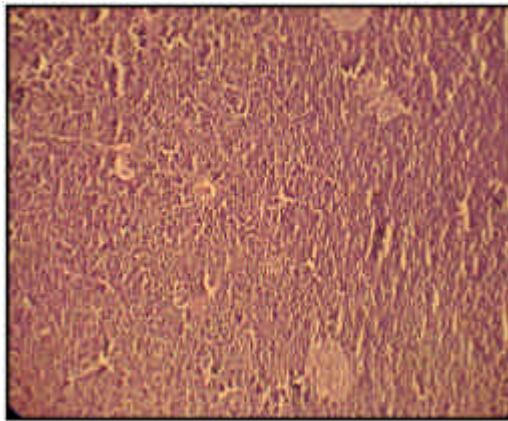


Fig. 15: Spleen, control. H&E (125x)

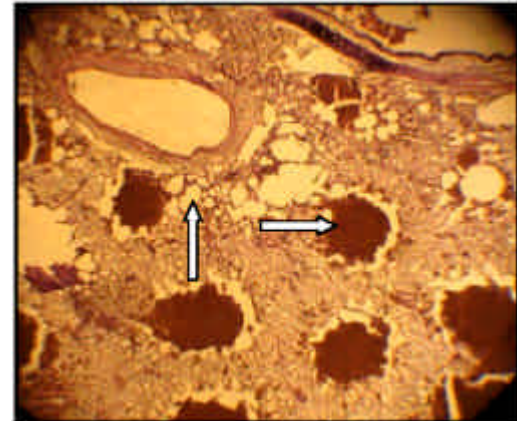


Fig. 18: Lung, congestion and emphysema, areas of foamy alveolar macrophages, low dose, H&E (125x)

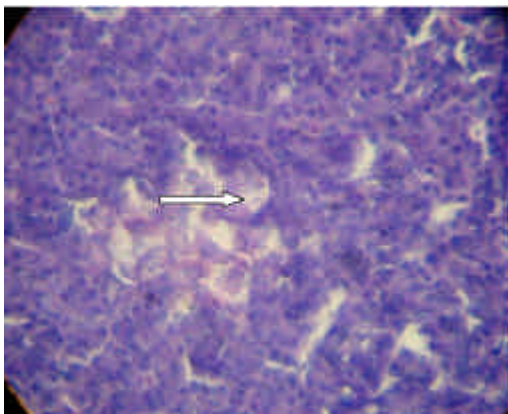


Fig. 16: Pancreas, vacuolated cells of the islets of langerhans, high dose, H&E (500x)

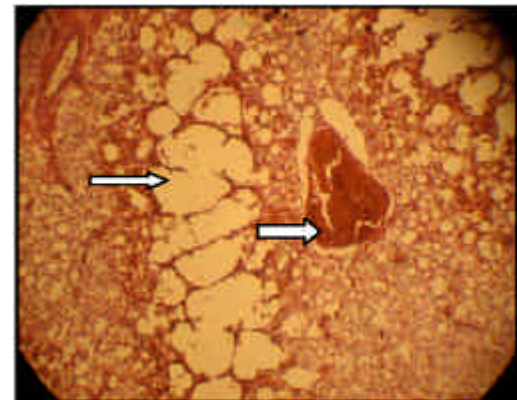


Fig. 19: Lung, congestion and emphysema, areas of foamy alveolar macrophages, intermediate dose, H&E (500x)

emphysema and peri bronchial aggregate of lymphocytes and prominent bronchial epithelium were found (Fig. 21, 22) as compared with control group (Fig. 23).

**Kidney:** Areas of dilated cortical tubules with aggregate of mononuclear cells and cortical tubular basophile

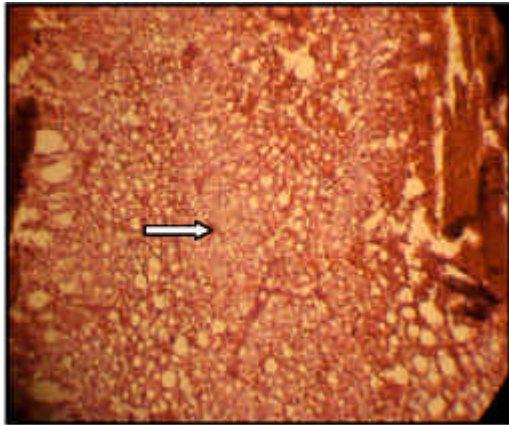


Fig. 20: Lung, minimal interstitial fibrosis, areas of foamy alveolar macrophages, intermediate dose, H&E (500x)

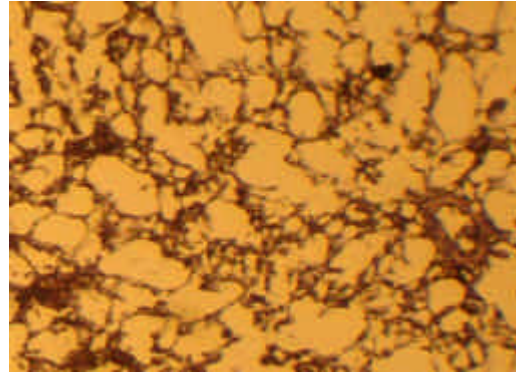


Fig. 23: Lung, control group, H&E (125x)

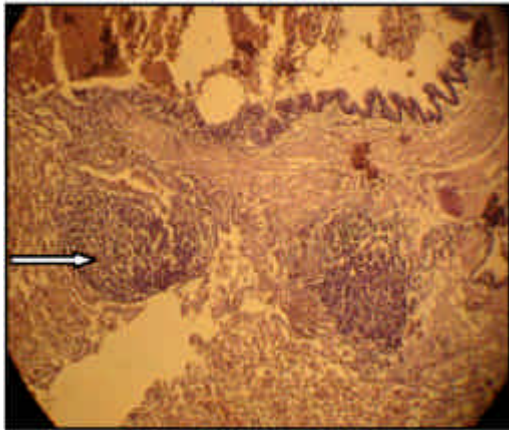


Fig. 21: Lung, per bronchial aggregates of lymphocytes, hypertrophy and proliferation of bronchial epithelium, high dose, H&E (125x)

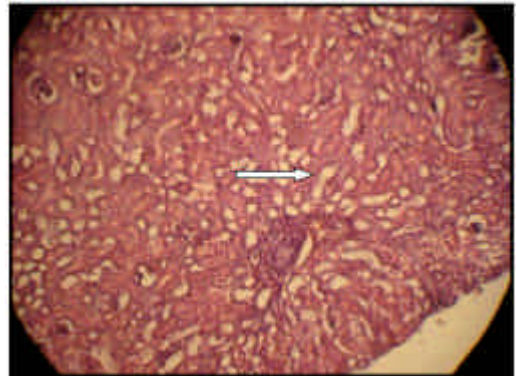


Fig. 24: Kidney of pigeon with low dose of piperazine showed a dilated cortical tubules. E&H (125x)

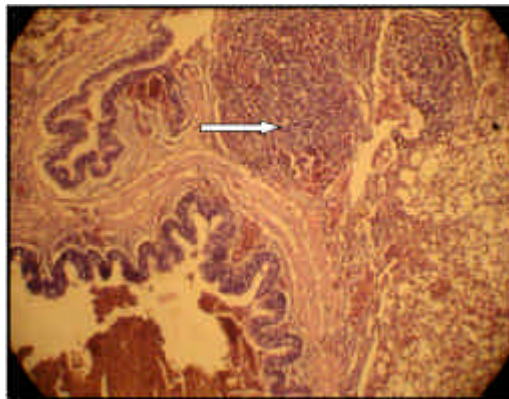


Fig. 22: Lung, congestion, emphysema and per bronchial aggregates of lymphocytes, area of foamy alveolar macrophages, high dose, H&E (500x)

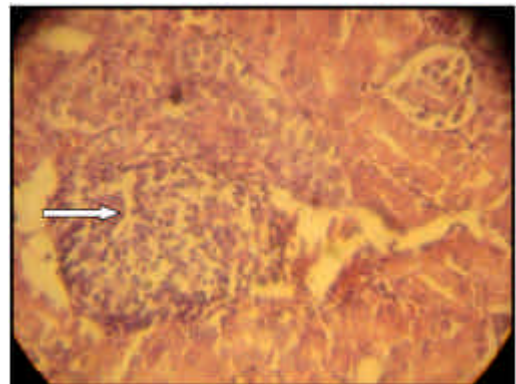


Fig. 25: Kidney of pigeon with low dose of piperazine showed aggregate of mononuclear cells and cortical tubular basophile. E&H (125x)

were founded in pigeons with low dose of piperazine (Fig. 24, 25). Areas of dilated cortical tubules were found in intermediate dose (Fig. 26), while, in high dose in addition of dilated cortical tubules there was infiltration of mononuclear cells and congestion with cortical aggregate of lymphocytes and interstitial fibrosis (Fig. 27, 28) as compared to control group (Fig. 29).

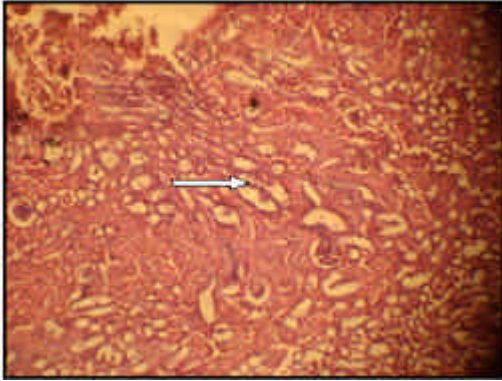


Fig. 26: Kidney, areas of dilated cortical tubules, intermediate dose, H&E (125x)

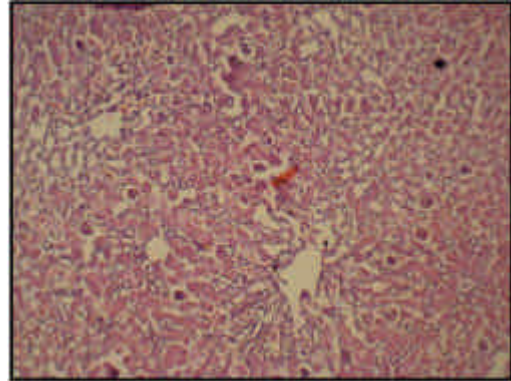


Fig. 29: Kidney, control, H&E (125x)

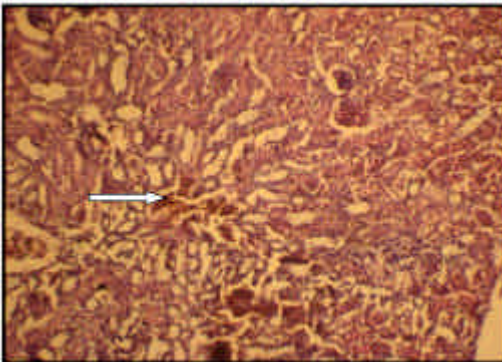


Fig. 27: Kidney, congestion, infiltration of mononuclear cells and areas of dilated cortical tubules, high dose, H&E (125x)

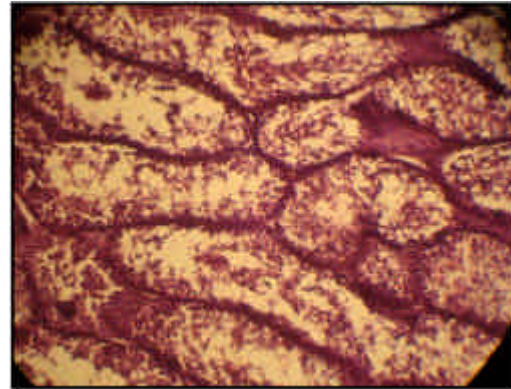


Fig. 30: Testes, suppression of spermatogenesis, associated with marked vacuolation of spermatogonia and sertoli cells, low dose, H&E (125x)

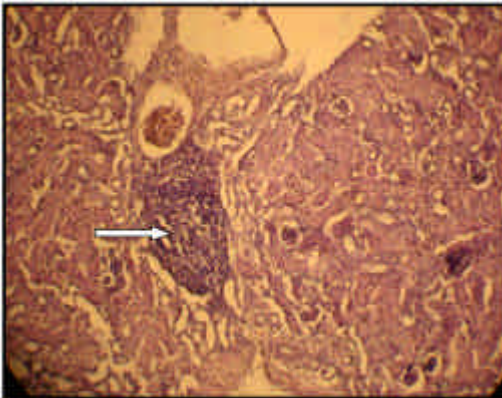


Fig. 28: Kidney, cortical aggregates of lymphocytes and areas of dilated cortical tubules, high dose, (125x)

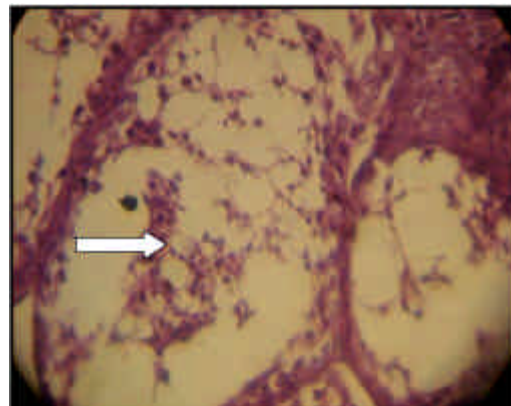


Fig. 31: Testes, suppression of spermatogenesis associated with marked vacuolation of spermatogonia and sertoli cells, low dose, H&E (500x)

**Testes:** Suppression of spermatogenesis associated with marked vacuolation of spermatogonia and sertoli cells, in low dose group (Fig. 30, 31), while, in intermediate and high dose only primary and secondary spermatogenesis were found, indicating

suppression of spermatogenesis associated with marked vacuolation of spermatogonia and sertoli cells (Fig. 32, 33).



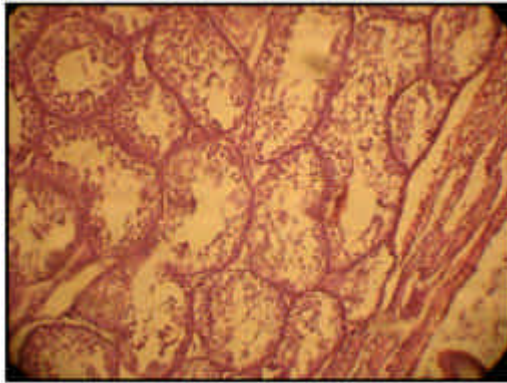


Fig. 32: Testes only primary and secondary spermatogenesis with marked vacuolation of spermatogonia and sertoli cells, intermediate dose, H&E (125x)

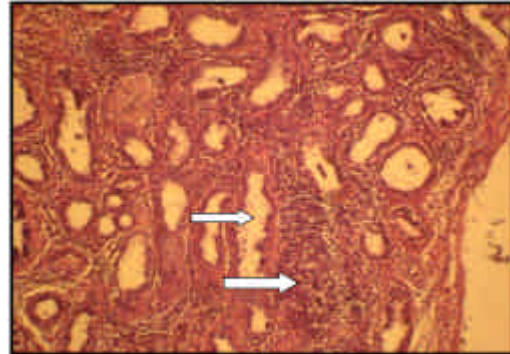


Fig. 35: Epididymus of high dose of piperazine a tubules empty with an aggregate of lymphocytes, H&E (125x)

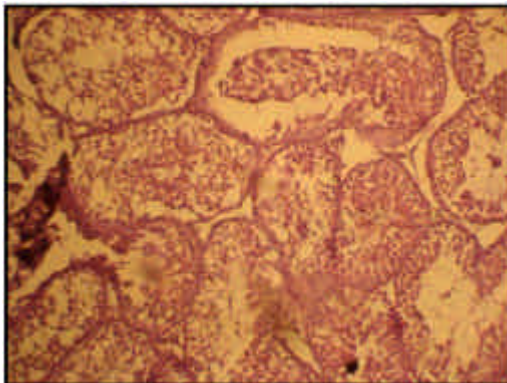


Fig. 33: Testes a suppression of spermatogenesis, only primary and secondary spermatocytes, with vacuolation of spermatogonia and sertoli cells, high dose, H&E (125x)

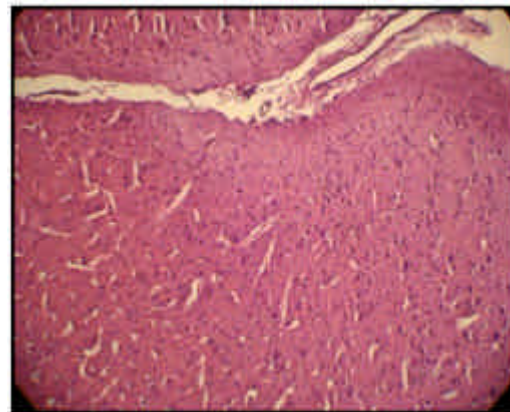


Fig. 36: Brain of high dose treated with piperazine no changes and appeared as normal, H&E (125x)

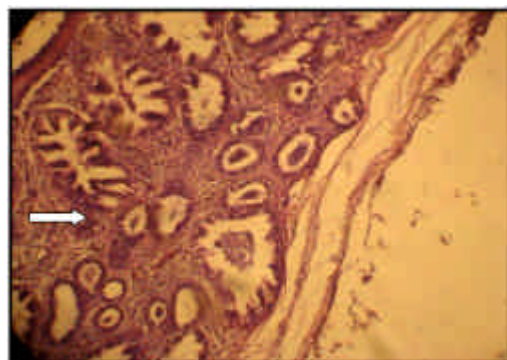


Fig. 34: Epididymus of intermediate dose of piperazine, with some mononuclear cells in the interstitial and tubules with few spermatozoa, H&E (125x)

presences of mononuclear cells in the interstitium and tubules with few spermatozoa (Fig. 34), while, in the high dose, the tubules were empty and area of interstitial mononuclear cells (Fig. 35).

**Brain:** The brain in all treated groups of piperazine in this study did not show any evidence of treatment related changes (Fig. 36).

**Sciatic nerve:** The sciatic nerve in pigeons with low dose of piperazine showed occasional degenerate vacuolated nerve fibers (Fig. 37), while, in intermediate dose the occasional degenerate vacuolated nerve fibers (with less intensity than those of spinal cord) (Fig. 38). In high dose, few to several degenerate vacuolated nerve fibers (Fig. 39) as compared with control (Fig. 40).

**Spinal cord:** Several degenerate vacuolated nerve fibers were found in the spinal cord of pigeons at low and intermediate dosage levels of piperazine (Fig. 41). In high dose marked degenerate vacuolated nerve fibers in white matter were seen (Fig. 42).

**Epididymus:** There was no changes in the epididymus of pigeons with low dose, but in the intermediate dose

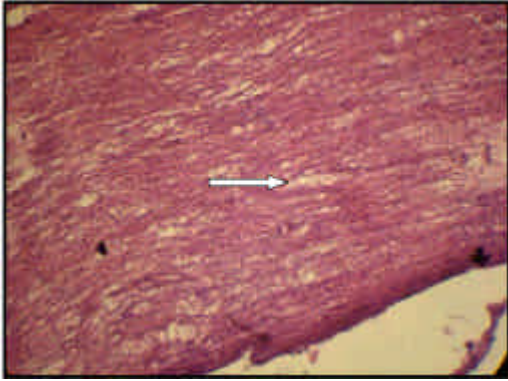


Fig. 37: Sciatic nerve of pigeon with low dose of piperazine with occasional degenerate vacuolated nerve fibers. H&E (500x)

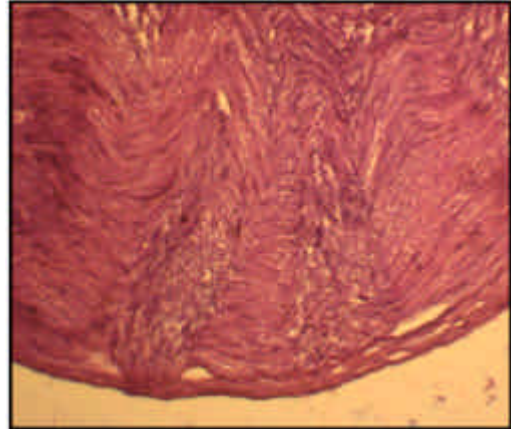


Fig. 40: Sciatic nerve of pigeon, control H&E (125x)

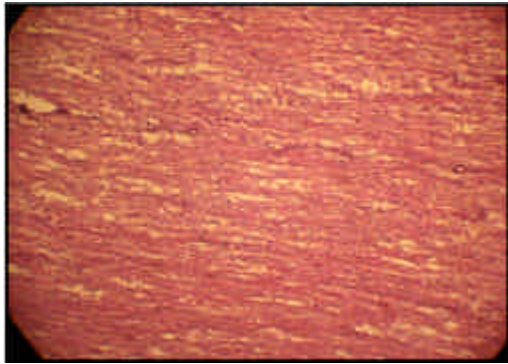


Fig. 38: Sciatic nerve of pigeon, intermediate dose of piperazine with occasional degenerate vacuolated nerve fibers. H&E (500x)

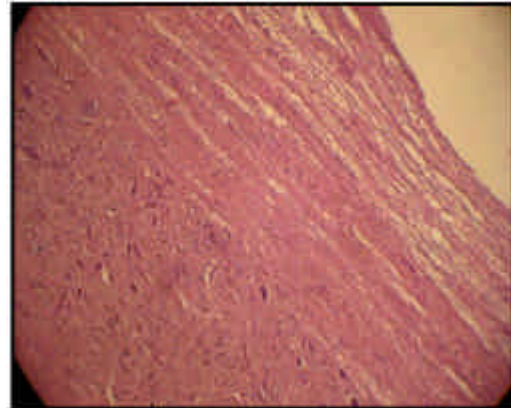


Fig. 41: Spinal cord of pigeon of intermediate dose of piperazine several degenerate vacuolated nerve fibers. H&E (125x)

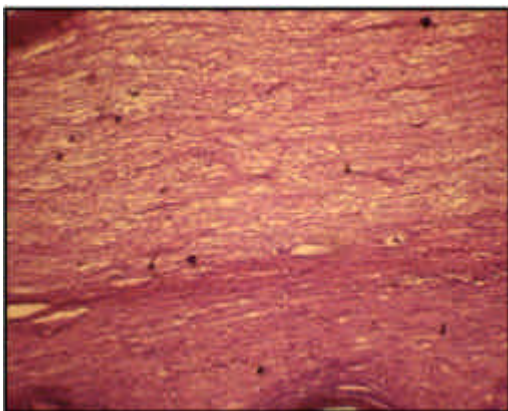


Fig. 39: Sciatic nerve of pigeon, high dose of piperazine several degenerate vacuolated nerve fibers, H&E (125x)

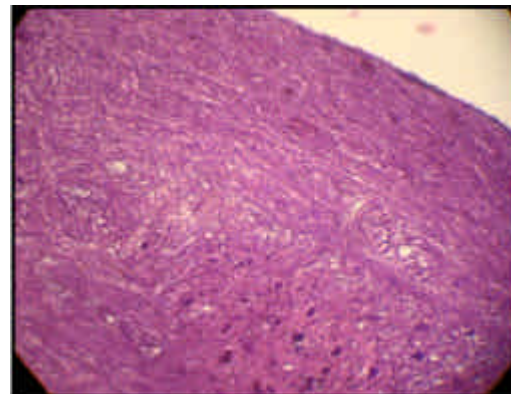


Fig. 42: Spinal cord of pigeon, high dose of piperazine several degenerate vacuolated nerve fibers in white matter. H&E (125x)

## **DISCUSSION**

Piperazine base is strongly alkaline. It is used in the synthesis of various products including pharma-

ceuticals. For a number of years piperazine salts were used to treat intestinal worm infections. This used has

largely ceased but piperazine salts are still used to treat intestinal worm infections in various domestic and farm animals (CSTEE, 2004).

Piperazine has a low acute toxicity in animals and man. However there had been occasional reports of neurotoxicity when piperazine was administered to individuals with intestinal worm infections. It has been suggested that the mechanism of neurotoxicity involves GABA receptors antagonism. Piperazine base is strongly alkaline and therefore is an irritant; however its salts have a much lower irritant potential. The above findings were supported by the findings in the present paper, as treated pigeons at various dosage levels shows evidence of neurotoxicity supported by the findings of degenerate vacuolated nerve fibers mainly in white matter of sciatic nerve and spinal cord with dose related effects.

Piperazine is a mild hepatotoxin and neurotoxin. In dogs which appeared to be among the more sensitive laboratory animal NOEL values of 25 mg/kg body weight day<sup>-1</sup> and 50 mg/kg body weight day<sup>-1</sup> have been identified. Neurotoxic effects had also been observed in man generally at relatively high levels. However some individuals do appear to be rather more sensitive than the general population to the neurotoxic effects. Consequently a NOEL for humans has not been established satisfactorily. It is likely to be of the order of 30 mg/kg body weight day.

A number of developmental toxicity studies had been conducted in rats and rabbits. The effects had been rather non specific mainly a reduction in fecundity. There was no reliable data on reproductive effects in man.

Piperazine is a sensitizing agent in several animal models. In a study in mice using the lymph node essay a weak positive effect was observed. In guinea pig maximization test some cross sensitization had been reported. A number of human case studies described contact dermatitis. Piperazine had also been demonstrated to induce asthma in some workers. It must be concluded that piperazine was both dermal and respiratory sensitizing agent. The present paper showed treatment related effects on the lungs associated with foamy alveolar macrophages, due to phospholipidosis effects induced by piperazine and was reported by (JPHTM *et al.*, 2004).

The piperazine adipate is alternative drug in the treatment of ascaridosis. Cure rates are over 90% when patients are treated for 2 days. Also it can be used for enterobiosis treatment. Piperazine causes paralysis of nematodes by blocking acetylcholine at the myoneural junction. Thus, the paralyzed roundworms are unable to maintain their position in the host and are expelled live by normal peristalsis. No pre-or post treatment cathartics are used. Mild adverse effects occur occasionally, including nausea, diarrhea, abdominal pain and headache. Patients with epilepsy may have an exacerbation of seizures (Wikiveristy, 2011; EC, 2006). In the present study, neurotoxicity effects were noted as

degenerate vacuolated nerve fibers in spinal cord and sciatic nerve respectively, which in agreement with the above findings of the effect of piperazine on the nervous system.

In mammalian species piperazine can produce electroencephalogram alterations, a dose dependent construction of isolated smooth muscles is produced which appears to be mediated by muscarinic cholinergic receptors.

Acute toxicity studies have been performed using piperazine and several salts, the salts which are rapidly hydrolysed to generate piperazine show a correlation of decreased toxicity with decreased solubility (EMEA, 1999).

A three groups of rats were given piperazine sultosylate by gavage at dose 0, 150, 1500 mg/kg bw/day during 6 weeks showed no abnormalities in the weight curves blood and urine analyses, organ weights or histopathological examination of the organs in all groups (EMEA, 2001).

Piperazine base represented at 24 hrs, 34, 44, 68 and 20% of the total piperazine residues in skin fat, skeletal muscles, kidney and liver respectively and 14%, 15%, 34% and 13% respectively at 48 hrs and dropped at 96 hrs to 3, 3, 14, 5% respectively. The metabolites were not identified. Piperazine base was retained as the marker residue (EMEA, 2001).

Taking into account the fact that piperazine is known as secondary amine that can interact with nitrites to produce nitrosamines, which may be carcinogens and this biochemical risk has been evaluated against data generated in several studies (EMEA, 2001).

The administration of 110 mg piperazine (as the adipate) per kg body weight orally to rats for 8 weeks did not result any significant pathological changes ([http://ecb.jrc.it/DOCUMENTS/ExistingChemicals/RISK\\_ASSESSMENT/REPORT/piperazinereport324.pdf](http://ecb.jrc.it/DOCUMENTS/ExistingChemicals/RISK_ASSESSMENT/REPORT/piperazinereport324.pdf), 2011). While, tested full strength by application of drop to rabbits eyes, it has caused severe injury, graded 9 on scale of 1 to 10 after 24 hr. no injury was caused by 0.2 molar at ph 7.5 dropped continuously on rabbit eyes for 10 min after mechanical removal of corneal epithelium to permit penetration (Grant, 1986).

The inhalation of 100 ppm/piperazine adipate/by guinea pigs for 3 hrs, with 7 exposures during a period of 11 days failed to elicit any toxicological reactions ([http://ecb.jrc.it/DOCUMENTS/ExistingChemicals/RISK\\_ASSESSMENT/REPORT/piperazinereport324.pdf](http://ecb.jrc.it/DOCUMENTS/ExistingChemicals/RISK_ASSESSMENT/REPORT/piperazinereport324.pdf), 2011). For the repeated dose toxicity it was shown that a 30-day study in the rat with doses of piperazine hexahydrate given by gavage up to 150 mg/kg bw/day (equivalent to 66 mg piperazine base/kg bw/day) did not provoke adverse effects. However, the average lipid content of liver, muscle, heart, kidney, lungs and serum in the treated group was significantly decreased compared to the control group, while the overall weight gain was not different in both groups ([http://www.ema.europa.eu/ema/index.jsp?curl=pages/document\\_library/landing/docu](http://www.ema.europa.eu/ema/index.jsp?curl=pages/document_library/landing/docu)

ment\_library\_search.jsp&murl=menus/document\_library/document\_library.jsp&mid,2010).

Piperazine (probably the hexahydrate at 0.1% (1000 ppm) in the diet has been administered to rats for 90 days with no effects on appearance, behavior, growth, mortality, food consumption, final body or organ weights, or gross and microscopic examination of the tissues. Doses of 1 and 3% caused moderate liver and kidney pathological effects (Clayton and Clayton, 1982). When administered at 6.25 g/kg in the feed (about 938 mg/kg/day) for 28 weeks and sacrificed at 40 weeks, it failed to induce any significant increase in the incidence of lung adenomas in groups of 40 Swiss mice per sex in comparison with controls (80 animals per sex) ([http://ecb.jrc.it/DOCUMENTS/ExistingChemicals/RISK\\_ASSESSMENT/REPORT/piperazinereport324.pdf](http://ecb.jrc.it/DOCUMENTS/ExistingChemicals/RISK_ASSESSMENT/REPORT/piperazinereport324.pdf).2011).

## REFERENCES

- Annprece, H.T., 1972. A manual for histological Technicians. 3th Edn., Little Brown and Company. Boston, USA, pp: 428.
- Clayton, G.D. and F.E. Clayton, 1982. Patty's Industrial Hygiene and Toxicology: Volume 2A, 2B, 2C: Toxicology. 3rd Edn., New York: John Wiley Sons, pp: 2692.
- CSTEE, 2004. Scientific Committee on Toxicity, Ecotoxicity and the Environment. Opinion on the results of the Risk Assessment of: PIPERAZINE Human Health part. CAS N°: 110-85-0 EINECS N°: 203-808-3 Carried out in the framework of Council Regulation (EEC) 793/93 on the evaluation and control of the risks of existing substances<sup>1</sup> Adopted by the CSTEE during the 43rd plenary meeting of 28.
- Drug-Forum, 2008. The international drugs community discussion forum. TEMPP experiences: <http://www.drugs-forum.co.uk/forum/showthread.php?p=348422>.
- European Medicines Agency (EMA), 1999. The European Agency for the Evaluation of Medicinal Products, Veterinary Medicines Evaluation Unit, Committee for Veterinary Medicinal Products; Piperazine, Summary Report (1). EMEA/MRL/531/98-Final (May 1999).
- European Medicines Agency (EMA), 2001. The European Agency for the Evaluation of Medicinal Products, Veterinary Medicines Evaluation Unit, Committee for Veterinary Medicinal Products; Piperazine, Summary Report (3). EMEA/MRL/807/01-Final (November 2001).
- European Medicines Agency (EMA), 2006. The European Agency for the Evaluation of Medicinal Products, Veterinary Medicines Evaluation Unit, Committee for Veterinary Medicinal Products; Piperazine, Summary Report (3). EMEA/MRL/807/01-Final (November 2001).
- European Commission, 2006. EUR 21642 EN European Union Risk Assessment Report Piperazine, Volume 56. Luxembourg: Office for Official Publications of the European Communities (2005). Available from, as of November 15.
- Fantegrossi, W.E., G. Winger, J.H. Woods, W.L. Woolverton and A. Coop, 2005. Reinforcing and discriminative stimulus effects of 1-benzylpiperazine and trifluoromethylphenylpiperazine in rhesus monkeys. *Drug Alcohol Depend.*, 77: 161-168.
- Grant, W.M., 1986. Toxicology of the Eye. 3rd Edn., Springfield, IL: Charles C. Thomas Publisher, pp: 741.
- [http://www.ema.europa.eu/ema/index.jsp?curl=pages/document\\_library/landing/document\\_library\\_search.jsp&murl=menus/document\\_library/document\\_library.jsp&mid](http://www.ema.europa.eu/ema/index.jsp?curl=pages/document_library/landing/document_library_search.jsp&murl=menus/document_library/document_library.jsp&mid).<http://www.PIPERAZINE-34> directions for use. (2010).
- [http://ecb.jrc.it/DOCUMENTS/ExistingChemicals/RISK\\_ASSESSMENT/REPORT/piperazinereport324.pdf](http://ecb.jrc.it/DOCUMENTS/ExistingChemicals/RISK_ASSESSMENT/REPORT/piperazinereport324.pdf), 2011.
- JPHTM Poemen, J. Kelder and T. Hafmans, 2004. Toxicologic Pathology, Elsevier.
- Obiukwu, M.O. and I.O. Onyali, 2006. Comparative efficacy of ancylool, ivomec, mebendazole and piperazine against *Ancylostoma caninum* in experimentally infected pups. *Anim. Res. Inter.*, 3: 540-544.
- Urquhart, G.M., 1996. Veterinary Parasitology, 1st Edn., ELBS, Longman House, Burnt Mill, Harlow, England, pp: 256-257.
- Wikiveristy, 2011. Antimicrobial agents III. [www.wikiveristy.Com](http://www.wikiveristy.Com).