

ISSN 1682-8356
ansinet.org/ijps



INTERNATIONAL JOURNAL OF
POULTRY SCIENCE

ANSI*net*

308 Lasani Town, Sargodha Road, Faisalabad - Pakistan
Mob: +92 300 3008585, Fax: +92 41 8815544
E-mail: editorijps@gmail.com

Efficacy of HVT-IBDV Vector Vaccine Against Recent Egyptian vvIBDV in Commercial Broiler Chickens

Hesham Sultan¹, Hussein A. Hussein², Alaa G. Abd El-Razik¹, Sallah El-Balall³,
Shaima M. Talaat¹ and Awad A. Shehata^{1,4}

¹Department of Poultry and Rabbit Diseases, Faculty of Veterinary Medicine,
Minoufiya University, Minoufiya, Egypt

²Department of Virology, Faculty of Veterinary Medicine, Cairo University, Giza, Egypt

³Department of Pathology, Faculty of Veterinary Medicine, Minoufiya University, Minoufiya, Egypt

^{1,4}Institute of Microbiology, Faculty of Veterinary Medicine, Leipzig University, Leipzig, Germany

Abstract: The efficacy of a turkey herpesvirus (HVT-IBD) vector vaccine encoding the VP2 gene of Infectious Bursal Disease (IBD) was evaluated in comparison with classic vaccines on two commercial broiler chicken farms (A and B), with high levels of Maternal Derived Antibodies (MDA). The HVT-IBD vaccine was administered into chickens of farm A at 1-day-old while intermediate and intermediate-plus vaccines were given at 1-and 14-day-old into chickens of farm B, respectively. An early significant seroconversion was detected at 21-day-old in chickens of farm A, while no significant serological response was detected in farm B at this time. The antibody level was significantly higher in chickens in farm A at 28-and 35-day-old. Moreover, HVT-IBD vaccine provided complete protection against recent Egyptian vvIBDV isolate. In conclusion, HVT-IBD vaccine has the ability to induce an immune response in birds with high levels of MDA and could protect against recent Egyptian vvIBDV isolates.

Key words: Recombinant viral vectored vaccines, infectious bursal disease, herpesvirus of turkeys, very virulent IBDV

INTRODUCTION

Infectious Bursal Disease (IBD) or Gumboro disease, caused by IBDV, is an acute and highly contagious disease in chickens at 3 weeks of age and older. It causes high mortality and immunosuppression in recovered chickens leading to a variety of secondary infections and a decreased response to vaccinations, which results in an important economic impact to the poultry industry worldwide (van den Berg *et al.*, 2000). IBDV targets the bursa of Fabricius, causing damage by destroying developing B-lymphocytes. Several clinical forms of IBD are observed in the field ranging from mild immuno-depression to high mortality (90-100%). The latter is caused by very virulent IBDV (vvIBDV) strains (Chettle *et al.*, 1989). The double stranded RNA (dsRNA) viral genome consists of two segments, A and B (Murphy *et al.*, 1995). Segment B, the smaller, encodes the 97 kDa VP1 with polymerase and capping enzyme activities, while segment A contains a large Open Reading Frame (ORF) encoding a 110 kDa precursor protein that is processed into the mature structural proteins VP2 and VP3 by viral protease VP4 (Boot *et al.*, 2001). The VP2 is responsible for serotype specificity; conversely, VP3 is a group-specific antigen that is recognized by non-neutralizing antibodies, which may cross-react with both serotypes (Oppling *et al.*, 1991). The VP2 has been identified as the major host-protective antigen and

conformational dependent immuno-dominant epitopes located in a hyper variable region of VP2 and capable of eliciting viral neutralizing antibodies against IBDV (Becht *et al.*, 1989; Fahey *et al.*, 1989; Islam *et al.*, 2001; Ashraf *et al.*, 2007). Different Modified Live Vaccines (MLVs) containing classical or variant viruses are commercially available and are classified according to their degree of attenuation as "mild", "intermediate", "intermediate plus" and "hot" IBD vaccines (Saif, 1998; van den Berg, 2000; Muller *et al.*, 2003). Mild and intermediate vaccines are safer, in that they cause less bursal damage, than "hot" vaccines, but have a poor efficacy in the presence of MDA and against vvIBDVs. In contrast, less attenuated strains ("intermediate plus" and "hot" vaccines) can overcome higher levels of MDA, but they may cause more severe lesions in the bursa follicles, resulting in immunosuppression. These strains are not recommended for chickens younger than 10 days of age (Prandini *et al.*, 2008). Many new IBDV vaccines were developed, including subunit, DNA and vector vaccines. Most of them are still experimental but some have been used commercially. The main advantage of these vaccines is their ability to overcome difficulties in managing MDA on vaccine intake (Bublöt *et al.*, 2007; Hsieh *et al.*, 2007; Rong *et al.*, 2007; Villegas *et al.*, 2008; Le Gros *et al.*, 2009; Rojs *et al.*, 2011). Among these vaccines, a recombinant turkey herpes virus

(HVT)-IBD vaccine was generated by inserting an IBDV VP2 gene expression cassette into the HVT genome. Different vaccination programs are required to evaluate different IBDV vaccines under field conditions. The objective of these trials was to evaluate the protective efficacy HVT-IBD vaccine compared with intermediate and intermediate-plus vaccines against the recent Egyptian vvIBDV.

MATERIALS AND METHODS

Infectious bursal disease virus: A local field isolate of vvIBDV designated "Br/Men.Egypt/09", isolated from commercial broiler. This virus is highly pathogenic in 8-week-old susceptible commercial layer chickens. It causes 90% mortality rate in challenged birds after intraocular inoculation.

Molecular typing of local field isolate: Total RNA of "Br/Men. Egypt/09" field isolate was extracted from bursal supernatant using RNA extraction kit (Roche Diagnostic Co., Indianapolis, IN, USA), according to the manufacturer's instructions. The cDNA was synthesized followed by amplification of a 248 a specific fragment in the VP2 gene of IBDV (positions 804 to 1051, according to the numbering system of Bayliss and co-workers (Bayliss *et al.*, 1990) using the forward primer 5'-GTR ACR ATC CTG TTC GC-3' and the reverse primer 5'-GATGTR AYT GGC TGG GTT ATC TC-3'. After amplification, PCR product was subjected to electrophoresis on 2% agarose gels and stained with ethidium bromide. Purified PCR products were sequenced in Avian Diagnostic Laboratory (Athens, GA30606, USA), followed by analysis in an ABI PRISM 310 Genetic analyzer (Applied Biosystems). Sequences were assembling and edited using Chromas v.1.45 (<http://www.techelysium.com.au/chromas14x.html>). Nucleotide sequences were identified by NCBI Blast program (<http://blast.ncbi.nlm.nih.gov>). The following viruses sequences were used for the phylogenetic tree; Br/Men. Egypt/09 isolate (JN 860196), Giza 2008 (EU 584433), strain Beh 2003 (EU 860092), K 406/89 (AF 159218), HLJ 07 vvIBDV (JN 106051), France 04F7 (DQ 916196), France 97 AL 13 (DQ 916194), strain UK661 (AJ 878898), Strain NVRI 99582 (FJ 000331), Lukert (FJ 497057), Bursine plus (AF 281231), IBD Blen (AY 332560), Strain 2512 (DQ 355819), strain Faragher 52-70 (Y 14958), Var A (AJ 878675), VarE (AJ 878905).

IBDV vaccines: A commercial vector vaccine HVT-IBD (Merial S.A.S., USA), generated by inserting an IBDV VP2 gene (cloned from Faragher 52/70 IBDV strain) expression cassette into HVT genome and two classic vaccines, one intermediate "S706" and one intermediate plus vaccine "Bursin plus", were used in this study.

Chickens and vaccination programs: Two commercial broiler flocks (Hubbard) with 50,000 chickens per house,

designated A and B, were included in the field trial. They were populated at the same day. The chickens were originated from parent flocks, which had been vaccinated against IBDV with a live intermediate vaccine and boosted with an inactivated vaccine prior to the production period. Chicks in farm A were vaccinated subcutaneously, at 1-day-old with HVT-IBD vector vaccine, while chicks in farm B were vaccinated at 1 and 14 days of age with intermediate (by spray) and intermediate-plus (in drinking water), respectively. Other vaccinations against Newcastle Disease (ND), Avian Influenza (AI) and Infectious Bronchitis (IB) were the same in the two farms as follow: At one-day-old, chickens were vaccinated against ND with live and inactivated vaccines, AI with inactivated vaccine and IB with live vaccine. Chickens were boosted with Lasota at 10 and 21-day-old. On each farm, blood samples were randomly collected weekly from 20 birds for serological examinations. The individual bursa/body weight (B:B R) ratio was recorded for each flock. Ten broilers from each flock were randomly chosen weekly, weighted and necropsied to calculate B:B R ratio according to Sharma and co-workers (Sharma *et al.*, 1989). The bursal index was calculated as described by Lucio and Hitchner (1979): the bursa of Fabricius weight (gm)/body weight (gm) x 1000.

Laboratory vaccination experiment: Two hundred 1-day-old commercial broilers (Hubbard) were divided randomly to 8 groups (1-8). Chicks were floor reared under natural day light in strictly isolated experimental rooms, previously cleaned and disinfected and were provided with commercial broiler starter ration. Water and feed were provided ad libitum. Experimental vaccination and challenge were described in Table 1. Chicken blood were collected weekly from treated and non-treated chickens from wing vein or by slaughtering and kept in slop position at 37°C for one hour then at 4°C over night. Sera then separated by centrifugation at 3000 rpm/10 min and stores at -20°C till tested. Sera were inactivated at 56°C for 30 min before testing.

Indirect Enzyme linked Immunosorbant Assay (ELISA): Serum samples were screened by ELISA for antibodies to IBDV, using commercial ELISA Kits supplied by Synbiotic Corporation (11011 VIA San Diego, CA 92127) and BD-Plus ELISA (BioChek Corporation, Burg Bracklaan 57, 2811 BP Reeuwijk Holland). Application and interpretation of the test were carried out according to the instructions of the kits manufacturers.

Agar gel precipitation test: The test was used to demonstrate the presence of antibodies to 1 BDV in examined chicken sera and for detection of 1BDV antigen (s) in the cloacal bursa of affected chickens. A known positive and negative precipitating antigen in the form of bursal homogenates and a known positive and

Table 1: Results of the degree of protection in broiler chickens vaccinated with HVT-IBDV vector vaccine after challenge with Br/Men. Egypt/09 Egyptian isolate

Group No (n = 20)	IBD vaccination ¹	Age of challenge ²	Assessment of protection at 7 days post challenge			
			Mortality	B:BR ³	B:BI ⁴	MSI ⁵
1	Vaccinated	28	0%	0.77	0.30	2.00
2	Vaccinated	ND ⁶	10%	0.30	0.12	3.90
3	Non-vaccinated	28	0%	1.70	0.68	1.25
4	Non vaccinated	ND	0%	2.50	1.00	0.00
5	Vaccinated	28	0%	0.70	0.34	1.90
6	Vaccinated	ND	5%	0.29	0.14	4.00
7	Non-vaccinated	35	0%	1.32	0.63	1.50
8	Non vaccinated	ND	0%	2.08	1.00	0.00

¹Chickens vaccinated subcutaneously at one-day-old with HVT-IBD.

²Chickens subjected to oculonasal challenge with 100 µl/bird of Br/Men. Egypt/09 isolate (10³ EID₅₀)

³Mean Bursal body weight ratio (Sharma *et al.*, 1989).

⁴Mean Bursal body weight index expressed (Lucio and Hitchner, 1979)

⁵Mean severity index (Sharma *et al.*, 1989)

⁶Not challenged

negative precipitating reference antisera against IBDV were obtained from Intervet Co (Inter. B. V. Boxmeer, Holland).

Histopathological examination: Bursa of Fabricius of experimentally infected, vaccinated and control birds were fixed in neutral buffered 10% formalin solution and processed for paraffin sections in the usual way. Sections were stained with Hematoxylin and Eosin stains. The severity of bursal lymphoid tissue lesions were scored from 0 to 4 on the basis of the degree of lymphoid necrosis and/or lymphocytic depletion according to Sharma and coworkers (Sharma *et al.*, 1989) as follows: 0 = 5%, 1 = 5-25% 2 = 25-50%, 3 = 50-75% and 4 >75% of the lymphoid follicles per field affected.

Haemagglutination inhibition test: Sera were examined for HA-specific antibodies by HI test according to OIE manual (OIE, 2005) using either the commercial H5N2 (A/chicken/Mexico/232/94/CPA) for avian influenza A subtype H5 and NDV antigen (Inter. B. V. Boxmeer, Holland). Serial two-fold serum dilutions in PBS were subsequently mixed with equal volumes (25 µl) containing 4 haemagglutinating units (HAU) of the virus. 25 µl of washed chicken red blood cells was added and incubated for 40 min at room temperature. The HI titres were determined as reciprocals of highest serum dilutions in which inhibition of haemagglutination was observed. Know positive and negative NDV and AIV antisera were obtained from Intervet international (Inter. B. V. Boxmeer, Holland).

RESULTS

Molecular characterization of Egyptian field isolate (challenge virus): The molecular characterization of the Br/Men. Egypt/09 vvIBDV was achieved by RT-PCR and sequencing. Electrophoresis of the amplified segment

revealed the presence of the expected band (248 bp) of IBDV VP2 gene. The phylogenetic analysis of the nucleotide sequence showed that this isolate is a very virulent strain (Fig. 1).

Results of MDA waning and serological response: The decline of MDA in commercial broiler chickens, obtained from IBD-vaccinated parents, tested by classic and BD-plus ELISA was seen during the first few weeks (Fig. 2A and B). Sera obtained weekly from farm A (vaccinated with HVT-IBDV) and B (vaccinated with intermediate and intermediate plus vaccines) also was tested for IBDV antibodies by classic ELISA, BD-plus ELISA and AGPT. At 21-day of age, vaccinated chickens in farm A showed significant increase of IBDV antibodies compared with farm B and non-vaccinated chickens ($p < 0.001$), at this time, no significant antibody response was detected in chickens vaccinated with intermediate and intermediate plus. Moreover, the antibody level was significantly higher in farm A than in farm B ($p < 0.0001$) using classic or, BD-plus ELISA at 28 and 35 days-old (Fig. 3). The antibody response of chickens located in the two farms was also tested by AGPT. In Farm A, 10/20 (50%), 12/20 (60%) and 20/20 (100%) serum samples were positive at 21, 28 and 35-days of age, respectively, compared with 0/20 (0%), 5/20 (25%) and 19/20 (95%) in farm (B). The effect of IBDV vaccines on the serological response towards ND and AI vaccines were tested. There were no significant differences of haemagglutinating antibody titres for AI and ND Chickens in the two farms. At 35-day-old, the antibody titres towards AI were 4 log₂ and 3.9 log₂ for chickens in farm A and B, respectively, while, the titres towards ND were 4.6 log₂ and 4.3 log₂, respectively. The B/B ratio was calculated in the two farms at 2, 4 and 6 weeks of age. At the age of 4 and 6 weeks, a significant lower ratio was observed in farm B at $p < 0.001$ (Fig. 3).

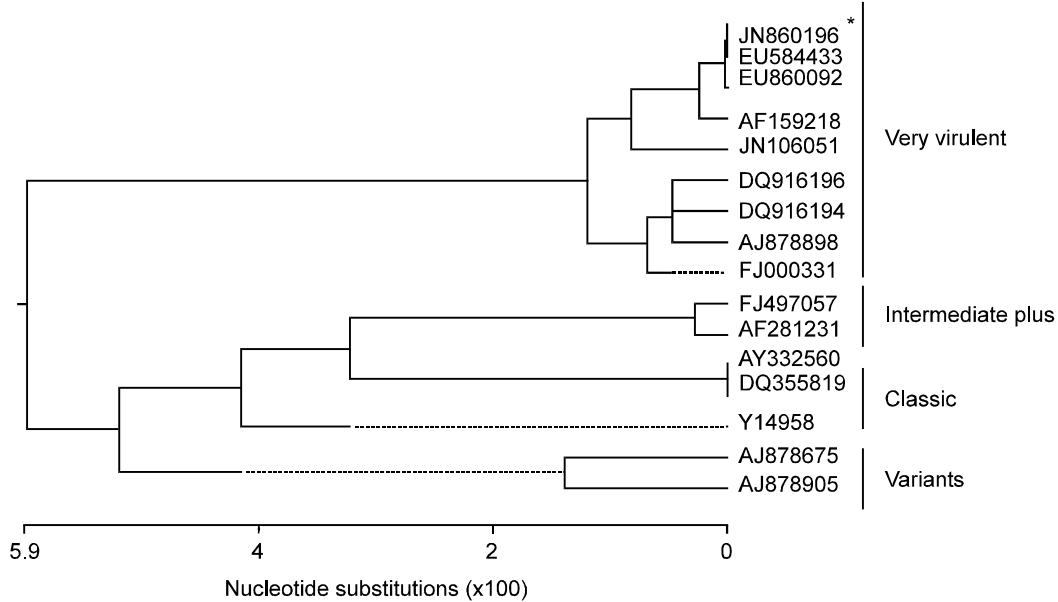


Fig. 1: Phylogenetic analysis of the amplified 248-bp IBDV VP2 segment (positions 804 to 1051 numbering according to Bayliss *et al.* (1990). *Br/Men.Egypt/09 isolate

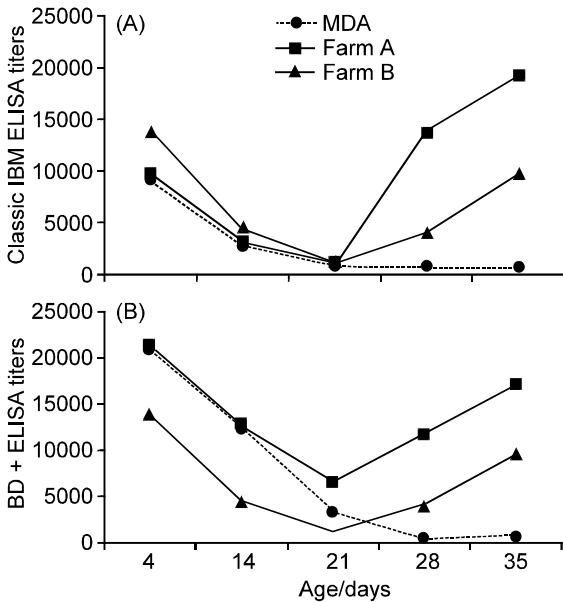


Fig. 2: ELISA average antibodies titres using classic- (A) and BD-plus ELISA (B) kits showing the waning of the maternal derived antibodies as well as the active immune seroconversion in vaccinated chickens. Chickens in farm A were received the HVT-IBDV vaccine at 1-day-old while chickens in farm B were received intermediate at 1-day-old and boosted with intermediate plus after two weeks

Results of experimental challenge: The efficacy of HVT-IBDV to the recent Egyptian IBDV isolate was studied.

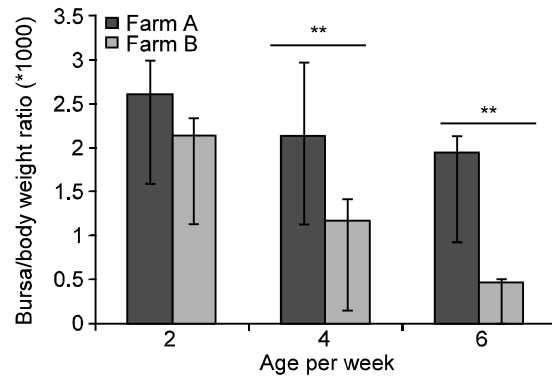


Fig. 3: Average evolution of Bursa/Body Weight Ratio (B/BR) over time in commercial broiler flocks vaccinated with HVT-IBDV at 1-day-old (Farm A). Asterisk (**) indicates a significant difference at $p < 0.001$

Clinical signs and mortality were observed in control chickens after challenge at 28- and 35-day-old. Out of 20 birds 2 (20%) birds were died in control group when challenged at 28-day-old and 1/20 birds (5%) were died when challenged at 35-day-old. Birds were depressed with ruffled feathers and showed white diarrhea. The typical bursal oedema was seen in post mortem examination. No mortalities were recorded in IBD vaccinated and challenged as well as in non-treated birds. The bursal atrophy was significantly clear in challenged non-vaccinated chickens (Table 1). Ten days post challenge non-vaccinated chickens showed a considerable rise in the antibody level while non-treated chickens still have residual MDA.

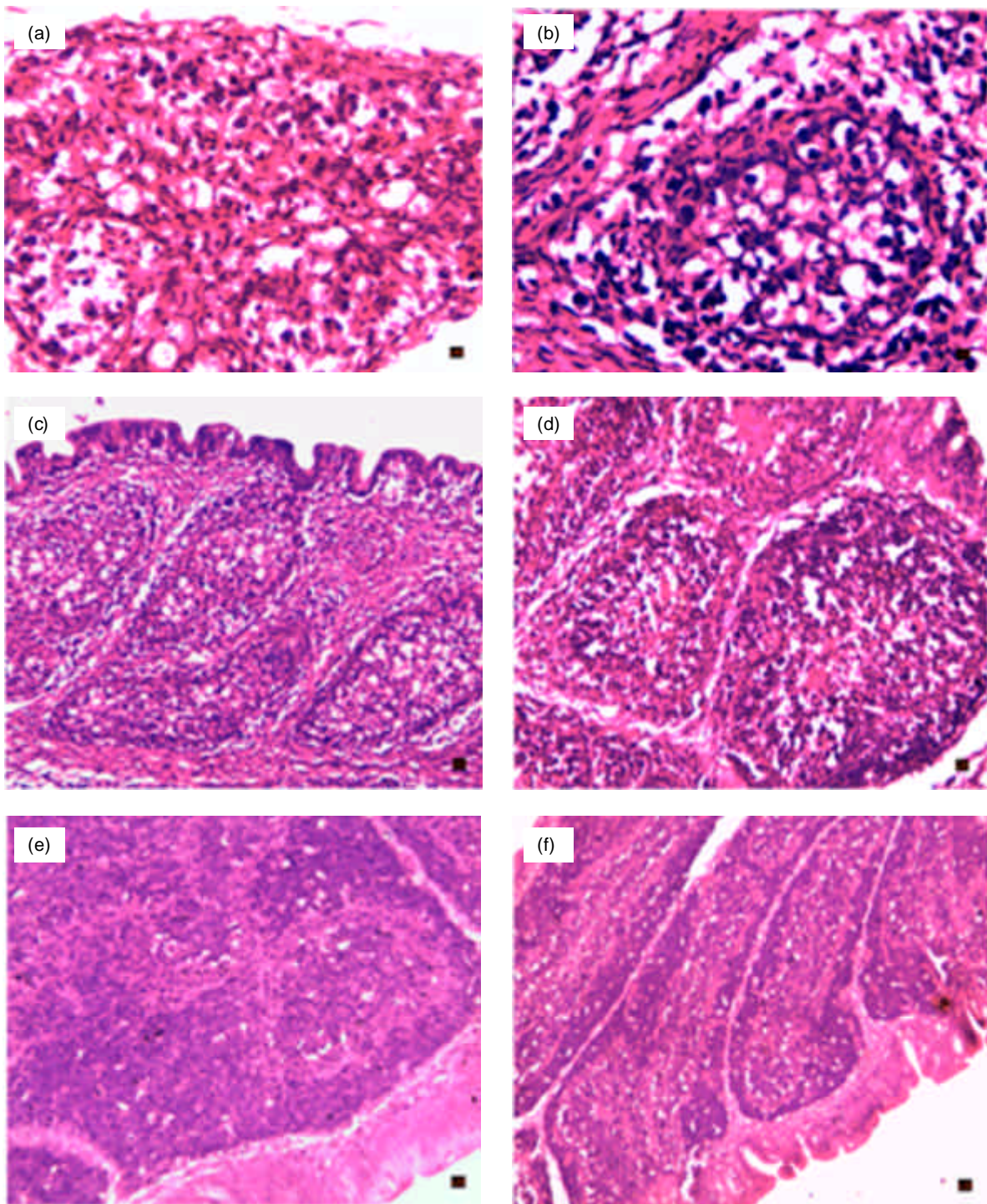


Fig. 4: Histopathological examination of bursa of Fabricius forevaluation of HVT-IBD vector vaccine in commercial broiler chickens. A and B: Bursa of non-vaccinated chickens and challenged with Br/Men.Egypt/09 isolate at 28- and 35 day-old, respectively, showing severe cysts formation and lymphocytic depletion (H&E x40). C and D: Bursa of chickens vaccinated at 1-day-old with HVT-IBD and challenged with Br/Men.Egypt/09 isolate at 28 and 35 day-old, respectively, showing mild cysts formation and lymphocytic depletion (H&E x10). E and F: Bursa of chickens vaccinated at one-day-old with HVT-IBD and non-challenged showing mild lymphocytic depletion (H&E x20)

DISCUSSION

The field observation at the farms level illustrated the difficulties in managing a vaccine programs with attenuated intermediate vaccines in the presence of MDA which interferes with protection from vaccinal virus. Additionally, IBDV is not neutralized by MDA (van den Wijngaard *et al.*, 2001). The optimal time of vaccination based on the half-life of the MDA and its variation, the genetic background of the chickens and the ability of the vaccine strain to overcome the MDA (Rautenschlein *et al.*, 2007; Block *et al.*, 2007). Also, the efficacy of IBD vaccines depends on the sequence of the circulating IBD viruses. Recent Egyptian IBD viruses showed genetic mutations in VP2 gene which resulted in antigenic and pathogenic variants that continues to cause disease in commercial reared chickens (Metwally *et al.*, 2009; Hussein and Sultan, 2009). The objective of the present study was to evaluate the efficacy of different IBDV vaccines against Egyptian vvIBDV. The immunogenicity and efficacy of two IBD vaccination programs were evaluated using two types of IBDV vaccines in chicken. Firstly, the molecular characterization of the vvIBDV in bursal homogenate designated "Br/Men. Egypt/09" was performed using RT/PCR and sequencing. Phylogenetic tree confirmed the existence and circulation of mutated vvIBDV in the Egyptian farms. In the present study, the efficacy of a HVT-IBD vector vaccine was compared with classic intermediate IBD vaccines in commercial broiler chickens, having high level of Maternal Derived Antibodies (MDA) and placed on two farms (A and B). In farm A, HVT-IBD vector vaccine was administrated subcutaneously at one-day of age and in farm B, intermediate and intermediate-plus were administrated at 1 and 14 day of age, respectively. The serological response in the two farms has been tested using two ELISA kits, the classic IBD Ab test kit and an "improved" kit, the BD-plus IBD test kit. Both kits are indirect ELISAs and recognize antibodies to both classical and variant strains of IBDV. The difference between the two tests lies in the nature of the IBDV antigen coated on the plates. Classic IBD ELISA kit uses an antigen derived from a classical strain grown in tissue culture while BD-plus ELISA kit uses a native bursal derived classical strain antigen. The BD-plus ELISA kit allows a more accurate detection of IBDV protective VP2 antibodies (Bublöt *et al.*, 2007). In non vaccinated group, kept in our laboratory to follow waning of MDA antibodies, MDA were more detected at 21-28 day of age using the BD-plus ELISA kit that confirm the sensitivity of this kit which agreed with previous studies (Bublöt *et al.*, 2007; Le Gros *et al.*, 2009; Rojs *et al.*, 2011). These results suggested that the serological examination of optimum vaccination for each flock is required to effectively control IBDV in the field (Tsukamoto *et al.*, 1995). Two main factors influence the correlation between the potency of

IBDV vaccines in young chickens and the protection against IBDV challenge. These are the strain used in the vaccine and the virulence of IBDV challenge strain (Riks *et al.*, 2001). Satisfactory vaccination with HVT-IBD vector vaccine was always followed by excellent seroconversion as suggesting that vector HVT-IBD was more immunogenic (Bublöt *et al.*, 2007; Le Gros *et al.*, 2009). IBDV-specific antibodies were measured by the AGPT. Antibody response was early detected at 21 day of age in chickens vaccinated with HVT-IBDV vaccine indicating its ability to induce an immune response in birds with a high level of MDA (Le Gros *et al.*, 2009; Rojs *et al.*, 2011). However, chickens vaccinated with the classic vaccine showed no antibody at this age which indicated that intermediate vaccines could not overcome MDA. On the other hand, IBD modified live vaccines may interfere with other vaccinations (Mazariegos *et al.*, 1999). Our study showed that vector HVT-IBD vaccine did not interfere with ND and AI vaccines (Bublöt *et al.*, 2007). The serological examinations of these viruses was performed to determine not only the IBDV-induced immunosuppression but also to study the bilateral effects between IBDV and these viruses. The HVT-IBD vector vaccine induced 100% protection in vaccinated broiler chickens when challenged either at 28-or 35-days of age with Egyptian vvIBDV. Since protection against mortality might not be considered as absolute criterion of efficiency of the tested vaccine, other parameter reflecting protection against bursal atrophy were included in this study. Broiler chickens vaccinated with vector HVT-IBD vaccine also protected from gross bursal lesion and bursal atrophy. The partial bursal atrophy in chickens vaccinated with vector HVT-IBD vaccine compared to non vaccinated control could speculate the high risk area of these farm and continuous exposure of chickens with vvIBDV. Partial protection of was represents by bursal index and MSI at 7-days post challenge (Fig. 4); similar results were described by Le Gros *et al.* (2009).

In conclusion, IBDV vaccine efficacy, under field condition, in broiler chickens depends on MDA levels, vaccination time, the vaccine strain and epidemiological field situation of vvIBDV. The MDA interfering with the live IBDV vaccines replication had no detectable effect on the vector vaccine intake and early serological response. Successful vaccination with vector vaccine could protect against mortality and partially against bursal atrophy against recent circulated Egyptian vvIBDV.

REFERENCES

- Ashraf, S., Y. Tang and Y.M. Saif, 2007. Development of differential RT-PCR assays and molecular characterization of the complete VP1 gene of five strains of very virulent infectious bursal disease virus. *Avian. Dis.*, 51: 935-941.

- Bayliss, C.D., U. Spies, R. Shaw, W. Peters, A. Papageorgiou, H. Muller and M.E.G. Boursnell, 1990. A comparison of the sequences of segment A of four infectious bursal disease virus strains and identification of a variable region in VP2. *J. Gen. Virol.*, 71: 1303-1312.
- Becht, H., H. Muller and H.K. Muller, 1989. Comparative studies on structural and antigenic properties of two serotypes of infectious bursal disease virus. *J. Gen. Virol.*, 59: 631-640.
- Block, H., K. Meyer-Block, D.E. Rebeski, H. Scharr, de S. Wit, K. Rohn and S. Rautenschlein, 2007. A field study on the significance of vaccination against Infectious Bursal Disease Virus (IBDV) at the optimal time point in broiler flocks with maternally derived IBDV antibodies. *Avian. Pathol.*, 36: 401-409.
- Boot, H.J., A.A. Huurne, S.A. Vastenhouw, A. Kant, B.P. Peeters and A.L. Gielkens, 2001. Rescue of infectious bursal disease virus from mosaic full-length clones composed of serotype I and II cDNA. *Arch. Virol.*, 146: 1991-2007.
- Bublot, M., N. Pritchard, F.X. Le Gros and S. Goutebrozey, 2007. Use of a vectored vaccine against infectious bursal disease of chickens in the face of high-titred maternally derived antibody. *J. Comp. Pathol.*, 137: 81-84.
- Chettle, N., J. Stuart and P. Wyeth, 1989. Outbreak of virulent infectious bursal disease in East Anglia. *Vet. Rec.*, 125: 271-272.
- Fahey, K.J., K. Erny and J.A. Crooks, 1989. Conformational immunogen on VP2 of infectious bursal disease virus that induces virus-neutralizing antibodies that passively protect chicken. *J. Gen. Virol.*, 70: 1473-1481.
- Hussein, H.A. and H.A. Sultan, 2009. Genetic Bursal Disease in Egypt. *Proc. 16th World Veterinary Poultry Association Congress. Marrakes, Morocco 8-12.*
- Hsieh, M.K., C.C. Wu and T.L. Lin, 2007. Priming with DNA vaccine and boosting with killed vaccine conferring protection of chickens against infectious bursal disease. *Vaccine*, 25: 5417-5427.
- Islam, M.R., K. Zierenberg and H. Muller, 2001. The genome segment B encoding the RNA-dependent RNA polymerase protein VP1 of very virulent Infectious Bursal Disease Virus (IBDV) is pathogenically distinct from that of all other IBDV strains. *Arch. Virol.*, 146: 2481-2492.
- Le Gros, F.X., A. Dancer, C. Giacomini, L. Pizzoni, M. Bublot, M. Graziani and F. Prandini, 2009. Field efficacy trial of a novel HVT-IBD vector vaccine for 1-day-old broilers. *Vaccine*, 27: 592-596.
- Lucio, B. and S.B. Hitchner, 1979. Infectious bursal disease emulsified vaccine: Effect upon neutralizing-antibody levels in the dam and subsequent protection of the progeny. *Avian Dis.*, 23: 466-478.
- Mazariegos, L.A., P.D. Lukert and J. Brown, 1999. Pathogenicity and immunosuppressive properties of infectious bursal disease intermediate strains. *Avian. Dis.*, 34: 203-208.
- Metwally, A.M., A.Y. Ausama, B.S. Iman, A.M. Walaa, M.M. Attia and M.R. Ismail, 2009. Re-emergence of very virulent IBDV in Egypt. *Int. J. virol.*, 5: 1-7.
- Muller, H., M.R. Islam and R. Raue, 2003. Research on infectious bursal disease-the past, the present and the future. *Vet. Microbiol.*, 97: 153-165.
- Murphy, F.A., C.M. Fauquet and D.H.L. Bishop, 1995. Virus taxonomy. Classification and nomenclature of virus. Six report of international committee on taxonomy of viruses. *Arch. Viral.*, suppl. 10: 1481.
- OIE, 2005. Manual of diagnostic tests and vaccines for terrestrial animals. Chapter, 2.7.12.
- Oppling, V., H. Muller and H. Becht, 1991. The structural polypeptide VP3 of infectious bursal disease virus carries group- and serotype-specific epitopes. *J. Gen. Virol.*, 72: 2275-2278.
- Prandini, F., M. Bublot, F.X. Le Gros, A. Dancer, L. Pizzoni and C. Lamichhane, 2008. Assessment of the immune response in broilers and pullets using two ELISA kits after in ovo or day-old vaccination with a vectored HVT IBD vaccine (VAXXITEK® HVT + IBD). www.zoonotica.international.com.
- Rautenschlein, S., C. Kaemer, E. Montiel, J. Vanmarck and C. Haase, 2007. Bilateral effect of vaccination against infectious bursal disease and Newcastle disease in specific Pathogenic free layers and commercial broiler chickens. *Avian. Dis.*, 51: 14-20.
- Riks, A., S. Venama, L. Hok, M. Jan and A.H. Huurnc, 2001. Efficacy of inactivated infectious bursal disease (IBD) vaccines: Comparison of serology with protection of progeny chickens against IBD virus strain of varying virulence. *Avian Pathol.*, 30: 345-354.
- Rong, J., T. Jiang, M. Shen, Y. Du, S. Li, S. Wang, B. Xu and G. Fan, 2007. Large-scale manufacture and use of recombinant VP2 vaccine against infectious bursal disease in chickens. *Vaccine*, 25: 7900-7908.
- Rojs, O.Z., U. Krapezi, B. Slavec and R. Jursic-Cizerl, 2011. Field efficacy of different vaccines against infectious bursal disease in broiler flocks. *Acta Veterinaria Hungarica*, 59: 385-398.
- Saif, Y.M., 1998. Infectious bursal disease and hemorrhagic enteritis. *Poult. Sci.*, 77: 1186-1189.
- Sharma, J.M., J.E. Dohms and A.L. Metz, 1989. Comparative pathogenesis of serotype 1 isolates of infectious bursal disease virus and their effect on humoral and cellular immune competence of specific-pathogen-free chickens. *Avian. Dis.*, 33: 112-124.

- Tsukamoto, K., N. Tsukannira, S.C. Kakita, K.M. Mase, K. Imai and H. Hihara, 1995. Efficacy of three live vaccines against highly virulent infectious bursal disease virus in chickens with or without maternal antibodies. *Avian. Dis.*, 39: 218-229.
- van den Berg, T., N. Eterradossi, D. Toquin and G. Meulemans, 2000. Infectious bursal disease (Gumboro disease). *Rev. Sci. Technol.*, 19:509-543.
- van den Berg, P., 2000. Acute infectious bursal disease in poultry: A review. *Avian. Pathol.*, 29: 175-194.
- van den Wijngaard, J.K. Avakian, C. Whitfill and E. Haddad, 2001. *In ovo* IBD vaccination surpass conventional approach. *World Poult. Elsev.*, pp: 16-17.
- Villegas, P., M. Hamoud, L.B. Purvis and F. Perozo, 2008. Infectious bursal disease subunit vaccination. *Avian. Dis.*, 52: 670-674.