

ISSN 1682-8356
ansinet.org/ijps



INTERNATIONAL JOURNAL OF
POULTRY SCIENCE

ANSI*net*

308 Lasani Town, Sargodha Road, Faisalabad - Pakistan
Mob: +92 300 3008585, Fax: +92 41 8815544
E-mail: editorijps@gmail.com

Morpho-Histological Study of the Thymus of Broiler Chickens During Post-Hatching Age

Khenenou Tarek¹, Melizi Mohamed¹, Bennoune Omar¹ and Benzaoui Hassina²
¹Laboratory of Animal Health, Animal Production and Environment (ESPA),
Department of Veterinary Medicine, University of Batna, Algeria
²EPH - Batna - Algeria

Abstract: The study of morphometric and histologic evolutions of the Thymus during 28 weeks of post-hatching age, realized on 86 subjects of broiler chicken they permitted to collect information about the morpho-histological aspect according to their post-hatching age; showed the size and the weight of the Thymus which reach their maximum at the 2nd week of age and the physiologic involution phenomena. These variations are in close relationship to the sexual maturity. These results can be used in the diagnosis of viral disease such as the Gumboro disease, Marek disease, Mycotoxicose.

Key words: Morphometry, histology, broiler chicken, post-hatching evolution, thymus

INTRODUCTION

The avian thymus lies parallel to the vagus nerve and internal jugular veins (Hodges, 1974). On each side of the neck there are 7-8 separate lobes, extending from the third cervical vertebra to the upper thoracic segments (Kendall, 1980). Each lobe is encapsulated with a fine fibrous connective tissue capsule and embedded into adipose tissue. From the capsule, septae invade the thymic parenchyma and incompletely divide the lobe into lobules. The button- or bean-shaped thymic lobes reach a maximum size of 6-12 mm in diameter by 3-4 months of age, before physiological involution begins (Ciriaco *et al.*, 2003).

MATERIALS AND METHODS

Chickens: The experimental study was carried out on 86 subjects of Broiler chickens. At each age a sample of 4 subjects was taken randomly among a band of 2000 subjects of only one poultry race, it is ISA 15 (chicken with fast growth). The animals are high on the ground, on litter heap of sheaves in a building into hard with windows non-ventilated and not air-conditioned. The chicks are high first day of the blossoming until the 23 weeks age under the same conditions of breeding, during the period from January to July 2008. The birds had no detectable developmental disorders and diseases that may cause any problem in the abnormalities of the histological architecture of lymphoid tissues.

Tissue processing for morphohistological study: The birds were killed by cervical dislocation method and the Thymus collected through ventral abdominal dissection, which is free from pathological lesions (Fig. 1).

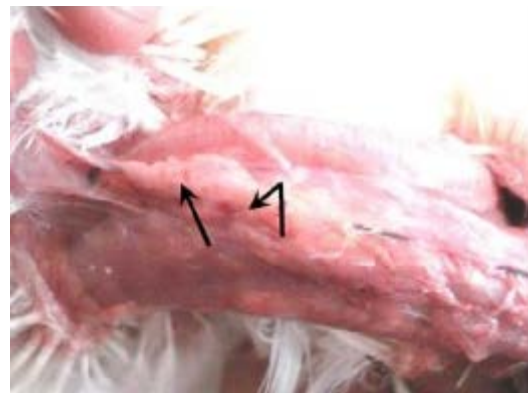

Fig. 1: The thymus (arrow) in its normal position

The thymus were carefully removed their average and relative. The Thymus obtained from chickens were fixed in Bouin's fluid (Gridley, 1960) for 24 hrs and were dehydrated in the series of ascending grade of alcohol followed by clearing in two changes in xylene and the tissues then infiltrated with different grades of melted paraffin in the oven. The tissues were then embedded in paraffin and finally the sections were cut at 5 μ thickness using sliding microtome (Microtom HM310, Waldorf, Germany). After cutting, the sections were floated on Luke-warm water in a 3 floatation bath at 38°C for stretching and then the sections were mounted on clean slides using egg albumin and dried on a slide warmer at 38°C (Luna, 1968; Darboux, 1994). The sections were stained using Mayer's Hematoxylin and Eosin (H & E). The histological structures of the Thymus were observed using light microscope under low (x10) and high (x40) magnification.

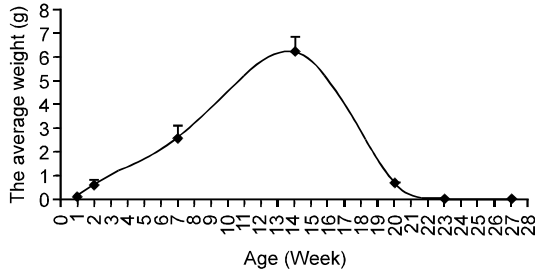


Fig. 2: Evolution of the average weight of the thymus with age

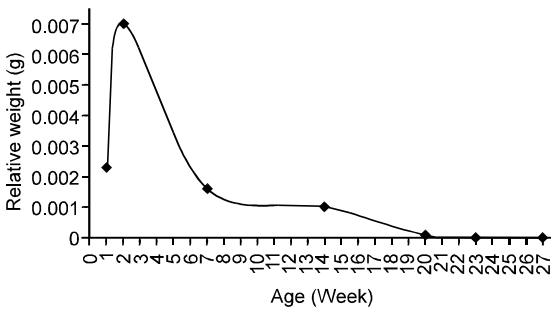


Fig. 3: Changes in the relative weight of the thymus with age

Photographs from the selected specimens were taken for better illustration of the results. Then the measurements of length and the width averages of the thymic lobules according to the age.

RESULTS AND DISCUSSION

The study of the evolution of the Thymus according to the age, during the postnatal life was realized on a sample of 86 subjects, cut down and dissected, from the first week to the 28th week.

Morpho-histological study of the thymus

Morphometric study: The Fig. 2 shows the results relating to the evolution of the average weight of the Thymus of broiler chicken. The average weight of this body passes from 0.09 g to reach an maximum average: 6.212±0.633 g at the 14th week of age and to reach 0.01 g and a total regression about the 23th week. Chatelain (1986) and Brugere-Picoux and Silim (1992) bring back similar result (regression between the 3rd and the 5th months).

The results of the relative weight growth of the Thymus expressed in Fig. 3 showed three different phases: the first is characterized by an accelerated growth; this phase begins from the first week of age and continues until the 2nd week of age where it reaches (0.007%).

The second phase finishes on the 7th week of age (0.0016%). From the 7th week we notice a fast

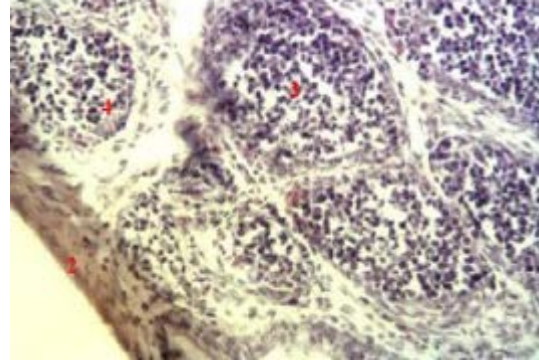


Fig. 4: From right to left are identified: the capsule, cortex and medulla (H&E x400)

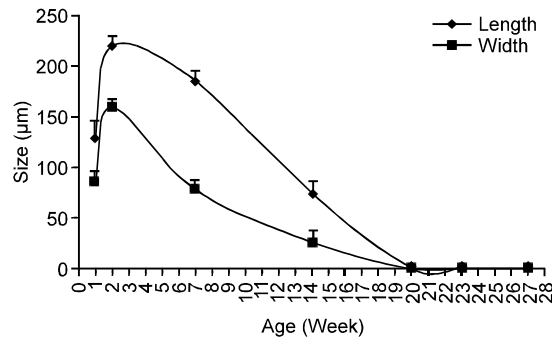


Fig. 5: The size of lobules (µm)

involution of the Thymus characterized by one reduction in the Thymus weight and a total regression about the 23th week. These results are close to the studies of Alamorgot (2005) and Guerin and Boissieu (2006).

Histological changes of the thymus according to the age: The morphometric and macroscopic changes of the Thymus were accompanied by histological modifications.

A phase of accelerated growth that begins the first week of birth is characterized by a clear appearance of the capsule, cortex and medulla, that shown in Fig. 4.

At second week The lobules continue their development and increase in size to reach the maximum; the length is 219±10.35 µm and the width is about 158.6±8.69 µm (Fig. 5); where The cortex and medulla are well demarcated (Fig. 6). While the fourteen week is marked by Regression of thymic lobules due to invasion of the parenchyma by adipose tissue (Fig. 7). At the 23rd week, a very significant interstitial adipose tissue and degeneration of the lobules was noticed. The results obtained on the broiler corroborating those of Alamorgot (2005), Guerin and Boissieu (2006) and Jolly (1993), Pastoret *et al.* (1990) who report that the thymus of the

chicken is well developed in young and atrophies at puberty between the 3rd and 10th months. The regression of the thymus is in relation to the increase in the rate of the sex hormones at the time of puberty.

Conclusion: The morphometric and histological study of the Thymus according to the age during the postnatal life showed that:

The size and the weight of the Thymus reach their maximum in the 2nd week. The development of the thymus is parallel to that of the bursa of Fabricius.

Thymus is in relation to the increase in the rate of the sex hormones at the time of puberty, where the organ is in gradually charge graisse. These variations are in close relationship to the sexual maturity.

REFERENCES

- Alamorgot, J., 2005. Manuel d'anatomie et d'autopsie aviaire. <http://www.Point-vet.fr>.
- Brugere-Picoux, J. and A. Silim, 1992. Manuel de pathologie aviaire. Edition France Agricole, France.
- Chatelain, E., 1986. Anatomie des volailles. Labo. d'anatomie. Ecole nationale vétérinaire de Lyon.
- Ciriaco, E., P.P. Pinera, B. Diaz-Esnal and R. Laura, 2003. Age-related changes in the avian primary lymphoid organs (thymus and bursa of Fabricius). *Microsc. Res. Technol.*, 62: 482-487.
- Darboux, R., 1994. Réalisation de coupe histologique pour le microscope optique. Faculté des sciences de la Santé de l'Université d'Abomey-Calavi Bénin.
- Gridley, M.F., 1960. Manual of Histologic and Special Staining Technique. McGraw-Hill Book Company, INC, New York, pp: 28-29, 82-83.
- Guerin, J. and C. Boissieu, 2006. L'autopsie en pathologie aviaire. *Elevage et santé animales et Cunicole*. <http://www.aviare@envt.fr>.
- Hodges, R.D., 1974. The circulatory system. In *The Histology of the Fowl*, pp: 151-241. Academic Press, London.
- Jolly, P., 1993. *Traité technique d'hématologie*. Maloine Edt. Paris.
- Kendall, M.D., 1980. Avian thymus glands: A review. *Dev. Comp. Immunol.*, 4: 191-210.
- Luna, L., 1968. Manuel of Histology, Staining methods of armed forces, Institute of pathology. 3rd Edn., McGraw-Hill Book, Co., New York, pp: 43.
- Pastoret, P., A. Gzoveart and H. Basin, 1990. *Immunologie animale*. Flammarion, pp: 740.