

ISSN 1682-8356
ansinet.org/ijps



INTERNATIONAL JOURNAL OF
POULTRY SCIENCE

ANSI*net*

308 Lasani Town, Sargodha Road, Faisalabad - Pakistan
Mob: +92 300 3008585, Fax: +92 41 8815544
E-mail: editorijps@gmail.com

Anatomical and Histological Changes of Reproductive Organs in Japanese Quail (*Coturnix japonica*) Embryos after *in ovo* Exposure to Genistein

Sittipon Intarapat¹, Achariya Sailasuta² and Orawan Satayalai³

¹Department of Anatomy, Faculty of Science, Mahidol University, Bangkok-10400, Thailand

²Department of Pathology, Faculty of Veterinary Science,
Chulalongkorn University, Bangkok-10330, Thailand

³Department of Biology, Faculty of Science, Chulalongkorn University, Bangkok-10330, Thailand

Abstract: Genistein, an isoflavonoid phytoestrogen, has a similar structure to endogenous estrogen and is also able to produce estrogen-like effects. Administration of exogenous estrogens as well as phytoestrogens causes reproductive abnormalities in adult birds. Here, we examine whether genistein affects reproductive organ development in Japanese quail at the sexually differentiated stage. Genistein (16 and 24 µg/g egg) was injected into the yolk via the blunt end of the fertilized egg prior to incubation. Both concentrations caused Müllerian duct abnormalities in both sexes and ovotestis formation in male embryos. This is the first report that genistein affects reproductive organ development in avian embryos.

Key words: Genistein, *in ovo*, quail embryos, reproductive organs, *Coturnix japonica*

INTRODUCTION

Phytoestrogens are estrogen-like substances produced by plants, especially from the family Leguminosae. Due to their chemical structures being similar to endogenous estrogen (estradiol), they have estrogen-like effects (Kanno *et al.*, 2002). Phytoestrogens are classified into three groups: isoflavones, coumestans and lignans (Turner and Sharpe, 1997; Setchell, 1998). Isoflavones are found at high concentrations in soybean and soy products (Adlercreutz, 1995). The isoflavones genistein and daidzein are considered to bind to the estrogen receptor (ER) with high affinity (Hanafy *et al.*, 2004; Hanafy *et al.*, 2005). Once they bind to ER they are able to act as either estrogen agonists or antagonists (Setchell, 1998; Lephart *et al.*, 2002).

The impacts of soy isoflavones on mammalian reproductive system and their estrogen-like effects were seriously concerned. It has been reported that female rats-treated with 50 µg/d of genistein at day 21 of gestation exhibited decreasing of ovaries and uterine weights as well as estrogen and progesterone levels in plasma (Awoniyi *et al.*, 1998). Casanova and colleagues have found that genistein and daidzein were estrogen agonists being able to bind with both ER alpha and beta that increased a ratio of uterine weight per body weight (Casanova *et al.*, 1999). Furthermore, female rats-treated with 40 mg/kg of genistein resulted in the increasing of uterine weight at day 22 of postnatal period (Lewis *et al.*, 2003). Moreover, prenatal rats-treated with genistein revealed sex differentiation and developmental failures (Lewis *et al.*, 2003). In female rats-treated with 250-1,250 ppm. of genistein exhibited the ductal-alveolar

hyperplasia, atretic follicles and ovarian antral follicles (Delclos *et al.*, 2001). In male rats-treated with genistein at concentration 1,250 ppm. delayed a spermatogenesis, whereas genistein at concentration 625 and 1,250 ppm. caused abnormal spermatozoa in epididymis (Delclos *et al.*, 2001). However, genistein at concentration 250 and 1,000 mg/kg affected neither testicular weight nor morphology (Fritz *et al.*, 2003). In mice, female-treated with 40 mg/kg body weight of genistein resulted in uterine enlargement, keratinization of vaginal epithelium and uterine squamous metaplasia (Cline *et al.*, 2004). Conversely, genistein at a concentration 40 mg/kg caused reduction of plasma testosterone concentrations, atrophy of seminiferous epithelium and accessory sex glands as well as squamous metaplasia of seminal vesicles (Cline *et al.*, 2004), whereas genistein at concentration 5 mg/kg reduced a number of spermatozoa (Lee *et al.*, 2004). There have been reported that genistein caused multi-oocyte follicle and polyovular follicles in female-mice treated with genistein at concentrations 50,000 µg/kg and 50 mg/kg, respectively (Jefferson and Newbold, 2000; Nagao *et al.*, 2001). Jefferson and colleagues have described that these phenomena caused by a binding of genistein with ER alpha, since these have not been observed in knocked out-ER beta gene mice (Jefferson *et al.*, 2002).

In the poultry industry, soybean is one of the most common sources of protein used for quails during the egg laying period (Woodard *et al.*, 1973). Isoflavones contained in soybean accumulate in products derived from poultry including eggs and meat (Lin *et al.*, 2004;

Jiang *et al.*, 2007). Moreover, the effects of phytoestrogens on avian reproduction have only been reported for adults in California quail (*Lophortyx californica*) (Leopold *et al.*, 1976), zebra finch (*Taeniopygia guttata*) (Millam *et al.*, 2002), chicken (*Gallus gallus domesticus*) (Opalka *et al.*, 2004; Wistedt *et al.*, 2012), duck (*Anas platyrhynchos*) (Zhao *et al.*, 2004; Zhao *et al.*, 2005), gander (*Anser anser domesticus*) (Opalka *et al.*, 2006; Kaminska *et al.*, 2008; Opalka *et al.*, 2008; Opalka *et al.*, 2012) and Japanese quail (*Coturnix japonica*) (de Man and Peeke, 1982; Akdemir and Sahin, 2009; Rochester *et al.*, 2009; Sahin *et al.*, 2009; Ekinci and Erkan, 2012) but not in embryos of any of these species.

Oviparous species use yolk as an energy supply for the embryo during development (Romanoff and Romanoff, 1949; Romanoff, 1960; Walker, 1967). A major component of the yolk is lipid. Endocrine disruptors (EDs) are mostly lipophilic substances dissolved in the yolk (Berg *et al.*, 1999). Several isoflavones are transferred and accumulated in the yolk such as equol (Saitoh *et al.*, 2004), daidzein (Saitoh *et al.*, 2001) and genistein (Saitoh *et al.*, 2001; Lin *et al.*, 2004; Jiang *et al.*, 2007). Therefore, avian embryos are the most likely to obtain phytoestrogens from isoflavone-enriched diet fed to the mother during the egg-laying period. Thus, it is possible that embryos become exposed to EDs accumulated in the yolk by maternal transfer via blood circulation.

Several routes of administration of EDs to avian embryos have been reported including egg dipping (Scheib and Reyss-Brion, 1979; Perrin *et al.*, 1995) and egg yolk (*in ovo*) injection (Brunstrom and Orberg, 1982; Berg *et al.*, 1998; Berg *et al.*, 1999; Biau *et al.*, 2007). The *in ovo* injection method is preferable for toxicity testing in oviparous species because it can deliver standardized doses (Walker, 1967) and it is also ecologically advantageous because it can minimize ED contamination of the environment (Berg *et al.*, 1998; Berg *et al.*, 1999).

Quail eggs have several advantages as the endocrine disrupting model: the eggs are small and easily exposed to substances (Berg *et al.*, 1998; Berg *et al.*, 1999; Halldin, 2005), they are available all year round (Berg *et al.*, 1999; Halldin, 2005) and their hypothalamic-pituitary-gonadal axis is well understood (Ottinger *et al.*, 2001; Ottinger *et al.*, 2002). Quails are therefore often recommended as a model for testing estrogen-like effects of EDs in birds (OECD, 1984; OECD, 2000; Touart, 2004).

Although genistein is widely used for studying estrogen-like effects and reproductive toxicity in mammalian reproductive system (Awoniyi *et al.*, 1998; Casanova *et al.*, 1999; Jefferson and Newbold, 2000; Delclos *et al.*, 2001; Nagao *et al.*, 2001; Jefferson *et al.*, 2002; Lewis *et al.*, 2003; Cline *et al.*, 2004; Lee *et al.*, 2004), little is

known about such effects on avian species. There have been found that genistein reduced a number of egg-laying periods in California quail (Leopold *et al.*, 1976) as well as inhibited testosterone secretion in roosters (Opalka *et al.*, 2004). Furthermore, genistein inhibited basal LH-stimulated testosterone production by Leydig cells and decreased the volume of ejaculates, the percentage of normal spermatozoa of Bilgoraj ganders (Opalka *et al.*, 2006; Opalka *et al.*, 2008). Mechanism of action of genistein inhibiting testosterone secretion in avian testicular cells was concluded that it interacted with key steroidogenic enzymes rather than estrogen receptors (Opalka *et al.*, 2012). In mammals, testosterone was also a target of estrogenic compounds since suppression of testosterone synthesis during a fetal life resulted in cryptorchidism and dysfunction of adult testis (Clark and Cochrum, 2007; Wohlfahrt-Veje *et al.*, 2009). There were strong evidences showed that genistein inhibited testosterone secretion by Leydig cells of mice fetal testes (Lehraiki *et al.*, 2011; Zhang *et al.*, 2013). Recently, it was reported that adult male quails received high doses of genistein exhibited testicular damage and apoptosis of germ cells (Ekinci and Erkan, 2012). Thus, the study of effects of genistein on embryonic testes in male quails needs to be investigated.

Even though there some studies have been undertaken of effects of genistein on adult quail reproduction (Akdemir and Sahin, 2009; Sahin *et al.*, 2009), its effects have not yet been in embryos. Previous studies used biological parameters to evaluate the endpoints of EDs on reproductive organs in avian embryos, including embryonic accessory duct (Willier *et al.*, 1935; Willier *et al.*, 1938; Romanoff, 1960; Stoll *et al.*, 1993; Berg *et al.*, 1998; Berg *et al.*, 1999; Berg *et al.*, 2001; Biau *et al.*, 2007) and the left testis (Willier *et al.*, 1935; Stoll *et al.*, 1993; Perrin *et al.*, 1995; Berg *et al.*, 1998; Berg *et al.*, 1999; Berg *et al.*, 2001; Oshima *et al.*, 2012). Since quail embryos exposed to EDs *in ovo* resulted in MDs retention in both sexes and ovotestis formation in male embryos (Perrin *et al.*, 1995; Berg *et al.*, 1998; Berg *et al.*, 1999; Berg *et al.*, 2001; Shibuya *et al.*, 2004; Shibuya *et al.*, 2005; Oshima *et al.*, 2012), MDs retention and ovotestis formation can be used as reliable biomarkers for evaluating estrogen-like effects of EDs (Berg *et al.*, 1998; Berg *et al.*, 1999).

Though genistein was reported that it acts as a tyrosine kinases inhibitor (Akiyama *et al.*, 1987; Huang *et al.*, 1992; Hong *et al.*, 2005), there were several studies demonstrated that genistein was an endocrine disruptor affecting the endocrine system of birds (Leopold *et al.*, 1976; Opalka *et al.*, 2004; Opalka *et al.*, 2006; Kaminska *et al.*, 2008; Opalka *et al.*, 2008; Opalka *et al.*, 2012). Interestingly, sex determination and differentiation of avian reproductive organs are predominantly controlled by sex hormones (Romanoff, 1960; Weniger, 1991;

Smith and Sinclair, 2001; Brunstrom *et al.*, 2003; Smith and Sinclair, 2004; Brunstrom *et al.*, 2009; Chue and Smith, 2011). Moreover, development of avian reproductive organs is estrogen dependent that estrogen-like compounds are able to disrupt such developmental process (Romanoff, 1960; Fry and Toone, 1981; Rattner *et al.*, 1984; Fry, 1995).

The present study aimed to examine the effects of genistein on reproductive organ development including embryonic accessory ducts in both sexes and the left testis in male quail embryos following *in ovo* exposure.

MATERIALS AND METHODS

Eggs and chemicals: Japanese quail (*Coturnix japonica*) eggs were obtained from the Department of Animal Science, Kasetsart University, Thailand. Genistein (4',5,7-Trihydroxyisoflavone; purity>98%) was purchased from Sigma chemical (St. Louis, Mo, USA). DMSO (dimethyl sulfoxide; purity>99%) was obtained from Merck (Darmstadt, Germany) and Mazola[®]corn oil was the product of CPC (AJI, Thailand).

Genistein preparation: A 10% DMSO was prepared by diluting DMSO in the distilled water and then mixed with corn oil for preparing the 10% DMSO/corn oil emulsion as a vehicle. To prepare genistein, genistein was dissolved in 10% DMSO as mentioned above. Due to genistein did not dissolve promptly in 10% DMSO, it was then mechanically dissolved by sonication (LR Ultrasonic sonicator, Fisher Scientific). Thereafter, a mixture of genistein/10% DMSO was then emulsified using vigorous vortexing with corn oil for preparing the genistein/10% DMSO/corn oil emulsion.

Dosing and *in ovo* exposure: Fertilized quail eggs were grouped into three treatments: the control, genistein-16 and genistein-24 µg/g-treated eggs. A mixture of 10% DMSO/corn oil was used as vehicle control, whereas 16 and 24 µg genistein administrated in 10% DMSO/corn oil emulsion were used as the genistein-treated groups. In the present study, genistein (16 and 24 µg/g egg) was selected for administration into the yolk (Brunstrom and Orberg, 1982), since genistein at concentration 7 µg/g egg showed no effect on quail reproductive organs (personal communication). Since 1.6 and 2.4 mg genistein were found in the yolk after feeding quail hens with 50 and 100 mg genistein, respectively (Lin *et al.*, 2004), an increase of genistein doses up to 10 fold was examined to observe adverse effects of genistein in this study.

Before starting *in ovo* exposure, quail eggs were cleaned with Betadine[®] solution (IDS manufacturing Ltd., Thailand). After cleaning, cleaned eggs were then weighed and labeled. The labeled eggs were punched with sterile disposable 25G needle (Nipro Corporation, Japan) at the blunt end of the egg. Before injection, a small hole was punched with a sterile disposable 25G

needle at the blunt end of the egg and the blunt end was wiped with 70% ethanol to get rid of small pieces of the eggshell. The eggs were then treated with two doses of genistein, 16 and 24 µg/g egg, by injecting into the yolk prior to incubation using Hamilton microliter syringe (Hamilton Company, USA). The amount of a mixture (20 µL/egg) was injected into the control and genistein-treated eggs. After *in ovo* exposure, the hole in the shell was sealed with paraffin wax and wiped with 70% ethanol. Injected eggs were then incubated at 37.5°C in a humid atmosphere and automatically turned by the incubator. Eggs were checked for embryonic mortality, fertility and unfertilized/or dead eggs were discarded. At day 15, a number of survival embryos were recorded and frequencies of embryo mortality, fertility and viability were analyzed. The fertilized eggs were used at minimum 30 eggs/treatment.

Anatomical and histological examinations: Quail embryos were sacrificed on day 15 of incubation (the sexually differentiated stage when embryonic sex can be distinguished by gonad morphology) and were staged according to Padgett and Ivey (Padgett and Ivey, 1960). Gross morphological abnormalities of the reproductive organs were observed under the SZ-PT stereomicroscope (Olympus, Japan). Biological parameters including accessory duct malformations in both sexes (e.g. partial or complete Müllerian duct retention in male embryos) and right Müllerian duct retention (longer than 3 mm compared to control group) with or without shell gland in female embryos were recorded.

For histological examination, the left testis was fixed in Bouin's fluid and embedded in Paraplast (Sherwood Medical Company, St. Louis, MO, USA.) and then sectioned at 6 µm with the microtome (The Gemmary, Fallbrook, USA). The sections were stained with Hematoxylin and Eosin. Ovotestis formation of the left testis was observed by a thickening of cortex layer containing five or more oocyte-like germ cells in meiotic prophase, showing eosinophilic cytoplasm in oocyte-like germ cells and transforming of germinal epithelial cells from squamous cells into cuboidal or columnar cells as described in previous studies (Berg *et al.*, 1998; Berg *et al.*, 1999; Berg *et al.*, 2001; Shibuya *et al.*, 2004; Shibuya *et al.*, 2005). The sections were visualized by PM-10M3 camera (Olympus, Japan)

Statistical analysis: Frequencies of embryo mortality, fertility, viability and reproductive organ abnormalities in both sexes in control and treated groups were compared using Fisher's exact test.

RESULTS

Mortality fertility and viability: Genistein (16 µg/g egg) caused high embryo mortality ($p<0.001$) (Table 1), whereas genistein at concentration 24 µg/g egg did not.

Table 1: Frequencies of mortality fertility and viability of quail embryos following *in ovo* injection

Treatment (µg/g egg)	Mortality (%) ^a	Fertility (%) ^b	Viability (%) ^c Sex (Female/Male)
Control ^d	19 (6/31)	97 (30/31)	80 (24/30) (Female = 13/Male = 11)
Genistein ^e (16)	54 (19/35)***	94 (33/35)	42 (14/33) (Female = 7/Male = 7)
Genistein ^e (24)	28 (8/35)	100 (35/35)	77 (27/35) (Female = 14/Male = 13)

^aRatio (in parentheses) represents the number of dead embryos divided by the number of treated eggs. Frequencies of the mortality, fertility and viability in the treatment groups were compared with the frequency in the control group using Fisher's exact test

^bNo. of fertile eggs divided by the number of total eggs

^cNo. of viable embryos divided by the number of fertile eggs

^dEggs-treated with DMSO/corn oil based emulsion

^eGenistein was dissolved with DMSO and emulsified with corn oil. Statistical difference in relation to the control group (***p<0.001)

Table 2: Frequencies of male and female 15-day-old quail embryos exhibiting abnormalities of MDs following genistein injection *in ovo* prior to incubation

Treatment (µg/g egg)	Female with MDs abnormalities (%) ^a	Male with MDs abnormalities (%) ^a
Control ^b	0 (0/13)	18 (2/11)
Genistein (16)	43 (3/7)*	71 (5/7)*
Genistein (24)	50 (7/14)**	54 (7/13)

^aRatio (in parentheses) represents the number of affected embryos divided by the number of embryos examined. Frequencies of the abnormality in the treatment groups were compared with the frequency in the control group using Fisher's exact test

^bQuail eggs treated with DMSO/corn oil based emulsion served as controls for the genistein-treated eggs Statistical differences in relation to the control group (*p<0.05; **p<0.01)

Table 3: Frequencies of male 15 day-old-quail embryos exhibiting ovotestis following genistein injection *in ovo* prior to incubation

Treatment (µg/g egg)	Male with ovotestis (%) ^{a,b}
Control	0 (0/11)
Genistein (16)	86 (6/7)***
Genistein (24)	85 (11/13)***

^aRatio (in parentheses) represents the number of affected embryos divided by the number of embryos examined. Frequencies of ovotestis in the treatment groups were compared with the frequency in the control group using Fisher's exact test

^bIdentifying characteristics of ovotestis formation according to the criteria including thickening of cortex layer containing oocyte-like germ cells in meiotic prophase, showing eosinophilic cytoplasm in oocyte-like germ cells, transformation of germinal epithelial cells from squamous cells into cuboidal and columnar cells. Statistical differences in relation to the control group (***p<0.001)

Frequencies of fertility of the control, 16 µg genistein and 24 µg genistein-treated eggs were 97, 94 and 100%, respectively (Table 1). Frequencies of embryo viability of the control, 16 µg genistein and 24 µg genistein-treated eggs were 80, 42 and 77%, respectively (Table 1).

Abnormality of embryonic accessory ducts: Normally, two days before anticipated hatching, female embryonic accessory ducts (Müllerian ducts, MDs) regress completely in male embryos, whereas the left MD still remains in female embryos. In quail embryos treated with 16 µg genistein/g egg, Müllerian duct (MD) abnormalities occurred in 3 of the 7 female embryos (p<0.05) and 5 of the 7 male embryos (p<0.05) (Table 2, Fig. 1). In contrast, MD abnormalities were observed in 7 of the 14 female embryos (p<0.01) and 7 of the 13 male embryos treated with 24 µg genistein/g egg (not significant compared with the control group; Table 2, Fig. 1). The frequencies of MD abnormalities in female and male embryos treated with 16 µg genistein/g egg were 43 and 71%, respectively (Table 2, Fig. 1), while the frequencies of MD abnormalities in female and male embryos treated with 24 µg genistein/g egg were 50 and 54%, respectively (Table 2, Fig. 1). MD

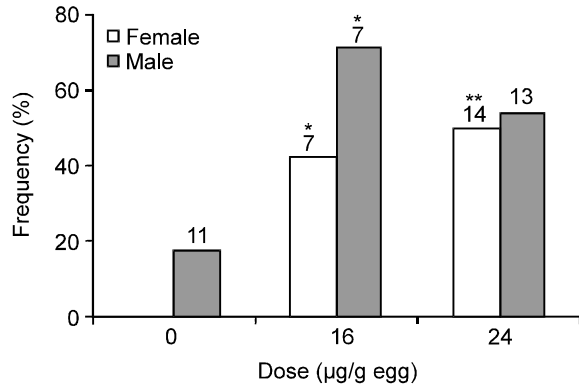


Fig. 1: Frequencies of female and male 15 day-old-quail embryos exhibiting abnormalities of MDs following genistein injection *in ovo* prior to incubation. A number of the examined embryos are indicated above the bars

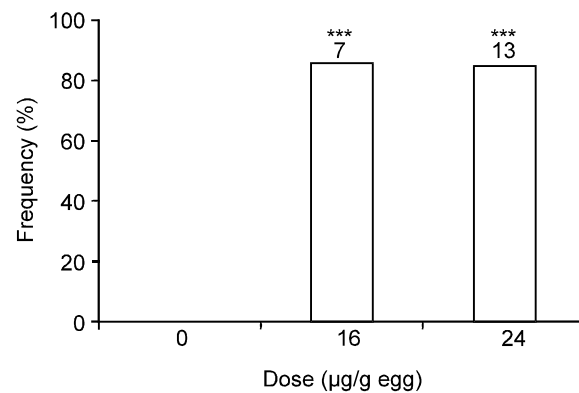


Fig. 2: Frequencies of male 15 days-old-quail embryos exhibiting ovotestis following genistein injection *in ovo* prior to incubation. A number of the examined embryos are indicated above the bars

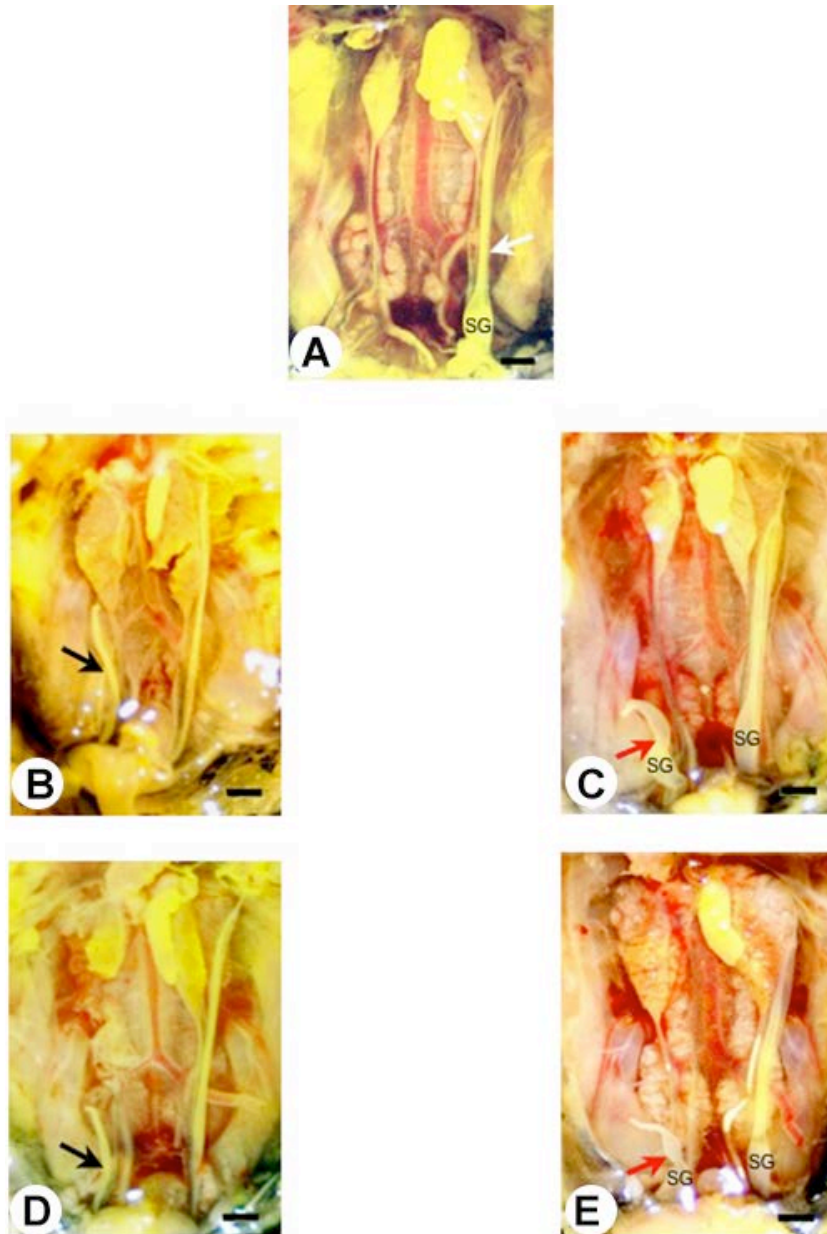


Fig. 3(A-E): Gross morphology of accessory ducts of 15 day-old-female quail embryos. (A) Müllerian Ducts, MDs (white arrows) of female embryo in the control group. (B,C) MDs abnormalities of female embryos treated with 16 μ g genistein/g egg. (D,E) MDs abnormalities of female embryos treated with 24 μ g genistein/g egg. Notice: right MDs retention without shell gland (SG) (black arrows) and right MDs retention with shell gland (red arrows). Bar = 2 mm

abnormalities including right MD retention (longer than 3 mm) with or without shell gland were observed in female embryos (Fig. 3). Likewise, left MD retention without shell gland and cyst-like portion of left and right MDs were observed in male embryos (Fig. 4).

Ovotestis formation in the left testis: Histological differences of embryonic gonads between female and

male embryos were observed. In female, left ovary exhibited a thick cortex, whereas male testes exhibited a thin cortex. In the present study, histological examination of 15 day-old-male embryonic testes in the control group showed the medulla containing dispersed testicular cords (T), (Fig. 5A) in which germ cells and Sertoli cells located within the cords. The thin cortex with smooth germinal epithelium consisting of one to two

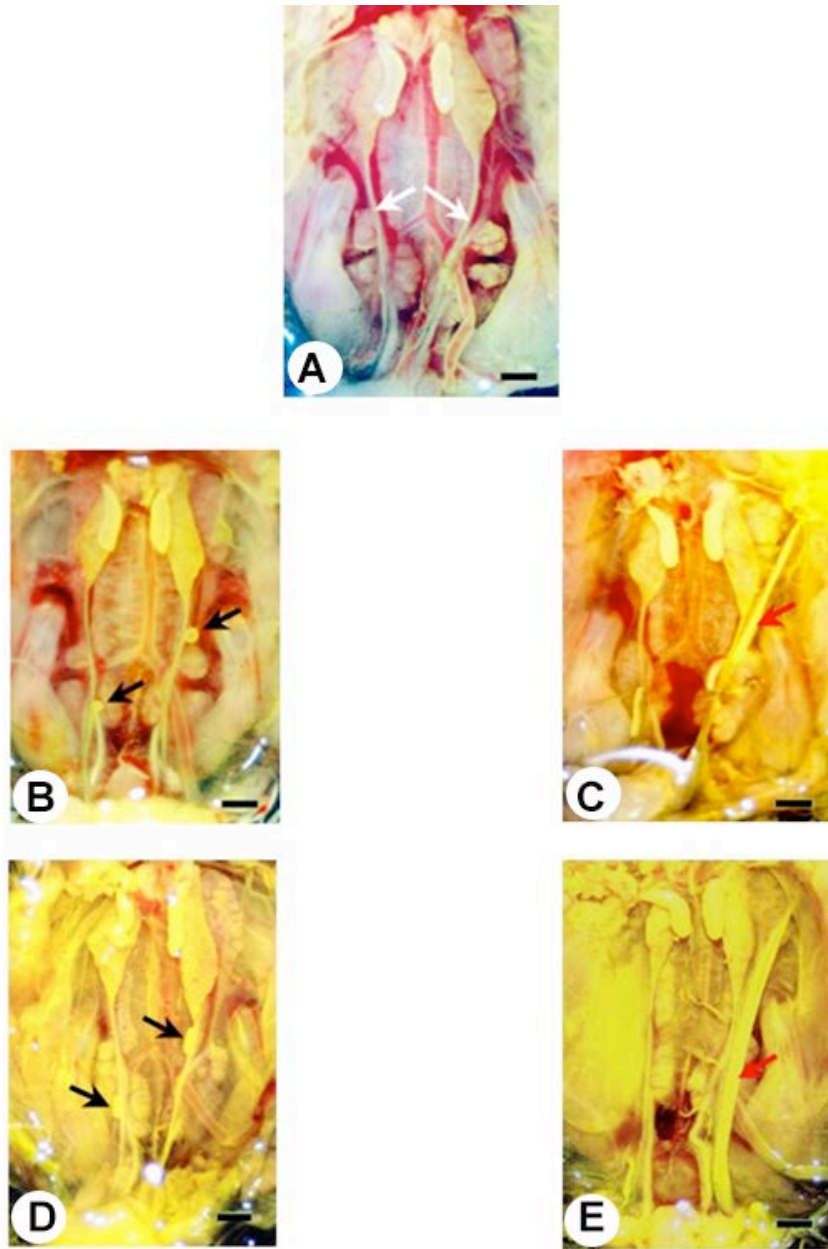


Fig. 4(A-E): Gross morphology of accessory ducts of 15 days-old-male quail embryos. (A) Wolffian Ducts, WDs (white arrow) of male embryo in the control group. (B,C) Accessory ducts abnormalities of male embryos treated with 16 μg genistein/g egg. (D,E) Accessory ducts abnormalities of male embryos treated with 24 μg genistein/g egg. Notice: cyst-like structure on WDs (black arrows) and left MDs retention (red arrows). Bar = 2 mm

layers of squamous epithelial cells covering the testicular cords was observed (Fig. 5B). The left ovary of 15 day-old-female embryos in the control group exhibited a thick cortex containing eight to ten layers of germinal epithelium (Fig. 5G) that lined by a cuboidal and/or columnar epithelium. Female germ cells (oocytes) locating in the cortex showed specific

characteristics such as a large nucleus with condensed chromatin and eosinophilic cytoplasm (Fig. 5H).

In quail embryos treated with 16 μg genistein/g egg, ovotestes were found in 6 of the 7 male embryos (86%; $p < 0.001$ with respect to controls) (Table 3, Fig. 2), while in genistein-treated embryos at concentration 24 $\mu\text{g}/\text{g}$ egg, ovotestes were observed in 11 of the 13 male

embryos (85%; $p < 0.001$ compared to controls) (Table 3, Fig. 2).

Ovotestis formation in embryos treated with both concentrations of genistein is characterized by the thickening of the cortex, containing oocyte-like germ cells in meiotic prophase (Fig. 5C,E), showing eosinophilic cytoplasm in oocyte-like germ cells (Fig. 5D,F) and transformation of germinal epithelial cells from squamous cells to cuboidal and/or columnar cells (Fig. 5E,F). The section of the left ovary in the control group (Fig. 5G,H) was compared.

DISCUSSION

In the present study, Japanese quail embryos were used as the endocrine disrupting model for testing estrogen-like effects of genistein on reproductive organ development. Both concentrations of genistein (16 and 24 $\mu\text{g/g}$ egg) used in this study caused abnormalities of reproductive organs including MD retention and ovotestis formation. Since both concentrations resulted in reproductive organ abnormalities in both sexes, it indicates the effective doses of genistein.

Quail embryos treated with genistein via injection into the yolk exhibited reproductive organ abnormalities, suggesting that genistein accumulating in the yolk can be transferred to the embryos. This also demonstrates that *in ovo* exposure of genistein via injection method is comparable to oral exposure since both routes elicit estrogen-like effects (Jefferson *et al.*, 2007). Due to several natural EDs are lipophilic substances, yolk sac injection is an environmentally relevant exposure of EDs to the embryos (Berg *et al.*, 1998; Berg *et al.*, 1999). In the present study, accumulated genistein in the yolk caused the abnormalities of quail reproductive organs, demonstrating that such accumulated genistein is high enough to cause adverse effects to both male and female embryos. Studies in mammals showed that phytoestrogens existing in the environment at high concentration caused adverse effects (Hearnshaw *et al.*, 1972; Setchell *et al.*, 1987). In mammals, nutritional doses of genistein given to the dam were passed to the pups during lactation in an amount sufficient to exert estrogen-like effects in suckling pups (Montani *et al.*, 2009). Moreover, transgenerational effects were observed in female offspring delivered from female dam-treated with 25 mg/kg genistein (Jefferson *et al.*, 2007). Thus, these findings demonstrate that genistein can be passed from maternal to fetal blood circulation and transmitted adverse effects to subsequent generation.

It has been reported that when female quails are fed with 50 and 100 mg of encapsulated genistein, 1.6 and 2.4 μg of the drug can be detected, respectively, in the yolk of the eggs laid by these hens (Lin *et al.*, 2004). In this study, doses of genistein were increased up to 10 fold (16 and 24 μg) compared with the previous study

(Lin *et al.*, 2004), to examine whether a higher dose of genistein affects reproductive organ development. Both doses used in this study have deleterious rather than advantageous effects. Thus, feeding hens with a diet enriched with a high content of soybean phytoestrogen during the egg-laying period might affect embryos. In addition, the study of advantages in having genistein in poultry industry or whether the lower 16 and 24 μg genistein/g egg do have advantageous effect, or whether it causes anomalies, needs to be investigated.

Sexual differentiation of quail embryos can be distinguished by morphological criteria of embryonic gonads and accessory ducts on day 8 of incubation. Here, the reproductive organs including embryonic accessory ducts and the left testis were used as biological parameters to observe the endpoint of estrogen-like effects of genistein. Several hormones and EDs caused accessory duct abnormalities (MD retention) and ovotestis formation in avian embryos, such as o,p'-DDT (Berg *et al.*, 1998), estriol (Biau *et al.*, 2007), estrone (Biau *et al.*, 2007), ethynylestradiol (Berg *et al.*, 1998; Berg *et al.*, 1999), diethylstilbestrol (Perrin *et al.*, 1995; Berg *et al.*, 1999), bisphenol A (Berg *et al.*, 2001; Oshima *et al.*, 2012), tetrabromobisphenol A (Berg *et al.*, 2001; Halldin *et al.*, 2001) and nonylphenol (Oshima *et al.*, 2012), suggesting the endpoints of estrogen-like effects of EDs on reproductive organ in avian embryos.

The present study is the first report on effective doses of genistein affecting reproductive organ development in quail. Both concentrations of genistein used in this study (16 and 24 $\mu\text{g/g}$ egg) caused the transformation of the left testis into ovotestis and the retention of MDs, suggesting that the abnormalities caused by genistein treatments gave the same effects. The minimum concentration of genistein that causes abnormalities needs further study. Quail embryos-treated with 16 and 24 μg genistein/g egg exhibited ovotestis formation in the left testis, suggesting that both concentrations of genistein used in this study can induce a feminization of male embryonic gonad. Ovotestis formation and MD retention in male embryos have also been found in chicken treated with EDs at different concentrations, such as 20 μg of o,p'-DDT/g egg (Fry and Toone, 1981), 2 mg of theelin (Willier *et al.*, 1935), 0.2 mg of theelol (Willier *et al.*, 1935), 1.2 mg of dehydroandrosterone (Willier *et al.*, 1938). It suggests that MD retention and ovotestis formation may primary targets of EDs as well as useful biological parameters for evaluating endpoints of EDs in avian embryos.

Genistein at 16 $\mu\text{g/g}$ egg caused mortality in quail embryos, whereas genistein at 24 $\mu\text{g/g}$ egg did not, suggesting that the specificity of a dose-response relationship of quail embryos exposed to genistein at 16 $\mu\text{g/g}$ egg. The relevant study has been demonstrated that the high mortality in quail embryos occurred after

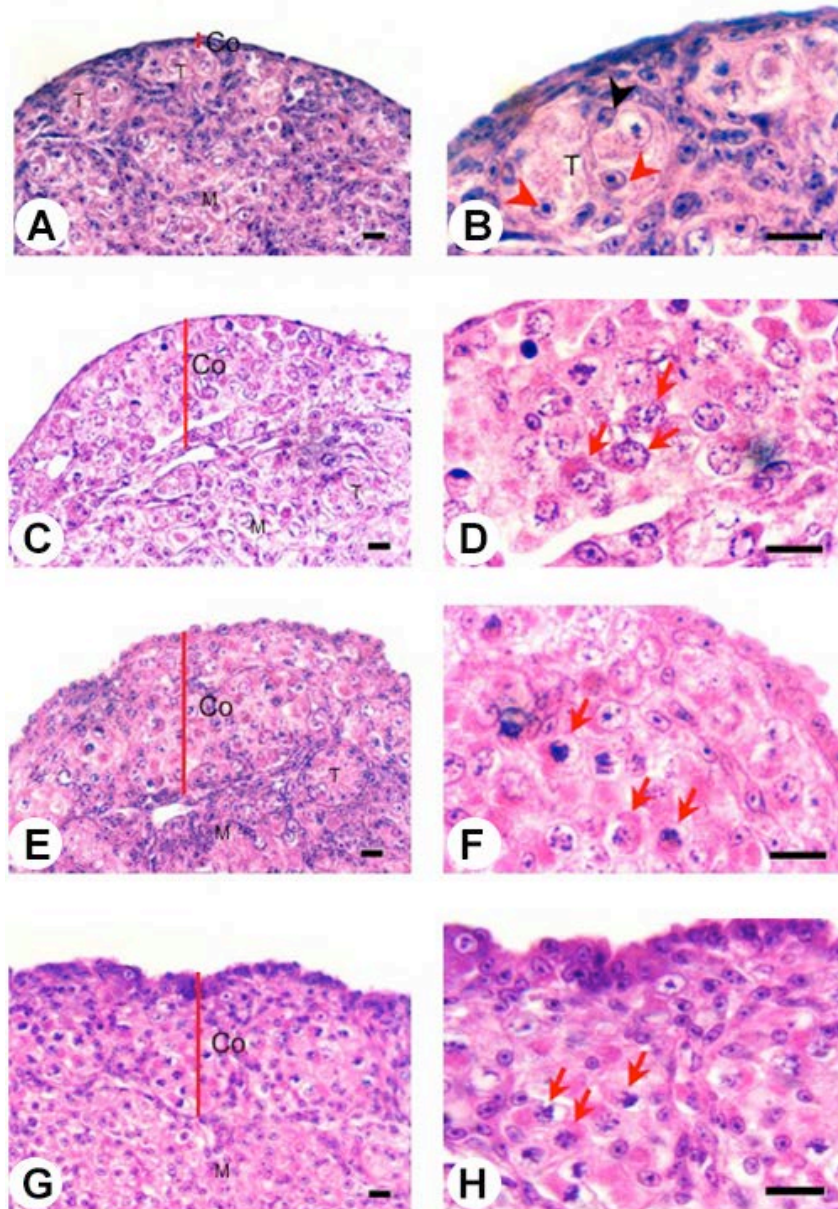


Fig. 5: Histology of the left testis of 15 day-old-quail embryos. (A,B) the left testis of male embryo in the control group. Notice: thin cortex (Co) and testicular cords (T) in the medulla (M), spermatogonia (red arrowhead) and Sertoli cells (black arrowhead) located within the cords. (C,D) Ovotestis of male embryos treated with 16 µg genistein/g egg. Notice: thick cortex (Co) containing oocyte-like germ cells in meiotic prophase (red arrows) is adjacent to testicular cords (T) in the medulla (M). (E,F) Characteristics of ovotestis were observed in male embryos treated with 24 µg genistein/g egg. (G,H) the section of left ovary of 15 days-old-female quail embryo was compared with that of ovotestes. H&E, Bar = 10 µm.

injecting the eggs with DES at 0.002 µg/g egg, while DES (0.2 µg/g egg) was not lethal to the embryos (Berg *et al.*, 2001). Although genistein at 16 µg/g egg caused high mortality, the mortality rate of quail embryos in the control and 24 µg genistein-treated eggs was relatively low. Moreover, frequencies of

embryo viability of the control and 24 µg genistein-treated eggs were 80% and 77%, respectively, which are considerably high. This demonstrates the acceptability of survival rate of the treated embryos. However, decreasing dose of genistein from 16 µg to observe the lowest observed adverse effect level (LOAEL) of

genistein on mortality rate of quail embryos requires further investigation.

In the present study, ovotestis formation was seen in the left testis of about 85% of quail embryos treated with genistein, suggesting that the left testis of quail embryos is sensitive to EDs. From histology of ovotestis, thickening of the cortex containing oocyte-like germ cells and transformation of epithelial cells were observed, suggesting that genistein alters cellular architectures of male embryonic gonads. Increase of cell proliferation in the cortex of embryonic testis is likely to be a result of the thick cortex. It has been reported that follicle stimulating hormone (FSH) is involved in the regulation of cell proliferation in chicken embryonic testis (Peralta *et al.*, 2009). Furthermore, molecular mechanism underlying testicular cell proliferation is regulated by tyrosine kinase (PTK) signaling. Since PTK inhibitor-herbimycin but not genistein increased 3H-thymidine proliferative cells (Peralta *et al.*, 2009), suggesting genistein did not act as a tyrosine kinase inhibitor for inducing testicular cell proliferation in chicken embryos. In this regard, genistein might act as an estrogen receptor modulator binding with ER in the fetal testicular tissue; since an activation of cell proliferation-correlated with luciferase activity increased two fold in fetal testis-exposed to genistein (Montani *et al.*, 2008; Montani *et al.*, 2009). In mammals, genistein altered testicular morphology as well as male germ cells in fetal mice and rat (Lehraiki *et al.*, 2011; Lehraiki *et al.*, 2011; Zhang *et al.*, 2013), demonstrating detrimental effects of genistein on male reproductive development. However, molecular mechanism in which genistein induces ovotestis formation in male embryos is still unknown.

The transformation of the left testis to ovotestis can be explained by changing of di-hormonal (estrogen and androgen) levels between estrogen and androgen in male gonads. Presumably, there was much higher level of estrogen than androgen during gonadal differentiation stage, since at this stage, a higher level of estrogen is synthesized than androgens in the ovaries of female embryos and vice versa according to the di-hormonal theory (Willier, 1952). In addition, the appropriate level of androgen could induce medullary development of the testes, but it also suppresses cortical development in male testes and vice versa (Willier *et al.*, 1935; Willier *et al.*, 1937; Willier, 1952). This is a likely explanation of ovotestis formation in male embryos whereby genistein acts as an estrogen agonist, elevating the level of estrogen in the left testis. Therefore, the level of genistein may be enough to promote cortical development in the left testis leading to a thickening of the cortex of the left testis. It has been found that the level of estrogen was much higher than that of androgen in quail embryos-treated with DES *in ovo* (Scheib and Reyss-Brion, 1979). Further study is required to determine whether estrogen levels are higher than

androgen levels in ovotestis of male quail embryos treated with genistein. These findings suggest that sex modification in male embryos (i.e., feminization or demasculinization) is the most likely to be a result of endocrine-disrupting effects.

Besides ovotestis formation, another the endocrine disrupting endpoint of genistein used in this study is MD abnormality. Abnormality of embryonic accessory ducts occurred in embryos treated with 16 and 24 µg genistein/g egg, including MD retention in male embryos and MD retentions with or without shell gland formation in female embryos. In mammalian counterparts, neonatal mice-treated with 50 mg genistein/kg/day caused abnormal oviduct morphogenesis (Jefferson *et al.*, 2011; Jefferson *et al.*, 2012). These findings demonstrate that embryonic oviduct (MD) is a target of genistein being able to exert adverse effects on both non-mammalian and mammalian species. In this study, we found that both concentrations of genistein resulted in left MD retention and cyst-like structure formation of WDs in male embryos. This alteration indicates that genistein somehow disrupts accessory duct development by binding to estrogen receptor in the ducts, leading to abnormalities of male embryonic accessory ducts. In a previous study, chick embryos-treated with 0.2 mg of theelin *in ovo* on day 2 of incubation, displayed abnormalities of embryonic accessory ducts (Willier *et al.*, 1935). Moreover, male quail embryo-treated with 2 ng DES/g egg *in ovo* on day 3 of incubation exhibited MD persistence with vestigial vesicles located on one or both sides of the ducts in the abdomen (Berg *et al.*, 1999). This indicates that apart from embryonic gonads, the accessory ducts of avian embryos are the targets of EDs. The mechanism of action of EDs leading to abnormalities of accessory ducts development requires further investigation.

Since quail embryos treated with bisphenol A (BPA) at 200 µg/g egg resulted in MD retention in both sexes and ovotestis formation in the left testis of male embryos (Berg *et al.*, 2001), there was the similarity between genistein and BPA in terms of their effects on reproductive organs in quail embryos. There have been previous reports on binding potency of xenoestrogen and phytoestrogen on quail estrogen receptor, suggesting that genistein had stronger binding than BPA to ER-alpha and beta (Hanafy *et al.*, 2004; Hanafy *et al.*, 2005). This suggests that xenoestrogen-DES and phytoestrogen-genistein are capable of binding to estrogen receptors. Increasing of concentration of genistein from 1.6 and 2.4 µg in the previous study (Lin *et al.*, 2004) to 16 and 24 µg/g egg in this study reflects obtaining of high content of phytoestrogen containing in quail's diet. This study showed that quail eggs injected with 16 and 24 µg genistein/g egg developed reproductive organ abnormalities in the embryos. Thus there is a risk to embryos if hens are fed with a diet

enriched with high content of phytoestrogen. Since genistein was detected in the yolk (Lin *et al.*, 2004), the embryos of oviparous species such as Japanese quail (Lin *et al.*, 2004) and chicken (Saitoh *et al.*, 2001; Saitoh *et al.*, 2004) are likely to be susceptible to exposure to EDs accumulated in the yolk. The effects of accumulated genistein in the yolk on the hatching and infertility of adult quails need further investigation.

Conclusion: In the present study, embryonic accessory ducts and the left testis were used as biological parameters to evaluate estrogen-like effects of genistein on reproductive organ development in Japanese quail embryos. Genistein at 16 and 24 µg/g egg resulted in abnormalities of accessory ducts in both sexes and ovotestis formation in male embryos. We conclude that accessory duct abnormalities and ovotestis formation are endpoints of endocrine disrupting effects of genistein. This is the first report on the effective doses of genistein that caused reproductive organs abnormalities in avian embryos.

ACKNOWLEDGEMENTS

We thank Dr. Claudio D. Stern for critical reading and comments on a manuscript. We also thank Artchariya Chaiyarat for technical assistance. This work was supported by The Centre of Excellence of Biodiversity, Department of Biology, Faculty of Science, Chulalongkorn University for grant number CEB_M_20_2005.

REFERENCES

Adlercreutz, H., 1995. Phytoestrogens: Epidemiology and a possible role in cancer protection. *Environ. Health. Perspect.*, 7: 103-112.

Akdemir, F. and K. Sahin, 2009. Genistein supplementation to the quail: Effects on egg production and egg yolk genistein, daidzein and lipid peroxidation levels. *Poult. Sci.*, 88: 2125-2131.

Akiyama, T., J. Ishida, S. Nakagawa, H. Ogawara, S. Watanabe, N. Itoh, M. Shibuya and Y. Fukami, 1987. Genistein, a specific inhibitor of tyrosine-specific protein kinases. *J. Biol. Chem.*, 262: 5592-5595.

Awoniyi, C.A., D. Roberts, D.N. Veeramachaneni, B.S. Hurst, K.E. Tucker and W.D. Schlaff, 1998. Reproductive sequelae in female rats after in utero and neonatal exposure to the phytoestrogen genistein. *Fertil. Steril.*, 70: 440-447.

Berg, C., K. Halldin and B. Brunstrom, 2001. Effects of bisphenol a and tetrabromobisphenol a on sex organ development in quail and chicken embryos. *Environ. Toxicol. Chem.*, 20: 2836-2840.

Berg, C., K. Halldin, B. Brunstrom and I. Brandt, 1998. Methods for studying xenoestrogenic effects in birds. *Toxicol. Lett.*, 102-103: 671-676.

Berg, C., K. Halldin, A.K. Fridolfsson, I. Brandt and B. Brunstrom, 1999. The avian egg as a test system for endocrine disruptors: Effects of diethylstilbestrol and ethynylestradiol on sex organ development. *Sci. Total. Environ.*, 233: 57-66.

Biau, S., S. Bayle, P. de Santa Barbara and B. Roig, 2007. The chick embryo: An animal model for detection of the effects of hormonal compounds. *Anal. Bioanal. Chem.*, 387: 1397-1403.

Brunstrom, B., J. Axelsson and K. Halldin, 2003. Effects of endocrine modulators on sex differentiation in birds. *Ecotoxicol.*, 12: 287-295.

Brunstrom, B., J. Axelsson, A. Mattsson and K. Halldin, 2009. Effects of estrogens on sex differentiation in Japanese quail and chicken. *Gen. Comp. Endocrinol.*, 163: 97-103.

Brunstrom, B. and J. Orberg, 1982. A method for studying embryo-toxicity of lipophilic substances experimentally introduced into hens' eggs. *Ambio*, 11: 209-211.

Casanova, M., L. You, K.W. Gaido, S. Archibeque-Engle, D.B. Janszen and H.A. Heck, 1999. Developmental effects of dietary phytoestrogens in sprague-dawley rats and interactions of genistein and daidzein with rat estrogen receptors alpha and beta *in vitro*. *Toxicol. Sci.*, 51: 236-244.

Chue, J. and C.A. Smith, 2011. Sex determination and sexual differentiation in the avian model. *FEBS J.*, 278: 1027-1034.

Clark, B.J. and R.K. Cochrum, 2007. The steroidogenic acute regulatory protein as a target of endocrine disruption in male reproduction. *Drug. Metab. Rev.*, 39: 353-370.

Cline, J.M., A.A. Franke, T.C. Register, D.L. Golden and M.R. Adams, 2004. Effects of dietary isoflavone aglycones on the reproductive tract of male and female mice. *Toxicol. Pathol.*, 32: 91-99.

de Man, E. and H.V. Peeke, 1982. Dietary ferulic acid, biochanin a and the inhibition of reproductive behavior in Japanese quail (*Coturnix coturnix*). *Pharmacol. Biochem. Behav.*, 17: 405-411.

Delclos, K.B., T.J. Bucci, L.G. Lomax, J.R. Latendresse, A. Warbritton, C.C. Weis and R.R. Newbold, 2001. Effects of dietary genistein exposure during development on male and female cd (sprague-dawley) rats. *Reprod. Toxicol.*, 15: 647-663.

Ekinci, S. and M. Erkan, 2012. Short term effects of genistein on the testes of quail (*Coturnix coturnix*). *Turk. J. Vet. Anim. Sci.*, 36: 251-257.

Fritz, W.A., M.S. Cotroneo, J. Wang, I.E. Eltoum and C.A. Lamartiniere, 2003. Dietary diethylstilbestrol but not genistein adversely affects rat testicular development. *J. Nutr.*, 133: 2287-2293.

Fry, D.M., 1995. Reproductive effects in birds exposed to pesticides and industrial chemicals. *Environ. Health. Perspect.*, 7: 165-171.

- Fry, D.M. and C.K. Toone, 1981. DDT-induced feminization of gull embryos. *Sci.*, 213: 922-924.
- Halldin, K., 2005. Impact of endocrine disrupting chemicals on reproduction in japanese quail. *Domest. Anim. Endocrinol.*, 29: 420-429.
- Halldin, K., C. Berg, A. Bergman, I. Brandt and B. Brunstrom, 2001. Distribution of bisphenol a and tetrabromobisphenol a in quail eggs, embryos and laying birds and studies on reproduction variables in adults following in ovo exposure. *Arch. Toxicol.*, 75: 597-603.
- Hanafy, A.M., T. Sasanami, K. Ichikawa, K. Shimada and M. Mori, 2004. Estrogen receptor binding of xenoestrogens and phytoestrogens in japanese quail (*Coturnix japonica*). *J. Poult. Sci.*, 41: 30-37.
- Hanafy, A.M., T. Sasanami and M. Mori, 2005. Binding of xenoestrogens and phytoestrogens to estrogen receptor beta of japanese quail (*Coturnix japonica*). *J. Poult. Sci.*, 42: 238-244.
- Hearnshaw, H., J.M. Brown, I.A. Cumming, J.R. Goding and M. Nairn, 1972. Endocrinological and histopathological aspects of the infertility in the ewe caused by oestrogenic clover. *J. Reprod. Fertil.*, 28: 160-161.
- Hong, M., M.Y. Lin, J.M. Huang, P. Baumeister, S. Hakre, A.L. Roy and A.S. Lee, 2005. Transcriptional regulation of the grp78 promoter by endoplasmic reticulum stress: Role of TFII-I and its tyrosine phosphorylation. *J. Biol. Chem.*, 280: 16821-16828.
- Huang, J., M. Nasr, Y. Kim and H.R. Matthews, 1992. Genistein inhibits protein histidine kinase. *J. Biol. Chem.*, 267: 15511-15515.
- Jefferson, W.N., J.F. Couse, E. Padilla-Banks, K.S. Korach and R.R. Newbold, 2002. Neonatal exposure to genistein induces estrogen receptor (ER) alpha expression and multioocyte follicles in the maturing mouse ovary: Evidence for estrogen-mediated and nonestrogenic actions. *Biol. Reprod.*, 67: 1285-1296.
- Jefferson, W.N. and R.R. Newbold, 2000. Potential endocrine-modulating effects of various phytoestrogens in the diet. *Nutr.*, 16: 658-662.
- Jefferson, W.N., E. Padilla-Banks and R.R. Newbold, 2007. Disruption of the developing female reproductive system by phytoestrogens: Genistein as an example. *Mol. Nutr. Food. Res.*, 51: 832-844.
- Jefferson, W.N., E. Padilla-Banks, J.Y. Phelps, K.E. Gerrish and C.J. Williams, 2011. Permanent oviduct posteriorization after neonatal exposure to the phytoestrogen genistein. *Environ. Health. Perspect.*, 119: 1575-1582.
- Jefferson, W.N., H.B. Patisaul and C.J. Williams, 2012. Reproductive consequences of developmental phytoestrogen exposure. *Reproduction*, 143: 247-260.
- Jiang, Z.Y., S.Q. Jiang, Y.C. Lin, P.B. Xi, D.Q. Yu and T.X. Wu, 2007. Effects of soybean isoflavone on growth performance, meat quality and antioxidation in male broilers. *Poult. Sci.*, 86: 1356-1362.
- Kaminska, B., M. Opalka and L. Dusza, 2008. The effects of acth, phytoestrogens and estrogens on corticosterone secretion by gander adrenocortical cells in breeding and nonbreeding seasons. *Acta. Biol. Hung.*, 59: 173-184.
- Kanno, J., H. Kato, T. Iwata and T. Inoue, 2002. Phytoestrogen-low diet for endocrine disruptor studies. *J. Agri. Food. Chem.*, 50: 3883-3885.
- Lee, B.J., E.Y. Jung, Y.W. Yun, J.K. Kang, I.J. Baek, J.M. Yon, Y.B. Lee, H.S. Sohn, J.Y. Lee, K.S. Kim and S.Y. Nam, 2004. Effects of exposure to genistein during pubertal development on the reproductive system of male mice. *J. Reprod. Dev.*, 50: 399-409.
- Lehraiki, A., C. Chamaillard, A. Krust, R. Habert and C. Levacher, 2011. Genistein impairs early testosterone production in fetal mouse testis via estrogen receptor alpha. *Toxicol. In vitro*, 25: 1542-1547.
- Lehraiki, A., S. Messiaen, R. Berges, M.C. Canivenc-Lavier, J. Auger, R. Habert and C. Levacher, 2011. Antagonistic effects of gestational dietary exposure to low-dose vinclozolin and genistein on rat fetal germ cell development. *Reprod. Toxicol.*, 31: 424-430.
- Leopold, A.S., M. Erwin, J. Oh and B. Browning, 1976. Phytoestrogens: Adverse effects on reproduction in california quail. *Sci.*, 191: 98-100.
- Lephart, E.D., T.W. West, K.S. Weber, R.W. Rhee, K.D. Setchell, H. Adlercreutz and T.D. Lund, 2002. Neurobehavioral effects of dietary soy phytoestrogens. *Neurotoxicol. Teratol.*, 24: 5-16.
- Lewis, R.W., N. Brooks, G.M. Milburn, A. Soames, S. Stone, M. Hall and J. Ashby, 2003. The effects of the phytoestrogen genistein on the postnatal development of the rat. *Toxicol. Sci.*, 71: 74-83.
- Lin, F., J. Wu, M.A. Abdelnabi, M.A. Ottinger and M.M. Giusti, 2004. Effects of dose and glycosylation on the transfer of genistein into the eggs of the japanese quail (*Coturnix japonica*). *J. Agri. Food. Chem.*, 52: 2397-2403.
- Millam, J.R., C.B. Craig-Veit, M.E. Batchelder, M.R. Viant, T.M. Herbeck and L.W. Woods, 2002. An avian bioassay for environmental estrogens: The growth response of zebra finch (*Taeniopygia guttata*) chick oviduct to oral estrogens. *Environ. Toxicol. Chem.*, 21: 2663-2668.
- Montani, C., M. Penza, M. Jeremic, G. Biasiotto, G. La Sala, M. De Felici, P. Ciana, A. Maggi and D. Di Lorenzo, 2008. Genistein is an efficient estrogen in the whole-body throughout mouse development. *Toxicol. Sci.*, 103: 57-67.

- Montani, C., M. Penza, M. Jeremic, G. Rando, P. Ciana, A. Maggi, G. La Sala, M. De Felici and D. Di Lorenzo, 2009. Estrogen receptor-mediated transcriptional activity of genistein in the mouse testis. *Ann. N. Y. Acad. Sci.*, 1163: 475-477.
- Nagao, T., S. Yoshimura, Y. Saito, M. Nakagomi, K. Usumi and H. Ono, 2001. Reproductive effects in male and female rats of neonatal exposure to genistein. *Reprod. Toxicol.*, 15: 399-411.
- OECD, 1984. Organization for economy and development. Avian reproduction test (test guideline 206). Paris, France.
- OECD, 2000. Organization for economy and development. Avian reproduction toxicity test in the japanese quail or northern bobwhite (proposal for a new test guideline). Paris, France.
- Opalka, D.M., B. Kaminska, M.K. Piskula, H. Puchajda-Skowronska and L. Dusza, 2006. Effects of phytoestrogens on testosterone secretion by leydig cells from bilgoraj ganders (*Anser anser*). *Br. Poult. Sci.*, 47: 237-245.
- Opalka, M., B. Kaminska, R. Ciereszko and L. Dusza, 2004. Genistein affects testosterone secretion by leydig cells in roosters (*Gallus gallus domesticus*). *Reprod. Biol.*, 4: 185-193.
- Opalka, M., B. Kaminska, A. Leska and L. Dusza, 2012. Mechanism of phytoestrogen action in leydig cells of ganders (*Anser anser domesticus*): Interaction with estrogen receptors and steroidogenic enzymes. *J. Environ. Sci. Health. A. Tox. Hazard. Subst. Environ. Eng.*, 47: 1335-1339.
- Opalka, M., J. Kugla-Owczarska, B. Kaminska, H. Puchajda-Skowronska, W. Hryniewicka and L. Dusza, 2008. Effects of dietary meals containing different levels of phytoestrogens on reproductive function in bilgoraj ganders. *Acta. Vet. Hung.*, 56: 379-391.
- Oshima, A., R. Yamashita, K. Nakamura, M. Wada and K. Shibuya, 2012. In ovo exposure to nonylphenol and bisphenol a resulted in dose-independent feminization of male gonads in japanese quail (*Coturnix japonica*) embryos. *Environ. Toxicol. Chem.*, 31: 1091-1097.
- Ottinger, M.A., M. Abdelnabi, M. Quinn, N. Golden, J. Wu and N. Thompson, 2002. Reproductive consequences of edcs in birds: What do laboratory effects mean in field species? *Neurotoxicol. Teratol.*, 24: 17-28.
- Ottinger, M.A., M.A. Abdelnabi, P. Henry, S. McGary, N. Thompson and J.M. Wu, 2001. Neuroendocrine and behavioral implications of endocrine disrupting chemicals in quail. *Horm. Behav.*, 40: 234-247.
- Padgett, C.S. and W.D. Ivey, 1960. The normal embryology of the coturnix quail. *Anat. Rec.*, 137: 1-11.
- Peralta, I., M.C. Romano and P.N. Velazquez, 2009. Signaling pathways involved in the effect of follicle-stimulating hormone on chick embryo testis cell proliferation. *Poult. Sci.*, 88: 380-386.
- Perrin, F.M., S. Stacey, A.M. Burgess and U. Mittwoch, 1995. A quantitative investigation of gonadal feminization by diethylstilboestrol of genetically male embryos of the quail coturnix coturnix japonica. *J. Reprod. Fertil.*, 103: 223-226.
- Rattner, B.A., V.P. Eroschenko, G.A. Fox, D.M. Fry and J. Gorsline, 1984. Avian endocrine responses to environmental pollutants. *J. Exp. Zool.*, 232: 683-689.
- Rochester, J.R., K.C. Klasing, L. Stevenson, M.S. Denison, W. Berry and J.R. Millam, 2009. Dietary red clover (*Trifolium pratense*) induces oviduct growth and decreases ovary and testes growth in japanese quail chicks. *Reprod. Toxicol.*, 27: 63-71.
- Romanoff, A.L., 1960. The avian embryo. The Macmillan Co., New York.
- Romanoff, A.L. and A.J. Romanoff, 1949. The avian egg. Wiley, New York.
- Sahin, K., F. Akdemir, M. Tuzcu, N. Sahin, M. Onderci, R. Ozercan, N. Ilhan, E. Kilic, S. Seren and O. Kucuk, 2009. Genistein suppresses spontaneous oviduct tumorigenesis in quail. *Cancer. Nutr.*, 61: 799-806.
- Saitoh, S., T. Sato, H. Harada and T. Matsuda, 2004. Biotransformation of soy isoflavone-glycosides in laying hens: Intestinal absorption and preferential accumulation into egg yolk of equol, a more estrogenic metabolite of daidzein. *Biochim. Biophys. Acta.*, 1674: 122-130.
- Saitoh, S., T. Sato, H. Harada and T. Takita, 2001. Transfer of soy isoflavone into the egg yolk of chickens. *Biosci. Biotechnol. Biochem.*, 65: 2220-2225.
- Scheib, D. and M. Reyss-Brion, 1979. Feminization of the quail by early diethylstilbestrol treatment: Histoenzymological investigations on steroid dehydrogenases in the gonads. *Arch. Anat. Microsc. Morphol. Exp.*, 68: 85-98.
- Setchell, K.D., 1998. Phytoestrogens: The biochemistry, physiology and implications for human health of soy isoflavones. *Am. J. Clin. Nutr.*, 68: 1333-1346.
- Setchell, K.D., S.J. Gosselin, M.B. Welsh, J.O. Johnston, W.F. Balistreri, L.W. Kramer, B.L. Dresser and M.J. Tarr, 1987. Dietary estrogens-a probable cause of infertility and liver disease in captive cheetahs. *Gastroenterol.*, 93: 225-233.
- Shibuya, K., M. Mizutani, K. Sato, M. Itabashi and T. Nunoya, 2005. Comparative evaluation of sex reversal effects of natural and synthetic estrogens in sex reversal test using F1 (AWE x WE) japanese quail embryos. *J. Poult. Sci.*, 42: 119-129.

- Shibuya, K., M. Mizutani, M. Wada, K. Sato and T. Nunoya, 2004. A new screening model using F1 (AWE x WE) japanese quail embryo for evaluating sex reversal effects. *J. Toxicol. Pathol.*, 17: 245-252.
- Smith, C.A. and A.H. Sinclair, 2001. Sex determination in the chicken embryo. *J. Exp. Zool.*, 290: 691-699.
- Smith, C.A. and A.H. Sinclair, 2004. Sex determination: Insights from the chicken. *Bioessays*, 26: 120-132.
- Stoll, R., F. Ichas, N. Faucounau and R. Maraud, 1993. Action of estradiol and tamoxifen on the mullero-regressive activity of the chick embryonic testis assayed in vivo by organotypic grafting. *Anat. Embryol.*, 187: 379-384.
- Stoll, R., F. Ichas, N. Faucounau and R. Maraud, 1993. Action of estradiol and tamoxifen on the testis-inducing activity of the chick embryonic testis grafted to the female embryo. *Anat. Embryol.*, 188: 587-592.
- Touart, L.W., 2004. Factors considered in using birds for evaluating endocrine-disrupting chemicals. *ILAR J.*, 45: 462-468.
- Turner, K.J. and R.M. Sharpe, 1997. Environmental oestrogens-present understanding. *Rev. Reprod.*, 2: 69-73.
- Walker, N.E., 1967. Distribution of chemicals injected into fertile eggs and its effect upon apparent toxicity. *Toxicol. Appl. Pharmacol.*, 10: 290-299.
- Walker, N.E., 1967. Growth and development of chick embryos nourished by fractions of yolk. *J. Nutr.*, 92: 111-117.
- Weniger, J.P., 1991. Embryonic sex hormones in birds. *Int. J. Dev. Biol.*, 35: 1-7.
- Willier, B.H., 1952. Development of sex-hormone activity of the avian gonad. *Ann. N.Y. Acad. Sci.*, 55: 159-171.
- Willier, B.H., T.F. Gallagher and F.C. Koch, 1935. Sex-modification in the chick embryo resulting from injections of male and female hormones. *Proc. Natl. Acad. Sci. U.S.A.*, 21: 625-631.
- Willier, B.H., T.F. Gallagher and F.C. Koch, 1937. The modification of sex development in the chick embryo by male and female sex hormones. *Physio. Zool.*, 10: 101-122.
- Willier, B.H., M.E. Rawles and F.C. Koch, 1938. Biological differences in the action of synthetic male hormones on the differentiation of sex in the chick embryo. *Proc. Natl. Acad. Sci. U.S.A.*, 24: 176-182.
- Wistedt, A., Y. Ridderstrale, H. Wall and L. Holm, 2012. Effects of phytoestrogen supplementation in the feed on the shell gland of laying hens at the end of the laying period. *Anim. Reprod. Sci.*, 133: 205-213.
- Wohlfahrt-Veje, C., K.M. Main and N.E. Skakkebaek, 2009. Testicular dysgenesis syndrome: Foetal origin of adult reproductive problems. *Clin. Endocrinol.*, 71: 459-465.
- Woodard, A.E., H. Abplanalp and R.L. Snyder, 1973. Oviposition time in the chukar partridge. *Poult. Sci.*, 52: 536-539.
- Zhang, L.D., Q. Deng, Z.M. Wang, M. Gao, L. Wang, T. Chong and H.C. Li, 2013. Disruption of reproductive development in male rat offspring following gestational and lactational exposure to di-(2-ethylhexyl) phthalate and genistein. *Biol. Res.*, 46: 139-146.
- Zhao, R., Y. Wang, Y. Zhou, Y. Ni, L. Lu, R. Grossmann and J. Chen, 2004. Dietary daidzein influences laying performance of ducks (*Anas platyrhynchos*) and early post-hatch growth of their hatchlings by modulating gene expression. *Comp. Biochem. Physiol. A. Mol. Integr. Physiol.*, 138: 459-466.
- Zhao, R.Q., Y.C. Zhou, Y.D. Ni, L.Z. Lu, Z.R. Tao, W.H. Chen and J. Chen, 2005. Effect of daidzein on egg-laying performance in shaoxing duck breeders during different stages of the egg production cycle. *Br. Poult. Sci.*, 46: 175-181.