

ISSN 1682-8356
ansinet.org/ijps



INTERNATIONAL JOURNAL OF
POULTRY SCIENCE

ANSI*net*

308 Lasani Town, Sargodha Road, Faisalabad - Pakistan
Mob: +92 300 3008585, Fax: +92 41 8815544
E-mail: editorijps@gmail.com

Growth Performance and Histological Changes in Ileum and Immune Related Organs of Broilers Fed Organic Acids or Antibiotic Growth Promoter

M.A. Mohamed, Eman F. El-Daly, Nafisa A. Abd El-Azeem, Amani W. Youssef and H.M.A. Hassan
Department of Animal Production, National Research Centre, 12622, Dokki, Egypt

Abstract: An experiment was designed to evaluate the effects of using organic acids as an alternative to antibiotic growth promoter on performance of broiler chicks. Carcass characteristics, histological changes of ileum and immune related organs (bursa, thymus and spleen) along with intestinal bacteria count were also studied. A number of 150 Cobb broiler chicks were fed on three dietary treatments: a basal corn-soybean meal diet served as a control treatment with no supplements or supplemented with either 0.025% Bacitracin Methylene Disalicylat (BMD, antibiotic) or 0.06% Galliacid[®] (organic acids) from 10 to 36 days of age. The results showed that birds fed antibiotic or organic acids gained significant ($p < 0.05$) more body weight than those fed the control diet. No significant differences were detected among treatments on feed intake while feed conversion ratio (FCR) values were significantly ($p < 0.001$) differ. Addition of organic acids or antibiotic did improve FCR by about 9 and 4%, respectively. These results indicated that birds fed either organic acids or antibiotic supplemented diets utilized feed more efficiently than those fed the control diet. Carcass characteristics were not affected by dietary treatments, while the addition of antibiotic or organic acids significantly ($p < 0.01$) increased spleen and bursa weight (% live body weight). Addition of organic acids was more effective than antibiotic on decreasing intestinal count of *Escherichia coli* and appearance of *Colostridium perfringers*. Organic acids as alternative to the antibiotic growth promoter have stimulated some histological change in histology of the villi and the immune related organs. Performance and feed efficiency are closely interrelated with the quantitative microbial load of the gut, the morphological structure of the intestinal wall and the activity of the immune system. In conclusion, dietary inclusion of organic acids increased growth performance and improved intestinal health and morphology of broiler chicks. It could be successfully used as alternative to antibiotic growth promoters in broiler diets or as a tool of controlling intestinal pathogenic bacteria.

Key words: Feed additives, broiler, caecum bacteria, immune organs, ileum histology

INTRODUCTION

Antibiotic growth promoters (AGPs) have been routinely supplemented to poultry feeds in order to improve the growth performance and to reduce the populations of potentially-pathogenic organisms. However, AGPs supplementation to poultry diets has been seriously condemned due to the risk of developing cross-resistance and multiple antibiotic resistances in pathogenic bacteria and there has been an ongoing necessity to identify effective replacements for AGPs in animal nutrition.

Organic acids are among the alternative growth promoters that are being used to stimulate growth performance in poultry (Dibner and Winter, 2002; Dibner, 2004; Adil *et al.*, 2010; Hassan *et al.*, 2010). Many studies demonstrated that supplementation of organic acids to broiler diets could be used to increased growth performance, reduced diseases and overcome some management problems (Gunal *et al.*, 2006; Islam *et al.*, 2008; Ao *et al.*, 2009; Hassan *et al.*, 2010; Sayrafi *et al.*, 2011). However, inconsistent results had been reported

on the effect of adding organic acids to broiler diets on growth performance. While, Hassan *et al.* (2010) concluded that organic acid are more efficient than antibiotic growth promoters in improving broiler performance, Sayrafi *et al.* (2011) showed that weight gain and feed intake were not affected by addition of organic acids.

On the other hand, supplementation of organic acids to poultry diets was shown to increases beneficial microbial activity in the small intestine (Cengiz *et al.*, 2012) and suppress the growth of certain species of bacteria such as *Salmonella*, *E. coli*, *Clostridium perfringes*, *Listeria monocytogenes* and *Campylobacter* (Van Immerseel, 2002; Hassan *et al.*, 2010). This may positively stimulus gut morphology. There were also some evidences related to the effect of addition of either antibiotic or organic acids to broiler diets on intestine histology (Sayrafi *et al.*, 2011). Organic acids increase villus length in poultry (Gunal *et al.*, 2006; Samik *et al.*, 2007) while antibiotic caused low villi height (Oliveira *et al.*, 2008; Abudabos *et al.*, 2014).

The objective of this study was to further compare the effects of adding commercial organic acid mixture (Galliacid) as alternative of antibiotic growth promoter (BMD) to broiler diets on productive performance, carcass characteristics and caecal bacterial content. Changes in histology of ileum and immune related organs (bursa, thymus and spleen) were also studied.

MATERIALS AND METHODS

Birds, feeding and management: A total number of 200 unsexed one day old Cobb 500 broiler chicks were brooded and fed on a starter diet for 10 days of age. Birds were then individually weighed and 150 chicks with almost the same live body weight were divided into three groups (5 replicates of 10 chicks, each). The average initial live body weight of all replicates was nearly similar. Replicates were randomly allocated in batteries of three-tier system that has 15 compartments (5 replicates x 3 dietary treatments). The dietary treatments involved a control diet of no feed additives, a diet supplemented with antibiotic growth promoter (BMD[®]) and a diet supplemented with the examined commercial products of organic acids (Galliacid[®]). BMD[®] is an antibacterial feed additive containing Bacitracin Methylene Disalicylat produced by Alpharma, USA (it is mainly used as growth promoter by prevention and control of necrotic enteritis in broiler and control of clostridial enteritis). Galliacid[®] is a mixture of fumaric acid, calcium formate, calcium propionate, potassium sorbate and hydrogenated vegetable oil produced by Jefo, Company, Saint-Hyacinthe Canada. These organic acids are coated and protected (microencapsulated) by a matrix of fatty acids.

Birds were fed on a commercial starter diets contained 23% CP and 3000 Kcal/kg for the first 10 days of age then switched to the experimental grower and finisher diets. The basal grower and finisher diets were formulated to cover all the nutrient requirements of Cobb 500 broilers. The formulation and nutrient composition of the grower (11-25 days) and finisher (26-36 days) control diets are shown in Table 1. The control grower and finisher diets were fed with no additives or supplemented with either 0.025% BMD or 0.06% Galliacid[®]. Supplementation levels were applied according to the producer recommendations. Birds were fed the experimental diets for *ad libitum* consumption from 10 to 36 days of age and light was provided 23 h daily. Birds were vaccinated against AI, ND, IB and IBD throughout the experimental time. After these medical treatments, a dose of vitamins (AD₃E) was offered in the drinking water for the successive 3 days.

Performance measurements: At 25 and 36 days of age, after fasting overnight, birds were individually weighed and feed consumption was recorded per replicate. Body weight gain and feed conversion ratio were then calculated.

Table 1: Formulation and nutrient composition of the basal grower and finisher diets

Ingredients (%)	Grower diet (11-25 d)	Finisher diet (26-36 d)
Yellow corn	59.00	64.40
Soybean meal (48%)	34.50	28.50
Vegetable oil	2.50	3.30
Dicalcium phosphate	1.45	1.40
Limestone	1.20	1.10
Vitamin and mineral mix ¹	0.30	0.30
Salt	0.25	0.22
Sodium bicarbonate	0.25	0.20
L-lysine HCl	0.15	0.18
DL-methionine	0.30	0.30
Choline HCl	0.10	0.10
Total	100	100
Calculated composition² (%)		
Crude protein	21.10	18.50
ME (Kcal/Kg)	3150	3250
Lysine	1.31	1.16
Methionine	0.59	0.57
Meth + Cystine	0.96	0.90
Calcium	0.95	0.90
Nonphytate P	0.47	0.45

¹Vitamin-mineral mixture supplied per kg of diet: Vit. A, 12,000 IU, Vit. D₃, 2,200 IU, Vit. E, 10 mg, Vit. K₃, 2 mg, Vit. B₁, 1 mg, Vit. B₂, 4 mg, Vit. B₆, 1.5 mg, Vit. B₁₂, 10 ig, Niacin, 20 mg, Pantothenic acid, 10 mg, Folic acid, 1 mg, Biotin, 50 ig, Copper, 10 mg, Iodine, 1 mg, Iron, 30 mg, Manganese, 55 mg, Zinc, 50 mg and Selenium, 0.1 mg, Phytase 500 U and xylam, 600 U.

²Calculated values based on feed composition Tables of NRC (1994)

Carcass characteristics: At day 36, five representative chicks with body weight close to the group average were selected, fasted for 12 h then individually weighed, slaughtered, feathered and eviscerated. Weights of carcass, liver, gizzard, heart, spleen, bursa and abdominal fat were recorded and calculated as % of live body weight.

Caecal *E. coli* and *Clostridium perfringens*: The counting method was adopted as described by Hassan *et al.* (2010). Caecal contents were immediately collected from the slaughtered birds and prepared based on the method of Weinack *et al.* (1979). *Clostridium perfringens* and *E. coli* colonies were counted according to Collins and Lyne (1984). The microbial counts were determined as colony forming units (cfu) per gram of sample.

Histological observations: At the end of the experiment, representative tissue samples from ileum and immune related organs (bursa, thymus and spleen) were taken to study the histological changes associated with the experimental treatments. Samples were fixed in a 10% formalin-saline solution before preparing the histological sections using paraffin method technique. All sections were dehydrated in ascending grades of ethanol, cleared in zylene and then embedded in paraffin wax. Transverse sections (4-5 microns, thickness) were

taken, mounted on glass slides and stained with haemotoxyline and eosin (H and E) stains. All sections were examined under electric microscope provided with computerized camera.

Statistical analysis: Data were statistically analyzed for analysis of variance using the General Liner Model of SAS Institute (1990). Significant differences among treatment means were separated by Duncan's multiple rang test (Duncans, 1955) with a 5% level of probability.

RESULTS

Growth performance: Performance of chicks fed the different experimental diets during the two feeding intervals (11-25 and 26-36 days of age) and the entire period (10-36 days of age) is summarized in Table 2. During the two intervals, body weight gain (BWG) did not significantly affect by the dietary treatments but significant (p<0.01) improvement was observed on feed conversion ratio (FCR). The results of the entire period showed birds fed BMD or Galliacid gained significant (p<0.05) more body weight than those fed the control diet. No significant differences were detected among treatments on feed intake. The recorded values of FCR were 1.71 for the control diet and 1.65 and 1.55 for those fed BMD and Galliacid supplemented diets, respectively. Addition of Galliacid or BMD did improve FCR by about 9 and 4%, respectively.

Carcass characteristics: Effects of dietary treatments on carcass characteristics of broilers are shown in Table 3. The results indicated that carcass characteristics were not affected by dietary treatments, while the relative weights of spleen and bursa were significantly (p<0.01) affected. Addition of antibiotic or organic acid significantly (p<0.01) increased relative weight of spleen and bursa compared with the control. No significant differences were detected on carcass

weight, dressing, heart, gizzard and liver (% body weight) among treatments. The relative weight of spleen and bursa were significantly improved (p<0.01) by supplementation of antibiotic or organic acids compared to the control diet.

Caecal bacteria: The effects of dietary treatments on intestinal microflora (*Escherichia coli* and *Clostridium perfringers*) of chicks fed the different dietary treatments are shown in Table 4. The results showed that the addition of antibiotic (BMD) did not decrease count of intestinal *Escherichia coli* compared to the control diet. Also, *Clostridium perfringers* was detected on intestine of birds fed antibiotic supplemented diet as the control treatment. Addition of organic acid (Galliacid) significantly (p<0.001) decreased intestinal count of *Escherichia coli* compared to the control diet and that supplemented with antibiotic. *Clostridium perfringers* was not detected on the intestine of birds fed organic acid supplemented diet. These results indicated that addition of organic acids to broiler diets was more effective than antibiotic on decreasing intestinal count of *Escherichia coli* and appearance of *Clostridium perfringers*.

Histological observations

A-small intestine (Ileum): Figure 1 shows the histological changes related to the feed additives. Villi height and width along with the number of crypts per the microscopic field were differed between the control (Fig. 1a) and the treated groups (Fig. 1b-c). There were more crypts of the treated groups compared with control. Furthermore, the epithelial lining of the crypts is cuboidal in these sections. These changes may reflect a positive effect of the growth promoters on the digestive tract histology as the major system for nutrients digestion and absorption.

Table 2: Growth performance of broiler chicks fed the different dietary treatments during the different intervals

Item	----- Grower period 10-25 day -----			----- Finisher period 26-36 day -----			----- Entire period 10-36 day -----		
	BWG (g)	FI (g)	FCR (g/g)	BWG (g)	FI (g)	FCR (g/g)	BWG (g)	FI (g)	FCR (g/g)
Dietary Treatments									
Control (No additives)	811	1306 ^a	1.61 ^a	769	1376	1.79 ^a	1576 ^b	2695	1.71 ^a
BMD (Antibiotic)	842	1317 ^a	1.56 ^b	790	1380	1.75 ^a	1632 ^a	2697	1.65 ^b
Galliacid (Organic acids)	836	1223 ^b	1.46 ^c	798	1315	1.65 ^b	1634 ^a	2538	1.55 ^c
SE of means	±11.76	±19.91	±0.03	±16.05	±13.15	±0.02	±21.95	±37.20	±0.02
Significances	NS	*	***	NS	NS	**	*	NS	***

*Mean within each column with no common superscript differ significantly (p<0.05). *p<0.05, **p<0.01, ***p<0.001. NS: Not significant (p>0.05)

Table 3: Carcass characteristics (% of live body weight) of 36 days old broiler chicks fed the different experimental diets

Item	Dressing (%)	Abdominal fat (%)	Liver (%)	Gizzard (%)	Heart (%)	Bursa (%)	Spleen (%)
Dietary Treatments							
Control (No additives)	72.18	1.85	2.09	1.60	0.59	0.09 ^a	0.08 ^b
BMD (Antibiotic)	72.59	2.13	2.37	1.61	0.48	0.10 ^{ab}	0.13 ^a
Galliacid (Organic acids)	71.51	1.80	2.51	1.58	0.48	0.12 ^a	0.13 ^a
SE of means	±0.25	±0.11	±0.15	±0.14	±0.11	±0.01	±0.03
Significances	NS	NS	NS	NS	NS	**	**

*Mean within each column with no common superscript differ significantly, NS: Not significant *p>0.05 **p<0.01

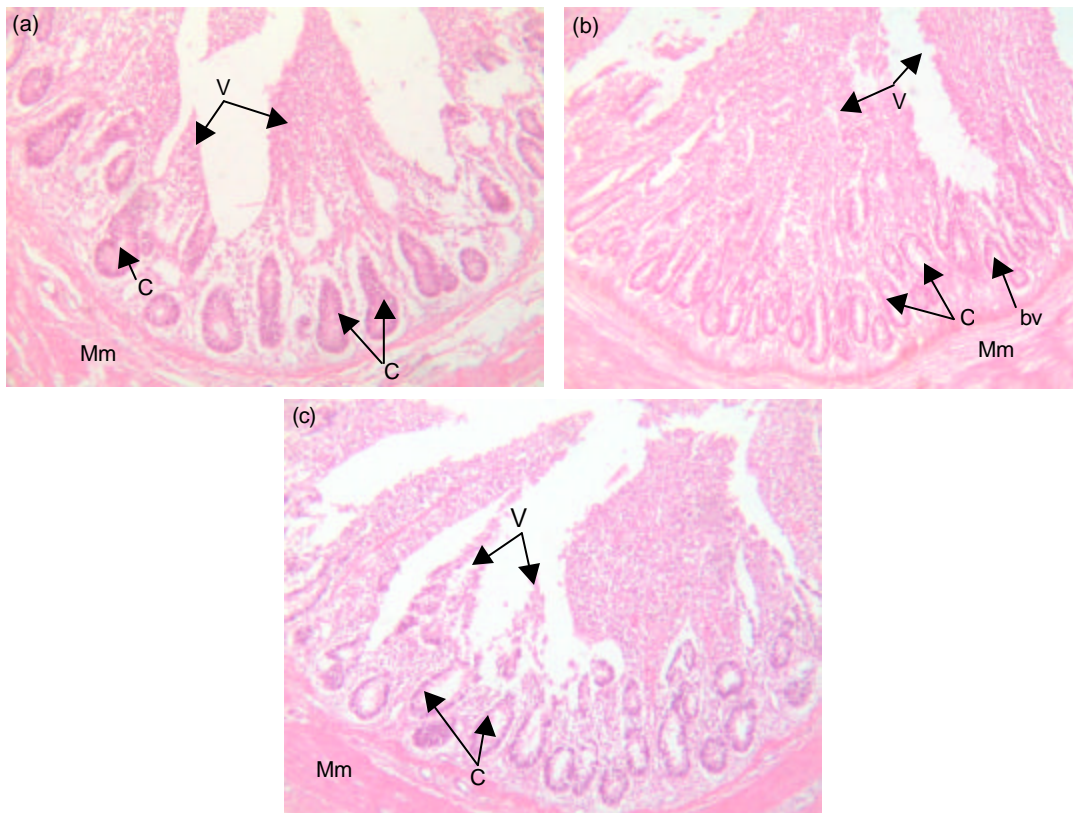


Fig. 1: Transverse section through the ileum as affected by the dietary treatments. (a) Control, (b) BMD (antibiotic) and (c) Galliacid (organic acid). Mm: Muscularis mucosa, Bv: Blood vessel, C: Crypts of Lieberkuhn, V: Villi

B-Immune-related organs

Bursa of fabricius: Fig. 2 shows the effect of dietary treatments on histology of chick bursa. As described by Hodges (1974), bursa of Fabricius is a primary lymphoid organ in birds and it is composed of about 15 plicae (folds), each contain numerous bursal follicles (F). These follicles have two distinct areas, cortex and medulla. The present sections show that the F of the control group (Fig. 2a) elongated with few large lymphocytes (LL) and abundant medullary area. This area is composed of apparently undifferentiated epithelial cells (pale-staining) and small lymphocytes (SL) or lymphoblasts. However, well developed bursal follicles could be seen in the antibiotic treated group (Fig. 2b). It is clear from this section that antibiotic addition enhances the activity of bursal follicles. This hyperactivity is accompanied by the presence of many large lymphocytes in the cortex area concomitant with many lumens between the follicles. These lumens are abundant in this treatment and to less extent in organic acid treatment (Fig. 2c). In general, the lumens are responsible for the phagocytic processes and for maintaining the B-cell production. It is also same age-related degenerative areas (dg) that could be seen with high frequency in Fig. 2a-c, respectively.

Thymus: The histological structures of thymus gland in response to dietary treatments are illustrated in Fig. 3. There is one lobule in each section with or without the fine septa in Fig. 3 (a-c). Khenenou *et al.* (2012) reported that thymus gland is enclosed by a fine connective tissue capsule with numerous fine septa which divide the gland into lobules. An increased number of small lymphocytes could be seen in all sections (Fig. 3a-c). Furthermore, there were several types of cellular degeneration and vaculation including necrotic areas concomitant with an irregular arrangement of thymic cells within cortex and medullary region since, the gland undergoes involution with age, the changes may be in lymphocytes number and size along with the presence of degenerative or necrotic areas these changes are more evident in the control, antibiotic and organic acid sections (Fig. 3a-c).

3-Spleen: Figure 4 illustrated the histological changes in spleen as affected by the dietary treatments. The histological section of spleen from the control group (Fig. 4a) shows the basic structure of the splenic tissues, where a large white pulp (WP) area and a dark-stained red pulp (RP) area could be seen. Also, numerous blood vessels, sinusoids and lymphocytes of

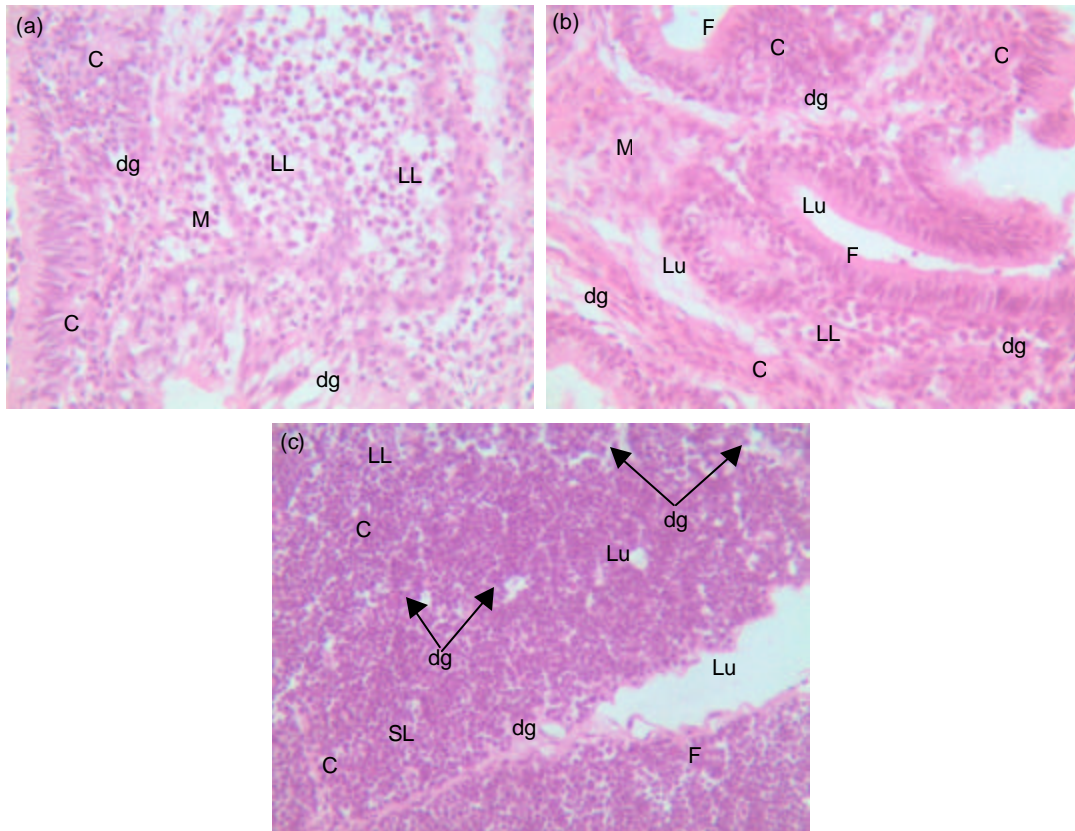


Fig. 2: Transverse section through the bursa of Fabricius as affected by the dietary treatments. (a) Control, (b) BMD (antibiotic) and (c) Galliacid (organic acid). F: Bursa follicles, LL: Large lymphocytes, Lu: Lumen, C: Cortex, M: Medulla, SL: Small lymphocytes, Dg: degenerative area

different size are observed. The main histological changes were detected in the organic acid treatment group (Fig. 4c). There were large numbers of small and large lymphocytes in both RP and WP areas and the RP area extended all over the splenic tissues. This trend was also detected in the antibiotic (Fig. 4b) treatment group section, however, the small lymphocytes are abundant than the large ones. In all sections, many basophilic hemosiderin granules could be observed in between the blood sinusoids accompanied with different patterns of WP and RP distribution within each section.

DISCUSSION

The obtained results were in agreement with those of Bozkurt *et al.* (2009) who reported that the different feed additive regimens that include organic acid significantly ($p < 0.05$) improved the growth rate of the birds compared to the control diet. However, Sayrafi *et al.* (2011) studied the effects of organic acid as an alternative feed additive to an antibiotic growth promoter (bacitracin) on the performance of broiler chicks and found that WG and feed intake were not affected by dietary treatments.

The resulted improvement in FCR is in agreement with the results of Pelicia *et al.* (2004) and Sahane *et al.* (2001) who suggested that this improvement might be due to a better ileal digestibility of nutrients. These results confirmed the growth promoting effect of supplemental organic acids as reported by Alcicek *et al.* (2004), Senkoylu *et al.* (2005) and Hassan *et al.* (2010). Hassan *et al.* (2010) indicated that organic acid mixtures (Galliacid) are more efficient than antibiotic growth promoters (Enramycin) in improving broiler performance and decreasing intestinal *Escherichia coli* and *Salmonella* spp. The obtained results also confirmed those reported by Sheikh *et al.* (2010) who found that broiler chicken fed diets supplemented with organic acids had significant ($p < 0.05$) improvement in body weight gain and feed conversion ratio. No effect ($p < 0.05$) on cumulative feed consumption was observed. Dietary treatments did not affect carcass weight and carcass yield. In the present study dietary treatments had no significant effect on carcass characteristics. Similar results were observed by Thirumeignanam *et al.* (2006) who found that carcass characteristics were not

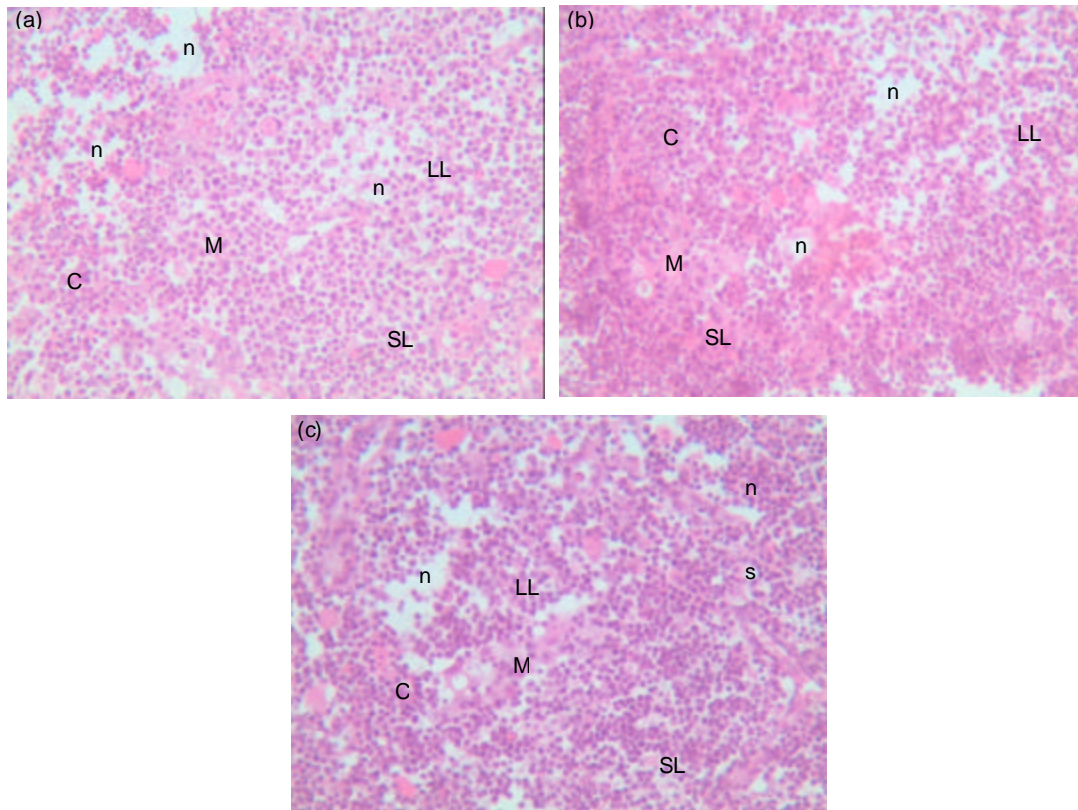


Fig. 3: Transverse section through the thymus gland as affected by the dietary treatments. (a) Control, (b) BMD (antibiotic) and (c) Galliacid (organic acid). C: Cortex, M: Medulla, S: Fine connective tissue septa, L, SL: Large small lymphocytes, N: Necrotic area

significantly affected when broiler chicks were fed diets supplemented with the organic acids.

Regarding the relations between performance and gut morphology, Vieira *et al.* (2008) reported that significant correlations were not observed between performance and villus height or crypt depth. But, Awad *et al.* (2009) concluded that villus condition is a common criteria measurement for investigation of the effects of nutrition on gut physiology. Longer villus could be considered as an indicator of an active functioning of intestinal villi. Increased villi height provides more surface area for nutrients absorption. Oliveira *et al.* (2008) and Abudabos *et al.* (2014) reported that antibiotic supplementation caused low villi height. The decrease in villi height could be attributed to the suppressing effect of the antibiotic for the beneficial bacteria in the gut, as *Lactobacillus* and *Bifidobacteria*, these bacteria play a major role in growth and maturation of the villi. Long villi are usually equated with excellent gut health, high absorptive efficiency and healthier intestinal tract of chickens. Also, Loddi *et al.* (2004) and Pelicano *et al.* (2005) explained that increased villus heights with most of the organic acids was attributed to the fact that organic acids reduce the

growth of many pathogenic or nonpathogenic intestinal bacteria, decreasing the intestinal colonization and infectious processes, ultimately decreasing the inflammatory reactions at the intestinal mucosa, which increases the villus height and functions of secretion, digestion and absorption of nutrients by the mucosa. Furthermore, several reports suggested that organic acids supplementation increase villus length in poultry (Gunal *et al.*, 2006; Samik *et al.*, 2007).

Abudabos *et al.* (2014) found that organic acids supplementation reduced the *Salmonella* count and improved the morphology of the ileum as a result the cumulative FCR improved.

The obtained results proved those of Abdel-Fattah *et al.* (2008) and Hassan *et al.* (2010) who found that organic acids significantly increased the relative weight of spleen and bursa. The higher weight of spleen and bursa indicated that broiler chicks fed antibiotic or organic acids supplemented diets had better immune response and disease resistance than the control birds. In this respect, Katanbaf *et al.* (1989) reported earlier that the increase in the relative weight of such organs is considered as an indication of the immunological advances.

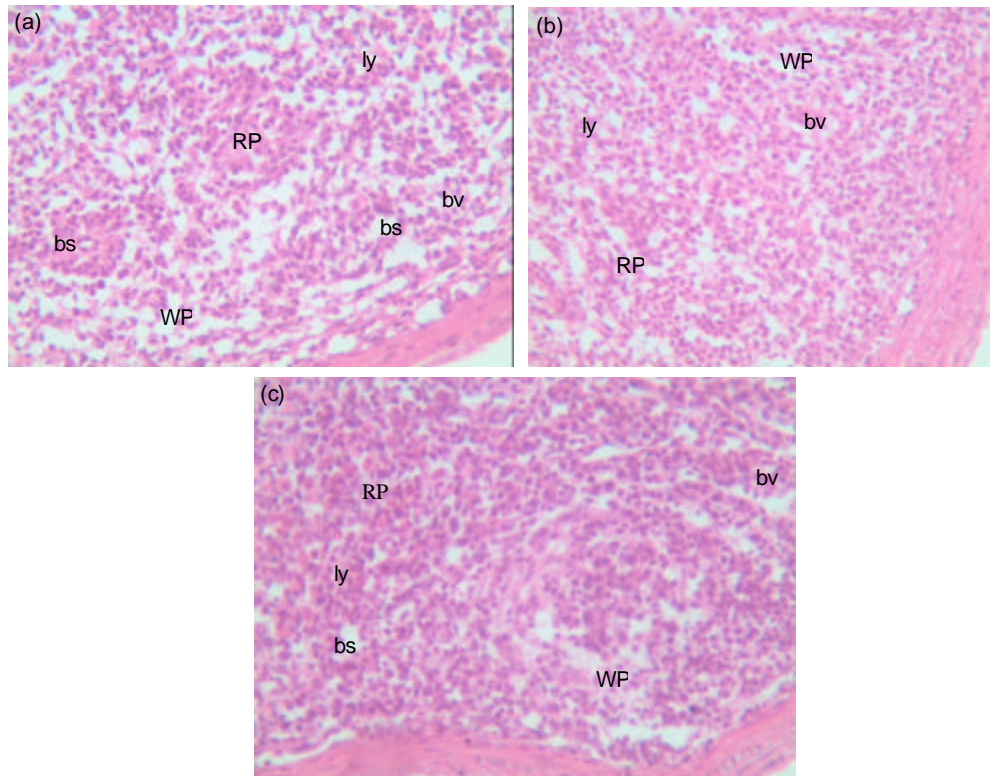


Fig. 4: Transverse section through the spleen as affected by the dietary treatments. (a) Control, (b) BMD (antibiotic) and (c) Galliacid (organic acid). RP: Red pulp, WP: Whit pulp, Bv: Blood vessel, Bs: Blood sinusoid, Ly: Lymphocytes

Table 4: Effect of dietary treatments on intestinal count of *E. coli* ssp and detection of *Clostridium perfringens* of broiler chicks at 36 days of age

Item	<i>E. coli</i> ssp. log10 cfu/g	<i>Clostridium perfringens</i>
Dietary treatments		
Control (No additives)	7.42 ^a	D
BMD (Antibiotic)	7.35 ^a	D
Galliacid (Organic acids)	6.15 ^b	ND
SE of means	±0.11	
Significances	***	

^{a,b}Mean within the column with no common superscript differ significantly
^{***}p<0.001. D: detectable ND: Non detectable

It appears from the obtained results also that the enhanced growth performance of broiler is associated with significant increases in lymphoid organs relative weights, indicative of better immune response and good physiological status of birds. This was also supported by the observed histological changes in villi height, crypts size and depth along with the presence of many goblet cells in the epithelial lining of crypts which reveal an active hyperplasia in villi epithelium and crypts of LieberKuhn.

It is concluded that organic acids stimulated some histological change in the villi histology and immune related organs, which may explain the observed

improvement in performance, immunity and gastrointestinal environment. This means that performance and feed efficiency are closely interrelated with the qualitative and quantitative microbial load of the animal gut, the morphological structure of the intestinal wall and the activity of the immune system. Thus, organic acids could be used either as growth promoters or as a tool of controlling intestinal pathogenic bacteria.

ACKNOWLEDGMENT

This work is a part of the Internal Research Project No. 10120502 of NRC, Egypt.

REFERENCES

- Abdel-Fattah, S.A., M.H. El-Sanhoury, N.M. El-Mednay and F. Abdel-Azeem, 2008. Thyroid activity, some blood constituents, organs morphology and performance of broiler chicks fed supplemental organic acids. *Int. J. Poult. Sci.*, 7: 215-222.
- Abudabos, A.M., S.I. Al-Mufarrej, A.H. Alyemni, H.M. Yehia, A.R. Garelnabi and M.N. Alotybi, 2014. Effect of using organic acids to substitute antimicrobial growth promoters on broiler chickens performance. *J. Food Agric. and Environ.*, 12: 447-451.

- Adil, S., T. Banday, G.A. Bhat, M.S. Mir and M. Rehman, 2010. Effect of dietary supplementation of organic acids on performance, intestinal histomorphology and serum biochemistry of broiler chicken. *Vet. Med. Int.*, 2010: 1-7.
- Alcicek, A., M. Bozkurt and M. Cabuk, 2004. The effects of a mixture of herbal essential oil, an organic acid or a probiotic on broiler performance. *S. Afr. J. Anim. Sci.*, 34: 217-222.
- Ao, T., A.H. Cantor, A.J. Pescatore, M.J. Ford, J.L. Pierce and K.A. Dawson, 2009. Effect of enzyme supplementation and acidification of diets on nutrient digestibility and growth performance of broiler chicks. *Poult. Sci.*, 88: 111-117.
- Awad, W.A., K. Ghareeb and S. Abdel-raheem, 2009. Effects of dietary inclusion of probiotic and symbiotic on growth performance, organ weights and intestinal histomorphology of broiler chickens. *Poult. Sci.*, 88: 49-56.
- Bozkurt, M., K. Kucukyilmaz, A.U. Catli and M. Cinar, 2009. The effect of single or combined dietary supplementation of prebiotics, organic acid and probiotics on performance and slaughter characteristics of broilers. *S. Afr. J. Anim. Sci.*, 39: 197-205.
- Cengiz, O., B.H. Koksall, O. Tatli, O. Sevim, H. Avci, T. Epikmen, D. Beyaz, S. Buyukyoruk, M. Boyacioglu, A. Uner and A.G. Onol, 2012. Influence of dietary organic acid blend supplementation and interaction with delayed feed access after hatch on broiler growth performance and intestinal health. *Vet. Med.*, 57: 515-528.
- Collins, C.H. and P.M. Lyne, 1984. *Microbiological methods*. Fifth Edition, Butterworth's, London, 331-345.
- Dibner, J. and B. Winter, 2002. Use of organic acids as a model study the impact of gut microflora on nutrition and metabolism. *J. Appl. Poult. Res.*, 10: 453-463.
- Dibner, J., 2004. Organic acids: Can they replace antibiotic growth promoters? *Feed Int.*, 25: 14-16.
- Duncans, D.B., 1955. Multiple range and multiple F test. *Biomet.*, 11: 1-42.
- Gunal, M., G. Yayli, O. Kaya, N. Karahan and O. Sulak, 2006. The effects of antibiotic growth promoter, probiotic or organic acid supplementation on performance, intestinal microflora and tissue of broilers. *Int. J. Poult. Sci.*, 5: 49-155.
- Hassan, H.M.A., M.A. Mohamed, Amani, W. Youssef and Eman R. Hassan, 2010. Effect of using organic acids to substitute antibiotic growth promoters on performance and intestinal microflora of broilers. *Asian-Aust. J. Anim. Sci.*, 23: 1348-1353.
- Hodges, R.D., 1974. *The histology of the fowl*. 1st ed. Academic Press, Inc (London) LTD.
- Islam, K.M.S., A. Schuhmacher, H. Aupperle and J.M. Gropp, 2008. Fumaric acid in broiler nutrition: a dose titration study and safety aspects. *Int. J. Poult. Sci.*, 7: 903-907.
- Katanbaf, M.N., E.A. Dunnington and P.B. Siegel, 1989. Restricted feeding in early and late feathering chickens, growth and physiological responses. *Poult. Sci.*, 68: 344-351.
- Khenenou, T., M. Mohamed, B. Omar and B. Hassina, 2012. Morpho histological study of the thymus of broiler chickens during post-hatching age. *Int. J. Poult. Sci.*, 11: 78-80.
- Loddi, M.M., V.M.B. Maraes, I.S.O. Nakaghi, F. Tucci, M.I. Hannas and J.A. Ariki, 2004. Mannan oligosaccharide and organic acids on performance and intestinal morphometric characteristics of broiler chickens, in *Proceedings of the 20th Annual Symposium on Computational Geometry*, supplement 1, p. 45, Brooklyn, NY, USA, June 2004.
- National Research Council (NRC), 1994. *Nutrient requirements of poultry*. 9th rev. ed. National Academy press, Washington, DC.
- Oliveira, M.C., E.A. Rodrigues, R.H. Marques, R.A. Gravena, G.C. Guandolini and V.M.B. Moraes, 2008. Performance and morphology of intestinal mucosa of broilers fed mannan-oligosaccharides and enzymes. *Arquivo Brasileiro de Med. Vet., e Zoo*, 60: 442-448.
- Pelicano, E.R.L., P.A. Souza and H.B.A. Souza, 2005. Intestinal mucosa development in broiler chicken fed natural growth promoters. *Brazilian J. Poult. Sci.*, 7: 221-229.
- Pelicia, K., A.A. Mendes, E.S. Saldanha, C. Piazzolante and S. Takahashi, 2004. Probiotic and prebiotic utilization in diets for free-range broiler chickens. *Br. J. Poult. Sci.*, 92: 99-104.
- Sahane, M.S., 2001. Mannan oligosaccharides in poultry nutrition: Mechanism and benefits. *Proc. Alltech's 17th Annual Symp.* Eds. Lyons, T.P. and Jacques, K.A., Nottingham University Press. pp: 65-77.
- Samik, H.E., N. Senkoylu, F. Koc, M. Kanter and A. Agma, 2007. Effects of *Enterococcus faecium* and dried whey on broiler performance, gut histomorphology and microbiota. *Arch. Anim. Nutr.*, 61: 42-49.
- SAS Institute, 1990. *SAS®/STAT User's Guide: Statistics*, Version 6, 4th edition. SAS Institute Inc, Cary, NC.
- Sayrafi, R., F. Soltanlinejad, R. Shahrooz and S. Rahimi, 2011. Comparative study of the effect of alternative and antibiotic feed additives on the performance and intestinal histomorphometrical parameters of broiler chickens. *Afr. J. Agric. Res.*, 6: 2794-2799.
- Senkoylu, N., H.E. Samli, H. Akyurek and A. Agma, 2005. Impacts of organic acids and nutrient density of basal diets on broiler growth and gut histomorphology. *Proc. 15th European Symp. Poultry Nutrition*. September 25-29, 2005, Balatonfured, Hungary. pp: 398-400.

- Sheikh, A., B. Tufail, A.B. Gulam, S.M. Masood and R. Manzoor, 2010. Effect of dietary supplementation of organic acids on performance, intestinal histomorphology and serum biochemistry of broiler chicken. *Veterinary Medicine International*. Volume 2010: 479-485.
- Thirumeignanam, D., R.K. Swain, S.P. Mohanty and P.K. Pati, 2006. Effects of dietary supplementation of organic acids on performance of broiler chicken. *Ind. J. Anim. Nutr.*, 23: 34-40.
- Van Immerseel, F., K. Cawerts, L.A. Devriese, F. Haesebrouck and R. Ducatelle, 2002. Feed additives to control *Salmonella* in poultry. *World's Poult. Sci. J.*, 58: 501-509.
- Vieira, S.L., O.A. Oyarzabal, D.M. Freitas, J. Berres, J.E. M. Pena, C.A. Torres and J.L.B. Coneglian, 2008. Performance of broilers fed diets supplemented with sanguinarine-like alkaloids and organic acids. *J. Appl. Poult. Res.*, 17: 128-133.
- Weinack, O.M., C.F. Smyserand and G.H. Soneyenbos, 1979. Evaluation of several methods of detecting salmonella in groups of chickens. *Avian. Dis.*, 23: 179-193.