

ISSN 1682-8356
ansinet.org/ijps



INTERNATIONAL JOURNAL OF
POULTRY SCIENCE

ANSI*net*

308 Lasani Town, Sargodha Road, Faisalabad - Pakistan
Mob: +92 300 3008585, Fax: +92 41 8815544
E-mail: editorijps@gmail.com



Research Article

Effects of Organic Acids on *Salmonella enteritidis* Growth Inhibition and Ileum Surface Area in Laying Ducks Fed Anaerobically Fermented Feed

¹A.T. Allaily Tarman, ¹N.R. Nahrowi Ramli, ¹M.R.M. Ridla, ²M.A.Y.M. Aman Yaman and ³A.S. Agus Setiyono

¹Department of Nutrition and Feed Technology, Faculty of Animal Science, Bogor Agricultural Institute, Agatis Street IPB, Darmaga Campus, 16680 Bogor, Indonesia

²Animal Husbandry, Agricultural Faculty, Syiah Kuala University, Tgk. Hasan Krueng Kalee, Street No. 3, 23111 Banda Aceh-Darussalam, Indonesia

³Veterinary Medicine Faculty, Bogor Agricultural Institute, Agatis Street, IPB Darmaga Campus, 16680 Bogor, Indonesia

Abstract

Objective: This study aimed to determine the organic acid content of anaerobically fermented feed, its capacity to inhibit *Salmonella enteritidis* and its effects on the ileum surface area of laying ducks. **Materials and methods:** To determine the organic acid content and inhibitory effects of fermented feed, four fermentation times were used as treatments (7, 14, 21 and 28 days) and each treatment was replicated three times. The feed ingredients included yellow corn, soybean meal, coconut meal, fish meal, CaCO₃, dicalcium phosphate (DCP), premix and lactic acid bacteria at 5×10^8 CFU mL⁻¹. The feed was anaerobically fermented with a moisture content of up to 45% and local 5 month old laying ducks were used. The surface area of the ileum was measured in 6.5 and 8 month old ducks assigned to the 3 treatments (R1 = Dry feed, R2 = Wet feed without fermentation, R3 = Wet anaerobically fermented feed). Ileum surface area was initially 10 cm. After treatment, the tissue was prepared with hematoxylin and eosin staining and the area was measured using ImageJ software. The measured parameters were: (1) Organic acids, (2) The inhibitory zone and (3) Ileum surface area. **Results:** Fermented feed contained organic acids, such as lactic acid, propionic acid and butyric acid, that inhibited pathogenic bacteria, such as *S. enteritidis*. Fermented feed resulted in an increase in ileum surface area. **Conclusion:** Anaerobically fermented feed maintained conditions that caused the ileum surface area become larger, increasing nutrient absorption.

Key words: Anaerobically fermented feed, ileum surface area, laying ducks, organic acid, wet feed

Received: November 28, 2016

Accepted: January 13, 2017

Published: February 15, 2017

Citation: A.T. Allaily Tarman, N.R. Nahrowi Ramli, M.R.M. Ridla, M.A.Y.M. Aman Yaman, A.S. Agus Setiyono, 2017. Effects of organic acids on *Salmonella enteritidis* growth inhibition and ileum surface area in laying ducks fed anaerobically fermented feed. Int. J. Poult. Sci., 16: 98-104.

Corresponding Author: A.T. Allaily Tarman, Department of Nutrition and Feed Technology, Faculty of Animal Science, Bogor Agricultural Institute, Agatis Street IPB, Darmaga Campus, 16680 Bogor, Indonesia

Copyright: © 2017 A.T. Allaily Tarman *et al.* This is an open access article distributed under the terms of the creative commons attribution License, which permits unrestricted use, distribution and reproduction in any medium, provided the original author and source are credited.

Competing Interest: The authors have declared that no competing interest exists.

Data Availability: All relevant data are within the paper and its supporting information files.

INTRODUCTION

Duck feed technology still relies on moistening dry feed but wet feed can be produced directly after harvest using the existing water content in the ingredients and anaerobic fermentation¹. In addition, anaerobic fermentation increases the storability of post-harvest ingredients and has multiple benefits for animal health². Fermented feed given to ruminant livestock had been reported to function as an antimicrobial agent³ against *Micrococcus luteus*, *Pseudomonas aeruginosa*⁴ and *Escherichia coli*⁵ and the use of anaerobically fermented feed in broiler chickens has been reported to maintain the condition of the small intestine⁶ and improve performance without affecting the morphology of intestinal villi⁷. Male Mojosari Alabio broiler ducks fed anaerobically fermented wet feed with a water content of 50% were of the best quality based on feed conversion ratios⁸ and local ducks in Vietnam showed improved feed intake, growth rates and feed conversion⁹.

The multiple benefits of anaerobically fermented feed are derived from the organic acids produced by Lactic Acid Bacteria (LAB) during the fermentation process; the dominant species of lactic acid bacteria is *Lactobacillus plantarum*¹⁰. Directly providing organic acids as a feed additive to broiler chickens has been reported to have antimicrobial effects on pathogens that limit their growth¹¹ but the effects of the organic acid content of fermented feed on laying ducks and its influence on the surface area of the ileum have yet to be reported. Therefore, this study is very important because it provides information about the organic acid content of anaerobically fermented feed, its inhibitory effects on pathogenic bacteria such as *Salmonella enteritidis* and its effect on the ileum surface area of laying ducks.

MATERIALS AND METHODS

Dietary composition and experimental animals: This research used the following feed ingredients: Yellow corn, soybean meal, rice bran, fish meal, coconut meal, Crude Palm Oil (CPO), CaCO₃, dicalcium phosphate (DCP), premix and a liquid inoculum containing a total of 5 × 10⁸ CFU mL⁻¹ of Lactic Acid Bacteria (LAB) for the fermentation process. Feed treatments included dry commercial feed (R1), wet feed without fermentation (R2) and wet feed with anaerobic fermentation (R3) and were based on the nutritional needs of laying ducks. The fermentation time was 7 days. The ducks used in the experiment were 5 months of age and came from Indramayu, West Java.

Anaerobic feed fermentation process: All feed ingredients were mixed according to the formulas in Table 1, with a water content of 45%, based on previous studies¹². Water was added to mixed feed containing 5 × 10⁸ CFU mL⁻¹ of LAB and approximately 1 kg of mixed ration was then compacted in a plastic bag. The plastic container was sealed and stored in a drum silo and then fermented under anaerobic conditions for 7, 14, 21 and 28 days (treatments).

Organic acid analysis: The contents of organic acids, such as lactic acid, propionic acid and butyric acid, were measured via High Performance Liquid Chromatography (HPLC). Every 2 g sample was placed in a 125 mL Erlenmeyer flask and 25 mL of water was added and stirred until the samples dissolved. The pH was maintained at 1-2 with 3 N HCl and extraction was performed twice with 25 mL of diethyl ether for 2 min. The resulting extract was basified to pH 8 with 2 N NaOH and then evaporated to the water phase. The remaining layer of water was diluted to 2 mL to a mobile phase and filtered through a 0.45 μm Millex filter and 20 mL was injected into the HPLC system.

A stock standard of 10,000 ppm of lactic acid was used and the standard series were as follows: Lactic acid: 312.5, 625, 1250 and 2500 ppm; propionic acid: 62.5, 125, 250 and 500 ppm and butyric acid: 62.5, 125, 250 and 500 ppm. Then, 10 mL of each were injected into 300 × 7.8 mm Meta Carb H

Table 1: Nutrient and feed ingredient composition

Ingredients	Composition (%)
Yellow corn	50.00
Soybean meal	20.00
Rice bran	10.00
Fish meal	8.00
Coconut meal	7.50
CPO	3.00
CaCO ₃	0.50
DCP	0.50
Feedmix B	0.50
Total	100.00
Nutrient composition	
Crude protein (%)*	21.01
Metabolic energy (kcal kg ⁻¹)**	2743.25
DM (%)*	88.50
Ash (%)*	10.75
Ca (%)*	3.03
P (%)*	0.56

Feedmix B: Vit A: 2000.000 IU, Vit D: 400.000 IU, Vit E: 600 mg, Vit B1: 200 mg, Vit B2: 1000 mg, Vit B12: 1000 mg, Vit K: 200 mg, Niacinamide: 1500 mg, Ca-d-pantothenate: 500 mg, Folic acid: 100 mg, Choline chloride: 20.000 mg, L-lysine: 15.000 mg, DL-methionine: 20.000 mg, Magnesium sulfate: 6.800 mg, Ferrous sulfate: 5000 mg, Manganese sulfate: 10.000 mg, Cupric sulfate: 100 mg, Zinc sulfate: 2.000 mg, Potassium iodine: 20 mg, Antioxidant and carrier at 1 mg,

*Nutrition and Feed Technology Laboratory Faculty of Animal Science IPB (2015)

**Nutrient value based on Leeson and Summers²⁵

Table 2: Organic acid contents of anaerobic fermented feed

Parameters (ppm)	Time fermented (Days)			
	7	14	21	28
Lactic acid	305.64±5.44 ^a	876.52±19.95 ^b	1666.79±20.87 ^c	4038.7±86.48 ^d
Propionic acid	164.05±2.92 ^a	158.88±2.60 ^a	244.16±3.65 ^b	325.92±44.96 ^c
Butyric acid	<0.62	<0.62	52.94±0.78	48.48±0.67

Different superscripts indicate a significant difference ($p < 0.05$), The Integrated Research and Testing Laboratory (LPPT) UGM (2015)

Plus HPLC columns. Phase motion was measured in 125 mL of H_2SO_4 in 500 mL of water at a flow rate of 0.6 mL min^{-1} , a wavelength of 215 nm and a temperature of 80°C .

Salmonella enteritidis inhibition zone: The inhibition zone was measured *in vitro* via the well-diffusion method in Muller Hinton Agar (MHA) using 10^6 CFU mL^{-1} of a standard Max Farlan fluid. After dripping *S. enteritidis* at 10^6 CFU mL^{-1} , 100% fermented feed liquid was dripped into the well, which was incubated for 24 h until a clear zone formed that could be observed and measured. The formation of a clear zone indicated the capacity of the fermented feed liquid to inhibit the growth of *S. enteritidis*.

Surface area measurement: Ileum surface area was calculated when the laying ducks were 6.5 and 8 months old, at which time the ducks had been receiving feed treatments (R1, R2 and R3) for 1.5 and 3 months, respectively. Ileum tissue was collected, cleaned and fixed in formalin for subsequent hematoxylin and eosin staining. The dyed tissue was photographed under a microscope at $4\times$ magnification along with a micrometer scale bar and ileum surface area was measured using ImageJ software.

Research design and analysis: Measurements of the organic acid contents and *S. enteritidis* inhibition were performed using a completely randomized design with 4 treatments, i.e., fermentation times: of 7, 14, 21 and 28 days. Each treatment was repeated 3 times and each replicate consisted of 1 kg of feed.

The ileum surface areas of laying ducks were descriptively analyzed in ducks given feed anaerobically fermented for 7 days. There were 3 diet treatments: dry feed (R1), wet unfermented feed (R2) and wet anaerobically fermented feed (R3).

All procedures were approved by the IPB ethics committee, letter number 09-2015 IPB.

Statistical analysis: Data were analyzed via an analysis of variance (ANOVA) using the Statistical Package for Social Sciences (IBM® SPSS® version 21.0). To determine the

differences between treatments, a Duncan's Multiple Range Test (DMRT) was performed.

RESULTS AND DISCUSSION

Organic acid content of anaerobically fermented feed: The organic acid contents of the anaerobically fermented feed are shown in Table 2. Fermentation time significantly ($p < 0.05$) increased lactic acid contents due to the growth of LAB. In anaerobic conditions, pathogenic aerobic bacteria would be depressed by the acidic conditions produced by LAB. Glucose and fructose were fermented by LAB into a mixture of acids, the most dominant of which was lactic acid and the high concentration of hydrogen ions inhibited the growth of undesirable microbes¹³. The impact of lactic acid-fermented feed resembles the effects of probiotics, suggesting that using lactic acid as a supplement could improve performance and increase small intestine weight in broilers¹⁴.

Improved acidic conditions, with decreased pH values, would inhibit the growth of pathogenic bacteria that produce ammonia¹⁵. The increased lactic acid content of fermented feed improves feed quality and storability¹⁶ because it inhibits the growth of fungus, molds and aerobic microbes¹⁷. In this study, the content of propionic acid significantly ($p < 0.05$) increased, although not as much as the lactic acid content. The fermentation period is an important parameter because it determines the time needed and cost to produce the feed and to optimize the nutrient content¹⁸ (Fig. 1).

The content of butyric acid was not significantly ($p > 0.05$) affected by fermentation because butyric acid-producing bacteria, such as Clostridia, present at the beginning of rapid fermentation are inhibited under anaerobic conditions and amino acid levels are influenced by bacterial fermentation¹³. Although butyric acid shows antimicrobial activity against pathogens, the success of the anaerobic fermentation process does not depend on the pH and the presence of organic acids alone as shown by studies on dairy products such as yogurt, which have a fermented lactic acid content of 0.78-0.94% but propionic acid only reached 0.002% effectiveness in preventing the growth of microbial pathogens¹⁹.

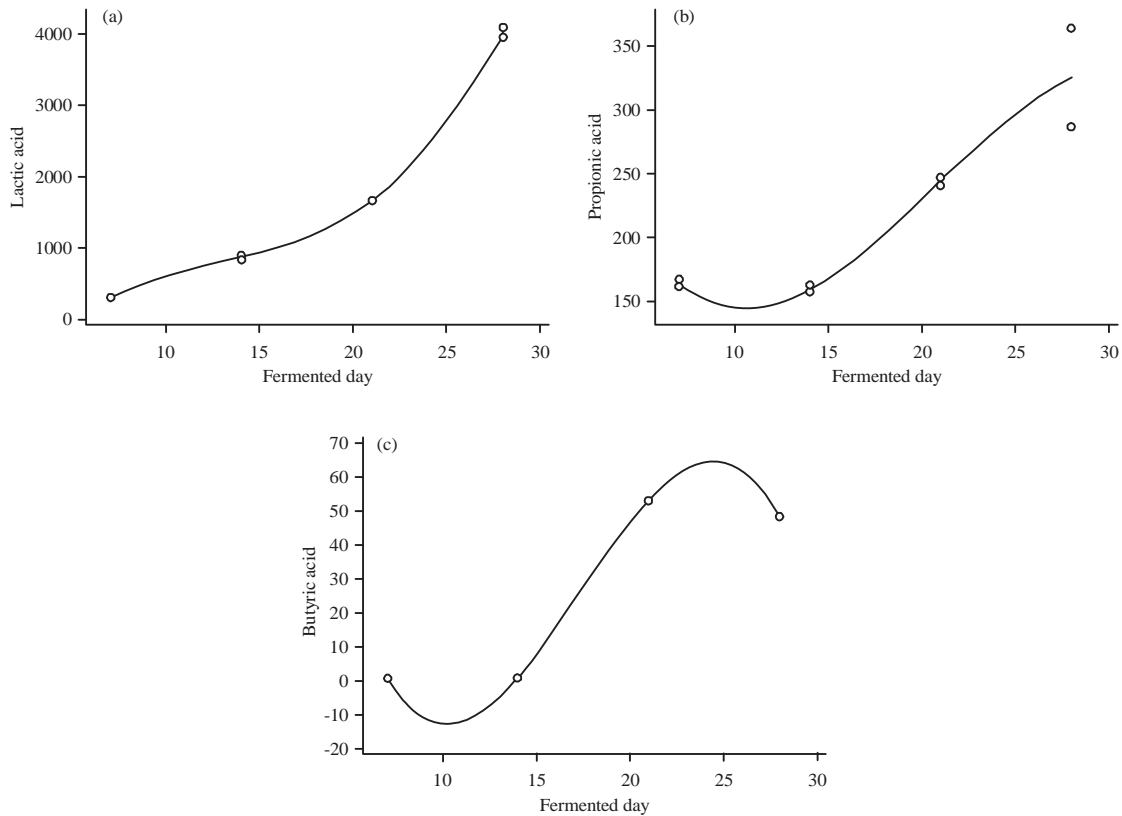


Fig. 1(a-c): Organic acid contents of an aerobically fermented feed

Table 3: *Salmonella enteritidis* inhibition zone

	Time fermented (Days)			
Parameter (mm)	7	14	21	28
Inhibition zone	2.22±0.67	3.56±0.81	3.56±0.81	2.28±1.20

Microbiology Laboratory at Faculty of Veterinary Medicine IPB (2016)

***Salmonella enteritidis* inhibition zone:** A clear zone was formed by the liquid from feed anaerobically fermented for 7-28 days as shown by the data from the 3 replicates in Table 3. The results of this study show that fermented feed liquid is capable of forming a clear zone, although fermentation time did not significantly affect ($p>0.05$) this process. Fluid from anaerobically fermented feed provided at a concentration of 100% inhibited *S. enteritidis* growth due to the presence of organic acids produced by LAB fermentation.

The use of organic acids not derived from fermentation as a feed supplement has been shown to lower the concentration of the coliforms *E. coli* and *Clostridium perfringens* in the small intestine of Khaki Campbell ducks²⁰. Industrially produced organic acid supplements have been shown to be an alternative to antibiotics as growth promoters for turkeys²¹. Finally, *Lactobacillus* sp., from the cloaca of a

hen inhibited *S. enteritidis* *in vitro*, resulting in a clear zone measuring 0.7 to 1.2 cm²².

The ability of anaerobically fermented feed and the liquid derived from it to prevent the growth of *S. enteritidis* shows that fermented feed has antimicrobial properties that could replace the benefits of antibiotics and produce healthy meat products and duck eggs that are safe for human consumption. Organic acids from fermented feed actively inhibited the growth of *S. enteritidis*. Using organic acids produced by fermented feed would also reduce feed costs because the organic acids used as feed additives are added separately. Fermented feed could produce multiple benefits, including increasing the feed storage time¹⁶ and the use of the post-harvest moisture content of fresh ingredients⁸ was able to improve the performance of broiler ducks²³.

Table 4: Ileum surface areas of laying ducks

Parameters (mm)	Treatments		
	R1	R2	R3
Ileum surface area at 6.5 months old	5.180.617	4.869.889	6.233.012
Ileum surface area at 8 months old	3.030.605	2.280.864	3.598.160

Pathology Laboratory at Faculty of Veterinary Medicine IPB (2016), R1: Dry feed, R2: Wet feed without fermentation and R3: Wet feed with anaerobic fermentation

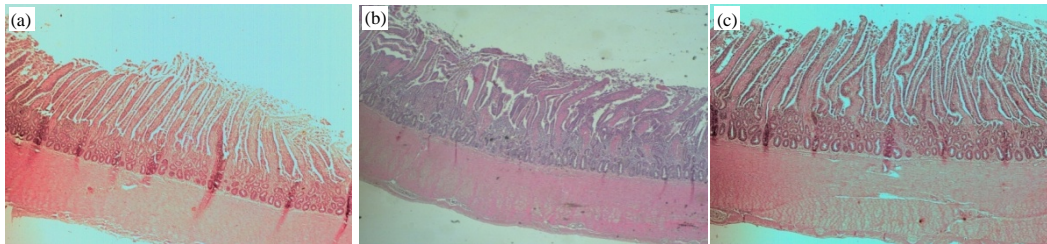


Fig. 2(a-c): Ileum surface area condition of ducks at 6.5 months of age, (a) R1: Dry feed, (b) R2: Wet feed without fermentation and (c) R3: Wet feed with anaerobic fermentation

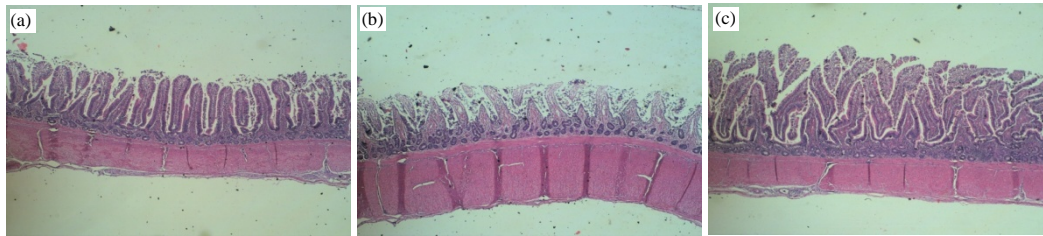


Fig. 3(a-c): Ileum surface area condition of ducks at 8 months of age, (a) R1: Dry feed, (b) R2: Wet feed without fermentation and (c) R3: Wet feed with anaerobic fermentation

Ileum surface area: The ileum surface areas of laying ducks fed feed fermented for 7 days are shown in Table 4. The laying ducks given wet fermented feed (R3) had the largest ileum surface areas when compared with the areas of those given dry feed (R1) and wet unfermented feed (R2). The greater the ileum surface area, the greater the absorption of nutrients, which would help maximize production. Fermented feed contains organic acids that could increase the surface area of the ileum. Studies using organic acids as direct feed additives in broiler chickens have shown increase in the height and width of the villi in the ileum²⁴.

The surface areas of duck ileum are shown in Fig. 2 and 3. The ileum surface areas of laying ducks fed the R3 feed showed higher intestinal villi than were observed in the ileum of ducks given dry feed (R1), which had villi that appeared smaller and were less abundant. The ileum of ducks that received wet feed without fermentation (R2) had irregular and broken villi and had a smaller surface area than did the ileum of ducks that received treatments R1 and R3. The ileum is the point of greatest absorption in the gastrointestinal tract.

Preparing wet feed without fermentation might result in feed becoming contaminated with pathogenic bacteria and this treatment did not maintain the condition of the surface of the ileum of laying ducks.

CONCLUSION

Anaerobically fermented feed contains organic acids, such as lactic acid, propionic acid and butyric acid, which could inhibit pathogenic bacteria such as *S. enteritidis*. The organic acid content of anaerobically fermented feed was able to maintain conditions that caused the surface area of the ileum to become larger, increasing the absorption of nutrients.

SIGNIFICANCE STATEMENT

This study discovered information about the ability of local laying ducks to accept fermented feed and the positive impact this had on increasing the surface area of the villi in the ileum, which can help maximize nutrient absorption. This

research is important because the fermented feed composition in other studies was not 100%. The results of this study prove that anaerobically fermented feed can be given to poultry as the primary feed. Thus, diets consisting only of anaerobically fermented feed can be given to local laying ducks from the age of 5 months on. However, the results of this study are limited because there are no data on using fermented feed in younger ducks.

ACKNOWLEDGMENTS

Gratitude is owed to the Directorate of Research and Community Service and the Directorate General of Higher Education of the Ministry of Education and Culture of Indonesian which funded this study.

REFERENCES

1. Pieper, B., U. Korn and R. Pieper, 2010. New procedures for the conservation of nearly un-fermentable feedstuffs and high moisture grains. Proceedings of the 14th International Symposium of Forage Conservation, March 17-19, 2010, Brno, Czech Republic.
2. Dibner, J.J. and J.D. Richards, 2005. Antibiotic growth promoters in agriculture: History and mode of action. *Poult. Sci.*, 84: 634-643.
3. Gollop, N., V. Zakin and Z.G. Weinberg, 2005. Antibacterial activity of lactic acid bacteria included in inoculants for silage and in silages treated with these inoculants. *J. Applied Microbiol.*, 98: 662-666.
4. Widayastuti, Y., 2008. [Silage fermentation and probiotics benefit of silage to the ruminants]. *Media Peternakan*, 31: 225-232, (In Indonesian).
5. Harahap, A.E., 2011. [Inhibition studies of lactic acid bacteria silage ration side results-based complete corn, cassava and oil]. *J. Peternakan*, 8: 44-48, (In Indonesian).
6. Merryana, F.O., 2007. [Performance and histopathology intestinal of broiler chickens fed by silage and treat by *Salmonella typhimurium*]. M.S. Thesis, Institut Pertanian Bogor, Bogor, Indonesia, (In Indonesian).
7. Akinola, O.S., A.O. Onakomaiya, J.A. Agunbiade and A.O. Oso, 2015. Growth performance, apparent nutrient digestibility, intestinal morphology and carcass traits of broiler chickens fed dry, wet and fermented-wet feed. *Livest. Sci.*, 177: 103-109.
8. Allaily, 2006. [Study of complete silage ration use local feed stuff for male Mojosari Alabio duck]. M.S. Thesis, Institut Pertanian Bogor, Bogor, Indonesia, (In Indonesian).
9. Tien, D.T.M., N.T.B. Tran, B.P.T. Hang and T.R. Preston, 2014. Performance of common ducks fed an ensiled mixture of banana pseudo-stem and taro (*Colocasia esculenta*) foliage as a supplement to restricted rice bran and *ad libitum* fresh duckweed. *Livest. Res. Rural Dev.*, Vol. 26.
10. Li, Y., F. Wang and N. Nishino, 2016. Lactic acid bacteria in total mixed ration silage containing soybean curd residue: Their isolation, identification and ability to inhibit aerobic deterioration. *Asian-Aust. J. Anim. Sci.*, 29: 516-522.
11. Franco, L.G. and D.E. Faria, 2010. Organic acids as alternative to antimicrobial growth promoter in broilers. Proceedings of the International Poultry Scientific Forum, January 25-26, 2010, Georgia World Congress Center, Atlanta, GA., USA.
12. Allaily, N. Ramli and R. Ridwan, 2011. [The quality of complete ration silage use traditional local feed materials]. *J. Agripet*, 11: 35-40, (In Indonesian).
13. McDonald, P., A.R. Henderson and S.J.E. Heron, 1991. *The Biochemistry of Silage*. 2nd Edn., Chalcombe Publications, Marlow, Bucks, UK., ISBN-13: 9780948617225, Pages: 340.
14. Adil, S., T. Banday, G.A. Bhat, M.S. Mir and M. Rehman, 2010. Effect of dietary supplementation of organic acids on performance, intestinal histomorphology and serum biochemistry of broiler chicken. *Vet. Med. Int.* 10.4061/2010/479485
15. Flythe, M.D and J.B. Russell, 2006. Fermentation acids inhibit amino acid deamination by *Clostridium sporogenes* MD1 via a mechanism involving a decline in intracellular glutamate rather than proton motive force. *Microbiology*, 152: 2619-2624.
16. Wildan, F., 2005. Determination of lactic acid levels in the silage and liquid rumen by gas chromatography. Proceedings of the National Technical Meeting of Agricultural Functional Staff, August 3, 2004, Centre for Research and Development of Animal Husbandry, Indonesia, pp: 100-103.
17. Muck, R.E., 2010. Silage microbiology and its control through additives. *R. Bras. Zootec.*, 39: 183-191.
18. Mohd-Setapar, S.H., N. Abd-Talib and R. Aziz, 2012. Review on crucial parameters of silage quality. *APCBEE Procedia*, 3: 99-103.
19. Suomalainen, T.H. and A.M. Mayra-Makinen, 1999. Propionic acid bacteria as protective cultures in fermented milks and breads. *Lait*, 79: 165-174.
20. Koley, S. and G. Samanta, 2012. Effect of organic acid supplementation on feed quality, performance, gastrointestinal milieu and blood minerals of Khaki Campbell ducks. *Anim. Nutr. Feed Technol.*, 12: 187-197.
21. Milbradt, E.L., A.S. Okamoto, J.C.Z. Rodrigues, E.A. Garcia, C. Sanfelice, L.P. Centenaro and R.L. Andreatti Filho, 2014. Use of organic acids and competitive exclusion product as an alternative to antibiotic as a growth promoter in the raising of commercial Turkeys. *Poult. Sci.*, 93: 1855-1861.

22. Miyamoto, T., T. Horie, T. Fujiwara, T. Fukata, K. Sasai and E. Baba, 2000. *Lactobacillus* flora in the cloaca and vagina of hens and its inhibitory activity against *Salmonella enteritidis in vitro*. *Poult. Sci.*, 79: 7-11.
23. Ridla, M., Allaily, F.K. Nikmah and N. Ramli, 2014. Performance of Mojosari Alabio males ducks fed complete ration silage. *Anim. Prod.*, 16: 176-182.
24. Mohamed, M.A., E.F. El-Daly, N.A. Abd El-Azeem, A.W. Youssef and H.M.A. Hassan, 2014. Growth performance and histological changes in ileum and immune related organs of broilers fed organic acids or antibiotic growth promoter. *Int. J. Poult. Sci.*, 13: 602-610.
25. Leeson, S. and J.D. Summers, 2005. *Commercial Poultry Nutrition*. 3rd Edn., University Books, Guelph, Ontario, Canada, ISBN-13: 9780969560050, Pages: 398.