



Journal of Applied Sciences

ISSN 1812-5654

science
alert

ANSI*net*
an open access publisher
<http://ansinet.com>

Gingival Ancient Schwannoma: Review of Literature and a Case Report

¹M. Amirchaghmaghi, ²J. Salehinejad, ³M. Basirat,
¹Z. Delavarian, ¹A. Javadzade and ⁴A. Forouzanfar

¹Oral Medicine and Dental Research Center,

²Oral and Maxillofacial Pathology and Dental Research Center,

School of Dentistry, Mashhad University of Medical Sciences, Mashhad, Iran

³Department of Oral Medicine, School of Dentistry,

Mashhad University of Medical Sciences, Mashhad, Iran

⁴Department of Periodontology and Dental Research Center,

School of Dentistry, Mashhad University of Medical Sciences, Mashhad, Iran

Abstract: Schwannoma is usually a solitary slow growing and encapsulated soft tissue or intrabony lesion. This tumor is often associated with the nerve sheath. Only a few ancient schwannomas have been reported in different parts of head and neck and in the gingiva, this tumor is very rare. In this report, a 14-year-old male patient with an ancient schwannoma of gingiva discussed. he was referred to oral medicine department of Mashhad dental school with Chief complaint of an asymptomatic enlargement of gingiva and histopathologic examination recommended. Based on clinical, histologic and immunohistochemical findings, the diagnosis of ancient schwannoma was made Ancient schwannoma is very rare in gingiva but the dentist must note the clinical presentation of periodontitis and any gingival enlargement should not be considered periodontitis. The purpose of this study is report of a rare case of ancient schwannoma in gingiva and a review of ancient schwannomas in literature.

Key words: Schwannoma, oral, gingiva, neurilemmoma, ancient

INTRODUCTION

Schwannoma also known as neurilemmoma is benign nerve sheath tumor arise from perineural schwann cells of the nerve sheath (Bayindir *et al.*, 2006; Subhashraj *et al.*, 2009; Yang and Lin, 2003; Neville *et al.*, 2009).

Histologically five variants of schwannomas including common, plexiform, cellular, epithelioid and ancient schwannoma have been described (Weiss, 2001).

Ackerman and Taylor were the first who described the term Ancient Schwannoma 1951. They defined that significant portion of these neurilemmomas were composed of only few cells within a hyalinized matrix (Bayindir *et al.*, 2006; Subhashraj *et al.*, 2009) about 25 to 45% of all schwannomas are found in the head and neck but only 1% have an intraoral origin (Bayindir *et al.*, 2006; Farzadnia *et al.*, 2007; Lopez-Carriches *et al.*, 2009; Pfeifle *et al.*, 2001). This tumor can be presented as a slowly enlarging painless mass in soft tissue or bone (Subhashraj *et al.*, 2009; Lopez-Carriches *et al.*, 2009; Scully, 2008).

Neurilemmomas in oral cavity show a predilection for the tongue. The palate, buccal mucosa, lip and gingiva are also affected in decreasing order (Pfeifle *et al.*, 2001). Ancient schwannoma is a rare benign neoplasm of the gingiva and to our knowledge this case report is the second case of gingival ancient schwannoma in Iran and English Articles.

CASE REPORT

A 14-year-old male patient was referred by a general dentist to oral medicine department of Mashhad Dental School in Desember 2009. Chief complaint of the patient was an asymptomatic enlargement of his gingiva during the past year. The patient's medical and family history was unremarkable. Extraoral examination was not contributory. Intraoral examination revealed gingival enlargement and mobility of right mandibular canine tooth. A firm and non tender mass, measuring approximately 1.5 cm in diameter was seen that covered by normal mucosa (Fig. 1).

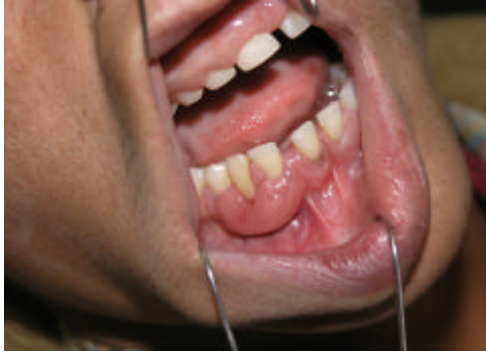

Fig. 1: Intra oral view: The tumor in the first premolar region with intact mucosa and gingival enlargement in maxilla and other parts of mandible

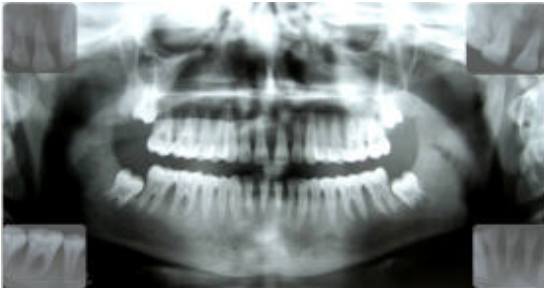

Fig. 2: Orthopantograph and periapical radiography revealed generalized alveolar crest bone loss especially in the anterior parts of jaws and loss of lamina dura in some of teeth

In other regions (from right lateral incisor up to left first premolar), mild gingival enlargement was seen. There were many carious teeth and calculus. Right central incisor and first molar, right and left lateral incisor, were mobile. No neurological abnormality was noted. All the teeth responded positively to pulp testing.

In the maxilla, gingival enlargement was seen in the anterior sextant. Left central incisors and right central and lateral incisor in maxilla was mobile. Orthopantograph and periapical radiography revealed generalized alveolar crest bone loss especially in anterior parts of the jaws and lamina dura was absent in some of teeth (Fig. 2). Provisional diagnosis was periodontitis but due to loss of lamina dura, blood tests (CBC, Ca, p, ALP) and urine analysis were performed to rule out hyperparathyroidism. All of them except ALP were normal. Probable diagnosis of periodontitis was made and patient referred to periodontist. The gingival mass of mandibular canine region was not consistent with periodontitis. So, neurofibroma was under consideration for this lesion (for the reason that the patient was teenager) and

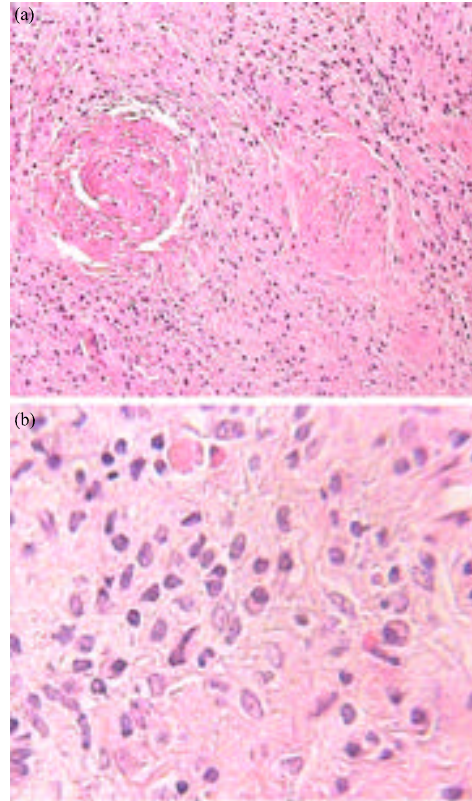


Fig. 3: (a, b) Bizarre Schwann cells with hyalinization

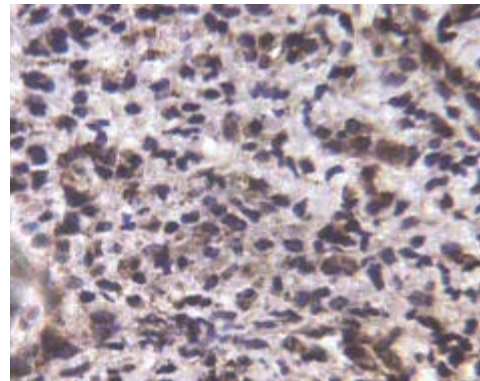


Fig. 4: Immunostaining with anti-S-100 protein. Benign schwannomatous components were positive for S-100 protein in the cellular areas

histopathologic examination as well as periodontal therapies recommended. On microscopic examination, an encapsulated tumor was seen in the gingiva (Fig. 3a, b). The tumor showed solid cellular and hypocellular areas and a large cystic space. The medium and high power fields showed tumor cells that were spindle shaped with twisted nuclei and indistinct cytoplasmic borders. They

were arranged in short bundles or palisades. Degenerative changes including Hyalinization and calcification was also seen.

Immunohistochemical investigation revealed diffuse, strong positive staining for S-100 protein (Fig. 4). Based on these findings, the diagnosis of ‘ancient schwannoma was made.

DISCUSSION

Schwannomas are encapsulated tumors of the neurilemma that can enlarge slowly with minimal symptom (Bayindir *et al.*, 2006). Histologically this tumor is composed of spindle cells forming highly cellular areas (Antoni A) and less cellular area (Antoni B) (Bayindir *et al.*, 2006; Subhashraj *et al.*, 2009). Long standing (Ancient) schwannoma may undergo degenerative changes with large cystic myxoid areas and bizarre spindle cells (Subhashraj *et al.*, 2009). In ancient Schwannoma, the area with hyper cellularity and atypia may lead the erroneous diagnosis of a malignant lesion (Subhashraj *et al.*, 2009).

In this case, the tumor was encapsulated and composed of both solid and cystic areas similar to previous reports. Ancient Schwannoma rarely occur in the head and neck and this tumor is extremely rare in gingiva and to the base of our knowledge, it is the second report of ancient schwannoma in gingiva

Reviewing the literature revealed only eleventh cases of ancient Schwannoma that there were in palate, floor of the mouth, tongue, upper lip, mandible and maxillary vestibular region and gingiva (Table 1). The age of these patients were between 9 to 55 years (Mean age 30.5) and were predominant in female. Recurrence and malignant transformation were not reported in any of intraoral ancient Schwannomas (Bayindir *et al.*, 2006).

The provisional diagnosis after clinical examination was periodontitis because of bone loss and pockets in

different parts of the gingiva. After clinical examination, we suspected hypophosphasia or hypophosphemia because of bone loss, tooth mobility and loss of lamina dura but tooth structural defect was absent and so these diagnoses were excluded. Loss of lamina dura with increased ALP can be seen in hyperparathyroidism. More investigation revealed loss of lamina dura is radiographic error. Blood tests (CBC, ca, p) and urine analysis were normal and Increased ALP might be dependent on physiologic changes at that age. Clinical diagnosis of periodontitis was made. Inflammation, drugs (such as anticonvulsants, immunosuppressants, ca-channel blockers), conditions (such as puberty, pregnancy vitamin c deficiency) and neoplasms can cause gingival enlargement. Gingival enlargement of puberty is usually limited to facial parts of the jaws (Newman *et al.*, 2006). Our patient neither had any systemic disease nor taking any medicine. Poor oral hygiene and calculus may be the main cause of gingival enlargement and puberty can exacerbate this condition probable diagnosis for gingival mass in mandibular canine was neurofibroma due to age of the patient. Although, this mass may lead to food retention and exacerbate periodontitis in this region. Periodontitis can also lead to gingival enlargement but the dentist must note the clinical presentation of periodontitis and any gingival enlargement should not be considered periodontitis. In histological study traumatic neuroma, solitary neurofibroma, neurofibromatosis and malignant Schwannoma were under consideration as differential diagnosis.

Immunohistochemical test revealed the Schwann cell to be positive for the protein S100, a marker for the nervous system (Greenberg and Glick, 2008; Farzadnia *et al.*, 2007; Lopez-Carriches *et al.*, 2009). Ultrasonography, CT and MRI may be helpful in diagnosis and treatment (Martins *et al.*, 2009). In this case incisional biopsy was made to establish the diagnosis. Histopathologic and immunohistochemical study revealed

Table 1: Reported cases of Ancient schwannoma in oral cavity

Duration	Size (mm)	Location	Sex	Age	References
Not known	25	Floor of the mouth and ventral of tongue	F	58	Eversole and Howell (1971)
Not known	35	Floor of the mouth	F	65	Marks <i>et al.</i> (1976)
Not known	20	Maxillary posterior vestibule	F	36	McCoy <i>et al.</i> (1983)
Not known	9	Maxillary vestibule	F	52	Dayan <i>et al.</i> (1989)
2 month	55	Floor of the mouth and ventral of tongue	F	40	Nakayama <i>et al.</i> (1996)
5 month	30	Floor of the mouth and ventral of tongue	F	21	Ledesma <i>et al.</i> (1999)
3 month	40	Floor of the mouth	F	55	Zehlicke <i>et al.</i> (2006)
18 year	30	Floor of the mouth	M	34	Chen <i>et al.</i> (2006)
23 years	NA	Buccal mucosa	NA	NA	Tobita <i>et al.</i> (2008)
8 month	31	Mandibular posterior vestibule	M	18	Subhashraj <i>et al.</i> (2009)
5 year	19	Mandibular gingiva	M	40	Salehinejad <i>et al.</i> (2009)

Schwann cells and positive reaction for S100 protein. The prognosis of Schwannoma is quiet favorable and conservative surgical removal is the treatment of choice (Yang and Lin, 2003).

CONCLUSION

Ancient schwannoma is uncommon in the head and neck region and extremely rare in the gingiva. This could be the second reported case of ancient schwannoma arising from the gingiva found in a 14 years old male patient which was presented for one year. Complete excision of the lesion was done by the periodontist under local anesthesia and there was no evidence of recurrence after 6 months.

It is important that dentists should be considered schwannomas in the differential diagnosis of any gingival mass, when other etiologic factors of gingival enlargement is ruled out.

REFERENCES

- Bayindir, T., M.T. Kalcioğlu, A. Kizilay, N. Karadag and M. Akarcay, 2006. Ancient schwannoma of the parotid gland: A case report and review of the literature. *J. Craniomaxillofac. Surg.*, 34: 38-42.
- Chen, C.Y., W.C. Wang, C.H. Chen, Y.K. Chen and L.M. Lin, 2006. Ancient schwannoma of the floor of the mouth – A case report and review. *Oral Oncol. (EXTRA)*, 42: 281-285.
- Dayan, D., A. Buchner and A. Hirschberg, 1989. Ancient neurilemmoma (Schwannoma) of the oral cavity. *J. Craniomaxillofac. Surg.*, 17: 280-282.
- Eversole, L.R. and R.M. Howell, 1971. Ancient neurilemmoma of the oral cavity. *Oral Surg. Oral Med. Oral Pathol.*, 32: 440-443.
- Farzadnia, M., M. Bakhshae and R. Badiei, 2007. Schwannoma of the tongue base: A case report. *Iranian J. Pathol.*, 2: 119-122.
- Greenberg, M.S. and M. Glick, 2008. *Burket's Oral Medicine*. 11th Edn., BC Decker Inc., Hamilton, Ontario, pp: 141.
- Ledesma, C., J. Portilla, F. Hernandez, M. Garces and J.C. Hernandez, 1999. Paraglandular ancient schwannoma. *Med. Oral*, 2: 398-402.
- Lopez-Carriches, C., R. Baca-Perez-Bryan and S. Montalvo-Montero, 2009. Schwannoma located in the palate: Clinical case and literature review. *Med. Oral Patol. Oral Cir. Bucal.*, 14: 465-468.
- Marks, R.K., R.F. Carr and A.J. Kreller, 1976. Ancient neurilemmoma of the floor of the mouth: Report of a case. *J. Oral Surg.*, 34: 731-735.
- Martins, M.D., L. Anunciato de Jesus, K.P. Fernandes, S.K. Bussadori, S.A. Taghloubi and M.T. Martins, 2009. Intra-oral schwannoma: Case report and literature review. *Indian J. Dent. Res.*, 20: 121-125.
- McCoy, J.M., H.H. Mincer and J.E. Turner, 1983. Intraoral ancient neurilemmoma (ancient schwannoma). Report of a case with histologic and electron microscopic studies. *Oral Surg. Oral Med. Oral Pathol.*, 56: 174-184.
- Nakayama, H., R. Gobara, F. Shimamoto and H. Kajihara, 1996. Ancient schwannoma of the oral floor and ventricular portion of the tongue: A case report and review of the literature. *Jpn. J. Clin. Oncol.*, 26: 185-188.
- Neville, B.W., D.D. Damm, C.M. Allen and J.E. Bouquet, 2009. *Oral and Maxillofacial Pathology*. 3rd Edn., Saunders Elsevier, Philadelphia, pp: 438-439.
- Newman, M.G., H.H. Takei, P.R. Klokkevold and F.A. Carranza, 2006. *Carranza Clinical Periodontology*. 10th Edn., Saunders Elsevier, Philadelphia, pp: 373-388.
- Pfeifle, R., D.A. Baur, A. Paulino and J. Helman, 2001. Schwannoma of the Tongue: Report of 2 Cases. *J. Oral Maxillofac. Surg.*, 59: 802-804.
- Salehinejad, J., R. Zare Mahmoodabadi, F. Babazadeh, S.H. Saghafi and H. Kade, 2009. Ancient schwannoma of oral cavity: A case report. *Iranian J. Otorhinolaryngol.*, 21: 101-104.
- Scully, C., 2008. *Oral and Maxillofacial Medicine, the Basis of Diagnosis and Treatment*. 2nd Edn., Churchill Livingstone, Toronto, pp: 362-363.
- Subhashraj, K., S. Balanand and S. Pajaniammalle, 2009. Ancient schwannoma arising from mental nerve. A case report and review. *Med. Oral Patol. Oral Cir. Bucal.*, 14: 12-14.
- Tobita, T., H. Ikeda, S. Fujita, M. Ikeda, S. Ohba and K. Shibahara, 2008. Ancient schwannoma in the buccal region. *Asian J. Oral Maxillofacial Surg.*, 20: 139-143.
- Weiss, S.W., 2001. *Enzinger and Weiss's Soft Tissue Tumors*. 4th Edn., Saint Louis Missouri, Mosby, pp: 1146-1167.
- Yang, W. and S.W. Lin, 2003. Schwannoma of the upper lip: Case report and literature review. *Am. J. Otolaryngol.*, 24: 351-354.
- Zehlicke, T., M. Lessle and L. Gramer, 2006. The ancient schwannoma. A rare tumor of the mouth floor. *HNO.*, 54: 307-311.