



Journal of Applied Sciences

ISSN 1812-5654

science
alert

ANSI*net*
an open access publisher
<http://ansinet.com>



Research Article

Acute Toxicity Study and Determination of Median Lethal Dose of *Catharanthus roseus* in Wistar Albino Rats

¹M.G. Ajuru, ²G. Ajuru, ¹F.W. Nmom, ¹C.W. Worlu and ¹P.G. Igoma

¹Department of Plant Science and Biotechnology, Faculty of Science, Rivers State University, Nkpolu-Oroworukwo, P.M.B. 5080, Rivers State, Nigeria

²Department of Anatomical Pathology, Faculty of Basic Medical Science, University of Port Harcourt Teaching Hospital, Choba, Port Harcourt, Rivers State, Nigeria

Abstract

Background and Objective: Herbs were utilized by mankind since the ancient past, as alternative medicines for treatment of various diseases due to their presumed trustworthiness, efficacy, safety and low price. *Catharanthus roseus* (L.) G. Don is well known for its medicinal properties, like antibacterial, antifungal and antiviral. It is widely used in traditional medicine in India, Nigeria and West Indies to control diabetes mellitus. Toxicity studies serve as a preliminary study for identification of hazard and evaluation of the safety of any drug. This research was carried out to evaluate the acute toxic effects of ethanol leaves extract of *C. roseus* and to determine its median lethal dose (LD₅₀). The objective was to investigate the toxicity of the leaves extract on the liver and biochemical parameters in rats.

Materials and Methods: Single oral doses of the ethanol leaf extract of *C. roseus* was administered to albino rats at the concentrations 0, 1900, 3000 and 5000 mg kg⁻¹. The animals were humanely sacrificed and blood and tissues obtained for biochemical and histological analysis on liver tissues. **Results:** The results revealed no significant changes in the control group but in the treatment group, there were changes such as dizziness, tremors and restlessness especially in treatment group D. Biochemical analysis showed normal alanine transaminase (ALT) levels in all treatment groups except in treatment group D where the level was significantly low (19 μ L⁻¹). Aspartate transaminase (AST) was elevated in all treatment groups. Protein level was normal for all treatment groups except treatment group D where it was significantly low (26). Histological results showed normal liver tissues with hepatocytes, sinusoids and central veins. In treatment group B, there was tissue fragmentation with mild degeneration. In Group C, there was congestion in the central vein, vacuolation, fatty, changes and necrosis of hepatocytes and connective tissues but in Group D, there were necrotic tissues in the liver.

Conclusion: In this study, no mortality was recorded, therefore, the LD₅₀ of the plant extract is slightly higher than 5000 mg kg⁻¹ which can lead to mortality. It is recommended that studies on higher doses than the one in this study should be carried out to determine the actual LD₅₀ of the drug.

Key words: *Catharanthus roseus*, ethanol leaf extract, biochemical study, histological study, Albino rats

Citation: M.G. Ajuru, G. Ajuru, F.W. Nmom, C.W. Worlu and P.G. Igoma, 2019. Acute toxicity study and determination of median lethal dose of *Catharanthus roseus* in Wistar albino rats. J. Applied Sci., 19: 217-222.

Corresponding Author: M.G. Ajuru, Department of Plant Science and Biotechnology, Faculty of Science, Rivers State University, Nkpolu-Oroworukwo, P.M.B. 5080, Rivers State, Nigeria Tel: +2347036834588

Copyright: © 2019 M.G. Ajuru *et al.* This is an open access article distributed under the terms of the creative commons attribution License, which permits unrestricted use, distribution and reproduction in any medium, provided the original author and source are credited.

Competing Interest: The authors have declared that no competing interest exists.

Data Availability: All relevant data are within the paper and its supporting information files.

INTRODUCTION

Catharanthus roseus, also known as *Vinca rosea* belongs to the family Apocynaceae. It is native to the Caribbean Basin and has been used to treat different diseases. Decoction of the leaves and/or the whole plant is used as household remedy for diabetes in several countries¹. Traditionally, in India seven flowers/leaves are used at a time while in the Cook Islands, seven leaves boiled in a kettle of water is used but in West Indies, roots of plants are infused in whiskey to control diabetes²⁻⁴. Earlier reports indicate significant blood glucose lowering activity with hydroalcoholic or dichloromethane-methanol extracts of leaves of *C. roseus* in laboratory animals⁵⁻¹¹.

It has more than 400 known alkaloids, some of which are approved as antineoplastic agents to treat leukemia, Hodgkin's disease, malignant lymphomas, neuroblastoma, rhabdomyosarcoma, Wilms' tumor and other cancers. Its vasodilating and memory-enhancing properties have been shown to alleviate vascular dementia and Alzheimer's disease^{12,13}. The major alkaloid is vincamine and its closely related semi-synthetic derivative widely used as a medicinal agent, known as ethyl-apovincamate or vinpocetine, has vasodilating, blood thinning, hypoglycemic and memory-enhancing actions^{10,14}. The extracts of *Vinca* have demonstrated significant anticancer activity against numerous cell types¹⁵.

Studies reveal that rose periwinkle contains vasodilating (widening of blood vessels) and memory-enhancing properties, which help to tackle vascular dementia and Alzheimer's disease. Fischhof *et al.*¹² investigated the therapeutic effects of vincamine for treating primary degenerative and vascular dementia.

According to Jaleel *et al.*¹⁶, the anticancer alkaloids (vinblastine and vincristine) found in the leaf and stem of *C. roseus* inhibits cancer and tumour cells in the body.

Nayak *et al.*¹⁷ carried out an experiment where rats were treated with 100 mg kg⁻¹/day of the *C. roseus* ethanol extract. These treated rats recorded high rate of wound contraction that significantly reduced the epithelization (process of covering a denuded surface with epithelium) period. The study supports the efficacy of *C. roseus* for treating and healing wounds.

Patil and Ghosh¹⁸ investigated some of the antimicrobial properties of the rosy periwinkle plant. The results show that the leaves extract can be used as a prophylactic (preventive) agent against several diseases.

Ethalsha and Retna¹⁹ examined the antibacterial properties of the crude extracts obtained from the roots of

C. roseus against several bacterial species of clinical significance. The root part of this plant was extracted in an appropriate solvent followed by the evaluation of the antibacterial effects using agar well diffusion assay against a total of 8 bacterial strains.

Patharajan and Balaabirami²⁰ assessed the antioxidant effectiveness of *C. roseus* leaves extracts and the fractions with solvents of various polarity (water, ethanol, methanol, butanol, acetone and hexane). The rosy periwinkle extracts and the fractions contained significant levels of antioxidants at various concentrations.

The results show that *C. roseus* extracts and fractions are an excellent source of natural antioxidants and could be utilized as a functional food or used for nutraceutical purposes.

Kumari and Gupta²¹ examined the antifungal properties of *C. roseus* against several clinically significant fungal strains namely; *Fusarium moniliforme*, *Candida albicans*, *Aspergillus niger* and *Aspergillus fumigatus*. The data showed that the pattern of inhibition is highly dependent on the extraction solvent. The organic extracts demonstrated more significant antifungal activity, unlike the aqueous extracts.

Zaini and Normala²² reported that the white root disease caused by the *Rigidoporus microporus* fungus is the most destructive disease found in a rubber plantation. Biological control using stems extract of *C. roseus* can be used as a healing agent of infected rubber trees.

According to Zaini and Normala²², *C. roseus* is regarded as a poisonous plant because of the presence of danvinrosidin, catharanthine, vindolinine, leurosine, akuammine, norharman, lochnerine, vinleurosine, tetrahydroalstonine, vindoline and vincamine in it. Furthermore, this plant can be quite toxic if excessively consumed orally thus only the recommended dosages should be consumed. This research was carried out to ascertain the dosage of *C. roseus* safe for human consumption and to contribute to the body of knowledge on this important herbal drug.

MATERIALS AND METHODS

Plant sample collection: The leaves of *C. roseus* was collected in the month of April, 2018 from the chapel of redemption, Rivers State University, Nkpolu, Port Harcourt and was conveyed to the Department of Plant Science and Biotechnology Rivers State University. It was identified and authenticated by Dr. M.G. Ajuru a plant taxonomist in the Department. Thereafter the plant leaves collected were air dried at room temperature (37°C) for a period of 30 days and them grounded to get in a fine powder.

Preparation of ethanol extract: The *C. roseus* powdered sample (41.5 g) was extracted with 600 mL of 95% ethanol and allowed to stay overnight before filtration with a Whatman filter paper. The filtrate was further evaporated to dryness with the use of electric hot plate and conical flask.

Experimental animals: The experimental animals used were Wistar Albino rats. The rats were purchased from a vendor in Delta State and transported down to Rivers State University; the rats purchased were mixed that is both male and female rats totaling 16 Wistar Albino rats. These rats were fed and kept under laboratory condition for acclimatization. They were separated into 4 cages with each cage containing 4 rats. The rats were weighed before, during and after the treatment.

Acute toxicity study: The acute toxicity of *C. roseus* was evaluated in rats (180-200 g). Four groups containing 4 rats each randomly selected according to their average body weight received ethanol extracts at dose of 0 (Group A) also known as the control, its driving agent was water; 1900 (Group B), 3000 (Group C) and 5000 (Group D) all measured in mg kg⁻¹ b.wt., the extracts were administered orally (via the mouth) to the rats using a syringe after a short fasting period.

The general behavior of the animals was continuously monitored during the first 24 h with special attention given within the first 4 h and daily thereafter for a total of 14 days. The detailed cage-side observation included basically general weakness and thirst amongst the rats. Special attention was directed to itching and diarrhea but there was no visible change. Surviving animals after the 14 days were weighed and humanely sacrificed and blood samples collected for hematological (blood) and histological (kidney) analysis.

Biochemical study: For biochemical study, sera were obtained by centrifuging the blood samples and storing them at 20 until the assays could be completed. Total protein concentration was estimated by the method in Lu²³, Aspartate aminotransferase (AST) and alanine aminotransferase (ALT) levels were determined colourimetrically according to Mahadevaswami *et al.*²⁴.

Histological study: For histological study, the kidneys were harvested, fixed in 10% formaldehyde processed through three changes of alcohol and xylene, infiltrated and embedded in paraffin wax. The tissue blocks were later section at 5 µm thickness and stained with Haematoxylin and Eosin.

The tissue sections photomicrographs were obtained using AmScope digital microscope attached on an Olympus microscope eye piece.

RESULTS

Effects of ethanol leaf extract of *C. roseus* on the body weight of rats treated:

The rats were weighed before and after the administration of the ethanol leaf extract of the plant. Table 1 showed the effects of the extract of *C. roseus* on the body weight of rats which includes the initial weight, final weight and weight changes in the control group and treatment groups. The weight gain was high in treatment groups C, D and control group but low in treatment group B.

Physical and behavioral changes: There were no significant changes observed in the Wistar rats in the control group before they were sacrificed. The Wistar rats in this group remain active throughout the duration of the study. There was no loss of appetite and they responded very well to stimuli.

But within the first 4 h of the administration of the ethanol extract of leaf of *C. roseus*, the Wistar rats in the treatment groups started showing signs of tremor, itching, restlessness, quietness, dull appearance, nausea, general body weakness and some trying to escape from the cage. There was no death recorded in the treatment and control group.

The degree of observable signs/effects depends on the concentration of the extract administered, more effects and signs were observed at higher dosage.

Based on these facts and the absence of death among the Wistar rats used in the study, it implies that the LD₅₀ of *C. roseus* is quite above the concentration used in this study. There was significant changes in the body weight of Wistar rats treated with leaf extract of *C. roseus* when compared with the normal group.

Biochemical analysis: The results of changes in biochemical parameters of the albino rats used in the study is presented

Table 1: Effects of ethanol leaf extract of *C. roseus* on the body weight of Wistar rats treated at dosages of 1900, 3000 and 5000 mg kg⁻¹

Groups	Treatment (mg kg ⁻¹)	Initial weight (g)	Final weight	Weight change
A	0	150	215	65
B	1900	150	190	40
C	3000	150	250	100
D	5000	150	250	100

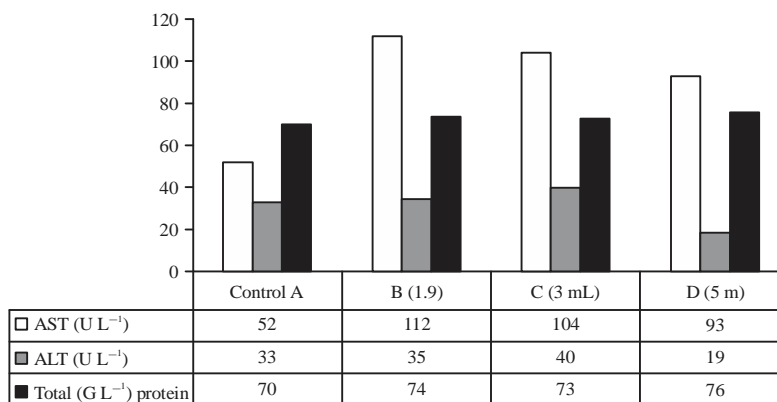


Fig. 1: Changes in biochemical parameters in the Wistar rats studied

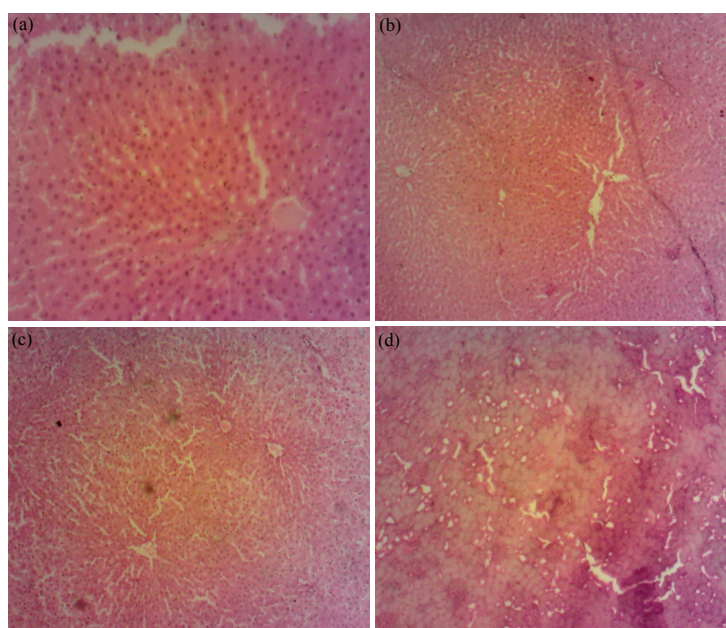


Fig. 2: Effect of ethanol leaf extract of *C. roseus* on the liver of wistar rats

Group A (control): Normal liver tissues with hepatocytes, sinusoids and Central veins (cv), Group B: Tissue fragmentation with mild degeneration with vacuolation, Group C: Congested central vein, vacuolation, fatty change and necrosis of hepatocytes and connective tissues, Group D: Total tissue damage with necrosis

in Fig. 1. The parameters examined were Aspartate aminotransferase (AST), Alanine aminotransferase (ALT) and total proteins. The level of AST in the treatment group was significantly higher, compared to the control group. It was highest in treatment group B (112 μL^{-1}), followed by treatment group C (104 μL^{-1}) and treatment group D (93 μL^{-1}). The changes in the levels of ALT and total proteins in the treatment groups were not significant, except in treatment group D where the level of ALT was significantly low (19 μL^{-1}) compared to the control group and total protein was equally low (26) compared to the control group.

Histopathological result: In group A (control), the section showed normal liver tissues with hepatocytes, sinusoids and central veins. In group B (treatment with 1900 mg kg⁻¹ of ethanol leaf extract of *C. roseus*), there was tissue fragmentation with mild degeneration including vacuolation. Group C (treatment with 3000 mg kg⁻¹ of ethanol leaf extract of *C. roseus*), tissues sections shows congestion in the central vein, vacuolation, fatty, changes and necrosis of hepatocytes and connective tissues. But in Group D (500 mg kg⁻¹), there was total tissue damage of the liver with necrosis as shown in Fig. 2.

DISCUSSION

Herbal drugs have gained importance globally. Since the Advent past, man has used plants to treat common diseases even before the discovery of microbes. Fossils records date back the use of plants by man for various purposes including plant poison for obtaining fish from water bodies. This is of great concern because of the adverse effects on the aquatic organisms. Most fish poison also called ichthyotoxins or piscicides has been identified in related plants species. A variety of chemicals found in these plants will stun fish when ingested making the fish to float to the surface for easy capture.

The *C. roseus* is widely used as an antidiabetic, antihypertensive and in the treatment of infection. The aerial parts of the plant contain about 90 different alkaloids. The isolation and purification of these indole alkaloids have been extensively studied. Most of these alkaloids are used in cancer chemotherapy.

Available literature revealed no published report on the toxicity of *C. roseus* in humans despite the widespread use of the plant in various herbal remedies. In this study, oral administration of the ethanolic extract of *Catharanthus roseus* to rats produced no observable toxicity in the liver in the applied dosages.

Toxicity evaluation is necessary to establish how safe a drug is for human consumption. In the pharmaceutical industries, acute toxicity tests are usually conducted on any drug before it is released into the market.

Toxicity is an indication of a substance being poisonous, pointing to the state of adverse effects led by the interactions between toxicants and cells. High dosage of some plants extracts has the potential to cause serious toxic effects. However, toxicity test is not comprehensive enough and other parameters like biochemical and histological analysis are usually carried out together to evaluate specific organ damage and causes of death in any study. Toxicity tests in conjunction with photomicrographs of stained and processed histological, tissue sections provide a clue as to the toxic characteristics of the drug or plant²⁵.

It was observed during the study that the plant extract had the capacity to reduce the body weight of treated animals. Significant decreased in weight was observed in Wistar rats treated with (1900 and 3000 mg kg⁻¹ b.wt.) those treated with 5000 mg kg⁻¹. This may not be unconnected with the low total protein levels observed in rats treated with 5000 mg kg⁻¹. There is the possibility of the extract interfering with proteins synthesis.

Histological examinations of the livers of these animals showed intact normal histological features. Histological

sections of the livers of treated rats shows no feature of cellular damage, since the sinusoids in the sections of the treated animals were devoid of congestion and were not waterlogged. There was no necrosis or edema of the hepatocytes except in the Group C and D. The portal tracts were free of inflammation.

It is a well known fact that when certain types of cells are damaged, the intracellular enzymes they contain may be released into the blood. Elevation of these enzymes is used as markers for injury to these organs. Alanine aminotransferase (ALT) is one such enzymes, it is markedly elevated in acute parenchyma liver damage. The enzyme aspartate aminotransferase (AST) has a similar role but it is found in various body tissues and organs such as liver, heart, brain, lungs, muscles and liver. The elevated levels of AST in the study shows that the enzyme could have come from other tissue and organs rather than liver since the more specific liver marker Alanine aminotransferase (ALT) remains low in the treated groups. Thus determination of ALT activity, is a relatively sensitive indicator of hepatic damage in certain animal species and can help to determine whether further diagnosis test are necessary²⁶. The release of ALT from the cytosol may occur secondary to cellular necrosis or as a result of cellular injury, with membrane damage and bleb formation²⁷.

The stable levels of ALT and total proteins following the administration of the ethanolic leaf extract of *Catharanthus roseus* suggests that the liver and the kidney, may not be damaged by the administration of the ethanolic leaf extract of *C. roseus*.

CONCLUSION AND RECOMMENDATION

The results from these studies indicate that at these dosages (1900-5000 mg kg⁻¹), the ethanolic leaf extract of *C. roseus* is relatively safe but may have toxic effects at higher dosage. Consequently, safety measures have to be applied when these products are used in higher dosages. These may include monitoring of serum enzymes levels, administration of milk as the alkaloids in *C. roseus* are found to interact and be resisted by multi-drug resistance associated protein. Further studies should be directed towards the effects of *C. roseus* at higher dosages in order to determine the LD₅₀ of the plant.

REFERENCES

1. Don, G., 1999. *Catharanthus roseus*. In: Medicinal Plants of the World: Chemical Constituents, Traditional and Modern Medicinal Uses, Volume 1, Ross, I.A. (Ed.). Humana Press, New Jersey, ISBN: 9780896035423, pp: 109-118.

2. Cowley, R.C. and F.C. Bennett, 1928. *Vinca rosea*. Aust. J. Pharm., 9: 61-61.
3. Kirtikar, K.R. and B.D. Basu, 1933. *Vinca rosea*. In: Indian Medicinal Plants, Volume III, Kirtikar, K.R. and B.D. Basu (Eds.). 2nd Edn., Lalit Mohan Basu Publications, Allahabad, India, pp: 1559-1560.
4. Sastry, B.N., 1953. The Wealth of India. CSIR Publication, New Delhi, India, pp: 205.
5. Pillay, P.P., C.P.N. Nair and T.N. Santi Kumari, 1959. *Lochnera rosea* as a potential source of hypotensive and other remedies. Bull. Res. Instit. Univ. Kerala, 1: 51-54.
6. Gordon, S.H., G. Marvin and R.A. Marry, 1964. Alkaloids of *Vinca rosea* (*Catharanthus roseus*). XXVIII. A preliminary report on hypoglycemic activity. Lloydia, 27: 361-363.
7. Stolle, K. and D. Greoger, 1967. *Catharanthus roseus*-a new medicinal plant. Pharm. Zentralh. Deut., 106: 285-306.
8. Ghosh, R.K. and I. Gupta, 1980. Effect of *Vinca rosea* and *Ficus racemosus* on hyperglycemia in rats. Indian J. Anim. Health, 19: 145-148.
9. Swanston-Flatt, S.K., C. Day, P.R. Flatt, B.J. Gould and C.Y. Bailey, 1989. Glycaemic effects of traditional European plant treatments for diabetes. Studies in normal and streptozotocin diabetic mice. Diabetes Res., 10: 69-73.
10. Chattopadhyay, R.R., S.K. Sarkar, S. Ganguly, R.N. Banerjee and T.K. Basu, 1991. Hypoglycemic and antihyperglycemic effect of leaves of *Vinca rosea* Linn. Indian J. Physiol. Pharmacol., 35: 145-151.
11. Singh, S.N., P. Vats, S. Suri, R. Shyam, M.M.L. Kumria, S. Ranganathan and K. Sridharan, 2001. Effect of an antidiabetic extract of *Catharanthus roseus* on enzymic activities in streptozotocin induced diabetic rats. J. Ethnopharmacol., 76: 269-277.
12. Fischhof, P.K., R. Moslinger-Gehmayr, W.M. Herrmann, A. Friedmann and D.L. Rußmann, 1996. Therapeutic efficacy of vincamine in dementia. Neuropsychobiology, 34: 29-35.
13. Hindmarch, I., H.H. Fuchs and H. Erzigkeit, 1991. Efficacy and tolerance of vinpocetine in ambulant patients suffering from mild to moderate organic psychosyndromes. Int. Clin. Psychopharmacol., 6: 31-43.
14. Chattopadhyay, R.R., 1999. A comparative evaluation of some blood sugar lowering agents of plant origin. J. Ethnopharmacol., 67: 367-372.
15. El-Sayed, A. and G.A. Cordell, 1981. *Catharanthus* alkaloids. XXXIV. *Catharanthamine*, a new antitumor bisindole alkaloid from *Catharanthus roseus*. J. Nat. Prod., 44: 289-293.
16. Jaleel, C.A., R. Gopi and R. Panneerselvam, 2009. Alterations in non-enzymatic antioxidant components of *Catharanthus roseus* exposed to paclobutrazol, gibberellic acid and *Pseudomonas fluorescens*. Plant Omics J., 2: 30-40.
17. Nayak, B.S., M. Anderson and L.M.P. Pereira, 2007. Evaluation of wound-healing potential of *Catharanthus roseus* leaf extract in rats. Fitoterapia, 78: 540-544.
18. Patil, P.J. and J.S. Ghosh, 2010. Antimicrobial activity of *Catharanthus roseus*-a detailed study. Br. J. Pharmacol. Toxicol., 1: 40-44.
19. Ethalsha, P. and A.M. Retna, 2014. Evaluation of antioxidant potential and antibacterial activity of crude extracts *Catharanthus roseus*. Int. J. Pharmaceut. Sci. Res., 5: 3490-3495.
20. Patharajan, S. and S. Balaabirami, 2014. Antioxidant activity and phytochemical analysis of fractionated leaf extracts of *Catharanthus roseus*. Int. J. Pharmacogn., 1: 138-143.
21. Kumari, K. and S. Gupta, 2013. Antifungal properties of leaf extract of *Catharanthus roseus* L (g.) Don. Am. J. Phytomed. Clin. Therapeut., 1: 698-705.
22. Zaini, H.M. and H. Normala, 2013. Stems extract of Kemuning cina (*Catharanthus roseus*) as biofungicides against white root fungal (*Rigidoporus microporus*) of rubber trees (*Hevea brasiliensis*). J. Biofertiliz. Biopestic., Vol. 4. 10.4172/2155-6202.1000136.
23. Lu, F.C., 1981. Basic Toxicology: Fundamentals, Target Organs and Risk Assessment. Hemisphere Publishing Co., Washington, DC., USA.
24. Mahadevaswami, M.P., U.C. Jadaramkunti, M.B. Hiremath and B.B. Kaliwal, 2000. Effect of mancozeb on ovarian compensatory hypertrophy and biochemical constituents in hemicastrated albino rat. Reprod. Toxicol., 14: 127-134.
25. Dapar, L.P.M., C.J. Aguiyi, N.N. Wannang, S.S. Gyang and M.N. Tanko, 2007. The histopathologic effects of *Securidaca longepedunculata* on heart, liver, kidney and lungs of rats. Afr. J. Biotechnol., 6: 591-595.
26. Bain, P.J., 2003. Liver. In: Duncan and Prasse's Veterinary Laboratory Medicine: Clinical Pathology, Latimer, K.S., E.A. Mahaffrey and K.W. Prasse (Eds.). 4th Edn., Iowa State Press, Ames, IA., USA., pp: 193-214.
27. Stockham, S. and M.A. Scott, 2002. Fundamentals of Veterinary Clinical Pathology. Iowa State University Press, Ames, IA., USA., ISBN-13: 9780813825618, pp: 434-459.