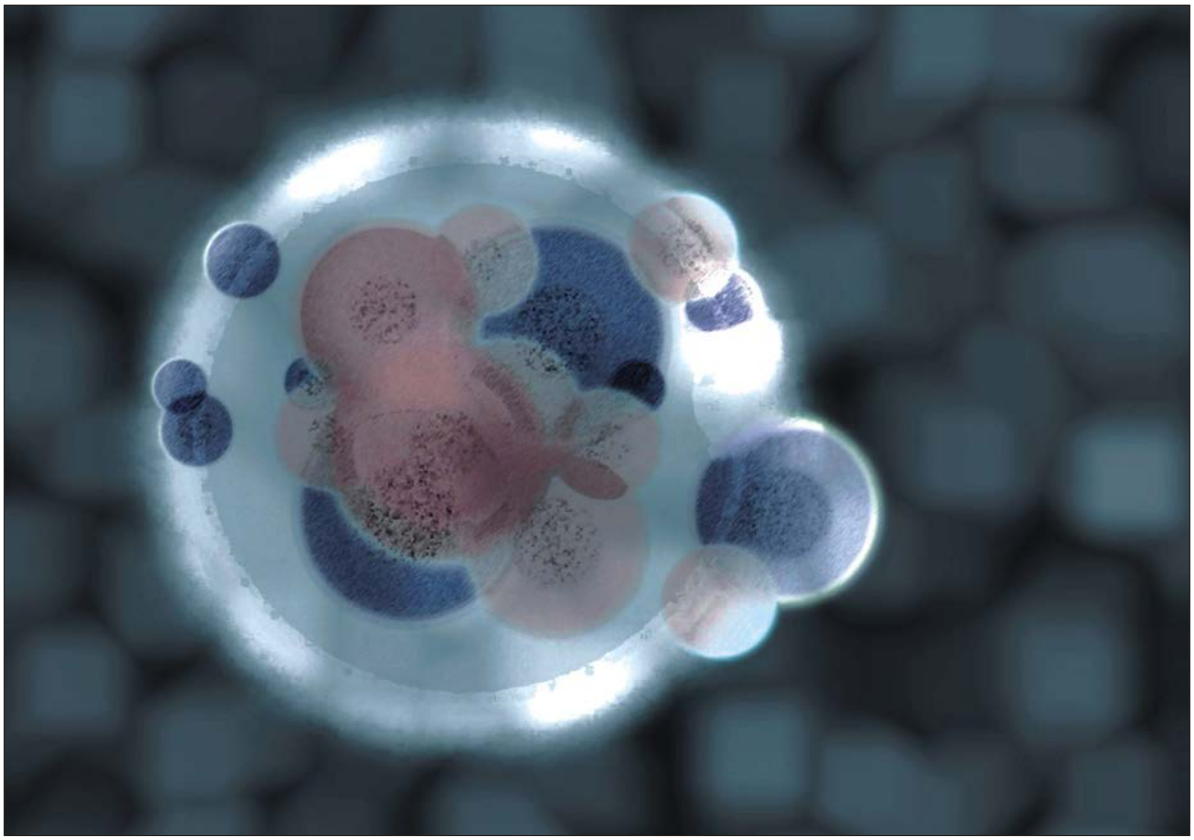

# Journal of Biological Sciences

ISSN 1727-3048

science alert

ANSInet
an open access publisher
http://ansinet.com

Journal of Biological Sciences 5 (4): 532-535, 2005
ISSN 1727-3048


# Bilateral Isolated Facial Paralysis Due to Lyme Disease

[1]Ismet Murat Melek, [1]Taskın Duman and [2]Turali Eraslan
[1]Department of Neurology, University of Mustafa Kemal School of Medicine,
[2]Department of Neurology, Adapazarı State Hospital, Antakya, Turkey

**Abstract:** Lyme disease, a tick-borne infection caused by the spirochete *Borrelia burgdorferi*, is a multisystem disease most commonly affecting the skin, joints, nervous system, or heart. Acute neurologic abnormalities occur in 15 to 20% of the patients and neuropathy, particularly facial paralysis, lymphocytic meningitis and motor and sensory radiculoneuritis are the most common manifestations. However, facial paralysis is an objective manifestation of acute neuroborreliosis as it occurs during the early disseminated phase of the infection. The incidence of facial paralysis was reported as 4.5% but isolated facial paralysis with out other clinical manifestations such as headache, neck pain, stiff neck or throat pain due to borreliosis is extremely rare A previously healthy 46-year-old male developed bilateral facial nerve paralysis. The neurological examination was normal except the bilateral facial nerve palsy. Serological investigation of CSF and serum revealed positive Enzyme-linked Immunosorbent Assay (ELISA) for Ig M and Ig G antibodies to *B. burgdorferi* antigens. An antibiotic regimen consisting of ceftriaxone 2 g/day for six weeks was initiated. The patient was fully recovered at the end of first month with full regression of serological and CSF laboratory findings. In this current case, we report a patient with sole bilateral facial nerve paralysis due to Lyme disease.

**Key words:** Facial paralysis, borreliosis

## INTRODUCTION

Lyme Disease (LD) is a multi system bacterial infection caused by a the spirochete *Borrelia burgdoferi*. Nerve conduction defects (weakness/paralysis of limbs, loss of reflexes, tingling sensations of the extremities, peripheral neuropathy), severe headaches, stiff neck, meningitis, cranial nerve involvement (e.g. change in smell/taste; difficulty chewing, swallowing, or speaking; hoarseness or vocal cord problems; facial paralysis-Bell's palsy; dizziness/fainting; drooping shoulders; inability to turn head; light or sound sensitivity; change in hearing; deviation of eyeball (wandering or lazy eye), drooping eyelid), stroke are common manifestations of the disease. Facial paralysis is an objective manifestation of acute neuroborreliosis as it occurs during the early disseminated phase of the infection[1-3].

The incidence of facial paralysis was reported as 4.5% but isolated facial paralysis with out other clinical manifestations such as headache, neck pain, stiff neck or throat pain due to borroliosis is extremely rare[4,5].

## CASE

A previously healthy 46-year-old male developed bilateral facial nerve paralysis. The neurological examination was normal except the bilateral facial nerve palsy. The patient defined no systemic disease and also he was on no medications. He did not recall a tick bite, skin rash, viral type illness, or joint symptoms. He did not define nausea, vomiting, headache or fever. He had no recent weight loss or gain.

On physical examination the patient was normal except bilateral facial paralysis. Signs of bilateral facial paralysis were prominent (Fig. 1 and 2). There were no signs of menengeal irritation or skin lesions. On neurological examination the patient was fully oriented and had a fluent speech. Magnetic resonance imaging of cranium was done and evaluated normal (Fig. 3). A lumbar puncture was done and Cerebrospinal Fluid (CSF) was harvested for further investigation. The leukocyte count was 110 cells/mm$^3$ (lymphocytes 72%, monocytes 28%), glucose 50 mg dL$^{-1}$ and protein 62 mg dL$^{-1}$. The complete blood count, liver and renal function tests and serum electrolytes, including calcium, potassium, phosphate and sodium were in normal ranges. Serological investigation of CSF and serum revealed positive Enzyme-linked Immunosorbent Assay (ELISA) for Ig M and Ig G antibodies to *B. burgdorferi* antigens. An antibiotic regimen consisting of ceftriaxone 2 g/day for six weeks was initiated. Neurological and laboratory examinations were repeated every week and patient's facial paralysis

**Corresponding Author:** Dr. Ismet Murat Melek, Emlak Bankası Evleri II. Kısım, A-5 Blok No: 14 Antakya, Turkey
Tel: 0 532 375 1530

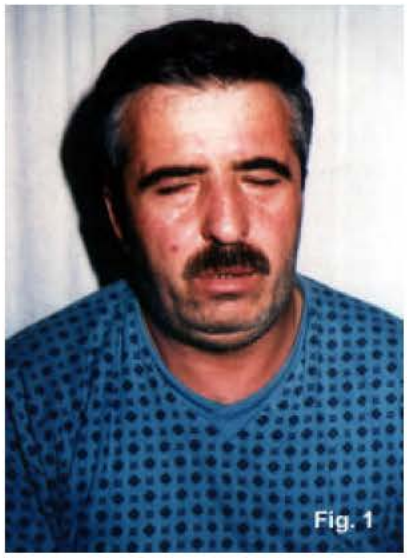


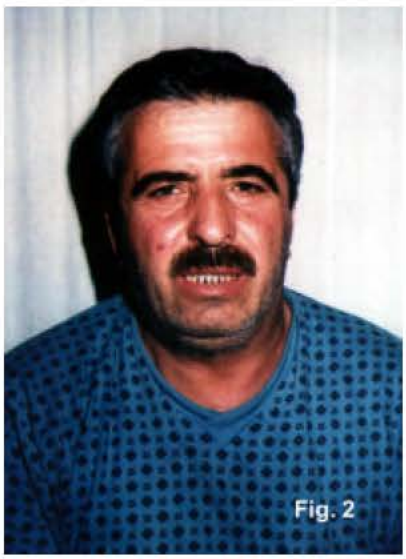


Fig. 1 and 2: Facial paralysis was prominent in the patient

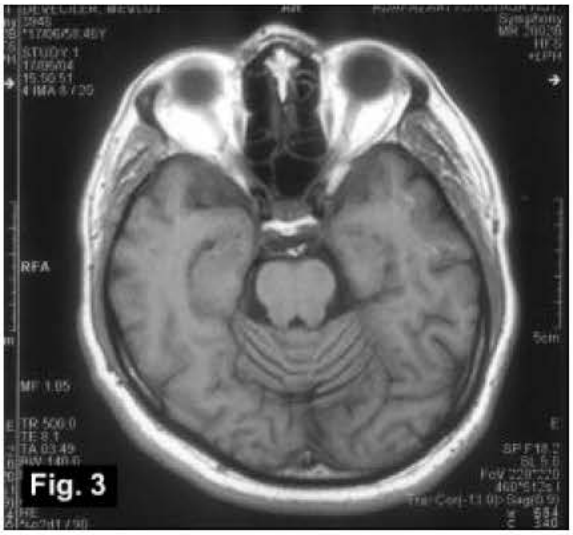


Fig. 3: Cranial MRI was entirely normal including the pons




Fig. 4: The patient fully recovered from facial paralysis after treatment

recessed in 3 weeks time (Fig. 4). The patient was fully recovered at the end of first month with full regression of serological and CSF laboratory findings. Ig M reactivity at ELISA disappeared, however Ig G reactivity persisted but the response did not expand. On a follow up 8 months after the initiation of antibacterial chemotherapy, patient was fully recovered from facial palsy.

## DISCUSSION

Lyme disease is a complex multisystem infection caused by *Borrelia burgdorferi* and is the most common vector-borne disease in the United States of America and Europe[6]. Lyme disease usually begins with the pathagonomic skin lesion, erythema migrans generally appears at the site of a tick bite and in seven to ten days *B. burgdorferi* spreads hematogenously[2]. Most of the patients skip the characteristic erythema migrans phase and this disables the early diagnosis of the disease. Thus, the skin lesions of Lyme disease show a variation from erythema migrans, lymphocytoma cutis to Acrodermatitis chronica atrophicans[2]. However, hematogenous spread of the spirochete is the main cause of the neurologic, cardiac and rheumatologic manifestations of the disease. Systemic complaints in patients with Lyme disease are

more common in USA than in Europe, as a result of different types of virulent genospecies. The most frequent symptoms of Lyme disease include fatigue (54%), myalgia (44%), arthralgia (44%), headache (42%), fever and/or chills (39%) and stiffness of the neck (35%)[7-9]. In this case report, a Lyme disease case with isolated bilateral facial paralysis was reported. As state above Lyme disease has a vast variety of clinical manifestations. However, this case has a unique clinical manifestation because of isolated bilateral facial nerve palsy without other clinical signs.

Neurological manifestations of Lyme disease were seen in up to 10% untreated patients. However, chronic neuroborreliosis generally needs at least several weeks to display clinical signs after the initiation of hematological spirochete spread. The neurological manifestations of neuroborreliosis are peripheral neuropathy (chronic axonal neuropathy), paresthesias, radicular pain, encephalopathy (typically subacute or chronic, subtle memory and cognitive dysfunction) and encephalomyelitis (unifocal or multifocal inflammatory disease)[2]. On the other hand, in Europe the frequency of neuroborreliosis seems higher, potentially due to the greater neurotropism of *B. garinii*[9]. Involvement of cranial neuropathy or neuritis to disease may be the main complaint of the most patients in the early stages of the disease[4]. In this case, bilateral facial paralysis was the one and only clinical expression of the disease. The differential diagnosis of facial nerve paralysis was the most important issue for treatment and follow up of the patient. In this case, Bell's palsy, Ramsey Hunt's syndrome, trauma, other infectious disease and malignant disease were other possible causes of facial nerve palsy. Bell's palsy was ruled out as it is generally demonstrates unilateral facial paralysis. The Ramsey Hunt's syndrome due to presumably to herpes zoster of the geniculate ganglion, consist of a facial palsy associated with a vesicular eruption in the external auditory canal, other parts of the cranial integument and mucus membrane of the oropharynx. Often the eight cranial nerve is affected as well, causing vertigo and deafness. The Ramsey Hunt's syndrome ruled out as there was not any eruption and other nerve involvement. Other infectious and malignant diseases were also ruled out with normal computed tomography and magnetic resonance imaging[9,10].

The diagnosis of erythema migrans in locations endemic for Lyme borreliosis is purely clinical[2]. Under these conditions, laboratory testing is neither necessary nor recommended. Culture of *B. burgdorferi* from specimens in early erythema migrans, acrodermatitis lesions, less often from plasma and cerebrospinal fluid enables a definitive diagnosis. In the late phase of the disease, Polymerase Chain Reaction (PCR) technique is very accurate to isolate spirochete from joint fluid[2]. Furthermore, monoclonal antibody staining and PCR techniques can be used to detect DNA sequence specific for *B. burgdorferi* in clinical specimens, but this technique cannot distinguish between live and dead organisms. Moreover positive results may persist after clinical cure. However in such cases like our case clinical manifestation may vary and serological investigation was the only tool for diagnosis[9]. That's why ELISA test and detection of Ig M and G antibodies were chosen to investigate the *B. burgdorferi* infection. These two tests may be considered as complementary tests which are supporting the others results. On the other hand, these tests cannot be used for screening of the effective therapy as antibodies against *B. burgdorferi* flagella antigens decrease in such a long period of time[10].

The pathophysiological mechanism of infection related facial nerve dysfunction is still uncertain. Hypothesized mechanisms include an inflammatory process affecting the nerve within the subarachnoid space (the mechanism postulated for acute facial nerve paralysis associated with other bacterial infections, such as pyogenic meningitis and syphilis) or direct infection of the geniculate ganglion or of the facial nerve it self, with or without swelling of the nerve in the bony fallopian canal (the mechanism presumed to occur with certain viruses, such as herpes agents)[11]. We couldn't find any pathologic finding neither in computed tomography nor magnetic resonance imaging studies of head. The only pathological finding in the physical examination was bilateral facial paralysis. According to the marked elevation of the white blood cells in the CSF, an ongoing inflammation process could be taken into account. Nevertheless, after the termination of the medication and regression of the symptoms, the elevation of white blood cell count in the CSF markedly decreased to normal levels. This strong correlation and exact timing supports the inflammation hypothesis.

## REFERENCES


1. Steere, A.C., 2001. Lyme disease. New Engl. J. Med., 345: 115-25.
2. Hemgge, U.R., A. Tannapfel, S.K. Tyring, R. Erbel, G. Arendt and T. Ruzicka, 2003. Lyme borreliosis. Lancet Infect. Dis., 3: 489-500.
3. Shotland, L.I., M.A. Mastrioanni, D.L. Choo, Y. Szymko-Bennett, L.G. Dally, A.T. Pikus, K. Sledjeski and A. Marques, 2003. Audiologic manifestations of patients with post-treatment Lyme disease syndrome. Hear, 24: 508-517.

4. Peltomaa, M., I. Pyykkö and I. Seppala *et al*., 2002. Lyme borreliosis and facial paralysis-a prospective analysis of risk factors and outcome. Am. J. Otolaryngol., 23: 125-32.
5. Logigian, E.L., R.F. Kaplan and A.C. Steere, 1990. Chronic neurologic manifestations of Lyme tdisease. New Eng. J. Med., 323: 1438-1444.
6. CDC., 1995. Lyme disease: United States 1996, MMWR. Morbidity and Mortalitiy Weekly Report, 44: 590-591.
7. Nadelman, R.B., J. Nowaskowski and G. Forseter *et al*., 1996. The clinical spectrum of early Lyme borreliosis in patients with culture-confirmed erythema migrans. Am. J. Med., 100: 502-08.
8. van Dam, A.P., H. Kuiper and K. Vos *et al*., 1993. Different genotypes of *Borrelia burgdorferi* are associated with distinct clinical manifestations of Lyme borreliosis. Clin. Infect. Dis., 17: 708-17.
9. Stanek, G., S. O'Connell and M. Cimmino *et al*., 1996. European Union concerted action on risk assessment in Lyme borreliosis: Clinical case definitions for Lyme borreliosis. Wien Klin Wochenschr, 108: 741-47.
10. Panelius, J., I. Seppala H. Granlund D. Nyman and P. Wahlberg, 1999. Evaluation of treatment responses in late Lyme borreliosis on the basis of antibody decrease during the follow-up period. Eur. J. Clin. Microbiol. Infect. Dis., 18: 621-29.
11. Belman, A.L., L. Reynolds, T. Preston, D. Postels, R. Grimson and P.K. Coyle, 1997. Cerebrospinal fluid findings in children with Lyme disease-associated facial nerve palsy. Arch. Pediatr. Adolesc. Med., 151: 1224-1228.