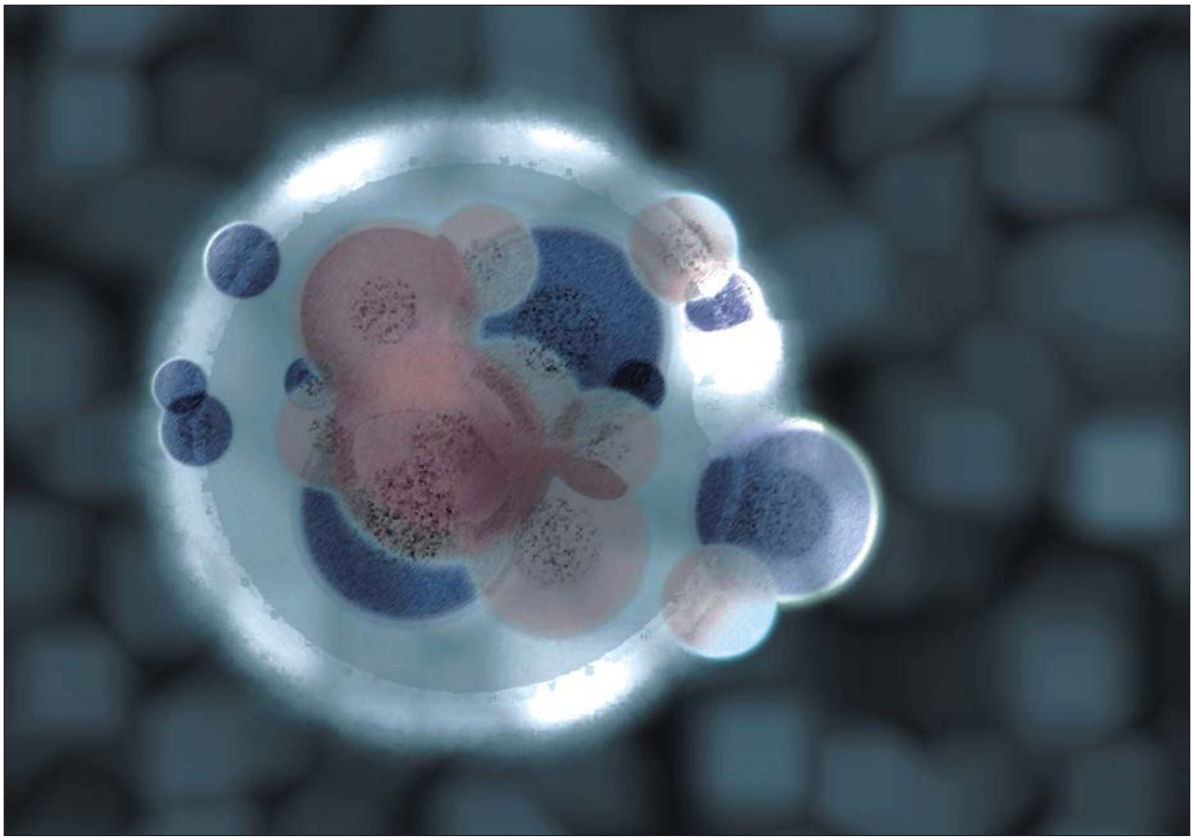

Journal of Biological Sciences

ISSN 1727-3048

science alert

ANSInet
an open access publisher
http://ansinet.com

Journal of Biological Sciences 5 (5): 542-546, 2005
ISSN 1727-3048
© 2005 Asian Network for Scientific Information

Light and Electron Microscopy of Gall Bladder Epithelium of the Gray Monitor, *Varanus griseus*, Infected with *Eimeria griseus* (Apicomplexa: Eimeriidea)

M.S. Alyousif, Y.R. Al-Shawa and Mohammad Mubarak
Department of Zoology, College of Science, King Saud University,
P.O. Box 2455, Riyadh-11451, Saudi Arabia

Abstract: The present study provides more morphological description of the endogenous stages of *E. griseus* and pathological changes of the infected gall bladder epithelium of the gray monitor. The infected epithelium manifested marked hyperplasia, surface alterations and cytoplasmic changes. No corresponding inflammatory cell reaction was recognized. The developmental stages of merogony and schizogony of *Eimeria griseus* were demonstrated in the infected epithelial cells.

Key words: *Eimeria griseus*, gall bladder, light and electron microscopy

INTRODUCTION

Coccidia are among the most important Apicomplexan parasites infecting vertebrate animals[1,2]. Eimeria parasites are considered the most common coccidian protozoa[3-7].

Considerable number of *Eimerian* species infecting lacertilian hosts have been reported[7-13]. However, the studied members of the family Varamidae manifested only six *Eimerian* species[10].

Moreover, studies conducting on the gray monitor, *Varanus griseus* inhabiting the Arabian peninsula, have yielded two *Eimerian* species infecting this monitor lizard, namely *E. rimahensis* and *E. zulphinesis*[9,10]. Previous study[14] has reported a new *Eimerian* species infecting the gray monitor, *E. griseus,* which found to infect the gall bladder epithelium. The morphological distinguishing criteria of the exogenous stages of this parasite have been elucidated.

The present study provides more morphological description of the endogenous stages of *E. griseus* and pathological changes of the infected gall bladder epithelium of the gray monitor.

MATERIALS AND METHODS

Among a large number of lizards surveyed for coccidian infections, ten adult gray monitors, *Varanus griseus*, were collected during April and May, 2004 from Al-Thumamah, central region of Saudi Arabia. Fecal samples were tested for the existence of coccidian oocysts according to the method described by Alyousif *et al.*[14].

Positively infected lizards were necropsied and tissue specimens from gall bladder were immediately fixed in 10% neutral buffered formalin and processed routinely for paraffin embedding technique. Tissue sections were stained with haematoxylin and eosin (H and E). Other tissue specimens of proper size were fixed by immersion in 3% glutaraldehyde buffered in sodium cacodylate buffer (pH 7.2) at 4°C for 4 h. Fixed tissue specimens were then post-fixed in 1% similarly buffered osmium tetroxide (OsO_4) for 2 h. Dehydration of the tissue specimens was done in ascending grades of ethanol and embedded in Epoxy resin mixture (Epon/Araldite) via propylene oxide. For the purpose of tissue orientation, semithin sections (0.5-1 μm) were cut on an ultramicrotome (Leica, UCT) using glass knives and stained with toluidine blue. Accordingly, ultrathin sections (70-80 nm) were prepared, contrasted with uranyl acetate and lead citrate and viewed in a transmission electron microscope (JEOL, CX 100) operating at 80 kV.

RESULTS

Sporulated oocysts, each containing 4 sporocysts, were detected in the examined wet mounts prepared from the infected animals (Fig. 1). The oocysts are ellipsoid in shape with smooth surface and measure 32.8×23.0 μm (length×width) (mean of 50). The sporulated oocysts have thick bilayered wall but lack micropyle, oocyst residuum and polar granule. The sporocysts are also ellipsoid but single walled possessing a residuum in the form of a subspherical mass of aggregated granules. However, Stieda or subStieda bodies are absent.

Corresponding Author: Dr. M.S. Alyousif, Department of Zoology, College of Science, King Saud University P.O. Box 2455, Riyadh-11451, Saudi Arabia
Tel: 00966 1 4675777 Fax: 00966 1 4678514

Fig. 1: Sporulated oocyst of *E. griseus*. The oocyst is ellipsoid, smooth surfaced and double-walled and contains 4 sporocysts. Micropyle, oocyst residuum and polar granule are lacking. Giemsa stain. x 400

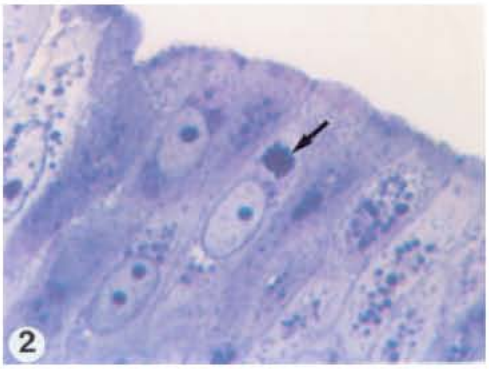

Fig. 2: Developing multinucleated schizont (arrow) surrounded by a parasitophorous vacuole in an epithelial lining cell of gall bladder. The growing merozoites in the schizont appear as dark blue dense bodies. Toluidine blue. x 200

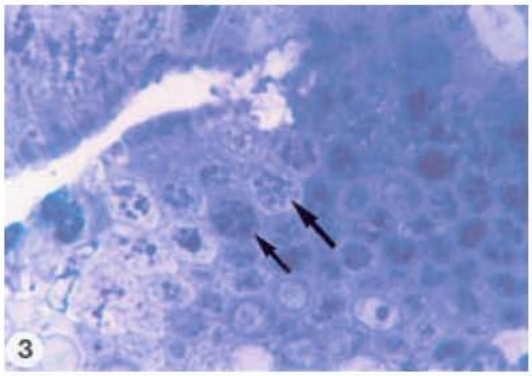

Fig. 3: Large number of mature schizonts (arrows) in the cytoplasm of the markedly hyperplastic gall bladder epithelial lining cells. The mature merozoites are released in the parasitophorous vacuole. The parasitized epithelial cells are swollen and their nuclei are pleomorphic and displaced. Toluidine blue. x 200

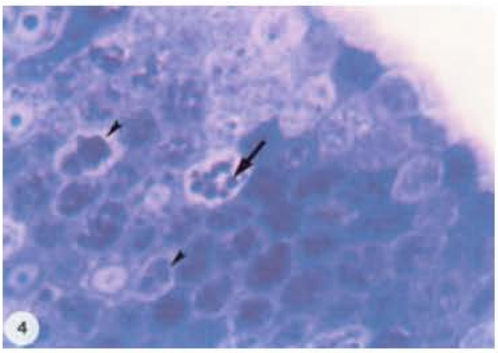

Fig. 4: Mature merozoites (arrow) scattered free in the cytoplasm of a swollen epithelial lining cell. Note the schizonts (meronts) enclosed within parasitophorous vacuoles (arrowheads). The gall bladder epithelium is markedly hyperplastic. Toluidine blue. x 200

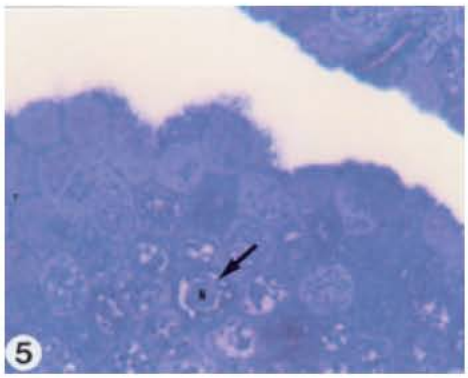

Fig. 5: Growing macrogamont (female gametocyte) (arrow) showing the development of peripherally situated wall forming bodies and central large nucleus (n). Toluidine blue. x 200

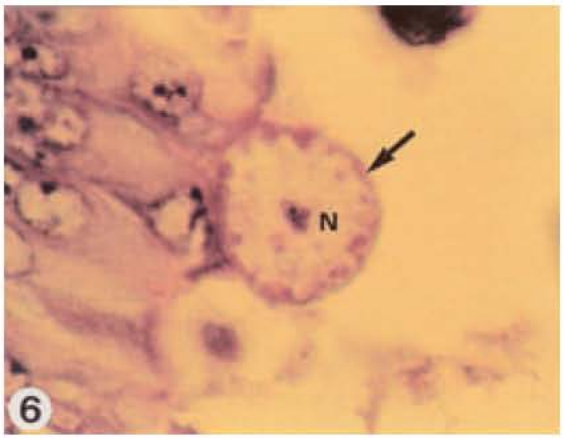

Fig. 6: Macrogamont (arrow) showing the regular arrangement of the wall forming bodies at its margin with the presence of a large central nucleus (n). Toluidine blue. x 1000

Light microscopy of the examined tissues revealed the endogenous developmental stages of *E. griseus*, including those of schizogony and gamogony, which were confined to the gall bladder epithelium. No parasitic stages were recognized in other examined tissues. Schizonts at various stages of development were observed in cytoplasm of the markedly proliferated epithelial lining cells of gall bladder. Mature meronts (schizonts) contained variable number of merozoits, most likely type B merozoites, representing 3rd or 4th generations. In the toluidine blue-stained semi-thin sections (0.5 μm), merozoites appeared as dark blue dense bodies of various sizes and shapes in the hyperplastic epithelium (Fig. 2 and 3). Developing and mature schizonts were present in the superficial epithelial cells as well as in the relatively deeper proliferated cells. The hyperplastic gall bladder epithelial cells had pleomorphic nuclei, most of them possessed prominent one or two nucleoli and deformed surface microvilli. Many infected epithelial cells showed either developing or mature merozoites enclosed within parasitophorous vacuoles. However, free mature merozoites were discerned scattered randomly in cytoplasm of the infected cells without the existence of any limiting membrane (Fig. 4). Developing gamonts, especially macrogamonts (female gametocytes) were detected in the mid-depth epithelial cells (Fig. 5). Fertilized macrogamonts containing peripherally arranged wall forming bodies, which are responsible for building up oocyst wall, were also seen (Fig. 6).

Electron microscopy revealed the existence of large number of meronts, both developing and mature, in the infected gall bladder epithelial cells (Fig. 7 and 8). Meronts were of various sizes and contained variable number of merozoites. However, many of the infected cells manifested mature merozoites scattering free in cytoplasm of the infected cells (Fig. 9 and 10).

Fig. 7: Epithelial lining cells of gall bladder showing variable number of merozoites (arrows) in their cytoplasm. Note the deformed microvilli (arrowheads) and the numerous cytoplasmic vacuoles. Transmission electron micrograph. x 5000

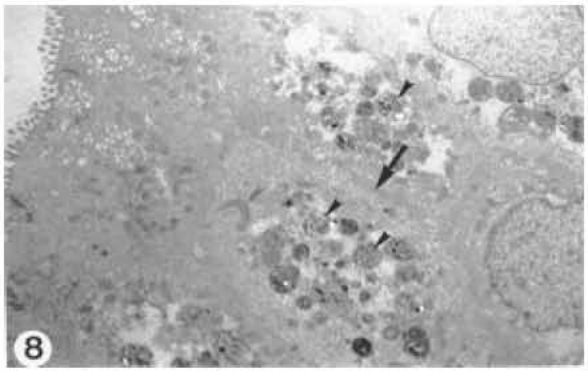

Fig. 8: Large number of transversely sectioned mature merozoites (arrows) in cytoplasm of epithelial lining cells of gall bladder. Note the amylopectin granules in merozoites. The inter-digitations folds in-between the neighboring epithelial cells are accentuated. Transmission electron micrograph. x 6700

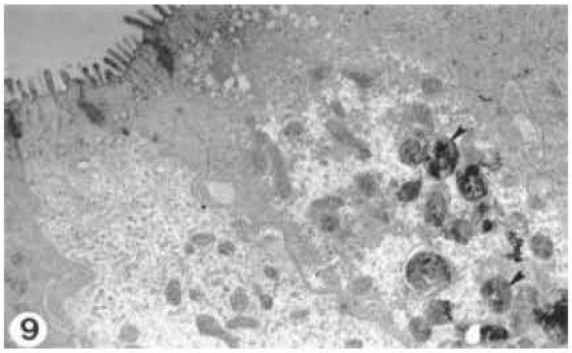

Fig. 9: Free mature merozoites (transversely sectioned) (arrows) scattered in cytoplasm of an infected epithelial cell. Note the obvious cytoplasmic vacuolation of the infected cell. Transmission electron micrograph. x 1000

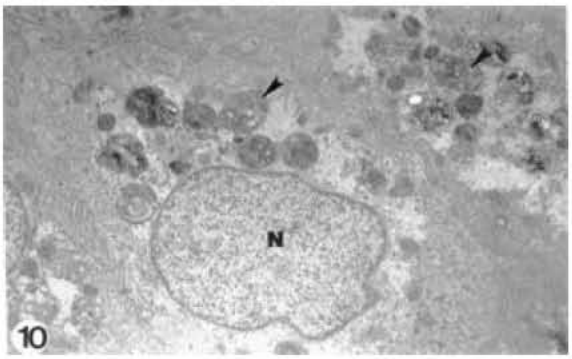

Fig. 10: Mature merozoites (arrows) in cytoplasm of the infected gall bladder epithelial cells. The swollen infected epithelial cell has irregular nucleus (N). Transmission electron micrograph. x 10000

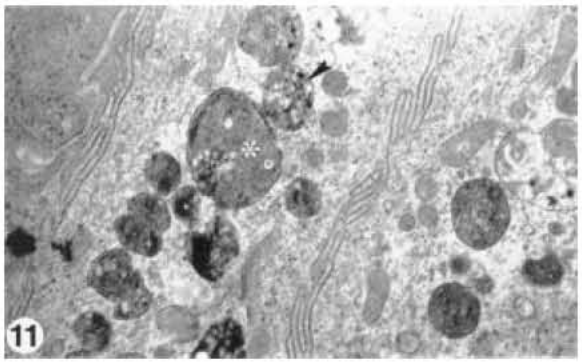

Fig. 11: Mature merozoites (arrows) released from a schizont (arrowhead) in a parasitized epithelial cell. The merozoites appear to release from the schizont by budding (ectomerogony). Transmission electron micrograph. x 14000

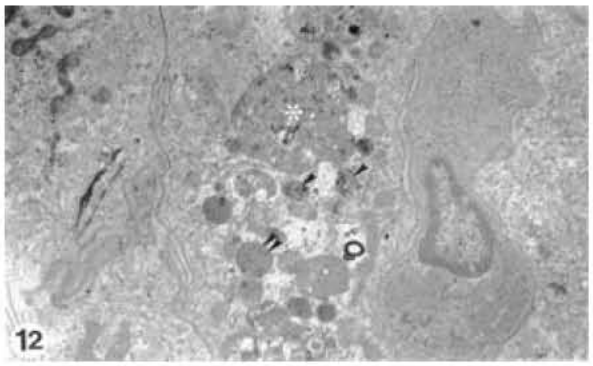

Fig. 12: Mature schizont (arrow) showing ectomerogony (budding of merozoites). Large number of released merozoites (arrowheads) are recognizable. Note the autophagolysosomes (double arrowheads). Transmission electron micrograph. x 10000

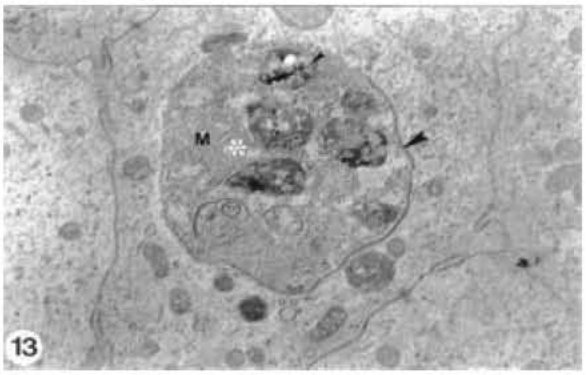

Fig. 13: Schizont (arrow) enclosed within a parasitophorous vacuole. Note that the membrane of the vacuole is directly apposed to the limiting membrane of the schizont. Transmission electron micrograph. x 10000

Budding of young merozoites from the progressively growing meronts were apparent in considerable number of the infected epithelial cells (Fig. 11 and 12). Developing meronts and free merozoites occupied most of the cytoplasm of infected cells, which showed marked deterioration of their organelles.

In addition, infected epithelial cells disclosed large number of cytoplasmic vacuoles and their plasma membranes exhibited accentuation of the interdigitation folds connecting them to the neighboring cells. Meronts enclosed within parasitophorous vacuoles which had distinct limiting membrane, were also recognizable (Fig. 13). Concerning the host tissue response for the developing parasitic stages, no inflammatory cells were noticed infiltrating on the infected hyperplastic epithelium of gall bladder. The sub-epithelium connective tissue was edematous and lamina propria disclosed distended capillaries and scattered lymphoid cells and plasma cells. Extravasated erythrocytes, indicating hemorrhages, were discerned in lamina propria as well as in-between the proliferated infected epithelial cells.

DISCUSSION

Presently, the endogenous stages of *E. griseus* infecting the gray monitor, *Varanus griseus*, have been demonstrated. The infecting *Eimerian* species was a new one basing upon its structure, geographic distribution, type of host, sporulation time and site of infection as reported in our previous study[14].

The present *Eimerian* species is a distinct one and considered the first recovered from gall bladder of the lizards belonging to genus Varanus. The currently demonstrated findings obviously show that the gall bladder epithelium is a predilection seat for development of the endogenous stages of *E. griseus*. This was evidenced by the widespread infection of the gall bladder epithelial lining cells and the existence of large sized meronts.

Large number of meronts were not enclosed in the parasitophrous vacuoles and consequently numerous free merozoites were recognized. From observation of the presently examined tissues, it seems that the stage of mergony of *E. griseus* occurs fully in the gall bladder epithelium. Merogony in the current infected cases is of ectomerogenous type similar to those described for the other *Eimerian* species and considered a common pattern among Apicomplexan parasites. The demonstrated meronts in the present cases may correspond to type B meront described in some other coccidial infections.

Pathogenicity of *Eimeria* species varies depending upon the resultant histopathological changes[5]. The

presently described coccidial infection is characterized by marked proliferation of the parasite-laden epithelium. This epithelial proliferation is reminiscent of that reported in bile ducts of rabbits infected with *E. stdie* and *E. coecicola*. The noticed remarkable epithelial cell hyperplasia was most likely a sequence to the damaging effect of intracellular parasitic replication. This tissue response was supposed to be a regenerative trial to replace the degenerated or necrosed epithelial cells arised as a sequel to parasitic infection.

The pathogenic effects of *E. griseous* on gall bladder epithelium were represented by cell swelling, cytoplasmic vacuolation displacement of nuclei and organellar deterioration. Formation of the noticed autophagosomes in the parasitized cells was an indication of the resultant destruction of cytoplasmic organelles. Additionally, apical cytoplasmic blebbings and microvillar deformities, including shortening and blunting, were also recognizable. These pathogenic effects were the sequence of the active parasitic replication, particularly the demonstrated noticeable schizogony. Process of schizogony was found to extensively damage the parasitized epithelium[2]. No corresponding tissue cell reaction was detected in response to these pathological cellular changes. Absence of cell reaction might account for the spreading of infection to the extent that the majority of gall bladder epithelial cells were heavily infected.

REFERENCES

1. Levine, N.D. and V. Ivens, 1972. Coccidia of the Leporidae. J. Protozool., 19: 572-581.
2. Duszynski, D.N. and S.J. Upton, 2001. Entric protozoans. In: Parasitic Disease of Wild Mammals. W.M. Samuel, M.J. Pybus and A.A. Kocan (Eds.). 2nd Edn. Jowa state Univ. Press, pp: 416-459.
3. Gres, V., S. Marchandeau and I. Landau, 2000. The biology and epidemiology of *Eimeria exigua*, a parasite of wild rabbit invading the host cell nucleus. Parasitologica, 42: 219-225.
4. Gres, V., T. Voza, A. Chabaud and I. Landau, 2002. Coccidiosis of the wild rabbit (*Orytologus cuniculus*) in France. Parasite, 10: 51-57.
5. Pakandl, M., D. Licosis and P. Coudert, 2001. Electron microscopic study on sporocysts and sporozoites of parental strains and precocious lines of rabbit coccidian *Eimeria intestinalis*, *E. media* and *E. magna*. Parasitol. Res., 87: 63-66.
6. Hanada, S., Y. Umemoto, Y. Omata, T. Koyama, K. Nishiyama and Y. Kobayashi *et al*., 2003. *Eimeria stiedai* merozoite 49-KDa soluble antigen induce protection against infection. J. Parasitol., 89: 613-617.
7. Paperna, I., 2003. The endogenous development, described by light and electron microscope, of *Eimeria jamescooki* (Apicomplexa: Eimeriidae) from the skink cryptobepharus virgatus. Folia Parasitological, 50: 89-96.
8. Kasim, A.A. and Y.R. Al-Shawa, 1988. *Eimeria sinatae* (Apicomplexa: Eimeriidae) from the rock agama (*Agama sinaita*) in Saudi Arabia. J. Protozool., 35: 388-389.
9. Amoudi, M.A., 1989. Two new species of *Eimeria* (Apicomplexa: Eimeriidae) from the Saudi Arabian gray monitor (*Varnus griseus*). J. Sci. Res., 11: 72-81.
10. Upton, S.J. and P.S. Freed, 1990. Description of the oocysts of *Eimeria beccari* (Apicomplexa: Eimeriidae) from *Varanus prasinus beccari* (Reptilia: Varanidae). Z. Parasitink., 16: 181-184.
11. Alyousif, M.S. and Y.R. Al-Shawa, 1998. A new coccidian parasite (Apicomlexa: Eimeriidae) from the legless lizard, *Diplometopon zardudnyi* (Amphisbaenia: Trogonophidae) in Saudi Arabia. J. Egypt. Soc. Parasitol., 28: 257-261.
12. Al-Rashied, K.S. and M.S. Alyousif, 1998. *Eimeria yemenensae* (Apicomplexa: Eimeriidae) from the rock agama (*Agama yemenensis*) in Saudi Arabia. Parasitol. Intl., 47: 127-130.
13. Slapeta, J.R., D. Modry, J. Ashe and B. Koudela, 2003. Description of *Eimeria arabukosokokensis* (Apicomplexa: Eimeriida) from *Telescopus semiannulatus* (Serpents: Colubridae) with notes on *Eimerian coceidia* from snakes of Eastern Kenya. Folia Parasitological, 50: 23-30.
14. Alyousif, M.S., Y.R. Al-Shawa and M. Mubarak, 2004. *Eimeria griseus* (Apicomlexa: Eimeriidea) from the gray monitor, *Varanus griseus* in Saudi Arabia. J. Egypt. Soc. Parasitol., 34: 767-773.