



# Journal of Biological Sciences

ISSN 1727-3048

**science**  
alert

**ANSI***net*  
an open access publisher  
<http://ansinet.com>

## Study Towards Cellular Degradation Caused by Environmentally Persistent Chemical

<sup>1</sup>S.K. Das, <sup>2</sup>M. Sakakibara, <sup>2</sup>A. Sakurai, <sup>3</sup>J. Bhattacharjee, <sup>4</sup>M.M. Rahman and <sup>1</sup>M.A. Awal

<sup>1</sup>Department of Anatomy and Histology,

Bangladesh Agricultural University, Mymensingh-2202, Bangladesh

<sup>2</sup>Department of Applied Chemistry and Biotechnology, Fukui University, Fukui, Japan

<sup>3</sup>Department of Surgery and Obstetrics,

Bangladesh Agricultural University, Mymensingh-2202, Bangladesh

<sup>4</sup>Veterinary Surgeon, Shajadpur, Sirajgonj, Bangladesh

**Abstract:** To observe the effect of environmentally persistent chemical formalin on the cells of male genital system as well as reproduction an experiment was conducted in the Department of Anatomy and Histology, BAU, Mymensingh-2202, Bangladesh. Ten percent commercial formalin was used in 12 prepubertal male Black Bengal goats. At fifteen days after a single exposure of formalin, atrophy of testes was observed for the first time and at thirty days after exposure the mean weight, length and width of testes were significantly decreased compared to those of control group. In histopathological observation, it was found that the peripheral tubules were more affected than the central ones. In heavily affected areas, the seminiferous tubules were collapsed or shrunk. Focal or complete necrosis was also noticed in different regions of treated testes. In addition, increased connective tissues with macrophage infiltration were also observed in the interstitial region. Mark eosinophilic staining was also observed in the treated testicular tissue. The sloughed and necrosed seminiferous tubules were also found indicating cellular degradation caused by formalin. Further study is also needed to elucidate the exact mechanism of cellular degradation caused by such environmentally persistent chemicals both *in vivo* and *in vitro*.

**Key words:** Cellular degradation, environmentally persistent chemical, formalin

### INTRODUCTION

Environmental pollutants are a diverse group of chemicals that altering the functions of neuro-endocrine (Finch *et al.*, 1984) and reproductive system also have skeletal effects (Spelsberg and Riggs, 1987 and Ernst *et al.*, 1991). Several environmental chemicals/endocrine disruptors are known to have an estrogenic activity by interacting with development and functions of endocrine systems in nearly all classes of vertebrates (Kloas *et al.*, 1999; Krishnan *et al.*, 1993). Over the last 50 years, large amounts of these estrogenic man-made chemicals have been released into the environment (McLachlan, 1985). Evidence suggests that in many instances the presence of these chemicals has had deleterious effects on exposed wildlife populations (Colborn and Clement, 1992; Colborn *et al.*, 1993). Estrogens influence many developmental and physiological responses in target cells by regulating the activity of specific genes. Their action is mediated by a soluble intracellular receptor that functions as a

transcription factor (Parker, 1993). Untimely exposure to natural or synthetic estrogens can also adversely affect human health, particularly with regard to the reproductive cycle and reproductive function. In addition to decreased sperm counts in men and increased incidence of disorders of the male reproductive tract (Sharpe and Skakkebaek, 1993; Ginsberg, 1994), recent epidemiological studies suggest that cumulative exposure to estrogenic chemicals is related to the incidence of reproductive cancers (Henderson *et al.*, 1988).

Plastic and plastic products, widely used for daily necessities, contain estrogenic endocrine-disruptors and most of them are environmental pollutants. Kembra *et al.* (1999) reported that these products can interfere with mammalian reproduction. The chemical structure of hydroxylated diphenylalkanes or bisphenols consists of two phenolic rings joined together through a bridging carbon. This class of endocrine disruptors that mimic estrogens is widely used in industry, particularly in plastics (Perez *et al.*, 1998). The possible addition of this estrogenic molecule to the food supply since

polycarbonate plastic is used in myriad applications in the packaging of food and beverages (Feldman and Krishnan, 1995). Increasing concerns over the effects of environmental estrogens on wildlife and humans have highlighted the need for screening systems to assess potentially estrogenic effects to test compounds.

At present, it has been accepted that the reproductive organs are the major targets for their actions (Monsees *et al.*, 2000; Silvana *et al.*, 2000). Bisphenol-A has generally been used as polycarbonate plastic products such as baby bottles and packaging of beverage and food (Feldman and Krishnan, 1995). Takao *et al.* (1999) reported that bisphenol-A leaches out from such products and its rate increases with repeated use. It has been suggested that environmental contaminants with bisphenol-A affect the reproduction and other endocrine systems in human and wild life (Toppari *et al.*, 1996). To date, only a few studies on the effect of environmental persistent chemicals in Bangladesh have done, therefore, the present study can step ahead to evaluate the effect of environmental persistent chemicals like formalin on reproduction of prepubertal male goats. The present research will be of great importance to elucidate the effects of environmentally persistent chemicals like formalin including endocrine disruptors both in Bangladesh and Japan.

#### MATERIALS AND METHODS

A total of six uncastrated treated young male Black Bengal Goats were used in the present study that were collected from the local village farmer with age of the experiment animal was 21 days during experimental period. The experimental goats were apparently healthy and devoid of any external abnormalities. Ten percent formalin was injected intratesticularly in the right testes of three goats of total 6 (1c.c./testicle) and the normal saline was injected intratesticularly in the left testes of same goats as control (1c.c./testicle). In another three goats 10% formalin was injected intratesticularly in the left testes (1c.c./testicle) and the normal saline was injected in the right testes of the same goats as control (1c.c./testicle). The animals were observed carefully daily throughout the whole experimental period. Antiseptic was used before injection of formalin for all goats to prevent any infection of testes. After one month of treatment, the testes were removed by surgical operation in a sterile container immediately after collection. The size and weight of the

testes were measured. For microscopic observation the collected tissues were prepared by standard H and E stain and slides were studied thoroughly under microscope using 4, 10, 40 and 100 objectives. Under microscope all the cellular structures of testes especially seminiferous tubules were studied elaborately. All the recorded and calculated data were statistically analyzed using analysis of variance technique using SPSS statistical computer package program. An ANOVA was performed to compare data among selective treatments. Photographs from the selected specimens were prepared and illustrated for elaborating the result in details.

#### RESULTS AND DISCUSSION

**Gross study:** The mean length, width and weight of untreated testes at 51 days of age were measured as 2.73, 1.33 and 6.02 g, respectively, whereas the mean length, width and weight of formalin treated testes at 51 days of age were measured as 1.90, 1.19 cm and 4.50 g, respectively (Table 1). So the size and weight of formalin treated testes were reduced compared to the control group i.e. the testes after formalin treatment had been atrophied due to its destructive chemical action on testes (Fig. 1). These are in agreement with the reports of Ijaz (2000); Kang *et al.* (1993) and Anwar *et al.* (2001).

It was also observed that after 12 h of treatment, there was swelling of the treated testes and then it gradually subsided. This is in consistent with the report of Immegart *et al.* (2000). They reported that in the dog, injection of 70% glycerol solution caused testicular swelling after 24 to 48 h of treatment. The testes were reduced in size and volume after two weeks and continued to shrink. These are in agreement with the report of Samanta (1998). He also reported in the dog that injection of CaCl<sub>2</sub> solution intratesticularly resulted testicular atrophy.

Testicular atrophy may be due to nutritional deficiency (Vitamin A, Vitamin E etc), microbial infection, some chemicals or poisons (melatonin, carbamate etc.) supplied with feed or anyhow administered orally reported by Jones *et al.* (1983). But as animals were fed with proper nutrient, vitamin and mineral, so we can avoid such complexity. Additionally, if above mentioned factors are responsible for such conditions then the both testes would be atrophied. But in the present study, only formalin treated testes were atrophied (Fig. 1).

Table 1: Mean±SD of length, width and weight of the testes in treated and control group at the age of 51 days

Group	Ages (days)	Length (cm)	Width (cm)	Weight (g)
Treated group	51	1.8983±0.1795	1.19±0.1005	4.501±0.750
Control group	51	2.7300±7.885	1.33±9.4111	6.020±0.1712

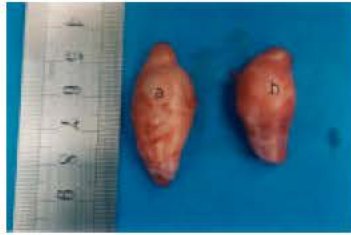


Fig. 1: Testes of Black Bengal Goat (after collection) showing control one (a) and formalin treated one (b) which is significantly atrophied

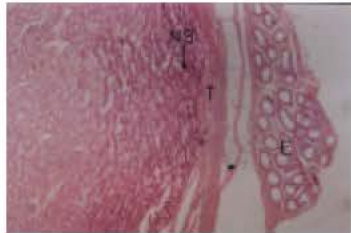


Fig. 2: Histopathology of formalin treated testes showing Epididymis (E), Tunica albuginea (T), Numerous collapsed and necrotized seminiferous tubules (NS) in the periphery of the testes. Haematoxylin and Eosin stain X 40

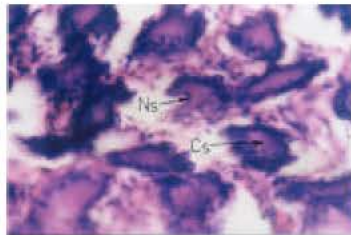


Fig. 3: Histopathology of formalin treated testes showing collapsed and necrotized seminiferous tubules (Ns) with heavy cloudy swelling (Cs) in their lumen. Haematoxylin and Eosin stain X 40

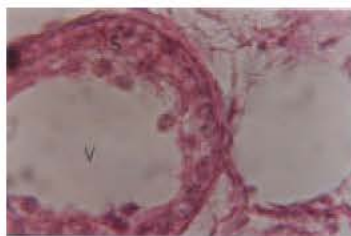


Fig. 4: Histopathology of formalin treated testes showing clear vacuolation (v) within the seminiferous tubules (s) in which nuclei of sertoli cells remain. Haematoxylin and Eosin stain X 100

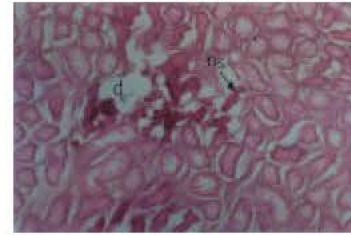


Fig. 5: Histopathology of formalin treated testes showing collapsed and necrotized seminiferous tubules (ns) with their complete disappearance (d) in some areas. Haematoxylin and Eosin stain X 10

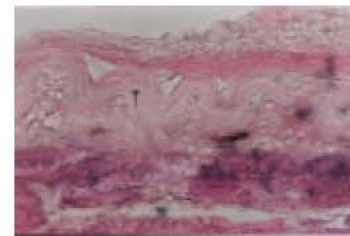


Fig. 6: Histopathology of formalin treated testes showing obvious wrinkling of tunica albuginea (T). Haematoxylin and Eosin stain X 40

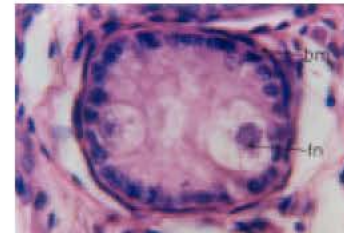


Fig. 7: Histopathology of formalin treated testes showing thickened basement membrane (bm) of seminiferous tubules with fragmentation of nuclei of sertoli cells (fn). Haematoxylin and Eosin stain X 100

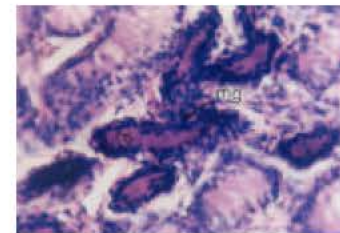


Fig. 8: Histopathology of formalin treated testes showing necrotized seminiferous Tubules (ns) with disarrangement of spermatogonia and infiltration of macrophages (mg). Haematoxylin and Eosin stain X 40

**Histopathological study:** In histopathological study of the treated testes, the numbers of the seminiferous tubules were higher in each field compared to that of the controls. It was in agreement with the findings of Ijaz (2000). He reported that in formalin treated testes, the number of seminiferous tubules were higher in each field and mentioned that in the treated testes, the seminiferous tubules were more prominent owing to the presence of a large number of connective tissue. In the present study, the density of the seminiferous tubules was found more prominent in the areas, where it appeared to be less affected. It is assumed that comparatively higher density may be due to compensatory hypertrophy of the seminiferous tubule, as some of these were destroyed in their close vicinity due to the chemical action of formalin.

The histopathological changes were not also observed uniformly. Comparatively the peripheral tubules were more affected than central tubules (Fig. 2). Akhter (1996) in his experiment on birds reported that administration of estradiol benzoate subcutaneously resulted distortion of the peripheral convoluted tubules with compared to that of the central tubules and is well agreement with the present study. Jubb *et al.* (1991) also stated that degenerative processes do not involve the testes uniformly. Degeneration initially involves dorsal portion of the testes.

In the present experiment on the male Black Bengal Goat, it was revealed that in the severely affected areas of the testes, the seminiferous tubules were collapsed and completely necrotized (Fig. 3). The diameters of the seminiferous tubules were also reduced in compare to that of the control group. These are in common with the reports of Samanta (1998); Ramirez-Harrera *et al.* (1992); Anwar *et al.* (2001); Jones *et al.* (1983) and Monsees *et al.* (2000).

Under microscope, vacuolation within the seminiferous tubule was also observed in the present study (Fig. 4). This finding is also in agreement with the report of Anwar *et al.* (2001). They reported that oral administration of formalin in male Japanese quail caused vacuolation within the seminiferous tubules.

In the present experiment, fibrosis and macrophagic infiltration within the interstitium were also observed (Fig. 8). These are in common with the report of Ramirez-Harrera *et al.* (1992) and Jones *et al.* (1983). They conducted an experiment on the testes of 21 days old pig by injecting epinephrine propylene glycol combination intratesticularly and found that necrosis was followed by fibrosis in 30 days.

Many authors have explained in different literatures that fibrosis and macrophagic infiltration occur due to inflammation, tissue necrosis and degradation. So, fibrosis and macrophagic infiltration in the present study are the

indication of inflammation, tissue necrosis and degradation.

By microscopic examination, a distinct wrinkling of the tunica albugenia (Fig. 6) and wavy thickening of the basement membrane of the seminiferous tubules were also observed (Fig. 7). These are in agreement with the reports of Jubb *et al.* (1991) and Jones *et al.* (1983). They stated that during testicular degeneration, a distinct wrinkling of the tunica albugenia might be present. He also stated that during testicular degeneration, there is a wavy thickening of the basement membrane of the seminiferous tubules.

In some focus, some seminiferous tubules were sloughed out disappeared (Fig. 5); it may be due to the chemical action of formalin. Due to the chemical action of formalin the seminiferous tubules first necrotized and then sloughed off, degraded and finally disappeared.

## REFERENCES

- Akhter, R., 1996. Effect of caponization on birds. MS Thesis, Bangladesh Agricultural University, Mymensingh.
- Anwar, M.I., M.Z. Khan, G. Muhammad, A. Bachaya and M. Babar, 2001. Effects of dietary formalin on the health and testicular pathology of male Japanese quails (*Coturnix coturnix Japonica*). *Vet. Hum. Toxicol.*, Dec; 43: 330-333.
- Colborn, T. and C. Clement, 1992. Chemically Induced Alterations in Sexual and Functional Development: the Wildlife/human Connection. Princeton, New Jersey: Princeton Scientific Publishing.
- Colborn, T., F.S. Vom Saal and A.M. Soto, 1993. Developmental effects of endocrine-disrupting chemicals in wildlife and humans. *Environ. Health Perspect.*, 101: 378-384.
- Ernst, M., M.G. Parker and G.A. Rodan, 1991. Functional estrogen receptors in osteoblastic cells demonstrated by transfection with a reporter gene containing an estrogen response element. *Mol. Endocrinol.*, 5: 1597-1606.
- Finch, C.E., L.S. Felicio, C.V. Mobbs and J.F. Nelson, 1984. Ovarian and steroidal influences on neuroendocrine aging processes in female rodents. *Endocrin. Rev.*, 5: 467-497.
- Feldman, D. and A. Krishnan, 1995. Estrogens in unexpected places: Possible implications for researchers and consumers. *Environ. Health Perspect.*, 103: 129-133.
- Ginsberg, J., 1994. Environmental oestrogens. *Lancet*, 343: 284-285.
- Henderson, B.E., R. Ross and L. Bernstein, 1988. Estrogens as a cause of human cancer: The Richard and Hinda Rosenthal Foundation Award Lecture. *Cancer Res.*, 48: 246-253.

- Ijaz, A., A.A. Abalkhail and W.H.H. Khamas, 2000. Effect of intratesticular injection of formalin on seminiferous tubules in Awassi lambs. *Pak. Vet. J.*, 20: 129-134.
- Immegart, H.M. and W.R. Threlfall, 2000. Evaluation of intratesticular injection of glycerol for nonsurgical sterilization of dogs. *Am. J. Vet. Res.*, 61: 544-549.
- Jones, T.C. and R.D. Hunt, 1983. *Veterinary Pathology*. 5th Edn., Lea and Febiger, Philadelphia, pp: 203-204, 1149-1152.
- Jubb, K.V.F., P.C. Kennedy and N. Palmer, 1991. *Pathology of Domestic Animals*. Academic Press INC. Harcourt Brace Jovanovich, Publishers. Sandiego, New York, Boston, London, Sedney, Tokyo, Toronto, pp: 494-499.
- Krishnan, A.V., P. Starhis, S.F. Permeth, L. Tokes and D. Feldman, 1993. Bisphenol-A: An estrogenic substance is released from polycarbonate flask during autoclaving. *Endocrinology*, 132: 2279-2286.
- Kang, Y.S., C.S. Park and H.S. Ching, 1993. Chemical castration by intratesticular injection of silver nitrate solution in pigs. *Kor. J. Anim. Sci.*, 35: 463-469.
- Kembra, L.H., K.H. Andrew, A.T. Kristina, G.V. John and F.S. Vom Sall, 1999. Exposure of bisphenol-A advances puberty. *Nature*, 401: 763-764.
- Kloas, W., I. Lutz and R. Einspamer, 1999. Amphibians as a model to study endocrine disruptors: II. Estrogenic activity of environmental chemicals *in vitro* and *in vivo*. *Sci. Total Environ.*, 225: 59-68.
- McLachlan, J.A., 1985. *Estrogens in the Environment II*. New York: Elsevier.
- Monsees, T.K., M. Franz, U. Gebhardt, W. Winterstein, B. Schill and J. Hayatpour, 2000. Sertoli cells as a target for reproductive hazards. *Andrologia*, 32: 239-246.
- Parker, M.G., 1993. Mortyn Jones Memorial Lecture: Structure and function of the oestrogen receptor. *J. Neuroendocrinol.*, 5: 223-228.
- Perez, P., R. Pulgar, F.O. Serrano, M. Villalobos, A. Rivas, M. Metzler, V. Pedraza and N. Olea, 1998. The estrogenicity of bisphenol-A related diphenylalkanes with various substituents at the central carbon and hydroxy groups. *Environ. Health Perspect.*, 106: 167-174.
- Ramirez-Harrera, M.A., G.G. Optif, M.L. Mendoza-Magana and R.J. Barba-Lopez, 1992. Non surgical castration of pigs by intratesticular injection of a preparation of epinephrine and propylene glycol. *Veterinaria Mexico*, 23: 41-46.
- Spelsberg, T.C. and R.L. Riggs, 1987. Evidence of estrogen receptors in normal human osteoblast-like cells. *Science*, 241: 84-86.
- Sharpe, R.M. and N.E. Skakkebaek, 1993. Are oestrogens involved in falling sperm counts and disorders of the male reproductive tract? *Lancet*, 341: 1392-1395.
- Samanta, P.K., 1998. Chemosterilization of stray dogs. *Ind. J. Anim. Health*, 37: 61-62.
- Silvana, A.A., S.K. Tatjana, S.S. Stanko and Z.K. Radmila, 2000. Inhibition of rat testicular androgenesis by a polychlorinated biphenyl mixture aroclor 1248<sup>1</sup>. *Biol. Reprod.*, 62: 1882-1888.
- Takao, Y., H.C. Lee, Y. Ishibashi, S. Kohra, T. Tominaga and K. Arizono, 1999. Fast screening method for bisphenol-A in environmental water and food by Solid-phase Microextraction (SPME). *J. Health Sci.*, 45: 39.
- Toppiari, J., J.C. Larsen and P. Christiansen, 1996. Male reproductive health and environmental xenoestrogens. *Environ. Health Perspect.*, 104: 741-757.