



Journal of Biological Sciences

ISSN 1727-3048

science
alert

ANSI*net*
an open access publisher
<http://ansinet.com>

Hypoglycemic Effect of *Ficus microcarpa* Leaves (Chinese Banyan) on Alloxan-Induced Diabetic Rats

K. Asok Kumar, M. Uma Maheswari, A.T. Sivashanmugam,
V. Subhadra Devi, N.V. Prasanth and T.K. Ravi
Department of Pharmacology, College of Pharmacy,
Sri Ramakrishna Institute of Paramedical Sciences,
395, Sarojini Naidu Road, Coimbatore-641 044, India

Abstract: The ethanolic extract of *Ficus microcarpa* L. leaves (EEFML) was evaluated for its hypoglycaemic activity against alloxan-induced diabetes. Diabetes was induced by intraperitoneal injection of alloxan (150 mg kg⁻¹, body weight). EEFML was administered at 100 and 200 mg kg⁻¹ body weight orally for 14 days. The blood glucose was estimated on 0, 7 and 15 days of drug treatment. Glibenclamide (5 mg kg⁻¹) served as positive control. Other parameters such as serum cholesterol, triglycerides, HDL, LDL, VLDL, liver antioxidant enzymes (CAT, SOD, GPx) and TBARS levels were also estimated. Biochemical observations were supplemented with histopathological examination of pancreas. Administration of 200 mg kg⁻¹ of EEFML significantly ($p < 0.001$) reduced the amount of blood glucose (101.5 ± 8.58 mg dL⁻¹) when compared to diabetic control (266.91 ± 15.44 mg dL⁻¹). A decrease in TBARS and an increase in GPx, SOD and CAT levels clearly demonstrated the antioxidant property of EEFML. An increase in HDL and reduction in triglycerides, total cholesterol, LDL and VLDL of EEFML-treated groups against diabetic control evidenced its hypolipoproteinemic activity. These results reveal the beneficial role of *Ficus microcarpa* leaves as a potential hypoglycaemic agent against alloxan-induced diabetes mellitus in rats, which may be attributed to the increased levels of antioxidant enzymes and also by preserving the pancreatic β -cell integrity as evidenced by histopathological studies.

Key words: *Ficus microcarpa*, alloxan, hypoglycaemic activity, antioxidant enzymes

INTRODUCTION

Diabetes mellitus can be defined as a state in which homeostasis of carbohydrate metabolism is improperly regulated due to lack of insulin. Despite the great strides that have been made in understanding the management of diabetes, the disease and the related complications are increasing unabated (Tiwari and Rao, 2002). Hyperglycaemia and hyperlipidemia are two important characters of diabetes (Maiti *et al.*, 2005).

Chemical compounds inducing selective damage on pancreatic β -cells are called as diabetogenic drugs (Fischer, 1985). Alloxan induces damage and death of pancreatic islet cells in several animal models, causing diabetes (Mansi, 2006). Alloxan exerts its action with the generation of free radicals (Szkudelski, 2001).

It is widely accepted that the most challenging goal in the management of diabetes is to achieve blood glucose level as close to normal as possible (Kim *et al.*,

2000). Oral hypoglycaemic agents are useful in the treatment of diabetes mellitus (Holman and Turner, 1991) but have side effects along with their uses (Valiathan, 1998). But over the past few years there is an increase in the use of traditional herbal drugs because of their increased efficacy, minimal side effects in clinical experience, relatively low cost and upsurge in its popularity. Herbal medicines or their extracts are widely prescribed, even before their biologically active compounds are explored. The World Health Organization approved the use of plant-based drugs for different ailments, including diabetes mellitus (WHO, 1980).

Ficus microcarpa L.f. commonly known as Chinese banyan belongs to the Division-Magnoliophyta, Order-Urticales, Family-Moraceae is a large evergreen tree possessing few aerial roots. It is useful in conditions such as diabetes, ulcers, burning sensations, haemorrhages, leprosy, itching, liver disease and toothache (Warrier *et al.*, 1995). The cytotoxic (Chiang *et al.*, 2005)

and antifungal (Taira *et al.*, 2005) activities of the aerial parts have been reported. The present study was designed to evaluate the effect of ethanolic extract of *Ficus microcarpa* leaves (EEFML) on blood glucose level, lipid profile and antioxidant enzymes in alloxan-induced diabetes in rats.

MATERIALS AND METHODS

Plant material: The leaves of *Ficus microcarpa* have been collected from the Siruvani forests of Coimbatore, Tamil Nadu, India, during the month of June 2005 and were dried under shade. The leaves were identified and authenticated by Dr. G.V.S. Moorthy, Joint Director, Botanical Survey of India, Tamil Nadu Agricultural University Campus, Coimbatore [Ref No: BSI/SC/5/23-05-06/Tech/401]. The voucher specimen is available in the herbarium file of our department.

Preparation of extract: The shade dried leaves were pulverised into fine powder using a grinder and sieved through No. 22 mesh sieve and stored in an airtight container. About 60 g of powder was extracted with 70% ethanol (600 mL) for 48 h under agitation using a mechanical shaker (Subramoniam *et al.*, 1997). The content was filtered and concentrated under reduced pressure under controlled temperature to yield a dark gummy residue. The percentage yield of the extract EEFML was found to be 11.5% w/w.

Drugs and chemicals: Glibenclamide was procured from Hoechst Pharmaceuticals, Mumbai, India and alloxan was obtained from Sigma Chemical Company, USA. All other reagents and chemicals were obtained commercially and were of analytical grade.

Animals: *Wistar* male rats weighing between 150-200 g were used. The animals were acclimatized to laboratory conditions for 5 days prior to experiments. They were housed in polypropylene cages and were fed with standard food pellets and drinking water *ad libitum*. The experimental protocol has been approved by the Institutional Animals Ethics Committee and by the animal regulatory body of the government (817/04/AC/CPCSEA).

Acute toxicity studies: *Wistar* rats (150-200 g) maintained at standard laboratory conditions were used. A total of five animals were used which received a single oral dose (2000 mg kg⁻¹) of *Ficus microcarpa* leaf extract. Animals were kept overnight fasting prior to drug administration. After the administration of the extract, food was withheld for further 3-4 h. Animals were observed individually

at least once during the first 30 min after dosing, periodically during the first 24 h and upto 14 days after drug administration (OECD, 2000). The LD₅₀ of the extract falls under class 4 values as per the OECD guidelines. The biological evaluation was carried out at 100 and 200 mg kg⁻¹ body weight.

Evaluation of antidiabetic activity: Diabetes was induced by a single intraperitoneal injection of freshly prepared aqueous solution of alloxan monohydrate at a dose of 150 mg kg⁻¹ to overnight fasted rats. Animals that did not develop hyperglycaemia (blood glucose level above 200 mg dL⁻¹) after 48 h of alloxan injection were rejected. Immediately after confirmation of diabetes, rats were divided into five groups of six each. Group I served as control, which received normal saline (2 mL kg⁻¹, orally). Group II treated with alloxan 150 mg kg⁻¹ served as diabetic control. Group III and IV were treated orally with EEFML 100 and 200 mg kg⁻¹, respectively. Group V treated with glibenclamide (5 mg kg⁻¹, orally) served as reference standard. Treatment was continued for 14 consecutive days. Blood glucose was estimated in all groups on 0, 7th and 15th days of treatment (Sharma *et al.*, 1997). The results were analyzed by using One-way ANOVA followed by Dunnett's test.

On day 15, blood was collected by cardiac puncture under mild ether anaesthesia from overnight fasted rats and blood sugar was estimated (Giordano *et al.*, 1989). Serum was separated and analyzed for total cholesterol (Roeschlaue *et al.*, 1974), triglycerides (Muller *et al.*, 1977), HDL (Allain *et al.*, 1974), LDL and VLDL levels (Friedewald *et al.*, 1972). Animals were sacrificed and liver samples were dissected out and washed immediately with ice-cold saline to remove as much blood as possible. Liver homogenates (5% w/v) were prepared in cold 50 mM potassium phosphate buffer (pH 7.4) using a Remi homogenizer. The unbroken cells and cell debris were removed by centrifugation at 1000 rpm for 10 min using a Remi C-24 refrigerated centrifuge. The supernatant was used for the estimation of Thiobarbituric acid reactive substances (TBARS) (Fraga *et al.*, 1988) and antioxidant enzymes such as catalase (CAT) (Sinha, 1972), superoxide dismutase (SOD) (Kakkar *et al.*, 1984) and glutathione peroxidase (GPx) (Rotruck *et al.*, 1973).

Histopathological studies: The whole pancreas from each animal was removed after sacrificing the animal, placed in 10% formalin solution and immediately processed by the paraffin technique. Sections of 5 µm thicknesses were cut and stained by haematoxylin and eosin for histopathological examination and later the microscopic slides were photographed (de Las Heras-Castano *et al.*, 2005).

Statistical analysis: Values were expressed as mean±standard error mean (SEM) and analyzed using statistical package for social sciences (SPSS) version 10.0 using ANOVA followed by Dunnett's test. P values <0.01 were considered significant.

RESULTS

Acute toxicity studies: Preliminary acute toxicity studies carried out by the oral administration of a single dose of 2000 mg kg⁻¹ b.w. of EEFML caused neither mortality nor any signs of clinical abnormality in the tested animals during the observation period of 14-day post administration of highest dose.

Blood glucose level: Table 1 shows the level of blood glucose in normal and experimental animals on 0, 7 and 15 days of drug treatment. The 0 day blood glucose level indicates the levels after 48 h of alloxan treatment. Blood glucose level of alloxan diabetic rats increased significantly (p<0.001), when compared with normal rats, which indicates the induction of diabetes. Administration of EEFML and glibenclamide tends to bring the blood

glucose levels towards normal on 7th and 15th day of treatment when compared with alloxan diabetic rats. Interestingly, the reduction in the blood glucose by 200 mg kg⁻¹ of extract showed a better trend compared to the standard drug, glibenclamide 5 mg kg⁻¹.

Serum lipid profile: Table 2 shows the significant (p<0.001) increase in triglycerides, total cholesterol, LDL and VLDL levels and a decrease in HDL level in alloxan diabetic rats when compared to the corresponding control rats. Administration of the extracts and glibenclamide tends to bring back the levels to near normal. The effect of the extract at 200 mg kg⁻¹ was more prominent when compared with glibenclamide.

Lipid peroxidation and liver antioxidant enzymes: There was a significant (p<0.001) reduction in the activities of antioxidant enzymes like CAT, SOD, GPx and an increase in tissue TBARS levels of alloxan diabetic rats. Administration of 100 and 200 mg kg⁻¹ of EEFML and glibenclamide (5 mg kg⁻¹) tend to bring the values to near normal (Table 3).

Table 1: Effect of EEFML on blood glucose levels of alloxan diabetic rats

Treatments	Blood glucose level (mg dL ⁻¹)		
	0 day	7th day	15th day
Control (Normal Saline 10 mL kg ⁻¹)	90.83±2.85	90.17±3.46	90.65±6.16
Diabetic control	265.5±15.75 ^a	264±14.6 ^a	266.91±15.44 ^a
EEFML (100 mg kg ⁻¹)	268.53±12.93 ^a	173.56±10.53 ^b	128.36±7.88 ^b
EEFML (200 mg kg ⁻¹)	264.03±11.41 ^a	164.55±10.98 ^b	101.5±8.58 ^b
Glibenclamide (5 mg kg ⁻¹)	261.2±11.36 ^a	150.8±7.97 ^b	101.26±8.16 ^b
One way ANOVA			
F	254.37	226.43	345.46
df	4,25	4,25	4,25
P	<0.001	<0.001	<0.001

Data are expressed as mean±SEM; n = 6 in each group. ^ap<0.001 vs Control, ^bp<0.001 vs diabetic control (Dunnett's test)

Table 2: Effect of EEFML on the levels of triglycerides, lipoproteins and total cholesterol of alloxan diabetic rats

Treatments	TGL (mg dL ⁻¹)	HDL (mg dL ⁻¹)	LDL (mg dL ⁻¹)	VLDL (mg dL ⁻¹)	Total cholesterol (mg dL ⁻¹)
Normal	60.9±3.53	63.52±3.19	61.78±3.33	12.0±0.62	90.04±5.2
Diabetic control	100.12±6.53 ^a	16.77±1.51 ^a	93.07±4.23 ^a	21.02±1.25 ^a	140.2±8.2 ^a
EEFML (100 mg kg ⁻¹)	81.47±3.64 ^b	42.34±2.31 ^b	53.15±3.49 ^b	16.85±0.64 ^b	116.4±6.2 ^c
EEFML (200 mg kg ⁻¹)	72.29±3.52 ^b	51.77±2.56 ^b	47.25±2.33 ^b	12.44±0.68 ^c	109.8±6.2 ^b
Glibenclamide (5 mg kg ⁻¹)	61.98±3.74 ^b	39.43±1.59 ^b	57.46±4.69 ^b	12.42±0.7 ^c	110.7±7.3 ^b
F	84.77	344.70	140.32	86.8	111.2
df	4,25	4,25	4,25	4,25	4,25
P	<0.001	<0.001	<0.001	<0.001	<0.001

Data are expressed as mean±SEM; n = 6 in each group. ^ap<0.001 vs Control, ^bp<0.001 vs Control, ^cp<0.05 vs diabetic control (Dunnett's test)

Table 3: Effect of EEFML on the levels of tissue antioxidant enzymes and TBARS of alloxan diabetic rats

Groups	Catalase (units/mg liver protein)	Superoxide dismutase (units/mg liver protein)	Glutathione Peroxide (units/mg liver protein)	TBARS (nmole of MDA/mg liver protein)
Normal	294.07±17.1	75.91±6.21	0.951±0.030	
Diabetic control	163.75±6.78 ^a	32.31±0.67 ^a	0.747±0.053 ^a	1.74±0.14 ^a
EEFML (100 mg kg ⁻¹)	231.37±2.57 ^b	73.50±3.44 ^b	0.868±0.037 ^b	1.26±0.08 ^b
EEFML (200 mg kg ⁻¹)	258.47±4.51 ^b	84.90±0.98 ^b	0.975±0.062 ^b	1.23±0.11 ^b
Glibenclamide (5 mg kg ⁻¹)	270.31±2.21 ^b	85.84±0.56 ^b	0.982±0.058 ^b	1.12±0.04 ^b
F	91.72	118.1	59.7	192.7
df	4,25	4,25	4,25	4,25
P	<0.001	<0.001	<0.001	<0.001

Data are expressed as mean±SEM; n = 6 in each group. ^ap<0.001 vs Control, ^bp<0.001 vs diabetic control (Dunnett's test)

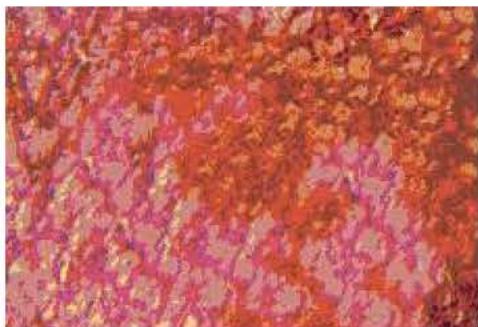


Fig. 1: Section of the pancreatic tissue of control rats showing normal histology, pancreatic acini and islets of Langerhans

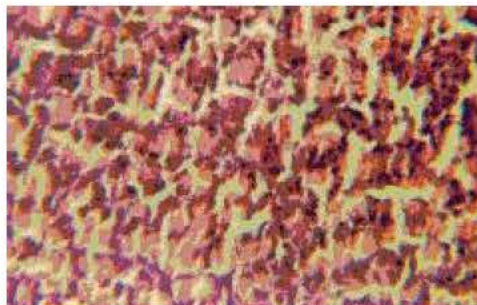


Fig. 4: Section of the pancreatic tissue of glibenclamide treated rats showing normal pancreatic orphology with mild degeneration

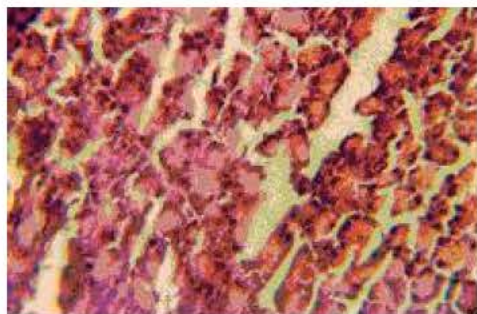


Fig. 2: Section of the pancreatic tissue of alloxan diabetic rats showing focal interstitial pancreatitis, degeneration and necrosis of pancreatic cells

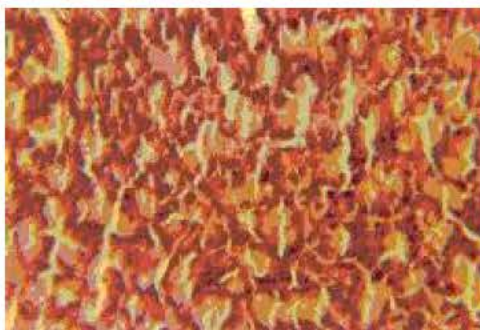

Fig. 3: Section of the pancreatic tissue of rats treated with EEFML 200 mg kg⁻¹ showing almost normal pancreatic histology with fewer fibrosis

Histopathological studies: The photomicrograph of vehicle treated rats showed normal acini and normal cellular population in the pancreatic islets of Langerhans (Fig. 1). Extensive damage and hyperplasia of islets could

be seen in alloxan diabetic rats (Fig. 2). The pancreas of rats treated with 200 mg kg⁻¹ of EEFML (Fig. 3) and glibenclamide (Fig. 4) reduced the dimensions and restored the normal cellular population size of islets. The extract at a dose of 200 mg kg⁻¹ was found to be more effective than 100 mg kg⁻¹.

DISCUSSION

Alloxan, a cyclic urea derivative, was reported as a potent diabetogenic agent (Dunn *et al.*, 1943) and has been widely used for the induction of experimental diabetes in animal species by damaging the insulin-secreting pancreatic β cells, resulting in a decrease in endogenous insulin release, which paves the ways for the decreased utilization of glucose by the tissues. Although the exact mechanism of action of alloxan is not fully understood, evidences indicate that the pancreatic β cell damage induced by alloxan is mediated through the generation of cytotoxic oxygen free radicals (Cohen and Heikkila, 1974; Okamoto, 1985; Takasu *et al.*, 1991; Yamamoto *et al.*, 1981).

LD₅₀ determination indicated safety profile of the drug upto a dose of 2000 mg kg⁻¹. The highly potent hypoglycaemic activity associated with the EEFML may be due to direct stimulation of β cells of the islets of Langerhans. This may lead to secretion of more insulin and facilitate peripheral utilization of glucose via the mediation of enhanced insulin secretion in normal rats. In the present investigation, the extra pancreatic effects and/or the existence of insulin-like compounds in the extract might have contributed the type of alteration seen in the blood glucose levels. Treatment with EEFML and glibenclamide in diabetic rats produced significant hypoglycaemia.

It is well known that in uncontrolled diabetes, there will be an increase in LDL, VLDL, total cholesterol and triglycerides with a decrease in HDL, all of which contribute to the coronary artery disease seen in some diabetic patients (Arvind *et al.*, 2002; Palumbo, 1998). From this point of view, it is interesting that EEFML brought down the elevated levels of LDL, VLDL, total cholesterol and triglycerides in diabetic animals to near normalcy. There was an increase in HDL, which is a desirable feature. Both the doses of EEFML produced a significant beneficial effect on the lipid profile in alloxan-induced diabetic rats.

When alloxan is injected into the rats, it accumulates in the islets of Langerhans and in the liver. Liver contains high superoxide dismutase, catalase and glutathione peroxidase activities, which can scavenge these free radicals. On the other hand, the islet cells have very low concentrations of these enzymes and are vulnerable to the cytotoxic effects of free radicals (Halliwell and Gutteridge, 1999). Present results reveal that there is an increase in antioxidant enzymes, which can prevent or decrease alloxan-induced toxicity.

Pancreatic tissue has been investigated histopathologically. The main histopathological changes found in diabetic rats were focal interstitial pancreatitis, degeneration and necrosis of pancreatic cells. The pancreas of the rats treated with extract and glibenclamide showed fewer fibrosis and degeneration.

In conclusion, it may be stated that there occurs a selective decrease in the hyperglycaemic state after the administration of EEFML, which may be mediated through a number of active principles/compounds present in the extract. The present study suggests that the plant extract can be successfully utilised for the management of diabetes due to their hypoglycaemic action. Further studies on the nature of active principles involved would enlighten the exact mechanism involved and thus help to rationalise their use in the treatment of diabetes more effectively.

REFERENCES

- Allain, C.C., L.S. Poon, C.S. Chan, W. Richmond and P.C. Fu, 1974. Enzymatic determination of total serum cholesterol. *Clin. Chem.*, 20: 470-475.
- Arvind, K., R. Pradeepa, R. Deepa and V. Mohan, 2002. Diabetes and coronary artery diseases. *Indian J. Med. Res.*, 116: 163-176.
- Chiang, Y.M., J.Y. Chang, C.C. Kuo, C.Y. Chang and Y.H. Kuo, 2005. Cytotoxic triterpenes from aerial roots of *Ficus microcarpa*. *Phytochemistry*, 66: 495-501.
- Cohen, G. and K.E. Heikkila, 1974. Generation of hydrogen peroxide, superoxide radical by 6-hydroxy dopamine, dialuric acid and related agents. *J. Biol. Chem.*, 49: 2447-2452.
- de Las Heras-Castano, G., M.T. Garcia-unzueta, A. Dominguez-Diez, M.D. Fernandez-Gonzalez, A.M. Garcia-de la Paz and M. Mayorga-Fernandez *et al.*, 2005. Pancreatic fibrosis in rats and its response to antioxidant treatment. *JOP. J. Pancreas*, 6: 316-324.
- Dunn, J.S., H.L. Sheehan and N.G. McLetchie, 1943. Necrosis of Langerhans produced experimentally. *Lancet*, 1: 484-487.
- Fischer, L.J., 1985. Drugs and chemicals that produce diabetes. *TIPS*, 6: 72-75.
- Fraga, C.G., B.E. Leibovitz and A.L. Tappel, 1988. Lipid peroxidation measured as TBARS in tissue slices: Characterization and comparison with homogenates and microsomes. *Free Radic. Biol. Med.*, 4: 155-161.
- Friedewald, W.T., R.T. Levy and D.S. Fedrickson, 1972. Estimation of the concentration of low-density lipoprotein cholesterol in plasma without use of the preparative ultracentrifuge. *Clin. Chem.*, 18: 499-502.
- Giordano, B.P., W. Thrash, L. Hollenbaugh, W.P. Dube, C. Hodges and A. Swain *et al.*, 1989. Performance of serum blood glucose testing systems at high altitude. *Diabetes Educ.*, 15: 444-448.
- Halliwell, B. and J.M.C. Gutteridge, 1999. *Free Radicals in Biology and Medicine*. 3rd Edn., New York, Oxford University Press, pp: 561-563.
- Holman, R.R. and R.C. Turner, 1991. *Oral Agents and Insulin in the Treatment of Diabetes*. Blackwell, Oxford, pp: 467-469.
- Kakkar, P., B. Das and P.N. Viswanathan, 1984. A modified spectroscopic assay of superoxide dismutase. *Ind. J. Biochem. Biophys.*, 21: 130-132.
- Kim, J.S., C.S. Kwon and K.H. Son, 2000. Inhibition of alpha-glucosidase and amylase by luteolin, a flavanoid. *Biosci. Biotechnol. Biochem.*, 64: 2458-2461.
- Maiti, R., U.K. Das and D. Ghosh, 2005. Attenuation of hyperglycaemia and hyperlipidemia in streptozotocin induced diabetic rats by aqueous extract of seed of *Tamarindus indica*. *Biol. Pharm. Bull.*, 28: 1172-1176.
- Mansi, K.M.S., 2006. Effects of oral administration of *Nigella sativa* on the hypothalamus pituitary and renal axis in experimental diabetes. *Int. J. Pharmacol.*, 2: 104-109.
- Muller, P.H., R.M. Schmulling, H.M. Liebich and M. Eggstgein, 1977. A fully enzymatic triglyceride determination. *J. Clin. Chem. Clin. Biochem.*, 15: 457-464.

- OECD, 2000. Acute oral toxicity-acute oral toxic class method. Guideline 423, adopted 23.03.1996. In: Eleventh Addendum to the OECD Guidelines for the Testing of Chemicals. Organisation for Economic Co-operation and Development, Paris.
- Okamoto, H., 1985. Molecular basis of experimental diabetes: Degeneration, oncogenesis and regeneration of pancreatic β -cells of islet of Langerhans. *BioEssay*, 2: 15-21.
- Palumbo, P.J., 1998. Metformin: Effect on cardiovascular risk factor in patients with non-insulin dependent diabetes mellitus. *J. Diabetes Complications*, 12: 110-119.
- Roeschlau, P., P. Bernt and W. Gruber, 1974. Enzymatic determination of total cholesterol in serum. *Z. Klini. Chem. Klini. Bioch.*, 12: 226.
- Rotruck, J.T., A.L. Pope and H.E. Ganther, 1973. Selenium: Biochemical role as a component of glutathione peroxidase purification assay. *Science*, 179: 588-590.
- Sharma, S.R., S.K. Dwivedi and D. Swarup, 1997. Hypoglycemic, antihyperglycemic and hypolipidemic activities of *Caesalpinia bonducella* seeds in rats. *J. Ethnopharmacol.*, 58: 39-44.
- Sinha, A.K., 1972. Colorimetric assay of catalase. *Anal. Biochem.*, 47: 389-394.
- Subramoniam, A., V. Madhavachandran, S. Rajasekaran and P. Pushpangadam, 1997. Aphrodisiac property of *Trichopus zeylanicus* extract in male mice. *J. Ethnopharmacol.*, 57: 21-27.
- Szkudelski, T., 2001. The mechanism of alloxan and streptozotocin action in B cells of rat pancreas. *Physiol. Res.*, 50: 536-546.
- Taira, T., A. Ohdomari, N. Nakama, M. Shimoji and M. Ishihara, 2005. Characterization and antifungal activity of gazyumaru (*Ficus microcarpa*) latex chitinase: Both the chitin-binding and the antifungal activities of class 1 chitinase are reinforced with increasing ionic strength. *Biosci. Biotechnol. Biochem.*, 69: 811-818.
- Takasu, N., T. Asawa, I. Komiya, Y. Nagaswa and T. Yamada, 1991. Alloxan-induced DNA strand breaks in pancreatic islets: Evidence for H_2O_2 as an intermediate. *J. Biol. Chem.*, 266: 2112-2114.
- Tiwari, A.K. and J.M. Rao, 2002. Diabetes mellitus and multiple therapeutic approaches of phytochemicals: Present status and future prospects. *Curr. Sci.*, 83: 30-38.
- Valiathan, M.S., 1998. Healing plants. *Curr. Sci.*, 75: 1122-1126.
- Warrier, P.K., V.P.K. Nambiar and C. Ramankutty, 1995. Indian medicinal plants a compendium of 500 species. Vol. 3. Madras: Orient Longman, pp: 31-33.
- World Health Organization, 1980. Second Report of the Who Expert Committee on Diabetes Mellitus. Technical Report Series 646, Geneva: World Health Organization, pp: 66.
- Yamamoto, H., Y. Uchigata and H. Okamoto, 1981. DNA strand breaks in pancreatic islets by *in vivo* administration of alloxan or streptozotocin. *Biochem. Biophys. Res. Commun.*, 103: 1014-1020.