



# Journal of Biological Sciences

ISSN 1727-3048

**science**  
alert

**ANSI***net*  
an open access publisher  
<http://ansinet.com>

## Biochemical and Pathological Study of Protective Effect of Vitamin E in Azathioprine-Induced Hepatotoxicity in Rat

<sup>1</sup>B. Amouoghli Tabrizi, <sup>2</sup>D. Mohajeri, <sup>1</sup>G. Mousavi, <sup>3</sup>F. Farajzade, <sup>4</sup>A. Khodadadi, <sup>3</sup>S.B. Alizade and <sup>3</sup>B. Reihani

<sup>1</sup>Department of Clinical Science, Faculty of Veterinary Medicine, Islamic Azad University, Tabriz Branch, Tabriz, Iran

<sup>2</sup>Department of Pathobiology, Faculty of Veterinary Medicine, Islamic Azad University, Tabriz Branch, Tabriz, Iran

<sup>3</sup>Faculty of Veterinary Medicine, Islamic Azad University, Tabriz Branch, Tabriz, Iran

<sup>4</sup>Young Researchers Club, Faculty of Veterinary Medicine, Islamic Azad University, Tabriz Branch, Tabriz, Iran

**Abstract:** In the present research, we decided to study about the protective effect of vitamin E against Azathioprine-induced toxicity. In this study, 40 male Wistar rats were divided to 4 groups (each group contains 10 rats). For the first group, as the control one, normal saline was given. The second and third groups received 20 mg kg<sup>-1</sup> of vitamin E daily and for 7 days by Intra Muscular (IM) injection. The fourth group, that had similar state with three others, normal saline was injected for 7 days. On the seventh day, both 3 and 4 group treated by 15 mg kg<sup>-1</sup> Azathioprine as a single dose and Intra Peritoneal (IP) form. Two other groups only received the dissolvent of Azathioprine in the same dose and manner. Twenty four hours after Azathioprine injection, the animals after being weighted were anesthetized by ether and blood sample were taken via., the tail vein and pathological sample was got from liver. The samples were allowed to clot and then their serum was separated by centrifuge machine of 2500 rpm for 10 min. This study showed that Azathioprine-induced damage on liver in group 3 is less than group 4 and function of organ in group 3 is nearly same with control group. Results of this study demonstrated that vitamin E decrease Azathioprine-induced hepatotoxicity in rat. According to surveys that have done, the necrotic regions and hepatic cellular death in liver was so lesser in the group that treated together with Azathioprine and vitamin E than the group that treated only by Azathioprine and was so similar to control group. Generally, the pathological results of this study confirm the biochemical results.

**Key words:** Vitamin E, Azathioprine, hepatotoxicity, biochemical, histopathological, rat

### INTRODUCTION

Azathioprine (AZA) is an immunosuppressive drug (Aarbakke *et al.*, 1997; Czaja, 1999) that use in medicine and veterinary to remedy different disease like as Inflammatory Bowel Diseases (IBD) (Ludwig and Stange, 1999; Pearson *et al.*, 2000), acute lymphoblast leukemia (Sood *et al.*, 2000), rheumatoid arthritis (Khodabakhshi, 2004), ulcerative colitis (Kader *et al.*, 1998; Sood *et al.*, 2000) and etc., (Czaja, 1999) and synchronous use of this drug by corticosteroid is the best choice to prevent the graft rejection (Di Landro *et al.*, 2000). Although, the Azathioprine is mostly use, but despite of its lymphocyte suppressive effect in patient (Amin and Hamza, 2005), there is evidence that it cause bone marrow toxicity, digestive system toxicity an hepatotoxicity either (Lee and

Farrell, 2001; Menor *et al.*, 2004). It has been cleared out that, by causing an oxidative damage, this drug leads to liver toxicity (Watanabe *et al.*, 1979; Pearson *et al.*, 2000; Lee and Farrell, 2001). This drug produces free radical in the tissues, witch is one of the most important toxicity factors in organs (Watanabe *et al.*, 1979; Kaplowitz, 1997). Watanabe *et al.* (1979) confirmed that Azathioprine oral consumption increases alkaline phosphatase (ALP), Gama Glutamyl Transferase (GGT) in liver. In addition, from a pathological respect this drug cause necrosis in lobular center, proliferation of mitochondria and endoplasmic reticule (Watanabe *et al.*, 1979). Sun *et al.* (1996) showed that using Azathioprine, changes the rate of liver enzymes and increase Alanine Amino Transferase (ALT), ALP and malonyl deltoid, but decrease glutamine rate. These days, applying antioxidants in order to



prevent disease such as cancer or prostate disease, heart disease and etc. is recommended. Menor *et al.* (2004) used N-acetyl-L-cysteine to decrease its side effects in liver tissue and finally came to this end that this composition can play a protecting role in liver tissue. Amin and Hamza (2005) surveyed effects of saliva, hibiscus, rosmarinus against liver problems due to using Azathioprine that indicated these plants can decrease the drug's side effects in liver. Vitamin E is one of the fat soluble elements with delightful antioxidant effect (Karakilcik *et al.*, 2004), results achieved from researcher's studies convey that this drug plays an important role in reducing and destroying free radicals (Karakilcik *et al.*, 2004; Ramirez Farias *et al.*, 2008). Karakilcik *et al.* (2004) demonstrated that using vitamin E and C can decrease oxidative effects due to B1 aflatoxin in rabbit's liver. Andres and Cascales (2002) indicated that vitamin E can reduce oxidative effects due to using Siklosporin A. Researchers in Mexico University indicated that vitamin E and C are able to reduce oxidative damages as a result of using ethanol in rat's liver (Ramirez Farias *et al.*, 2008). As the rat's hepatotoxicity is because of oxidative Azathioprine drug and producing free radicals. The objective of this study was to evaluate the effects of vitamin E against hepatotoxicity due to Azathioprine prescription.

## MATERIALS AND METHODS

Investigations using experimental animals were conducted in accordance with the internationally accepted principles for laboratory animal use and care as found in the United States guidelines (United States National Institutes for Health publication No. 85-23, revised in 1985) and the Ethical Committee on Animal Care approved the protocol. Forty male Wistar rats that were apparently healthy have selected and divided into 4 equal groups. After body-weighting of each group by digital balance, all animals were kept in individual cages during the whole experimental period, under strict hygienic conditions and fed with standard ration for rat ad libitum, in lightning for 12 h and darkness for the same hours in 25°C to get used to the environment. Then 1.5 mL of blood sample was taken via the tail vein from the members of all groups and the samples were studied in a way that will describe as following.

For the first group, as the control one, normal saline was given. The second and third groups received 20 mg kg<sup>-1</sup> of vitamin E daily and for 7 days by IM injection. The fourth group, that had similar state with three others, normal saline was injected for 7 days. On the 7th day, both group 3 and 4 treated by 15 mg kg<sup>-1</sup> Azathioprine (Ramopharmin Pharmaceutical Lab-50 mg

per tablet) as a single dose and IP form. Two other groups only received the dissolvent of Azathioprine in the same dose and manner. Twenty four hours after Azathioprine injection, the animals after being weighted were anesthetized by ether and blood sample were taken via the tail vein and pathological sample was got from liver. The samples were allowed to clot and then their serum was separated by centrifuge machine of 2500 rpm for 10 min. Biochemical parameters including total bilirubin, ALT, AST, ALP, albumin, LDH, cholesterol, HDL, calcium, phosphorous and triglyceride were measured by identification kit of biochemistry and Biowave spectrophotometer apparatus. Tissue samples were fixed in formalin 10% and then pathology cope was produced of them. After Hem toxin and Eosin staining, they were compared in terms of cellular damages such as degenerative changes, cellular death and inflammation changes.

**Statistical analysis:** All biochemical results were expressed as Mean±SD. Significant differences among the groups were determined by one-way Analysis of Variance (ANOVA) followed by student t-test using the statistical analysis software (SPSS) Ver. 13, under Windows XP. Statistical significance was considered at p<0.05.

## RESULTS

**Biochemical study:** Results from studying the animals' average weight in several groups as initial weight average and final one are shown in Table 1. By surveying these results, one can see that animals of the control group and vitamin E and its receivers together with Azathioprine usage as an antioxidant against the drug's side effects, have meaningful statistical increment (p<0.05), but comparing the initial and final body weights averages in animals that received Azathioprine by itself, shows that meaningful statistics come down (p<0.05).

Table 2 shows the average of chemical parameters such as total bilirubin, ALT, AST, ALP, albumin, LDH, cholesterol, HDL, calcium, phosphorus and triglyceride in both control and Azathioprine receiving group and the group got vitamin E and the group got vitamin E together with Azathioprine.

Table 1: Initial and final weight averages in several groups of animals

Groups	Initial weight average	Final weight average
Control	153±5 <sup>a</sup>	161±4 <sup>b</sup>
AZA	158±3 <sup>a</sup>	152±5 <sup>b</sup>
Vitamin E	152±5 <sup>a</sup>	160±3 <sup>b</sup>
AZA+vit. E	155±5 <sup>a</sup>	162±5 <sup>b</sup>

Dissimilar letter(s) in each row shows that there is a meaningful difference (p<0.05)



Table 2: Biochemical parameters in liver tissue

Variables	Control	AZA	Vitamin E	AZA+vit. E
Total bilirubin (mg dL <sup>-1</sup> )	0.210±0.05 <sup>a</sup>	0.38±0.02 <sup>b</sup>	0.21±0.05 <sup>a</sup>	0.20±0.07 <sup>a</sup>
ALT (U L <sup>-1</sup> )	19.500±1.29 <sup>a</sup>	39.00±0.00 <sup>b</sup>	14.50±1.00 <sup>a</sup>	10.00±1.41 <sup>a</sup>
AST (U L <sup>-1</sup> )	38.000±1.29 <sup>a</sup>	49.00±3.46 <sup>b</sup>	33.00±0.00 <sup>a</sup>	29.00±0.00 <sup>a</sup>
ALP (U L <sup>-1</sup> )	36.750±0.50 <sup>a</sup>	83.00±1.41 <sup>b</sup>	32.88±0.44 <sup>a</sup>	29.50±4.19 <sup>a</sup>
Albumin (g dL <sup>-1</sup> )	3.950±0.56 <sup>a</sup>	4.08±0.56 <sup>a</sup>	4.00±0.56 <sup>a</sup>	4.33±0.24 <sup>a</sup>
LDH (U L <sup>-1</sup> )	707.720±39.14 <sup>a</sup>	728.00±3.15 <sup>a</sup>	710.22±11.00 <sup>a</sup>	771.00±172.05 <sup>a</sup>
Chol (mg dL <sup>-1</sup> )	56.450±8.70 <sup>a</sup>	77.87±22.45 <sup>a</sup>	57.78±6.70 <sup>a</sup>	73.88±6.10 <sup>a</sup>
HDL (mg dL <sup>-1</sup> )	37.125±1.93 <sup>a</sup>	38.25±5.56 <sup>a</sup>	36.00±1.99 <sup>a</sup>	33.50±2.12 <sup>a</sup>
Ca (mg dL <sup>-1</sup> )	10.530±0.42 <sup>a</sup>	11.31±0.30 <sup>a</sup>	10.43±0.45 <sup>a</sup>	10.34±1.09 <sup>a</sup>
P (mg dL <sup>-1</sup> )	6.150±0.94 <sup>a</sup>	6.20±0.08 <sup>a</sup>	6.30±0.10 <sup>a</sup>	6.80±0.70 <sup>a</sup>
Trig. (mg dL <sup>-1</sup> )	66.400±13.59 <sup>a</sup>	58.32±16.45 <sup>a</sup>	68.44±15.32 <sup>a</sup>	99.83±4.60 <sup>a</sup>
Total Pr. (g dL <sup>-1</sup> )	6.260±0.17 <sup>a</sup>	6.61±0.60 <sup>a</sup>	6.14±0.25 <sup>a</sup>	5.64±0.93 <sup>a</sup>

Data are expressed as Mean±SEM, N = 10. Dissimilar letter(s) in each row shows that there is a meaningful difference (p<0.05)

Average of serum's bilirubin in Azathioprine group shows meaningful statistical increase than the control one (p<0.05), while average of serum's bilirubin in group of Azathioprine with vitamin E does not indicate meaningful statistical difference with the control group, also in comparing group of vitamin E and the control group, there is no significant statistical differences.

In surveying ALT, AST and ALP enzymes, there is a significant statistical increase in Azathioprine group than the control one (p<0.05), while studies the average of serum's AST and ALT enzymes in the control group with one receiving just vitamin E, there is no such a significant statistical differences.

Studying the average of serum's biochemical parameters such as total protein, albumin, LDH, calcium, phosphorus and triglyceride among groups treated by Azathioprine, Azathioprine with vitamin E and only vitamin E with the control group, no significant statistical difference was seen.

**Histopathological survey:** Histological studying on liver tissue of groups under consideration was done. Histological parameters in this organ in the control group were normal. However, parameters which in group that has treated by Azathioprine showed some alternations, which can categorize them from mediate tissue damages to severe ones as following:

Necrotic and degenerated random points, vessel congestion and dilatation necrosis and degeneration of preportal region, necrosis and destruction of vessel's epithelial, accumulation of Couper cells by phagocytizing activity around the preportal spaces, wide areas of degenerative necrosis in central parts of hepatic lobes, lymphocytes and granulocytes influence in portal region, wide scattering of degenerated necrosis and bleeding (Fig. 1-3).

Histopathological studies of liver tissue of the group that was treated by vitamin E together with Azathioprine, there was no distinct change or damages due to Azathioprine in liver tissue (Fig. 4). Studying the hepatic

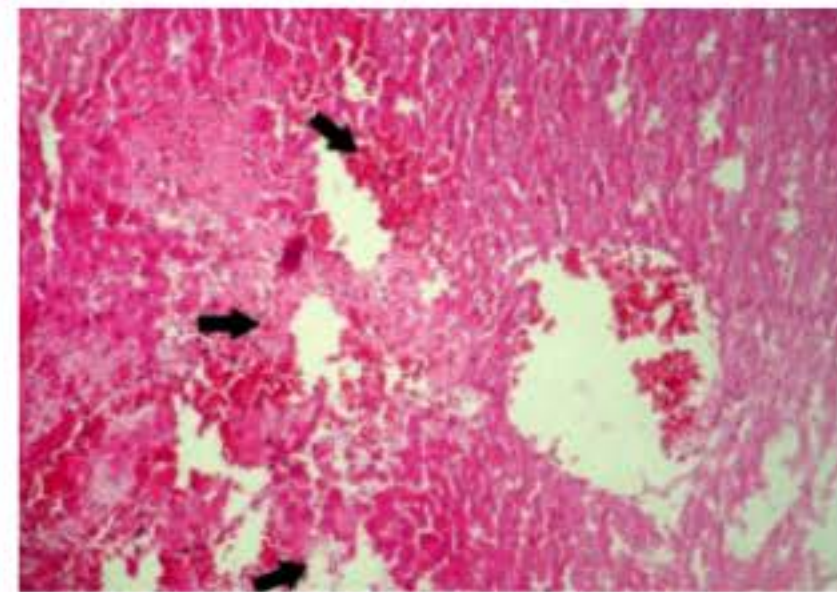


Fig. 1: An image of hepatic tissue in animals of the group, treated by Azathioprine. The arrows show wide areas of degenerative necrosis and hemorrhage in central part hepatic lobes. Pay attention to abnormal dilatation of central vein and its epithelial destruction (Hem toxin-Eosin staining, magnification: 60x)

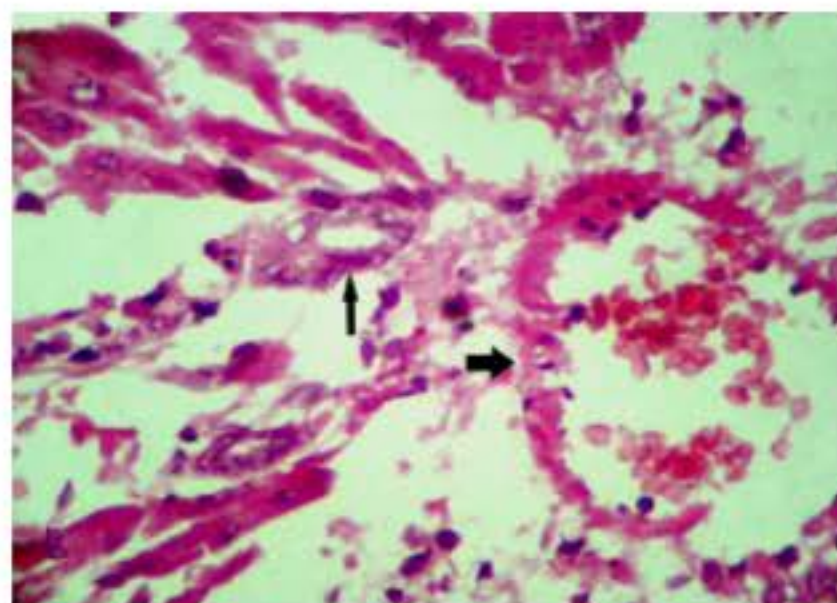


Fig. 2: Liver of animals in Azathioprine group, preportal severe necrosis and portal vein destruction (thick arrow) and epithelium of biliary/cystic duct (thin arrow). Atrophic remained preportal hepatocytes and as a result, their sinusoid spaces are more dilated (Hem toxin-Eosin staining, magnification: 400x)



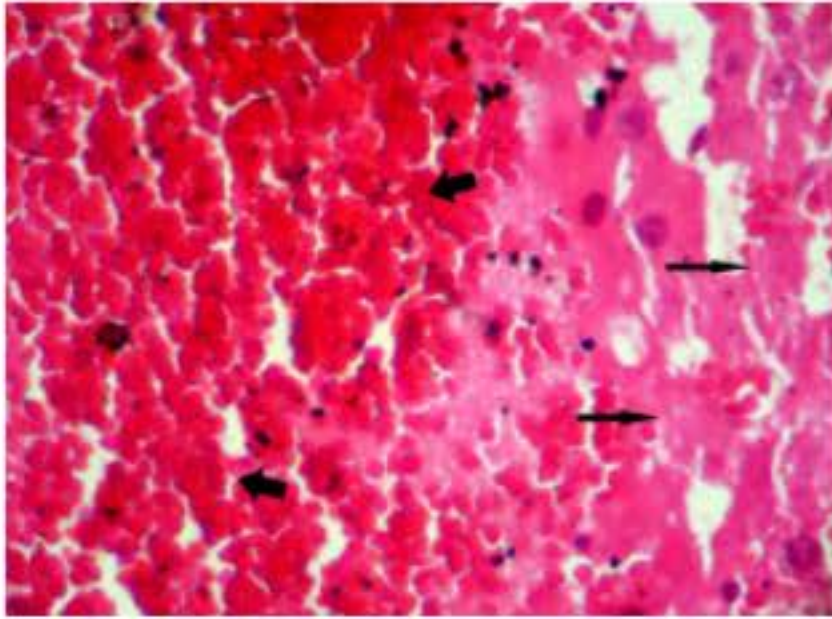


Fig. 3: A microscopic image of liver of animals in group that treated by Azathioprine, shows wide areas of analyzed necrosis (thin arrow) and hemorrhage (thick arrows) (Hem toxin-Eosin staining, magnification: 400x)

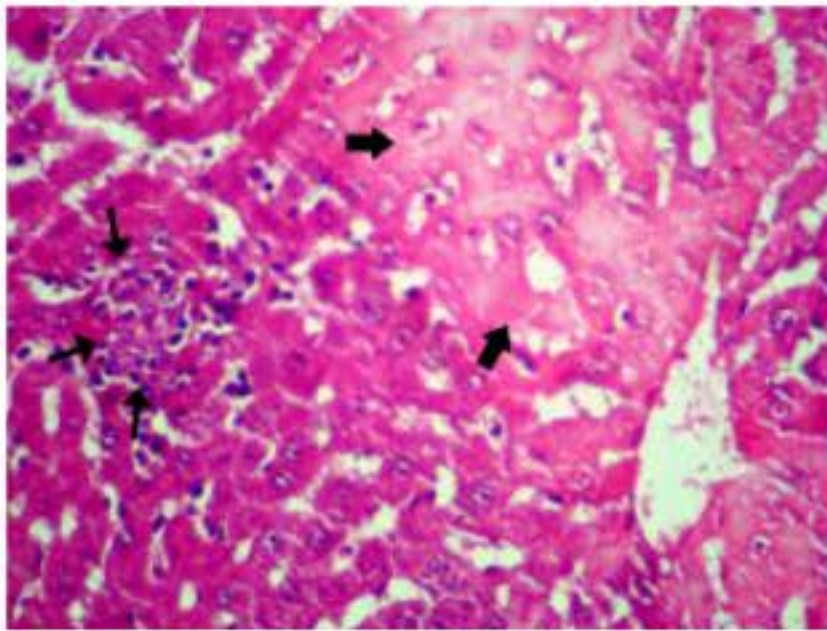


Fig. 4: A microscopic survey of liver of animals in group that treated by Azathioprine and vitamin E together, shows centrilobular necrotic areas (thick arrows) and Couper cells regional accumulation (thin arrows) (Hem toxin-Eosin staining, magnification: 400x)

damages in the group that treated by vitamin E together with Azathioprine, indicated that, there were no microscopic distinct alterations of hepatocyte' damages except centrilobular necrotic regions, lack of slight arrangement and usual arrangement of hepatocyt, slight dilatation of sinusoids, minor dilatation of hepatic central vein and Couper cells' regional accumulation (Fig. 4).

### DISCUSSION

Now a days, diseases such as cancers and auto-immune problems are common throughout the world and increase continuously. In order to encounter against

these troubles, it involves using drugs that not only prevent disease progression, but has also lessen side effects on natural function of cells and organs patient's body. Among these drugs, Azathioprine is one of the widely used of them in these days (Lee and Farrell, 2001; Raza *et al.*, 2003). This drug is prescript in diseases such as IBD, acute lymphoblastic leukemia, rheumatoid arthritis, ulcerative colitis, auto immune hepatitis, IgA nephropathy, dermatologic disease and etc. It can prevent resynthesis of purine bases and so preventing cellular replication by inhibiting the RNA and DNA synthesis. The toxicity of this drug in different organs, such as bone marrow, liver, digestive system and pancreas, following its usage is distinct. The toxicity of this drug is because of producing free radicals in body. Surveying these results presented that Azathioprine causing increment the amount of AST and ALT enzymes. ALT or alanine amino transference is a cytoplasmic enzyme that has more value in diagnosis of hepatic disease than other organs. Increment of this enzyme can be a sign of hepatic failures following the drug prescription. Increment of ALT after prescribing the Azathioprine was reported by Sun *et al.* (1996). No significant changes were seen in ALT amount than the control group at the time of using vitamin E along with the drug that can be due to anti-oxidant and preservative effects of this drug against Azathioprine side effects. AST or aspartate amino transference has various isoenzymes such as muscular, hepatic, pancreatic and etc. so increasing the amount of this enzyme can be seen in different disease. In prescribing Azathioprine, the amount of this enzyme in serum, indicated a significant increase than the control group. This amount, although has been mentioned in natural range in references, it can be due to damages established in body by Azathioprine, but since lactate dehydrogenize enzyme, which is under more consideration in muscular damages, has no significant changes and increasing the amount of ALT enzyme together with AST, therefore doubt about more hepatic failures. In using vitamin E together by the drug, the amount of this enzyme did not present a significant difference in compare with control group, which is because of these drug's anti-oxidant effects against Azathioprine. The increment of this enzyme was reported by Sun *et al.* (1996). By surveying the results achieved from present study, it's cleared that ALP enzyme has significant statistical differences in Azathioprine treated group compare with three other groups. Since, the enzyme has various isoenzymes, we can never relate its difference to hepatic problems, but whereas the amount of Ca and P has no significant difference among the groups of this research and attending that the hepatic and osseous ALP-isoenzymes are the main ones, so we can say that



it's increasing is the consequence of hepatic failures. By surveying the amount of serum's ALP in the group that was treated by Azathioprine together with vitamin E, there was no significant statistical difference in quantities of this enzyme in compare with control group that is the sign of its protective role against Azathioprine side effects. Similar study was down by Amin and Hamza (2005) about the effects of hibiscus, rosmarinus and salvia on Azathioprine-induced toxicity in rats and the results is shown that these drugs can lessen toxicity effect Azathioprine to somehow. The average of serum's bilirubin in the group that was treated only by Azathioprine has significant increment in compare with control group. Since, this drug is metabolized and expelled in liver, can affect on body's antioxidant system, especially on hepatic tissue, increasing bilirubin and other hepatic enzymes such as ALT and AST, perhaps can be due to hepatic tissue damages. Using Azathioprine together with vitamin E can compensate this increase, because this vitamin is a strong antioxidant and by simultaneous consumption of it, the serum's average bilirubin in these groups have no significant statistical differences in compare with control group. The average of serum's cholesterol, LDH, total protein, albumin, HDL, Ca, P and triglyceride have no significant changes in compare with control group in this research. Histopathological results either indicate that simultaneous consumption of vitamin E with Azathioprine, mainly reduces hepatic complications due to treating by Azathioprine. According to surveys that have done, the necrotic regions and hepatic cellular death in liver was so lesser in the group that treated together with Azathioprine and vitamin E than the group that treated only by Azathioprine and was so similar to control group. Generally the pathological results of this study confirm the biochemical results.

### CONCLUSION

First, since the toxicity of Azathioprine in different tissues has been approved, so we should try to use this drug as less as possible except in emergency occasions. Then, as this drug can affect body's antioxidant system, it's better to use vitamins and antioxidant drugs together with it. Finally, it is suggested that the amount of GSH and MDA that are considered part of antioxidant system in body, should be assessed after Azathioprine and vitamin E consumption.

### REFERENCES

Aarbakke, J., G. Janka-Schaub and G.B. Elion, 1997. Thiopurine biology and pharmacology. Trends Pharmacol. Sci., 18: 3-7.

Amin, A. and A.A. Hamza, 2005. Hepatoprotective effects of hibiscus, rosmarinus and salvia on Azathioprine-induced toxicity in rats. Life Sci., 77: 266-278.

Andres, D. and M. Cascales, 2002. Novel mechanism of vitamin E protection against cyclosporine A cytotoxicity in cultured rat hepatocytes. Biochem. Pharmacol., 64: 267-276.

Czaja, A.J., 1999. Drug therapy in the management of type 1 autoimmune hepatitis. Drugs, 57: 48-49.

Di Landro, D., G. Sarzo and F. Marchini, 2000. New immunosuppressive treatment in kidney transplantations. Clin. Nephrol., 53: 23-32.

Kader, H.A., M.R. Mascarenhas, D.A. Piccoli, N.O. Stouffer and R.N. Baldassano, 1998. Experiences with 6-Mercaptopurine and azathioprine therapy in pediatric patients with severe ulcerative colitis. J. Pediatric Gastroenterol. Nutr., 28: 54-58.

Kaplowitz, N., 1997. Interaction of azathioprine and glutathione in the liver of the rat. J. Pharmacol. Exp. Ther., 200: 479-486.

Karakilcik, A.Z., M. Zerim, O. Arslanm, Y. Nazligul and H. Vural, 2004. Effects of vitamin C and E on liver enzymes and biochemical parameters of rabbits exposed to aflatoxin B1. Vet. Hum. Toxicol., 46: 190-192.

Khodabakhshi, S., 2004. Clinical usage of azathioprine and 6-mercaptopurine. Shiraz E-Medical J., Vol. 5, No. 3, <http://semj.sums.ac.ir/vol5/jul2004/khodabakhshi.htm>.

Lee, A.U. and G.C. Farrell, 2001. Mechanism of azathioprine induced injury to hepatocytes: Roles of glutathione depletion and mitochondrial injury. J. Hepatol., 35: 756-764.

Ludwig, D. and E. Stange, 1999. Efficacy of azathioprine in the treatment of chronic active Crohn's disease. J. Gastroenterol., 37: 1085-1091.

Menor, C., M.D. Fernandez Moreno, J.A. Fueyo, O. Escibano and T. Olleros *et al.*, 2004. Azathioprine acts upon rat hepatocyte mitochondria and stress-activated protein kinases leading to necrosis: Protective role of N-acetyl-L-cysteine. J. Pharmacol. Exp. Therapeutics Fast Forward, 104: 269-286.

Pearson, D.C., G.R. May, G. Fick and L.R. Sutherland, 2000. Azathioprine for maintaining remission of Crohn's disease. Cochrane. Database. Syst. Rev., <http://www.ncbi.nlm.nih.gov/pubmed/10796482>.

Ramirez Farias, C., E. Madrigal Santillan, J. Gutierrez Salinas, N. Rodriguez Sanchez and M. Martinez Cruz *et al.*, 2008. Protective effect of some vitamins against the toxic action of ethanol on liver regeneration induced by partial hepatectomy in rats. World J. Gastroenterol., 14: 899-907.

- Raza, M., M. Ahmad, A. Gado and O.A. Al-Shabanah, 2003. A comparison of hepatoprotective activities of aminoguanidine and N-acetylcysteine in rat against the toxic damage induced by azathioprine. *Comp. Biochem. Physiol. C Toxicol. Pharmacol.*, 134: 451-456.
- Sood, A., V. Midha, N. Sood and V. Kaushal, 2000. Role of azathioprine in severe ulcerative colitis: One year, placebo controlled, randomized trial. *Indian J. Gastroenterol.*, 19: 14-16.
- Sun, C., D. Chen, Z. Qu, J. Hao and J. Wang, 1996. Protective effects of radix *Salviae miltiorrhizae* on azathioprine hepatotoxicity in rats. *Zhongguo Zhong Yao Zhi*, 21: 496-498.
- Watanabe, A., N. Hobara, K. Tobe, H. Endo and H. Nagashima, 1979. Biochemical and morphological study on hepatotoxicity of azathioprine in rat. *Acta Med. Okayama*, 33: 5-14.