

Brothers No Longer Sisters: Case Study of Pseudohermaphrodites

Syed Muhammad Jamal, Sajid Malik, Wasim Ahmad, Sayedul Haque
and ¹Habib Ahmad

A study was conducted on male pseudohermaphrodites who got transformed from females to males during the years 1983-85, at the age of eighteen and thirty-two. The younger sister (18 years old) transformed before marriage, whereas, the elder sister (32 years old) remained a housewife for about 20 years. No one else in the family was recorded with similar genital anomaly except one ambiguous female. The clinical reports, morpho-anatomical features and chromosomal pattern reveal their testicular feminization/male pseudohermaphroditism.

Habib Ahmad
Department of Botany
Government Post Graduate
Jehanzeb College,
Saidu Sharif, Swat, Pakistan

Key words: Male pseudohermaphroditism, testicular feminization syndrome, type II 5 α -reductase, androgen receptors

Department of Biological Sciences, Quaid-i-Azam University, Islamabad,
Pakistan

¹Department of Botany, Government Degree College, Matta Swat,
Pakistan

Introduction

Sex of an individual is determined by genetic events that direct the bipotential fetal gonads either to develop testes or ovaries in an individual (Eicher, 1988). In human beings the presence of Y-chromosome (Page, 1988) determines whether a particular human embryo will differentiate into a male (XY) or a female (XX) baby. However, sometimes the individual determined as male or female develops ovarian or testicular tissues giving rise to the complete sex reversal (Eicher, 1988) or differentiate into pseudohermaphrodite (Synder and David, 1957). The pseudohermaphrodites bearing testes with the external genitalia like that of females are referred to as male pseudohermaphrodites, whereas, female pseudohermaphrodites bear ovaries with the external genitalia like that of males (Thompson and Thompson, 1966).

The present study was conducted on male pseudohermaphrodites where an engaged girl and a married woman got transformed into males at the age of eighteen and 32, years respectively.

Materials and Methods

Two in individuals, morphologically females, born of the same parents, transformed into males in District Swat, were investigated in this study. The family pedigree was constructed by interviewing the elders of the family and all information was checked by interviewing different persons of the community. The blood samples were collected and chromosomal analysis was carried out according to the method described by Moorhead *et al.* (1960).

Clinical Report: The 18 years old younger sister (VII-20), an engaged girl, consulted the doctor on complaint of continuous pain in her lower abdomen. She was recognized as male by the doctor and was operated upon followed by gonadotrophin therapy. A year after the transformation, his 32 years old sister, a married woman, was operated upon and transformed into male. Both were females morphologically before transformation, having well-developed mammary glands (gynaecomastia), female external genitalia and large clitorises (clitoromegaly). However, they possessed hirsutism i.e. growth of facial hair and male distribution of pubic hair. They had no menstruation (primary amenorrhea). The pitch of their voices was initially high but gradually changed towards that of males. According to surgical report, right testes was found in the neck of scrotum and the left one in the scrotum. The scrotum had invaginated in the form of labia majora (labioscrotal fold). There was no uterus, oviducts or ovaries. The penis was in the form of large clitoris with perineo-scrotal hypospadias. The urogenital slit was closed, the scrotal pouch was corrected and the testes were descended into scrotum. The perineo-scrotal hypospadias was corrected.

Results and Discussion

Case history (Table 1), clinical reports, morpho-anatomical features and chromosomal pattern (44, xy) of the subjects reflect that they were male pseudohermaphrodites/testicular feminization syndromes as described by Wu *et al.* 1997, Nordenskjold and Ivarsson, 1998. According to Griffith *et al.* (1993) the frequency of testicular feminization syndrome is one in 65,000 male births. The appearance of female secondary sex characters in these patients at puberty is due to estrogens secreted by the Leydig cells of their testes (Ham and Veomett, 1980).

Embryological studies reveal that in the 7th week of gestation, normally each embryo has two pairs of male and female primordial genital ducts i.e. mesonephric or wolffian ducts and paramesonephric or mullerian ducts differentiating into male internal genitalia (epididymis and vas deferens) and female

internal genitalia (oviducts and uterus), respectively (Gilbert, 1997). The differentiation of external genitalia is dependent upon the urogenital slit. If it disappears, formation of male external genitalia results and its persistence gives rise to differentiation of female external genitalia (Sadler, 1995; Ganong, 1997). Development of genital ducts system and external genitalia occurs under the influence of hormones i.e. mullerian inhibiting substance (MIS) and testosterone circulating in the fetus. MIS and testosterone are secreted by the Sertoli and Leydig cells, respectively, of the fetal testes. MIS causes regression of the mullerian ducts, whereas testosterone is responsible for maturation of wolffian ducts into vas deferens and epididymis. Differentiation of male external genitalia occurs under the influence of dihydrotestosterone which is produced from testosterone by an enzyme, type II 5 α -reductase present in genital tissues and prostate, whereas, type I 5 α -reductase is present in the skin throughout the body including scalp. These two types of enzymes are encoded by different genes (Ganong, 1997) localized on chromosome 2 and chromosome 5, respectively (Thigpen *et al.*, 1992).

Male pseudohermaphroditism or testicular feminization syndrome, where the tissues of external genitalia develop and differentiate like that of females, is a hereditary character (Thompson and Thompson, 1966) which occurs either due to presence of a mutation in androgen receptors gene present on chromosome X and transmitted from a carrier mother to the offspring (Govan *et al.*, 1988; Griffith *et al.*, 1993) or deficiency of type II 5 α -reductase encoded by a recessive gene localized on chromosome 2 (Thigpen *et al.*, 1992) or because of defective embryonic testes, which are unable to secrete MIS due to a mutant gene present on chromosome 19 (Cohen-Haguenaer *et al.*, 1987). This condition occurs due to congenital deficiency of 17 α -hydroxylase, encoded by a recessive gene present on chromosome 10 (Sparkes *et al.*, 1991).

As it is clear from the pedigree (Fig. 1), the family initially comprised of eleven persons i.e. two parents, eight sisters and a brother. Now they are three brothers and six sisters. One of their sisters (VII-10), though had married, could not produce any child and is ambiguous sexually. The family refuses to provide information about her due to tribal norms. Remaining five sisters (VII-8, VII-16, VII-18, VII-21 and VII-22) have married and have children.

Personal history of the subjects shows that they had feminine body contour, and were involved in household activities before transformation. The younger one was engaged and elder one remained a housewife for about 20 years. They were more powerful among their age group females. Emotionally, they behaved as normal females but later on their sentiments inclined towards that of males, however they were regarded as females and they used to present women society. Before transformation, the elder one used to shave his beard and hide his face to other members of the community. After operation, their behavior and emotions were changed so rapidly that they married in a short period of 1-3 years. Presently, the younger one (VII-20) is a father of two children (VIII-9 and VIII-10). His fertility is perhaps due to the fact that previously, his testes were not exposed to the abdominal temperature for longer time as he was diagnosed in the early days of puberty. The elder one has no children and his sterility is perhaps due to the exposure of his testes to higher abdominal temperature for longer time. Chromosomal analysis show a male 44, XY karyotype.

Pinsky *et al.* (1978) Nordenskjold and Ivarsson (1998) reflect that the cases described here are due to the presence of

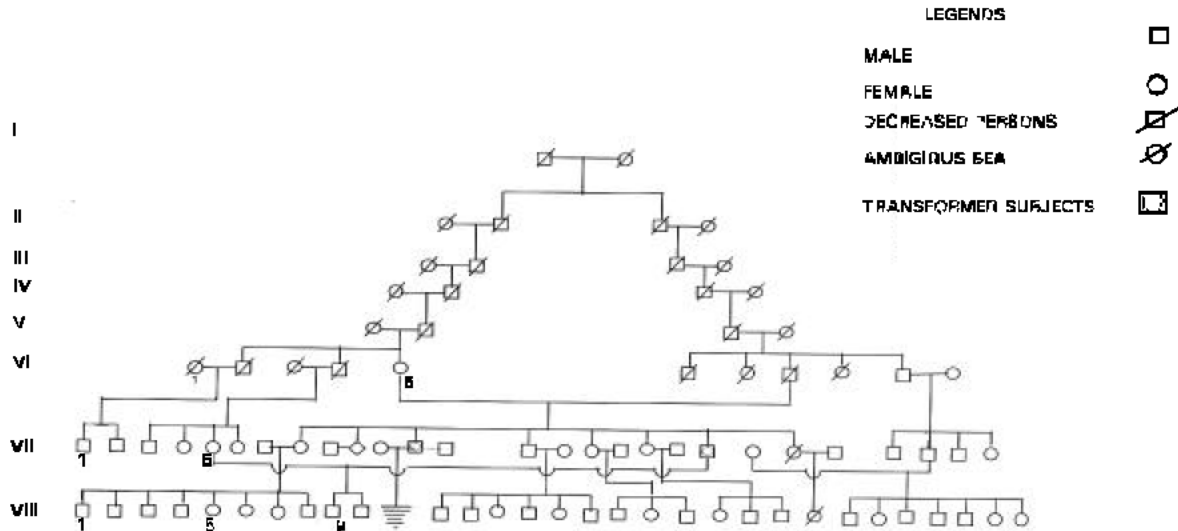


Fig. 1: Pedigree of the family with transformed subjects (male pseudohermaphrodites)

Table 1: Case history of male pseudohermaphrodites

Subjects	Year of Birth	Age (years) at the time of :			Children		
		Marriage as female	Transformation	Marriage as male	No.	Year of Birth	Sex
Younger one (VII-20)	1965	18	19	2	i. 1991 ii. 1997	Male Male	
Elder one (VII-12)	1953	32	35	--	--	--	

mutations either in type II 5 α -reductase or dihydrotestosterone receptors genes, localized on human chromosomes 2 and X, respectively. If it had been due to mullerian inhibiting substance (MIS) deficiency, the mullerian ducts system would have developed into female internal genitalia in the subjects (Behringer *et al.*, 1994; Mishina *et al.*, 1998). Similarly, if the cases had been due to congenital deficiency of 17 α -hydroxylase, synthesis of androgens would have not taken place resulting in neither differentiation of male internal genitalia (Walter *et al.*, 1998) nor hirsutism in the subjects.

Acknowledgments

The authors are thankful to the family members for their co-operation and hospitality. The help of Mr. Tariq Shah, Mr. Tasnimul Haque, Mr. Ikram Elahi, Mr. Arshad, Mr. Nasir, Mr. Ambara Khan, Shahinshah Gilani, Hayat Khan, Sajid, Ansar and Irfan during the course of this study are highly acknowledged.

References

Behringer, R.R., M.J. Finegold and R.L. Cate, 1994. Mullerian inhibiting substance function during mammalian sexual development. *Cell*, 79: 415-25.
 Cohen-Haguener, O., J.Y. Picard, M.G. Mattei, S. Serero, N. Van Cong, M.F. de Tand, D. Guerrier, M.C. Hors-Cayla, N. Jossa and J. Frezal, 1987. Mapping of the gene for anti-mullerian hormone to the short arm of human chromosome 19. *Cytogenet. Cell Genet.*, 44: 2-6.
 Eicher, E.M., 1988. Genetic control of primary sex determination in mice. *Genome*, 30: 22-23.
 Ganong, W.F., 1997. Review of Medical Physiology. Appelton and Lange. Norwalk, Connecticut/San Mateo, California.
 Gilbert, S.F., 1997. Developmental Biology. Sinauer associates, Inc. Publishers. Sunderland, Massachusetts.
 Griffith, A.D.T., J.H. Miller, D. T. Suzuki, R. C. Lewontin, and W.M. Gelbart, 1993. An Introduction to Genetic Analysis. W. H. Freeman and company/New York.

Ham, R. G. and M.J. Veomett, 1980. Mechanisms of Development. The C. V. Mosby Company. St. Louis, Toronto and London.
 Mishina, Y., R. Rey, M.J. Finegold, M.M. Matzuk, N. Jossa, R.L. Cate and R.R. Behringer, 1996. Genetic analysis of the Mullerian-inhibiting substance signal transduction pathway in mammalian sexual differentiation. *Genes Dev.*, 10: 2577-2587.
 Moorhead, P.S., P.C. Nowell and W.J. Mellman, 1960. Chromosomes preparation of leukocytes cultured from human peripheral blood. *Exp. Cell. Res.*, 20: 613-616.
 Nordenskjold, A. and S.A. Ivarsson, 1998. Molecular characterization of 5-alpha-reductase type 2 deficiency and fertility in a Swedish family. *J. Clin. Endocr. Metab.*, 83: 3236-3238.
 Page, D.C., 1988. The sex determination gene of the Y-chromosome. *Genome*, 30: 22-24.
 Pinsky, L., M. Kaufman, C. Straisfeld, B. Zilahi and C.S.G. Hall, 1978. 5-Alpha-reductase activity of genital and nongenital skin fibroblasts from patients with 5-alpha reductase deficiency, androgen insensitivity or unknown forms of pseudohermaphroditism. *Am. J. Med. Genet.*, 1: 407-416.
 Sadler, T.W., 1995. Langman's Medical Embryology. Williams and Wilkins. Baltimore, London and Tokyo.
 Sparkes, R.S., I. Klisak and W.L. Miller, 1991. Regional mapping of genes encoding human steroidogenic enzymes: P450_{scc} to 15q23-q24, adrenodoxin to 11q22; adrenodoxin reductase to 17q24-q25 and P450_{c17} to 10q24-q25. *DNA Cell Biol.*, 10: 359-365.
 Synder, L.H. and P.R. David, 1957. The Principles of Heredity. D. C. Heath and Company, Boston.
 Thigpen, A.E., D.L. Davis, A. Milatovich, B.B. Mendonca, J. Imperato-McGinley, J.E. Griffin, U. Francke, J.D. Wilson and D.W. Russell, 1992. The molecular genetics of steroid 5-alpha-reductase 2 deficiency. *J. Clin. Invest.*, 90: 799-809.
 Thompson, J.S. and M.W. Thompson, 1966. Genetics in Medicine. W. B. Saunders Co., Philadelphia and London.
 Walter, J.B., I.C. Talbot, H.A. Gardner, P.F. Halleran, M. Zuckerman, A.G. Bird, and A. Forbes, 1996. Walter and Israel General Pathology. Churchill Livingstone. N. Y. London and Tokyo.
 Wu, M.H., M.F. Hsieh, M.P. Yau and C.C. Hsu, 1997. Bilateral laparoscopic gonadectomy for testicular feminization syndrome. *Kao-Hsiung-I-Hsuch-Ko-Hsuch-Tsa-Chih.*, 13 : 511-5.