
Research Paper

The Sciences 2 (1): 7-11
January-February, 2002

*The Sciences (ISSN 1608-8689)
is an International Journal
serving the International
community of Medical
Scientists*

*For further information about
this article or if you need
reprints, please contact:*

A. G. Pillay,
Department of Biomedical
Sciences,
Faculty of Medicine and Health
Sciences, University Putra
Malaysia, 43400 UPM, Serdang,
Selangor, Malaysia

E.mail: agpillay@hotmail.com

Processed Bovine Tunica Vaginalis as a Biomaterial for the Repair of Large Abdominal Wall Defects in Surgical Treatment

Wong Siew Tung, Jamaludin Zainol, A. G. Pillay,
²Norimah Yusof and ¹Loqman Mohamad Yusof

The repair of large abdominal wall defects remains a complex surgical problem of insufficient autogenous tissue for adequate abdominal wall closure. The aim of this investigation was to investigate the effectiveness of processed bovine tunica vaginalis, as a biomaterial in repairing such large abdominal wall defects. The rats are used as an experimental models. Twenty-four adult laboratory rats were randomly divided into two equal groups. In the treated group, an abdominal wall defect was created in each animal and then repaired with processed bovine tunica vaginalis. In the control group, a midline incision was made at the abdominal wall muscle and then closed with suture. Macroscopic examination of the abdominal wall showed that there was no evidence of herniation, seroma and distortion of the grafts. Adhesion between the biomaterial and the greater omentum was observed in all animals, but there was no adhesion to the underlying visceral organs. The inflammatory response gradually decreased by time. The biomaterial incorporated in the host tissue by the ingrowth of both collagenous and muscular tissues, and also by the formation of blood vessels and peritoneal lining. This investigation showed that the processed bovine tunica vaginalis can be used as an effective biomaterial to repair large abdominal wall defects.

Key words: Tunica vaginalis, biomaterial, large abdominal wall defects

Department of Biomedical Sciences, Faculty of Medicine and Health Sciences, ¹Department of Surgery, Faculty of Veterinary Medicine, University Putra Malaysia, Serdang, Selangor, Malaysia, ²Division of Agrotechnology and Biosciences, Malaysian Institute for Nuclear Technology Research, Bangi, 43000 Kajang, Selangor, Malaysia

ANSI*net*
Asian Network for Scientific Information

Introduction

The surgical repair of large abdominal wall defects remains a significant problem. Most abdominal wall defects can be repaired by primary closure. However, where the defect is larger and there is tension on the closure of the wound, the use of a prosthetic material is indicated (Park and Lakes, 1992). A variety of synthetic prostheses such as polypropylene mesh (PPM) and expanded polytetrafluoroethylene (PTFE) and biologically derived materials such as human cadaveric dura mater, bovine pericardium and collagen xenografts and Polyglactin mesh (Vicryl) have been used for repairing large abdominal wall defects. However, none of these currently available prostheses is entirely satisfactory in repairing the abdominal wall defects (Takahashi *et al.*, 1994).

The aim of this project is to investigate the effectiveness of the processed bovine tunica vaginalis in repairing a rat abdominal wall defect model. Tunica vaginalis is the serous membrane covering the front and sides of the testis and epididymis. Bovine tunica vaginalis is used because it is derived from the peritoneum, which is the serous membrane originally lining the wall of the abdominal cavity (Werkmeister *et al.*, 1998). So, it imitates the properties of the natural abdominal wall. Furthermore, it does not carry too much rejection properties because it is supplied by little blood vessels. It is also easily available and inexpensive.

Materials and Methods

Twenty four healthy adult laboratory rats of either sex weighing between 200-250g were used. The rats were randomly divided into two groups (12 rats each). These are as follows:

- a. Treated Group: An abdominal wall defect was created and repaired with processed tunica vaginalis
- b. Control Group: An abdominal wall midline incision was created and closed with suture

Four rats from each group were randomly selected and sacrificed at time intervals of weeks 1, 2 and 4 after surgery.

Preparation of Processed Bovine Tunica Vaginalis: Tunica vaginalis was peeled off with care from the bovine testis, washed thoroughly and kept in normal saline at 4°C for short-term storage. They were then transported to the Tissue Bank of Malaysian Institute for Nuclear Technology Research (MINT) in Bangi, Selangor, for processing. Here they were cleaned with sterilized distilled water and sterile normal saline, disinfected with sodium hypochlorite 0.05%, freeze-dried with freeze dryer and irradiated by gamma (γ) rays (Cobalt 60, Type JS 8900, IR - 174) at 17-25 kGy. This sterilised biomaterial was used to repair the abdominal wall defect in rats (Rodgers *et al.*, 1982).

Experimental Procedures: All surgical procedures were conducted under general anesthesia induced by a combination of ketamine 50mg kg⁻¹ body weight (Ketamav 100, Mavlab Pty, Ltd, Queensland) and xylazine 8mg kg⁻¹ body weight (Xylazine Hydrochloride, Indian Immunologicals Ltd., Hyderabad). The animal was anesthetized by an intramuscular injection at the quadriceps muscles. A 3cm long ventral abdominal midline incision was made. The skin and subcutaneous tissues were dissected from the abdominal muscle by a blunt dissection. In the treated group, using a Malaysia ten-cent coin as a template, a full thickness segment in the midportion of the abdominal wall (muscle, fascia

and peritoneum) identical to the size of the coin was excised. A piece of processed tunica vaginalis was cut to the same size, bathed in normal saline and sutured to the abdominal wall margin to fit into the defect with the help of 3-0 chromic catgut suture. The sutures were spaced 3mm apart around the biomaterial, with an overlap of 2-3mm between the implanted biomaterial and the muscle wall of abdomen. Later on, the skin was closed with 4-0 monofilament nylon suture (Takahashi *et al.*, 1994).

In the control group, a sham operation was performed in each animal where a 2cm long midline incision was made in the abdominal wall muscle and then closed with 3-0 chromic catgut suture in a simple continuous pattern. Similarly, the skin was closed by a 4-0 monofilament nylon suture.

No antibiotic prophylaxis was used in either group. Bandages were applied to all the animals. The animals were maintained with food and water ad libitum. The abdominal wounds were assessed regularly for evidence of infection.

Four rats from each group were randomly selected and sacrificed with a lethal dose of chloroform (CHCl₃) after 1, 2 and 4 weeks. The abdominal wall was assessed for obvious defects, herniation, infection, distortion of original shape of the implant, and seroma (Jenkins *et al.*, 1983). The abdominal wall was resected to include 5mm margins around the perimeter of the biomaterial. Any of the underlying viscera which was found adhered into the biomaterial (treatment group) or into the native abdominal wall (control group) of the animals was freed. Using the adhesion scoring system described by Jenkins *et al.* (1983), qualitative assessment of adhesions were made by classification into four grades:

- | | |
|----|---------------------------------------------------------------------------------------------------|
| 0= | no adhesions |
| 1= | minimal adhesions that could be freed by gentle blunt dissection |
| 2= | moderate adhesions that could be freed by aggressive blunt dissection |
| 3= | dense adhesions that required sharp dissection to free the biomaterial from the abdominal viscera |

The excised blocks of tissues were submitted for microscopic evaluation by conventional histology. Foreign body reaction, fibrosis, presence of fibroblasts, host tissue incorporation of processed tunica vaginalis etc., were assessed.

Results

Macroscopic Examination

Treated group: It was observed that the closure of skin appeared to be equally secured in all the animals, except for one where the suture was broken at 1st week. All the implants were retained in their original shape and position. The wound appeared to have been contracted with a slight decrease in its original diameter. There was no identifiable hernia and the patches appeared to be secure in all the animals. The biomaterial was held firmly by the sutures. At any instance, there was no evidence of fragmentation of the biomaterial. Moreover, all the biomaterials were integrated with the abdominal wall with an evidence of extensive growth of new tissue at every advanced post-operative interval. New blood vessel formation (neovascularization) could be clearly seen under naked eye observation. Blood vessels were protruding and gradually progressing into the biomaterial from the surrounding host tissue. None of the wounds became infected except in one animal where the suture of the skin was broken. In this animal the wound was swollen with the accumulation of pus at week 1. There was no evidence of seroma at the repaired area. The dead space between the skin and the abdominal wall was obliterated completely during the operation. Therefore, there was no accumulation of body fluid.

Control group: Skin closure was well-secured in every animal. There was no evidence of herniation or infection in all these animals. The sutures were holding the two edges of the cut muscles very well and did not tend to tear. During the first week, after operation, the midline incision was covered with a thin film of transparent connective tissue. Scar tissues were obviously observed at the site of midline incision at week 2 and 4. No seroma was observed in any of the animals.

Formation of Intra-abdominal Adhesion

Treated group: There was no evidence of adhesion between the biomaterial and the underlying visceral organs in all the experimental animals, although there was frequent formation of adhesion between the peritoneal side of the biomaterial and the greater omentum.

Control group: None of the animals showed adhesions between the abdominal wall and the underlying viscera.

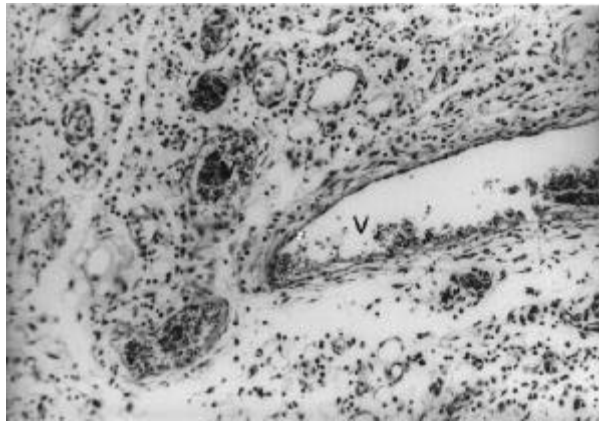


Fig. 1: One week after treatment. Extensive formation of new blood vessels (v) and infiltration of inflammation cells in the biomaterial. H & E stain, X200.

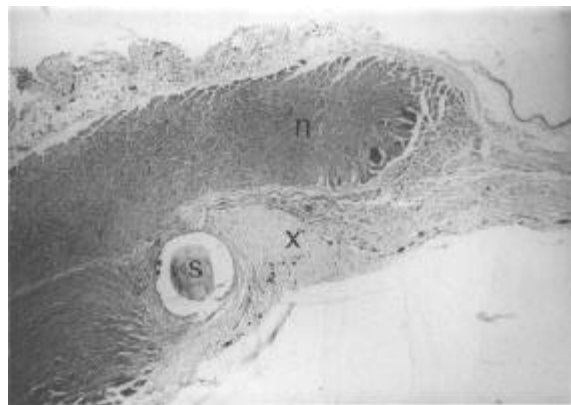

Fig. 2: Four weeks after treatment. Incorporation of Biomaterial (x) with native muscle (n) of the host by infiltration of muscle and collagen fibres, suture (s), H & E stain, X40.

Histological Evaluation

Treated group: There was a significantly high inflammatory response during the 1st week. There was evidence of infiltration by polymorphonuclear leukocytes and lymphocytes throughout the biomaterial (Fig. 1), most prominent at its periphery and

around the suture holes. The inflammatory response was gradually reduced in every advancing period. The growing peritoneum bridged over the gap between the biomaterial and the host tissue continued to grow over the undersurface of the biomaterial across the wound. At 1st week, the growth of peritoneum was prominent only at the junctional area. A bulging which is filled with connective tissues and blood vessels in an irregular and unorganized form was observed at the peritoneal side of the biomaterial. During advancing periods (2nd and 4th weeks), well-organized peritoneal lining was formed as an uninterrupted continuous sheet. Mesenchymal cells and fibroblasts were observed throughout the biomaterial. During the first week, the collagen fibers were delicate, immature and observed in an unorganized form. But during the second week, the fibers were infiltrated throughout the biomaterial with extensive growth in a more organized form. Later at 4 weeks, the collagen fibers were increased in amount, density and coarseness and became more clearly defined and well organized. A firm connection was established between the biomaterial and the host tissue by the incorporation of collagen fibers and cellular elements (Fig. 2). During the 1st week, myoblasts were observed in the vicinity of the native host muscles at the junctional area with biomaterial. There was a clear evidence of development of young muscles which was getting more and more prominent

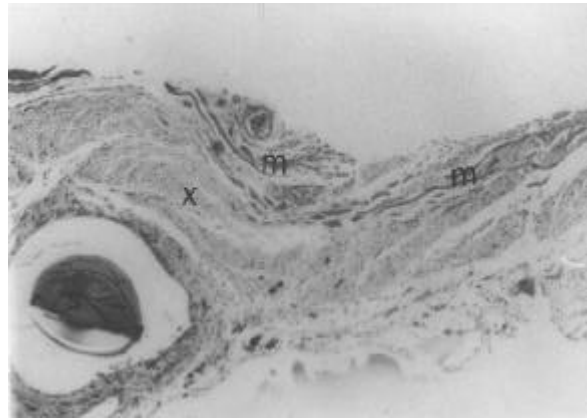


Fig. 3: Four weeks after treatment. Infiltration of the muscle fibres (m) into the biomaterial (x), H & E stain, X65.

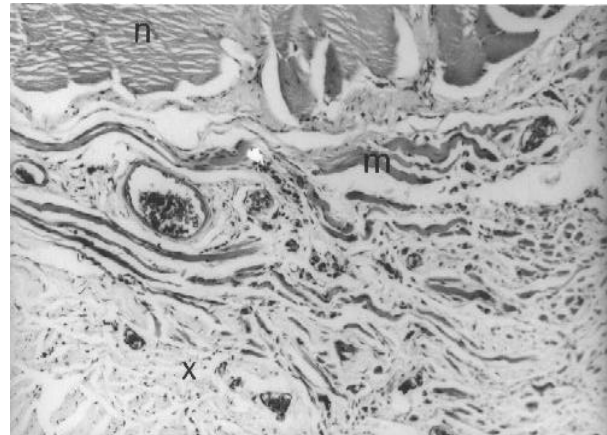


Fig. 4: Four weeks after treatment. New muscle fibres (m) extended from near the host native muscle (n) into biomaterial (x), H & E stain, X100.

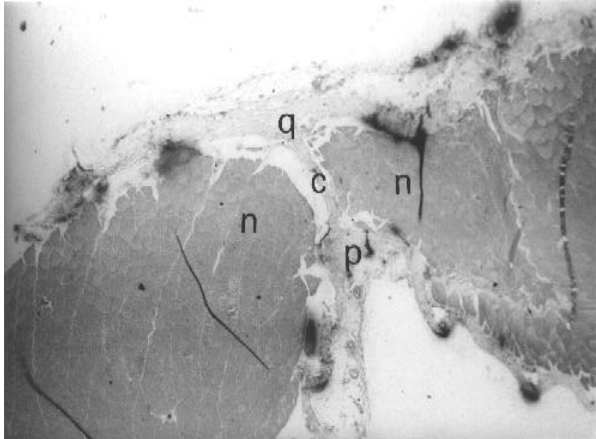


Fig. 5: Four weeks after sham-operation, Control. Connective tissue (c) within the gap between the two edges of native muscle (n) connect the peritoneum (p) and subcutaneous tissues (q), H & E stain, X40.

at the junctional area close to the native host muscle. On 2nd and 4th weeks, the myoblasts infiltrated throughout the biomaterial and some of them were in the transitional stage growing into delicate muscle fibers. The over-all structure of these muscle fibers showed that they were in the early stages of development and later became more clearly defined with peripherally located nuclei. The diameter of the newly formed muscle fibers increased gradually during advancing period of growth. They became well defined, matured and expanded further into the biomaterial (Figs. 3 and 4). Many native muscle fibers located near the junctional area showed cytoplasmic vacuolation. Neovascularization or the formation of new blood vessels was observed in the biomaterial (Fig. 1). During the first week, the blood vessels were most prominent within the connective tissue bulging in the peritoneal side of the biomaterial. The shape and size of these blood vessels varied greatly. Blood clots could be observed within these newly formed vessels. It was observed that some blood islands appeared in the biomaterial, similar to early developmental stages.

Control group: On macroscopic examination, the midline-incision wound was apparently closed outside by scar tissues. However, the histological examination showed a narrow gap between the edges of the wound. The gap was not filled with any new tissue during the first week. In advancing periods (2nd week and 4th week), the gaps were filled with connective tissue in an unorganized form, which later became the scar tissue. This tissue passes between the two edges of the wound, bridging the peritoneal lining inside and the dermis outside (Fig. 5). However, a narrow space was left between the native muscles and the connective tissue bridging. There was no evidence of new muscle formation at or near the wound at anytime. There was an accumulation of inflammatory cells near the cut-edges of the native muscle in the first week. The inflammatory cells continued to remain at week 2 in the interstitial spaces of the connective tissue. However, in the 4th week, there was only a minimal amount of inflammatory cells. During the first week, the peritoneal lining across the gap between the native wall and biomaterial was not formed. There was also no evidence of vascularization in the wound. By the second week, the peritoneal lining was found bridging across the gap of the wound. The blood vessels have also appeared in the connective tissue. There was no evidence of development of new muscle fibers at or near the wound.

Discussion

Macroscopic Examination: In one of the experimental animals, the suture gave way leading to the exposure of the wound thereby causing an infection. This was because the animal used to bite around the bandage and the suture thread, which caused their removal and spread of infection.

In this investigation of using processed bovine tunica vaginalis for repairing abdominal wall defects, none of the wounds became infected except in one animal mentioned earlier. However, it is known from the literature that the post-operative infection of the wound is one of the common complications in the repair of abdominal wall defects while using prostheses. The EPTFE (expanded polytetrafluoroethylene) patches and PPM (polypropylene mesh) are two of the commonly used prostheses. However, as described by Werkmeister *et al.* (1998), these prostheses are prone to infection. This would clearly suggested that the processed bovine tunica vaginalis is practically superior to both EPTFE and PPM in repairing the abdominal wall defects.

The processed bovine tunica vaginalis were held firmly in its position by the suture. The suture contributed to the strength at the interface between the biomaterial and the host tissue during the early stages of repair and retained the biomaterial with adequate strength to facilitate repair process. Later, the interface became stronger since collagenous connective tissue and muscle fibers infiltrated into the biomaterial.

In this investigation, there was no sign of fragmentation of the biomaterial. Neither experimental nor control animals demonstrated hernia at any time of evaluation. The occurrence of hernia at the interface was prevented by the firm incorporation of the biomaterial with host tissue. In an extensive review of literature, Park and Lakes (1992) found that the incidents of abdominal incisional hernia after primary closure ranged from 1 to 3%. Earlier studies indicate that 30% of patients, in whom the hernias have been repaired without using any prosthetic patches, had the recurrence of herniation (Bauer *et al.*, 1988). Some of the prosthetic materials (EPTFE, PPM) which were used to repair hernias, have the weaknesses such as erosion into intra-abdominal organs, mesh extrusion and lack of incorporation with host tissue, all of which subsequently led to herniation.

In this research work, even though processed bovine tunica vaginalis were retained in its original shape, contracture of the wound resulting in a decreased diameter was observed. Absence of herniation of abdominal content, fragmentation and distortion of the implant had proved the benefits of processed bovine tunica vaginalis as an effective biomaterial in repairing abdominal wall defects. In the control animals, a thin film of transparent connective tissue was found overlying the midline incision during the first week. This possibly indicated the beginning of healing process. By the 2nd and 4th weeks, the midline incision wound had been apparently repaired by scar tissue.

Formation of intra-abdominal Adhesion: One of the important clinical problems associated with the use of prosthetic materials is the adherence of the material to the intestinal wall leading to fistula. This intra-abdominal adhesion would require reoperation and removal of the patch. Processed bovine tunica vaginalis demonstrated an advantage is that it can be placed in direct contact with underlying viscera without stimulating any intra-abdominal adhesion. However, adhesion was formed between the peritoneal side of the biomaterial and the greater omentum. The use of preserved human dura mater as a biomaterial had shown similar result (Rodgers *et al.*, 1982). In a case report of an infected full-thickness abdominal wall defect treated with human dura mater allograft, the omentum was sutured to the peritoneal side of the graft to avoid subsequent adhesion to the small bowel (Takahashi *et al.*, 1994). Extensive visceral adhesions leading to biomaterial-induced intestinal fistula had been reported while using polypropylene mesh to repair abdominal wall defects (Werkmeister *et al.*, 1998). The control animals never showed intra-abdominal adhesion.

Histological Evaluation: The attack of body's immune system on the implant can cause failure of the biomaterial to serve as the tissue replacement. Biocompatibility involves the acceptance of the biomaterial by the surrounding tissues and by the body as a whole (Park and Lakes, 1992).

Result of this research work showed that the inflammatory response in all the animals were significantly high during the first week, this was an immediate response initiated by the tissue injury when the abdominal wall defect was created. Inflammation is necessary as the transitional linking stage between tissue damage

and repair of connective tissue (Dumitriu, 1994). Inflammatory cells such as polymorphonuclear leukocytes, macrophages and lymphocytes were found throughout the biomaterial (Fig. 1), especially at the interface between the biomaterial and the host tissue. These cells were responsible for debridement of the injured tissue, elimination of foreign material and mediation of repair. The inflammation process gradually decreased in every advancing period in both the experimental and control animals. Maximum reduction of inflammatory cells were noticed on 4th week.

Proliferative phase of the repair process, also referred to as fibroplasia followed the inflammatory process. This phase is characterized by the aggregation of fibroblasts into the injured area and the formation of capillary blood vessels. Soon after the injury, mesenchymal cells evolve into the migratory fibroblasts that move into the injured site (Park and Lakes, 1992). These mesenchymal cells and fibroblasts were frequently observed throughout the biomaterial. In this investigation, collagen fibers and ground substance were synthesized and deposited by the migrating fibroblasts as indicated by the gradual spread of newly formed tissue in the biomaterial. The collagen fibers observed in the biomaterial in the 1st week, were delicate, immature and unorganized. Later on 2nd and 4th week, the amounts of collagen fibers increased and infiltrated throughout the biomaterial in a well-defined and organized form. The increasing amount of matrix accounted for the healing wound strength. In a normal wound healing process, the collagen restructuring process requires more than 6 months to complete, although the wound strength never reaches the original value (Park and Lakes, 1992). In this research work, the wound strength of repair was not evaluated by using tensile strength or breaking strength test. However, the firm integration between biomaterial and host tissue produced by the infiltration of fibrocollagenous connective tissues could be observed (Fig. 2). This has given the strength at the interface between the biomaterial and the host tissue, which is the most frequent site of failure for prosthetic materials in the abdominal wall. One of the causes of failure in EPTFE patches, the lack of permeability to allow tissue ingrowth of fibrocollagenous tissue (Werkmeister *et al.*, 1998).

New capillaries in various sizes and shapes, and blood islands as in early development stages were observed throughout the biomaterial (Fig. 1). This characteristic showed the advantage of processed bovine tunica vaginalis in supporting new blood vessel formation (angiogenesis). This again emphasizes that the host body has accepted this biomaterial as a part of its own tissue. Myoblasts have been observed throughout the biomaterial. These myoblasts were possibly derived from the mesenchymal cells. They eventually evolved into young muscle fibers and later into more matured and well-defined muscle fibers, which extended inward into the biomaterial (Figs. 3 and 4). The regeneration of muscle fibers might have also occurred from the outgrowth of fibers on either side of the injury or from the satellite cells located within the muscle's connective tissue sheath. However, this is not confirmed by this study. Some of the native muscle fibers near the interface showed cytoplasmic vacuolation within the sarcoplasm. This might indicated the degeneration of injured muscle. Bridging of peritoneal lining across the wound was observed and this could contribute to the prevention of intra-abdominal adhesion between the biomaterial and the host tissue. In the control animals the wound healing process was observed to be imperfect where a scar tissue has formed just to seal off the edges of the wound. Although the midline incision wound was

apparently closed from outside macroscopically, a narrow gap existed between the edges of the wound on microscopic observation. Moreover, during the 1st week some part of this gap was not filled with any tissue. Muscle regeneration was not observed between the two edges of wounded muscle even in advancing periods (week 2 and 4). Therefore, a weak point is formed in this place where the wound could be easily ruptured due to inadequate mechanical strength and subsequently lead to future herniation. This is quite possible that the recurrence of herniation as described by Bauer *et al.* (1988) should have been caused by the persistence of this weak point with unfilled gap observed in this control study.

Therefore, this investigation indicated that the processed bovine tunica vaginalis has significant advantage as an abdominal wall replacement. The results had demonstrated the effective use of this biomaterial in repairing large abdominal wall defects. Processed bovine tunica vaginalis is not prone to fragmentation and infection. Furthermore, it also prevents the herniation of abdominal contents. It does not stimulate the formation of any adhesion with the underlying viscera. The incorporation of this biomaterial with the host tissue is proved by the infiltration of mesenchymal cells into the biomaterial and infiltration of collagenous connective tissues throughout the biomaterial, the ingrowth of muscle fibers, formation of new blood vessels and bridging of peritoneal lining across the biomaterial.

It is concluded that with further investigation and improvements, processed tunica vaginalis could be considered as a successful and effective alternative for repairing large abdominal wall defects.

Acknowledgment

This research project was sponsored by the Faculty of Medicine and Health Science, University Putra Malaysia.

References

- Bauer, J. J., B. A. Salky, M. I. Gelernt and I. Kreef, 1988. Repair of large abdominal wall defects with expanded polytetrafluoroethylene (PTFE). *Annals Surgery*, 206: 765-769.
- Dumitriu, S., 1994., Polymeric biomaterials. Marcel Dekker, Inc., 99-108.
- Jenkins, S. D., T. W. Klamer, J. J. Parteka and R. E. Condon, 1983. A comparison of prosthetic materials used to repair abdominal wall defects. *Surgery*, 93: 392-398.
- Lamb, J. P., T. Vitale and D. L. Kaminski, 1983. Comparative evaluation of synthetic meshes used for abdominal wall replacement. *Surgery*, 93: 643-648.
- Park, J. B. and R. S. Lakes, 1992. Biomaterials, an introduction. Second edition. Plenum Press, 1-6, 223-244.
- Rodgers, B. M., J. W. Maher and J. L. Talbert, 1982. The use of preserved human dura for closure of abdominal wall and diaphragmatic defects. *Annals Surgery*, 183: 608-610.
- Takahashi, M., K. Ono, R. Wakakuwa, O. Sato, Y. Tsuchiya, G. Kamiya, K. Nitta, K. Tajima and K. Wada, 1994. The use of a human dura mater allograft for the repair of a contaminated abdominal wall defect: Report of a case. *Surgery Today*, 24: 468-472.
- Werkmeister, J. A., G. A. Edwards, F. Casagrande, J.F. White, J.A.M. Ramshaw, 1998. Evaluation of a collagen-based biosynthetic material for the repair of abdominal wall defects. *J. Biomed. Mater. Res.*, 39: 429-436.

MS received 22nd September, 2001; accepted 20th November, 2001