



Journal of Medical Sciences

ISSN 1682-4474

science
alert

ANSI*net*
an open access publisher
<http://ansinet.com>

JMS (ISSN 1682-4474) is an International, peer-reviewed scientific journal that publish original article in experimental & clinical medicine and related disciplines such as molecular biology, biochemistry, genetics, biophysics, bio-and medical technology. JMS is issued six times per year on paper and in electronic format.

For further information about this article or if you need reprints, please contact:

A.G. Pillay
St. Matthew's University-
School of Medicine
Safe-Haven, Leeward Three
Post Box: 32330 SMB
Grand Cayman (BWI), UK

Experimental Evaluation of Repair Process of Burn-Wounds Treated with 15 UMF Manuka Honey

Yam Mun Fei, ¹A.G. Pillay and ²Jamaludin Zainol

In this experiment, 30 laboratory albino rats were tested to compare the effectiveness of 15 UMF manuka honey in the treatment of burn wounds in contrast to the control group for wounds' tensile strength and histopathological changes during healing process. The treatments were applied on the deep partial thickness burn wounds inflicted by modified electric solder (Yam Mun Fei, 2002). Three rats from each group were studied at day 5, day 10, day 15 and day 20 for histopathological and tensile strength studies. Three rats were randomly selected from each group (treatment and control groups) within 24 hours (day 0) post burned to determine histological changes. Generally, the tensile strength increased on day 5 and day 10 because of fibroblast activity (Kenyon and Michaels, 1983) and decreased on day 15 and day 20 due to the rearrangement of the collagen (Lee *et al.*, 1986). However, there is no significant difference ($P < 0.05$) in the tensile strengths of both the treatment and control groups on various days. The treatment group healed faster compared to the control group. The 15 UMF manuka honey treatment showed scar formation after 6 to 9 days post burned and the control showed scarring after 8-12 days. However, all the wounds didn't show any sign of infection and no pustule was observed during the experimental period. Epithelialization was observed in the 15 UMF manuka honey treatment on day 5 and almost completed by day 10, whereas the control group showed complete epithelialization only on day 15 and day 20.

Key words: 15 UMF Manuka Honey, burn-wounds, repair process

School of Pharmaceutical Sciences, Universiti Sains Malaysia, Malaysia

¹St. Matthew's University School of Medicine, Safe-Haven, Leeward Three, Post Box: 32330 SMB, Grand Cayman (BWI), U.K

²Department of Biomedical Sciences, Faculty of Medicine and Health Sciences, Universiti Putra, Malaysia

Introduction

Honey is carbohydrate-rich syrup produced by bees from floral nectar and has been used for its medicinal properties since ancient times. Recent studies indicated that honey is effective as a dressing on infected or non-infected wounds because honey is an anti-bacterial (Cooper *et al.*, 1999; Fox, 2002; Lawrence, 1999; Molan and Allen, 1997); anti-inflammatory (Molan, 1999); anti-odour (Molan, 1999 and Nychas *et al.*, 1988); granulation and epithelialization (Molan, 1999); shedding of necrotic tissue and an analgesic agent (Molan, 1999). Besides that, honey also provides a healing environment (low pH, high osmolarity) (Greenwood, 1993; Lawrence, 1999 and Molan, 1999) for the wounds to regenerate and repair.

Manuka honey contains an additional antibacterial component from *Leptospermum* or manuka trees what has been called "Unique Manuka Factor" (UMF). UMF manuka honey has been proven to contain two synergistic antibacterial components. UMF manuka honey is more stable compared to other honeys. Under certain conditions such as heat, protein digestive enzymes or on light exposure, the original honey will lose some hydrogen peroxide synthesizing enzyme, thus potency of the honey's antibacterial activity would most likely be reduced. Besides that, the UMF manuka honey's antibacterial activity is believed to diffuse deep into the skin tissues than does the hydrogen peroxide from other types of honey.

Materials and Methods

Animals

Healthy male and female SD rats weighing between 250-350 g were used in this investigation. The rats were kept according to the type of treatments, one rat in one cage and given regular standard feed and water *ad libitum*.

Burn wound model

The hairs on the back and flanks on both the left side and right side of the rats were shaved. This area was disinfected with 70% ethanol before inducing of wound. Partial thickness burn wounds were inflicted on animals by modified commercial soldering iron method (Yam Mun Fei *et al.*, 2002) under inhaled anaesthesia using diethyl ether.

Experimental protocol

Animals bearing the partial thickness burn wounds were divided into 2 groups with 15 animals each.

- 1: Control group (untreated): The wounds were covered by dressing.
- 2: 15 UMF manuka honey: The treatment was applied daily until sacrificed.

Determination of tensile strength

The tensile strength determination was done on day 5, 10, 15 and 20 post-burn. The skin was cut into dump-bell shape (wounded part lying in the center) by a special cutter. Instron

tensiometer was used to measure the tensile strength of the skin with 15 mm min^{-1} of crosshead speed (Yam Mun Fei, 2002).

Histopathology

Skin (containing both normal and healing sides) was collected on day 0, 5, 10, 15 and 20 for histological studies. Paraffin sections of $4\mu\text{m}$ thickness were stained by hematoxylin and eosin (H&E) and examined under light microscopy. The sections were scored on the fibroblast using a numerical grading system 0 to 4 (where 0 represents an undetectable infiltrate with increasing number of cells to massive infiltrate as 4).

Results

Histological studies

Control

These are typified by the illustration in Fig. 1. On day 0 post-burn, entire epidermis and upper portion of dermis were damaged. The dermal appendages were also abnormal. No sign of epithelialization was observed (Fig. 1a), very small collection of fibroblasts was found in the dermis (score 0). By day 5 post-burn, there was no sign of epidermis regeneration. Moderate numbers of polymorphonuclear leucocytes dispersed in the dermis (Fig. 1b) and few fibroblasts was observed (score 1). During day 10, debridement occurred, dermis was covered by granulated tissue and there was no evidence of epidermal regeneration. Abundant fibroblasts (score 4) were found in the dermis (Fig. 1c). Epidermis has completely regenerated on day 15 and moderate fibroblasts (score 3) accumulated in the dermis (Fig. 1d). By day 20, stratified epithelium (epidermis) has formed (Fig. 1e).

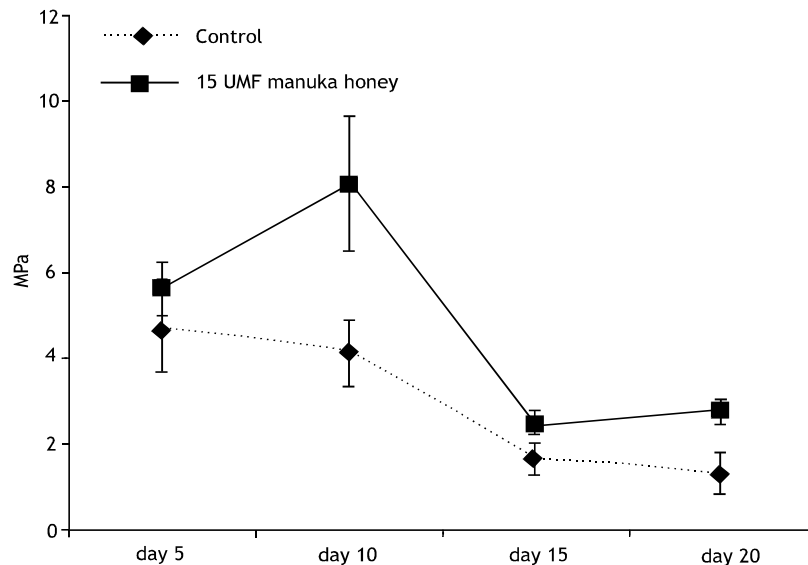


Fig. 1: Mean tensile strength \pm SEM of control and 15 UMF manuka honey treated wounds on various days

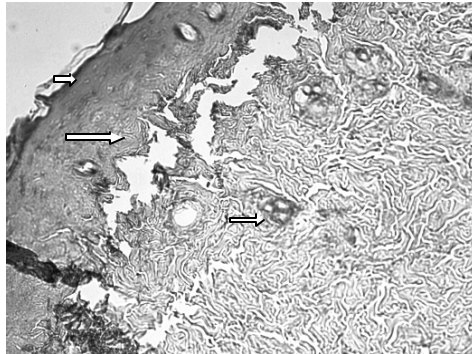


Fig. 1a: Control day 0, entire epidermis, upper region of dermis, hair follicle and sebaceous gland are damaged (arrow). There is no evidence of epidermal bridging. H&E stain $\times 200$

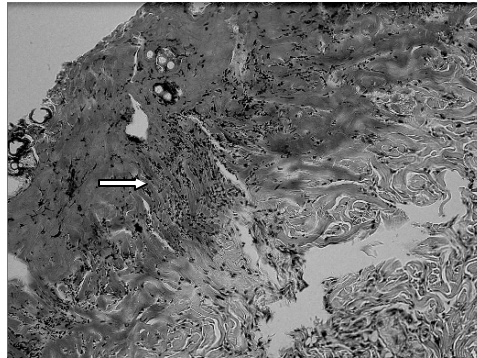


Fig. 1b: Control day 5. There is complete epidermal loss, no sign of epithelial regeneration and no dermal appendages persist. Note the polymorphonuclear leukocytes

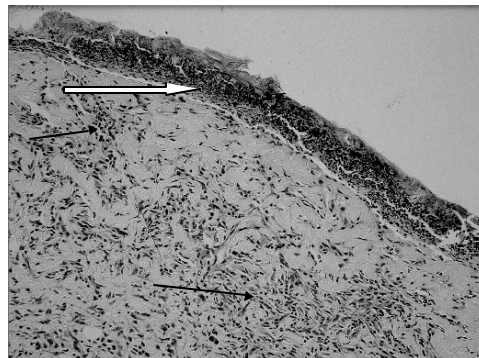


Fig. 1c: Control day 10. Debridement has occurred. The dermis is covered by granulation tissue (white arrow). There is no evidence of epidermal regeneration. Note the presence of polymorphonuclear leukocytes (black arrow) H&E stain $\times 200$

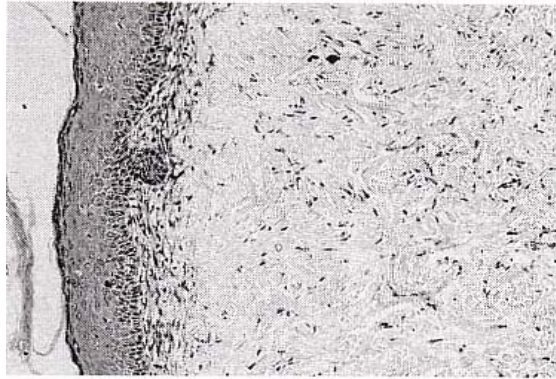


Fig. 1d: Control day 15. There is complete epithelialization and moderate number of fibroblasts dispersed in dermis. H&E stain $\times 200$

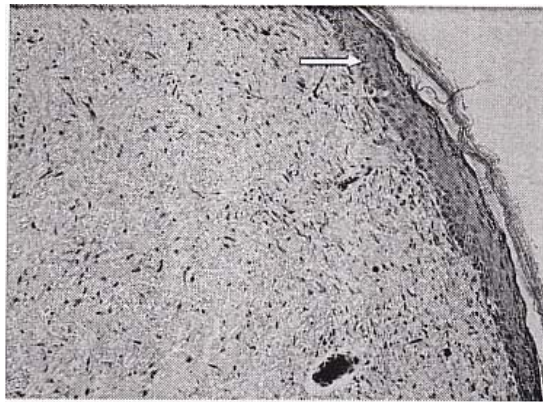


Fig. 1e: Control day 20. Shows complete regeneration of epidermis (arrow). H&E stain $\times 200$

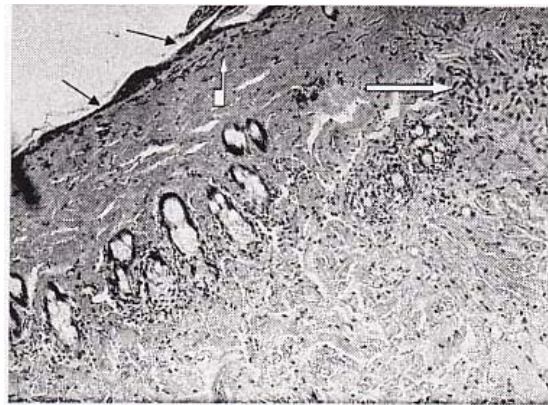


Fig. 2a: 15 UMF manuka honey treatment, day 0. Surface necrosis is found (black arrow). Moderate number of Polymorphonuclear leukocytes (white arrow) has accumulated in the upper part of the dermis (H&E stain $\times 100$)

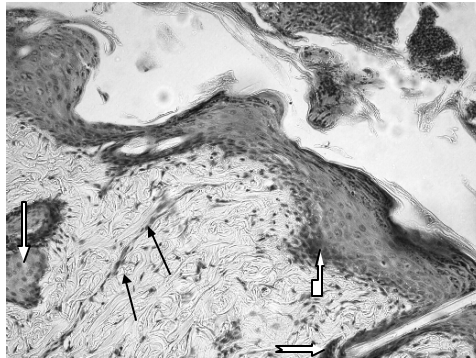


Fig. 2b: 15 UMP manuka honey treatment day 5. Epithelialization has occurred. Arrector pili muscle develops (back arrow). Note the active cells (white arrow) in basal layer of epidermis, sweat gland and hair follicle. There is no sign of inflammatory cells (H&E stain x 200)

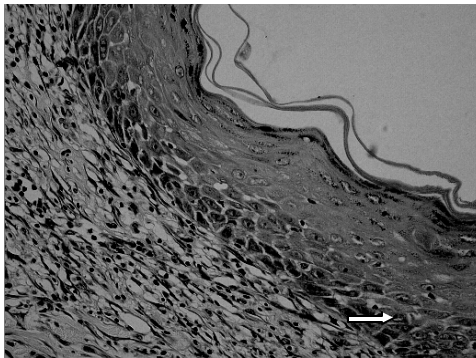


Fig. 2c: 15 UMP manuka honey treatment day 10. There is complete epithelialization and well identified epidermal strata (arrow). H&E stain x 400

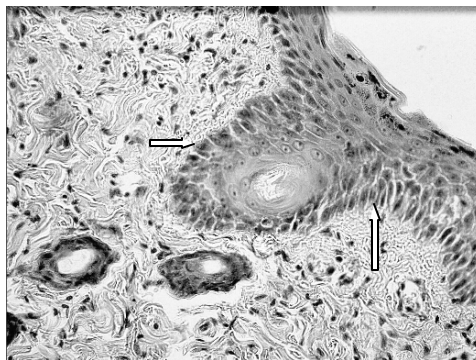


Fig. 2d: 15 UMP manuka honey treatment day 15. Note the complete regeneration and orderly stratification of the epidermis with basal layers of columnar cells (arrow) (H&E stain x 400)

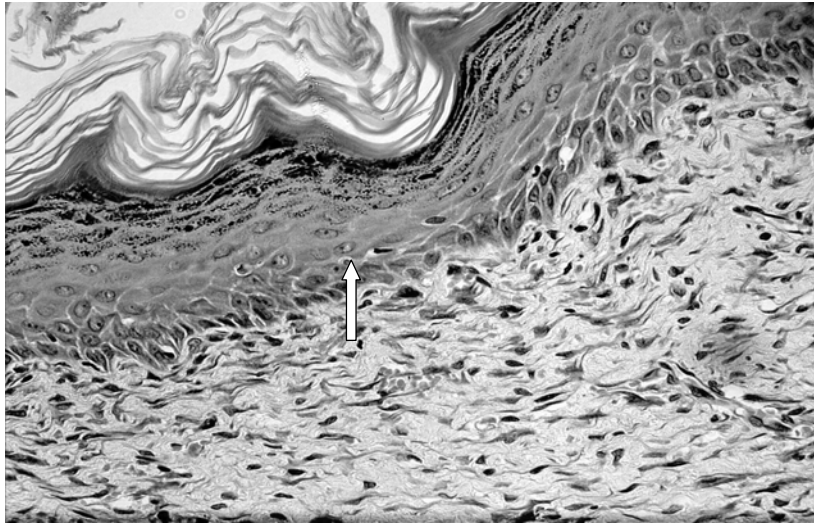


Fig. 2e: 15 UMF manuka honey treatment day 20. There is complete epithelialization and well identified epidermal strata (arrow) (H & E stain $\times 400$)

Treatment using 15 UMF manuka honey

On day 0 (Fig. 2a), moderate number of polymorphonuclear leucocytes has accumulated in the upper part of the dermis and very little fibroblasts are observed (score 0). There is no epithelialization over the injured site (Fig. 2a). On day 5, epithelialization has occurred and the injury is covered by new epidermal layers, arrector pili muscle develops (Fig. 2b). This epidermis might have been formed and migrated from the basal layers of near-by uninjured epidermis or from the undamaged hair follicle papillae, or from the sweat glands. Moderate number of fibroblasts (score 2) is observed in the dermis. On day 10 (Fig. 2c), a lot of fibroblasts (score 3) are clearly observed in the dermis and the process of epidermal regeneration is complete (Fig. 2c). On day 15 (Fig. 2d) and day 20 (Fig. 2e), epithelialization is complete having well-defined epidermal strata. Abundant fibroblasts (score 4) are also dispersed in the dermis.

Tensile strength

Treatment group always shows higher tensile strength (mean \pm SEM) compared to control during the experimental period. On day 5 post-injury, tensile strength in the treatment group is 5.668 \pm 1.139 MPa while in the control group the tensile strength is 4.746 \pm 1.893 MPa. On day 10 post-injury, tensile strength in the treatment group has increased to 8.008 \pm 2.702 MPa but in the control group this is slightly decreased having 4.170 \pm 1.332 MPa. On day 15 post-injury the tensile strength in the control and treatment groups are 1.664 \pm 0.648 and 2.511 \pm 0.485 MPa, respectively. Tensile strength of both treatment and control groups on day 20 post-injury are 1.345 \pm 0.85 and 2.799 \pm 0.5 MPa, respectively.

Discussion

The rats have been kept in good condition throughout the experimental period. There is no sign of infection and no pustule in all the wounds during experimental period. The wounds treated with 15 UMF manuka honey have healed faster compared to that in the control. Scars have formed between days 6-9 in treated group compared to the control's 8-12 days.

Tensile strength

Tensile strength of 15 UMF manuka honey treated wounds has increased between day 5 and day 10 while in the controls, the tensile strength has decreased during this period. The results in the present study is similar to that of Kenyon and Michaels (1983) and Lee *et al.* (1986) that showed that the tensile strength increased during the fibroblastic phase (day 3 to day 10 post-injuries) and decreased during the differentiation phase (day 15 to day 20 post injuries). However, there is no significant difference ($P < 0.05$) of tensile strengths in these two groups during various intervals of experimental period.

Histology

This investigation shows that wounds treated with 15 UMF manuka honey has healed faster than the controls. Epithelialization of treated wounds has occurred as from day 5 and is almost complete by day 10 compared with that in the control rats that showed epithelialization only on day 15. This clarifies that the honey (manuka honey) provides a healing environment to the wounds. Its antibacterial properties and its viscosity provide a barrier to cross-infection of wounds (Cooper *et al.*, 1999; Molan, 1999 and Fox, 2002). Therefore, during the whole period of this investigation, the wounds treated with 15 UMF manuka honey looked healthier compared to the control. Furthermore the manuka honey not only contains hydrogen peroxide (produced by a heat and light sensitive enzyme in honey), which has a mild antibacterial activity (Molan, 1999); but also has a second antibacterial agent which is stable through the entire manufacturing process.

Acidity of the honey not only assists in the antibacterial actions of the macrophages (Ryan and Manjo, 1977); but also prevents the toxic unionized form of ammonia from being released by the bacteria (Nychas *et al.*, 1988). The high concentration of glucose in the honey will be used by the infecting bacteria rather than the amino acids in dead tissue and serum (Nychas *et al.*, 1988) and this would produce lactic acid instead of ammonia, amines, or sulfur compounds which would cause odor in the wounds.

Granulation is an essential process before epithelialization in the wound healing process. Based on the results, debridement has been found earlier (in day 5) in 15 UMF manuka honey treated wound than the control (day 10). Manuka honey that has a high osmolarity (Greenwood, 1993 and Lawrence, 1999) is believed to induce outflow and the lifting of dirt and debris from the bed of wounds causing debridement (Molan, 1999) occurring earlier than those without treatment. Thus, the high osmolarity of honey will also cause an outflow of lymph that serves to provide nutrition for regenerating tissue. Usually healing of wound is delayed if the circulation of an area is poor. Some studies suggested that the application of honey might also increase oxygenation of tissues thus causing faster tissue regeneration (Efemsee, 1988).

Honey contains a wide range of nutrients including amino acids, vitamins and trace elements (White, 1975). These nutrients can be expected to have direct effects in regenerating tissue (Molan, 1999). Besides that, low levels of hydrogen peroxide can stimulate angiogenesis and fibroblasts. The present histological observation clearly showed that fibroblasts dispersed in the dermis of treatment wounds have higher scores than the controls on day 5, day 15 and day 20. This investigation clearly shows that the 15 UMF manuka honey helps to promote epithelial regeneration and increases wounds tensile strength of rats.

References

- Cooper, R.A., P.C. Molan and K.G. Harding, 1999. Antibacterial activity of honey against strains of *Staphylococcus aureus* from infected wounds. *J. R. Soc. Med.*, 92: 283-285.
- Efemsee, 1988. Clinical observations on the wound healing properties of honey. *Br. J. Surg.*, 75: 679-681.
- Fox, C., 2002. Honey as a dressing for chronic wound in adults. *B. J. Community Nursing*, 7: 530-534.
- Greenwood, D., 1993. Wound healing: Honey for superficial wounds and ulcers. *The Lancet*, 341: 90-91.
- Jeffrey, A.E. and C.M. Echazarreta, 1996. Medical uses of honey. *Rev. Biomed.*, 7: 43-49.
- Kaufman, T., E.H. Eichenlaub, M.F. Angel, M. Levin and J.W. Futrell, 1985. Topical acidification promotes healing of experimental deep partial thickness skin burns: a randomized double-blind preliminary study. *Burns*, 12: 84-90.
- Kenyon, A.J. and E.B. Michaels, 1983. Modulation of early cellular events in wound healing in mice. *Am. J. Vet. Res.*, 44: 340-343.
- Lawrence, J.C., 1999. Honey and wound bacteria. *J. Wound Care*, 8: 155.
- Lee, A.H., S.F. Swain, J.M. Pedersoli and J.A. McGuire, 1986. A newly designed tensiometer. *Am. J. Vet. Res.*, 47: 683-686.
- Leveen, H.H., G. Falk, B. Borek, 1973. Chemical acidification of wound. Adjuvant to healing and the unfavourable action of alkalinity and ammonia. *Ann. Surg.*, 178: 745-753.
- Molan, P.C., 1999. The role of honey in the management of wounds. *J. Wound Care*, 8: 415-418.
- Molan, P.C. and K.L. Allen, 1997. The sensitivity of mastitis-causing bacteria to the antibacterial activity of honey. *New Zealand Agril. Res.*, 40: 537-540.
- Nychas, G.J., V.M. Dillon and R.G. Board, 1988. Glucose, the key substrate in the microbiological changes in meat and certain meat products. *Biotechnol. Appl. Biochem.*, 10: 203.
- Ryan, G.B. and G. Majno, 1977. Inflammation. Kalamazoo, Michigan: Upjohn, pp: 80.
- White, J.W., 1975. Composition of honey. IN: Crane E, Ed. *Honey: A Comprehensive Survey*. London: Heinemann, pp: 157-206.
- Yam Mun Fei, Jamaludin Zainol, A.G. Pillay and Norimah Yusof, 2002. Experimental Evaluation of Healing Process of Burn-wound Treated by Lyophilized *Aloe vera* Dressing. *The Sciences*, 2: 1-6.