



# Journal of Medical Sciences

ISSN 1682-4474

**science**  
alert

**ANSI***net*  
an open access publisher  
<http://ansinet.com>

**JMS (ISSN 1682-4474) is an International, peer-reviewed scientific journal that publish original article in experimental & clinical medicine and related disciplines such as molecular biology, biochemistry, genetics, biophysics, bio-and medical technology. JMS is issued four times per year on paper and in electronic format.**

**For further information about this article or if you need reprints, please contact:**

Dr. M.A. Awal  
Dept. Anatom. Histol.,  
Faculty of Veterinary Science,  
Bangladesh Agricultural University,  
Mymensingh-2202, Bangladesh

Tel. +88-091-55695-7/2589  
Fax: +88-091-55810  
E-mail: awal963@yahoo.com

## **Formalin Affects the Male Reproduction of Black Bengal Goats During Prepubertal Stage Even at Low Concentration: *In vivo* Study**

<sup>1</sup>Mohammad A. Awal, Mohammad Mizanur Rahman,  
Sonkor Kumar Das, Nazmul Hassan Siddiki,

<sup>2</sup>Masamichi Kurohmaru, <sup>2</sup>Andriana B. Bibin and <sup>3</sup>Yoshihiro Hayashi

The effect of 10% commercial formalin on testicular tissues was evaluated in prepubertal male black Bengal goats. At fifteen days after a single exposure of formalin, testicular atrophy appeared for the first time. At thirty days, the mean weight, length and width of the testes were significantly decreased, compared to those of the control group (\* $p < 0.05$ ). In testes, histopathological changes were not observed uniformly. Peripheral tubules were more affected than central ones. Lesions in all affected seminiferous tubules were not similar. In severely affected areas, the seminiferous tubules collapsed or shrank. While, in some areas, focal or complete necrosis was found. The diameters of the seminiferous tubules were apparently smaller in comparison with that of the control group. Increased connective tissues together with macrophagic infiltration were observed in the interstitial region. Marked eosinophilic staining was also observed in treated testes. It is suggested here that 10% formalin is of advantage for earlier castration in black Bengal goats. Still it is not clear, how this chemical brings about testicular disfunction at prepubertal stage.

**Key words:** 10% formalin, testes, black Bengal goat, prepubertal stage

<sup>1</sup>Department of Anatomy and Histology, Faculty of Veterinary Science, Bangladesh Agricultural University, Mymensingh-2202, Bangladesh

<sup>2</sup>Department of Veterinary Anatomy, <sup>3</sup>Department of Global Animal Resource Science, Graduate School of Agricultural and Life Sciences, The University of Tokyo, Bunkyo-ku, Tokyo 113-8657, Japan

## INTRODUCTION

Black Bengal goats are known as poor man's economy in Bangladesh, because of occupying a very significant position as an animal genetic resource in the predominantly agrobased economy of the country. In recent years, goat production ranked second in term of the total number, milk, meat and skin production. In Bangladesh, the annual consumption of meat and milk percent is far below the normal requirements of the peoples compared to those in other developing countries. There is an acute shortage of animal protein in the country which becomes a great threat to the general health of the nation. The goats are known to be famous for their adaptability, fertility, delicacy of meat and superior leather quality.

Considering the various aspects of animal production such as management, nutrition, economy, genetic potential and acceptability to the rural farmers, the black Bengal goats have proved their worth to stand effectively in overall livestock production of the country.

To meet the increasing demand of animal protein, castration in goats may particularly contribute, as castration plays important role to improve the quality and quantity of meat production together with the quality of skin. In general, the open and close methods of castration have been followed in veterinary practices. In the open method of castration, it needs skill persons and remains a chance of tetanus infection having the threat on life. On the otherhand, a chemical method for castration is comparatively easier than others, less experienced persons can do it successfully, in addition to economically cheaper cost and no risk of infection.

To make the castration in goats easier, the chemical method has been trying to apply. Ijaz *et al.*<sup>[1]</sup>, applied 10% formalin solution on the testicular tissues of Awassi lambs and led them to atrophy.

In available literatures, the research regarding the use of formalin for castration has not yet been carried out<sup>[2]</sup>. Therefore, the present work was considered to evaluate the effects of 10% formalin on the testicular tissues of prepubertal male black Bengal goats and to detect the potentiality of formalin for chemical castration.

## MATERIALS AND METHODS

Six healthy prepubertal (21-day-old) male black Bengal goats were used in this experiment. The experiment was carried out in the Department of Anatomy and Histology, Bangladesh Agricultural University, during the period of June 2002-June, 2003. The animals were housed in the animal shed with concrete floor in our animal house.

The animal facilities were strictly maintained under a controlled condition. They were fed with commercially available food (Livestock<sup>(R)</sup>) along with routine grazing and filtered tap water *ad libitum*. The animals were equally divided into two groups. In the treated group, 10% formalin, approximately 1 ml in volume, were injected intratesticularly into the right and left testes alternately. The control group was treated with 0.9% physiological saline. To avoid the risk of infection, antiseptic measure was taken carefully. At one month after treatment, the testes were surgically removed. The average weight, length and width were recorded. For histological study, the testes were cut into pieces of 1 cm<sup>3</sup> and fixed in Bouin's solution. They were then dehydrated with a series of graded ethanol, cleared in xylene and embedded in paraffin. Tissues were cut at 5 µm in thickness and stained with Harris hematoxyline and eosin and/or PAS staining. The tissues were studied with a light microscope (Olympus, Japan). The data were statistically analyzed using SPSS statistical computer package programme. ANOVA was performed to compare the data among selective treatments. Photographs were made for illustrating the results.

## RESULTS

**Gross anatomy:** A marked swelling appeared in the site of injection at 12 h after treatment. The lesion persisted for about 12 to 15 h and the swelling was gradually subsided and disappeared within a few h. At two weeks, the testes fell into atrophy and continued to shrink, compared to those of the control group. At four weeks, the atrophied testes were significantly found (Fig. 1c-b). The mean weight, length and width of the testes were significantly different from those of the control (Table 1).

### Light microscopy

**Testicular morphology of 21-day-old black Bengal goats:** Like other domestic animals, tunica albuginea of the testis consisted of a thick capsule of irregular connective tissues (Fig. 2a, arrow). Connective tissue septa extended from the tunica albuginea into the testicular parenchyma and incompletely divided the testes into lobules. Within the lobule, convoluted seminiferous tubules were

Table 1: Comparison of mean, weight, length and width of testes between treated and control

Group	Ages (days)	Mean±SD weight (gm)	Mean±SD length (cm)	Mean±SD width (cm)
Control	51	6.02±0.17	2.73±0.89	1.33±0.41
Treated	51	4.50±0.75	1.90±0.18*	1.19±0.10*

The mean weight, length and width of the testes are significantly different from the control (\*p<0.05). The values are expressed as the mean ± S.E. (n=6)

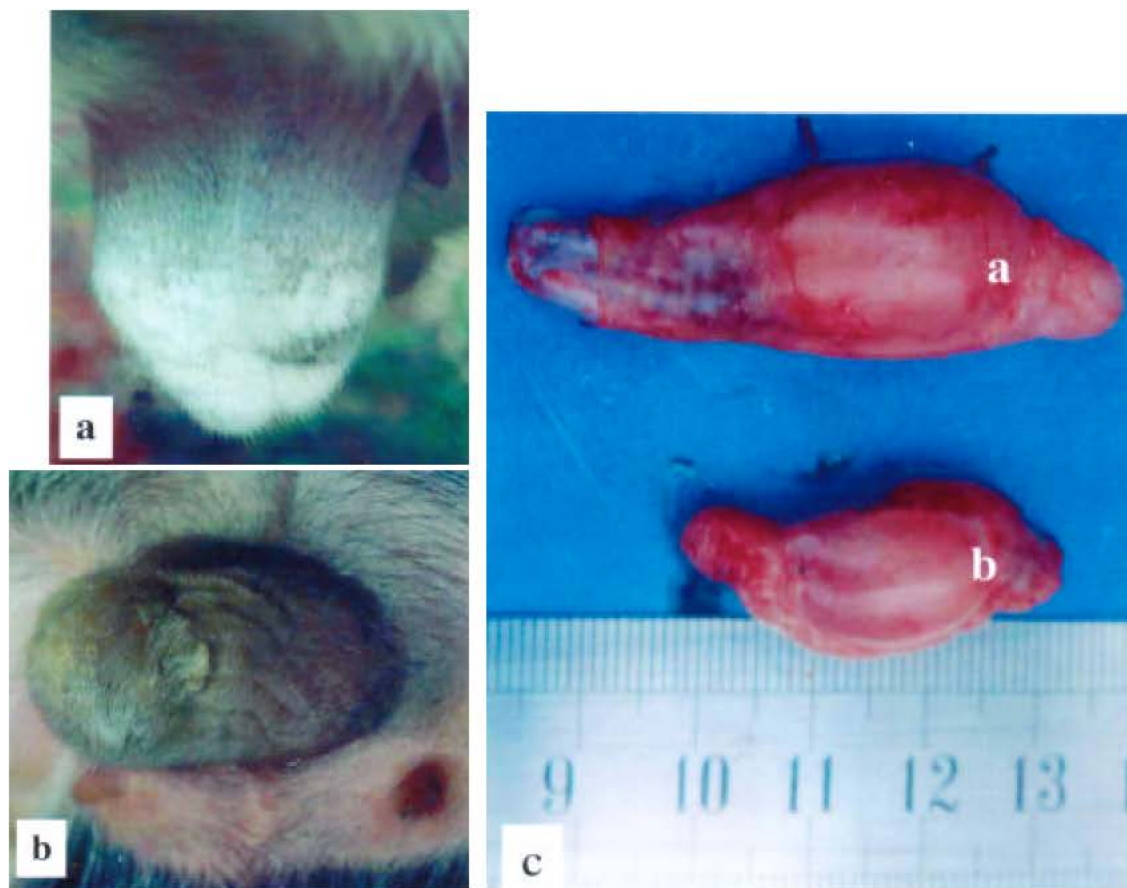


Fig. 1: Testis of black Bangal goat with scrotum and after removal of covering (Fig. 1a and 1c. A control and Fig. 1b and 1c, b treated)

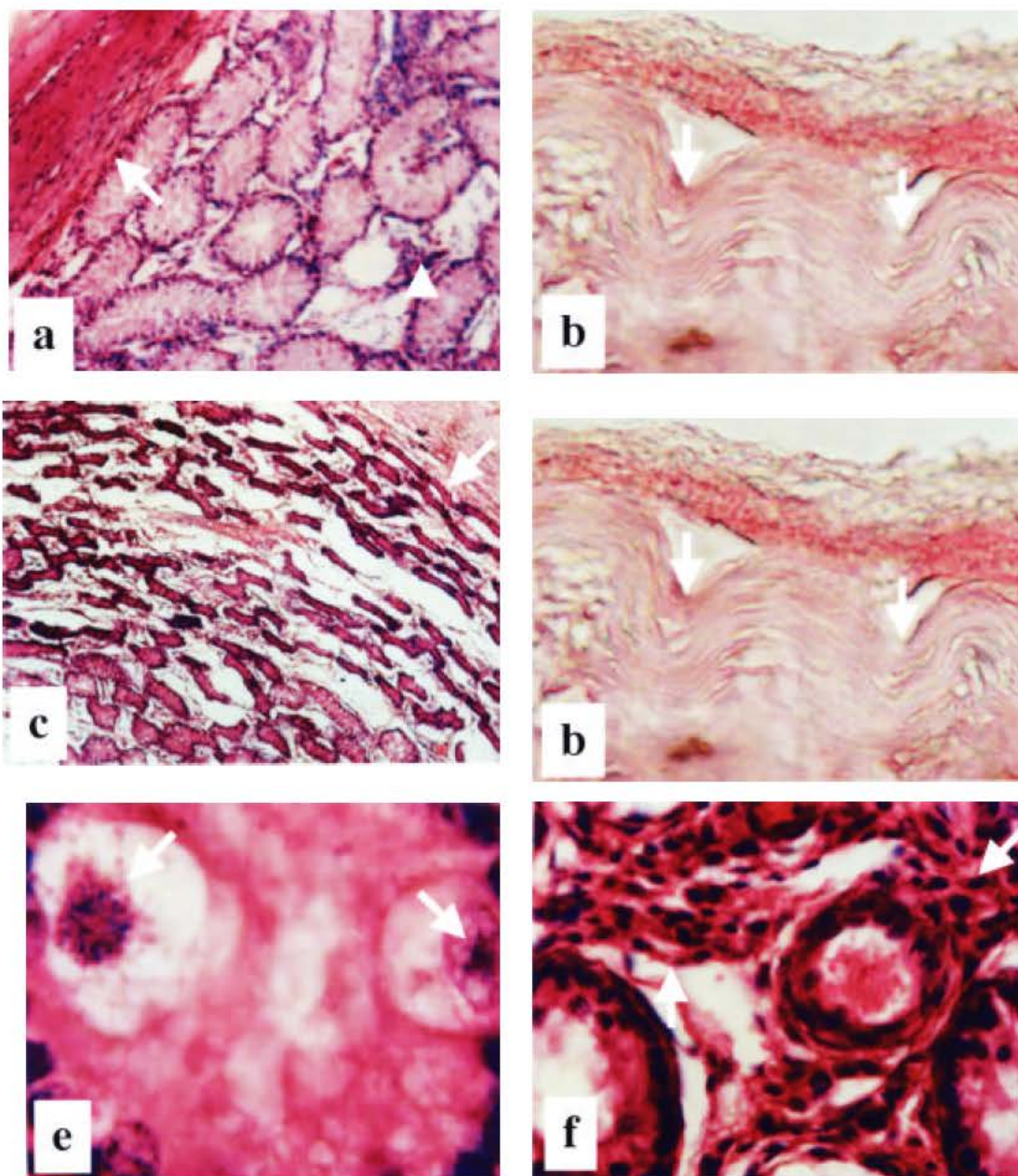
surrounded by a thin lamina propria of loose connective tissues. Only spermatogonia and Sertoli cells were found within the seminiferous tubules. No spermatids and spermatozoa were observed (Fig. 2a). Flattened contractile myoid cells along with fibroblasts were found around the basement membrane of the seminiferous tubule. The interstitial cells, showing polyhedral in outline and having rounded nuclei with foamy cytoplasm, were dispersely distributed within the intertubular connective tissues (Fig. 2a, arrowhead).

**Testicular morphology of 10% formalin injected black Bengal goats:** In treated group, the histopathological changes of the testes were not observed uniformly. A distinct wrinkling of the tunica albuginea appeared (Fig. 2b, arrow). Peripheral seminiferous tubules were more affected than central ones (Fig. 2c, arrow). Lesions in all affected tubules

were not similar. In severely affected areas, the seminiferous tubules collapsed or shrank and necrotic cells were found (Fig. 2c and d). The diameters of the seminiferous tubules were smaller (Data not shown), compared to those of the control group (Fig. 2a and c).

In less affected areas, the seminiferous tubules appeared more prominent owing to the presence of large quantity of connective tissues (Fig. 2f). Increased connective tissues with macrophagic infiltration were observed in the interstitial region (Fig. 2f, arrow). In some areas, the seminiferous tubules were densely arranged, compared to that of the control group (Fig. 2a and d). Marked eosinophilic staining was observed (Fig. 2c and d). In some areas, the seminiferous tubules disappeared. Splitted Sertoli cell nucleus was recognized alongside the basement membrane of the seminiferous tubules (Fig. 2e, arrow). Marked fibrosis in intertubular spaces, especially in severely affected areas, was observed (Fig. 2f).





**Fig. 2:** a: Tunica albuginea (arrow) with numerous seminiferous tubules. Interstitial cells are unevenly distributed within the interstitium (arrowhead, control). HE X 10.  
b: Marked wrinkling of the tunica albuginea are seen (arrow, treated). HE X 10.  
c: Seminiferous tubules are densely packed in peripheral areas (arrow, treated). HE X 10.  
d: Necrosis of seminiferous tubules is seen in a focal area. (treated). HE X 10.  
e: Splitted Sertoli cell nucleus is seen (arrows, treated). HE X 40.  
f: Marked fibrosis along with large number of macrophages and other connective tissues within the interstitium (arrow, treated). HE X 20.

## DISCUSSION

It has been suggested that human sperm counts have declined significantly throughout the world during the last five decades<sup>[2,3]</sup>. Until now, many drugs have been considered as reproductive toxicant and have revealed that those drugs cause the decrease of testicular weight and sperm production and alteration of testicular morphology<sup>[4-10]</sup>.

In the present study, the mean weight, length and width of treated testes were significantly reduced, compared to that of the control group. The similar finding was observed in Awassi lambs and pigs<sup>[1,11]</sup>. Intraperitoneal injection of formaldehyde caused the gradual diminution in body and testicular weight together with the impairment of Leydig cells functions<sup>[12]</sup>. Decreased testicular weight, vacuolation in the germinal epithelial layer of the seminiferous tubules, together with the smaller diameter of the tubules, were observed after treatment with formalin in Japanese male quails<sup>[13]</sup>. Intratesticular injection of 10% formalin in Awassi lamb caused decreased testicular size and weight<sup>[1]</sup>, which are consistent with our present finding. In our study, swelling developed at 12 h after treatment and gradually subsided within a few h. The similar finding was observed in dogs, when 70% glycerol solution was injected intratesticularly<sup>[14]</sup>.

In the treated testes, the tunica albuginea consisted of dense irregular connective tissues and was regular in form. Beneath the tunica albuginea, the seminiferous tubules were uniformly distributed, whereas the interstitial cells were sparsely present. This finding is in agreement with the observation in other domestic animals<sup>[15]</sup>. Only spermatogonia and Sertoli cells were observed, whereas no spermatids and spermatocytes were recognized. These findings are in common with the report in horses<sup>[16]</sup>. According to their report, only Sertoli cells and spermatogonia were observed along the basement membrane of seminiferous tubules, while interstitial cells were unevenly distributed<sup>[16]</sup>.

In treated group, the density of seminiferous tubules was higher compared to that of control. It was in well agreement with the finding in Awassi lambs<sup>[1]</sup>. Histopathological lesions were not observed uniformly. The peripheral tubules were more affected than the central ones. Subcutaneous administration of estradiol benzoate in birds resulted in distortion of the peripheral convoluted tubules<sup>[2]</sup>, being in well agreement with the present finding.

In the present study, clear necrotic zone beneath the tunica albuginea and focal necrosis in some areas were observed. The seminiferous tubules collapsed and

showed necrotic cells, resulting from loss of testicular blood supply due to unusual occlusion<sup>[17]</sup>. Our present study agrees well with their hypothesis.

Fibrosis and macrophage infiltration within the interstitium were observed in our present study. As described by many other authors in different literatures, fibrosis and macrophage infiltration occur in inflammation, tissue necrosis and / or degeneration<sup>[17]</sup>. A distinct wrinkling of the tunica albuginea and thickening of the basement membrane of the seminiferous tubules were observed. During testicular degeneration, a distinct wrinkling of the tunica albuginea might be present<sup>[17]</sup>. They mentioned that if the organ had a capsule and became into atrophy, the capsule of the organ might be wrinkled, reflecting the loss of volume of the underlying parenchyma. In some areas, seminiferous tubules disappeared. It is assumed that due to chemical action of formalin, the testicular cells first went into necrosis, sloughed off and finally disappeared. Still the mechanism of action of formalin on the testicular tissues is not clear. A further investigation is needed to elucidate the action of formalin on the testes of black Bengal goat at prepubertal stage.

## ACKNOWLEDGMENTS

This work was carried out in the Department of Veterinary Anatomy and Histology, Bangladesh Agricultural University with the financial assistance of Bangladesh Agricultural University Research and Education System (BAURES). Sincere thanks are extended to Mr. Liakot Hossain for taking care of the animals during the experiment. The authors are very much grateful to the laboratory of veterinary Anatomy, The University of Tokyo, Japan for some technical assistance during conducting some laboratory works and Dr. Mitsuharu Matsumoto, Kagoshima University, Japan for critical reviewing of this article.

## REFERENCES

1. Ijaz, A., A.A. Abalkhail and W.H.H. Khamas, 2000. Effect of intratesticular injection of formalin on seminiferous tubules in Awassi lambs. *Pak. Vet. J.*, 20: 129-134.
2. Akter, R., 1996. Effect of castration on birds. M.Sc. Thesis, Bangladesh Agricultural University, Mymensingh, Bangladesh.
3. Swan, S.H., E.P. Elkin and L. Fenster, 1997. Have sperm densities declined? A reanalysis of global trend data. *Environ. Health Perspect.* 105: 1228-1232.

4. Awal, M.A., M. Kurohmaru, Y. Kanai, K. Mizukami and Y. Hayashi, 2001. Biochemical effects of 2,3,7,8-Tetrachlorodibenzo-p-dioxin (TCDD) on the sertoli cell culture from prepubertal male Wistar rats. *Sciences*, 1: 311-315.
5. Awal, M.A., M. Kurohmaru, T. Mizukami, B.A. Bibin, Y. Kanai and Y. Hayashi, 2002. Effect of Bisphenol-A on the Sertoli cell culture from prepubertal male Wistar rats. *Sciences*, 2: 19-23.
6. Beard, A.P., P.M. Bartlewski, R.K. Chandolia, A. Honaramooz and N.C. Rawlings, 1999. Reproductive and endocrine function in rams exposed to the organochlorine pesticides lindane and pentachlorophenol from conception. *J. Reprod. Fertil.*, 115: 303-314.
7. Carlsen, E., A. Giwercman, N. Keiding and N.E. Skakkebaek, 1992. Evidence for decreasing sperm quality of semen during past 50 years. *Bio. Med. J.*, 305: 609-613.
8. Mojumder, P.K. and V.L. Kumar, 1995. Inhibitory effects of formaldehyde on the reproductive system of male rats. *Indian J. Physiol. Pharmacol.*, 39: 80-82.
9. Monsees, T.K., M. Franz, U. Gebhardt, W. Winterstain, B. Schill and J. Hayatpour, 2000. Sertoli cell as target for reproductive hazards. *Andrologia*, 32: 239-246.
10. Silvana, A.A., S.K. Tatjana, S.S. Stanko and K. Arizono, 2000. Inhibition of rat testicular androgenesis by a polychlorinated biphenyl mixture aroclor 1248. *Biol. Reprod.*, 62: 1882-1888.
11. Kang, Y.S., C.S. Park and H.S. Ching, 1993. Chemical castration by intratesticular injection of silver nitrate solution in pigs. *Korean J. Anim. Sci.*, 35: 463-469.
12. Chowdhury, A.R., A.K. Gautam, K.G. Patel and H.S. Trivedi, 1992. Steroidogenic inhibition in testicular tissue of formaldehyde exposed rats. *Indian J. Physiol. Pharmacol.*, 36: 162-168.
13. Anwar, M.I., M.Z. Khan, G. Muhammad, A. Bachaya and A.M. Babar, 2001. Effects of dietary formalin on the health and testicular pathology of male Japanese quails (*Coturnix coturnix japonica*). *Vet. Hum. Toxicol.*, 43: 330-333.
14. Nishimura, N., N. Kawati, T. Sawada and J. Mori, 1992. Chemical castration by a single intratesticular injection of lactic acid in rats and dogs. *J. Reprod. Dev.*, 38: 263-266.
15. Dellmann, H.D., 1971. *A Text Book of Veterinary Histology*. Lea and Febiger, Philadelphia, pp: 192-205.
16. Hondo, E., H. Murabayashi, H. Hoshiba, N. Kitamura, K. Yamanouchi, Y. Nambo, T. Kobayashi, M. Kurohmaru and J. Yamada, 1998. Morphological studies on testicular development in the horse. *J. Reprod. Dev.*, 44: 377-383.
17. Jones, T.C. and R.D. Hunt, 1983. *Veterinary Pathology*. 5th Edn. Lea and Febiger. Philadelphia, pp: 203-204 and 1149-1152.