Journal of Medical Sciences

ISSN 1682-4474

science alert

ANSInet
an open access publisher
http://ansinet.com

Research Paper

JMS (ISSN 1682-4474) is an International, peer-reviewed scientific journal that publishes original article in experimental & clinical medicine and related disciplines such as molecular biology, biochemistry, genetics, biophysics, bio-and medical technology. JMS is issued four times per year on paper and in electronic format.

For further information about this article or if you need reprints, please contact:

Dr. Al-Said Haffor
Department of Zoology,
College of Science,
King Saud University,
P.O. Box 2455,
Riyadh 11451, Saudi Arabia

J. Med. Sci., 5 (4): 253-259
October-December, 2005

Effects of *Cerastes cerastes gasperettii* Venom on Hepatocyte Mitochondria Ultrastructure and Blood Cells Count

M.K. Al-Sadoon and A.S.A. Haffor

The purpose of this study was to examine the effects of *Cerastes cerastes* Venom (CCV) on hepatocyte mitochondria pathological changes and blood cell counts. Thirty three rats were divided randomly into three groups Negative Control (NC), Positive Control (PC) and treatment. The positive control group was injected intraperitoneally saline for 8 days whereas the experimental group was injected intraperitoneally crude CCV, at a dose of ¼ LD_{50}, for the same period. All animals of the three groups were kept under normal laboratory and dietary conditions. The hepatocyte ultrastructure examination showed mitochondria swelling associated with a reduction in the cristae and dilution of the inner and outer membranes. Frequent mitochondria rapid division was noted that led to hyperplasia. Dilatation of smooth endoplasmic reticulum, hypertrophied kuffer cell associated with eosinophil infiltration and lipid accumulation were also observed. In comparison with the NC group there was a significant ($p<0.05$) increase in WBC and PLT whereas RBC, Hb and HCT decreased significantly ($p<0.05$) in the experimental group. As compared to the PC group all these measures were increased in the experimental group. The overall regression of Hb on RBC was significant ($R^2=0.85$). These results suggest that CCV contains biochemical factors that activated WBC proliferation and inhibit platelet aggregation. Long term exposure to CCV is related to hepatocyte mitochondria membrane and cristae dilutions and their subsequent deactivation of respiratory chain enzymes.

Key words: Snake venom, red blood cells, white blood cells, hepatocyte, ultrastructure

ANSInet
Asian Network for Scientific Information

Department of Zoology, College of Science, King Saud University, Riyadh 11451, Saudi Arabia

INTRODUCTION

Cerastes cerastes gasperettii bite is the most common threat of snakebite in Saudi Arabia[1]. Snakebite is associated with varieties of medical complications such as hemorrahage, necrosis and edema which induct physiological responses. The literature contains a number of studies regarding measurements of toxic effects of sand viper, *Cerastes cerastes*, crude venom (CCV) on blood cells counts. Some studies reported reduction in red blood cells (RBC), hemoglobin (Hb) and hematocrit[2-5]. On the contrary reported an increase in RBC and Hb. Other studies[6] it was reported no changes in RBC and Hb. Besides these conflicting results, the effect of envenomation varies among venom family, time of exposure, temperature and dose.

From physiological chemistry standpoint, the inhibition of liver function in terms of heam production is obviously known to cause decreased levels of circulating hemoglobin and the associated reduction in RBC. Hepatocyte is the site of several heam biosynthetic enzymes such as δ-Aminolevulinic Acid (ALA) synthase[7]. There are no previous studies that evaluated the effect of CCV on hepatocyte ultrastructure, the site of haem biosynthetic enzymes.

Previous research[8,9] showed that *Echis coloratus* venom caused reduction in the activities of Aspartate Aminotransferase (AST), Alanine Aminotransferase (ALT) and liver protein contents as well as increased activities of Lactate Dehydrogenase (LDH). The reduction in transaminases, AST and ALT, activities are noncellular but not reliable measures that ruled out hepatocytes damages. The reported reduction in protein contents indicated that hepatocyte physiological abilities to synthesize and secrete proteins were impaired. Protein synthesis is important to manufacture enzymes of the Smooth Endoplasmic Reticulum (SER) for detoxification functions. Therefore, the induced-venom impaired-protein expression and detoxification was ruled in. On the other hand, the reported increased activities of LDH relate to failure of the reducing equivalents (NAD^+) to accelerate, in attempt to maintain oxidative balance. This was confirmed by research from which *Cerastes cerastes gasperetti* venom caused a substantial reduction in glucose-6-phosphatase and phosphofructokinase, implying slow down in glycolysis and glycogenolysis[10].

The aim of this study was to examine the ultrastructure of mitochondrial pathological changes, the site of reducing equivalents and the proliferation of smooth endoplasmic reticulum, the site of detoxification enzymes. In addition, it was also necessary to design a controlled experiment in which the effects of desert viper, *Cerastes cerstes gaperettii*, venom was controlled for by needle stick in order to revaluate the conflicting changes in blood cells counts.

MATERIALS AND METHODS

Experimental design and venom injection: Thirty three male rats, *Ratus rattus*, matched with age and body size were randomly assigned into three groups; Negative Control (NC), Positive Control (PC) and treatment groups. Animals in the PC group were injected intraperitoneally with saline solution only. Animals of the treatment group were injected intraperitoneally with ¼ of the LD_{50} of diluted crude CCV as described previously[10].

Venom dose calculations: Venom was collected from *Cerastes cerastes gasperttii* snakes in the venom factors research laboratory, Department of Zoology, College of Science, King Saud University, Riyadh, Saudi Arabia. A series of repeated injection studies were conducted using ¼ of LD_{50} on two animals. The first animal was injected two times a day for 4 consequent days. The second animal was injected once a day for 8 days. Results of these pilot studies indicated there was no mortality for 8 days with minimum observed illness.

Blood sample collection: Three to five milliliter of blood samples were collected into EDTA syringe by heart puncture technique. Blood samples were used for WBC, RBC, Hb, Hct and PLT, using hematology system (ADVIA, Bayer Corp., NY., USA).

Ultrastructure procedure: Tissue samples from liver were immediately fixed in 3% buffered glutaraldehyde (0.1 M cacodylate buffer at pH 7.4 for 4 h at 2 to 4°C. The tissue samples were washed then were post fixed in 1% osmium peroxide in the buffer for 2 h at 2-4°C, then washed and kept overnight. Fixed tissue samples were dehydrated in graded concentrations of ethyl alcohol, (30, 50, 70 and 90%) for 30 min each and finally in absolute ethanol (100%) for 40 min. Tissues were infiltrated gradually in resin and embedded in plastic capsules in fresh full strength agar 100 epoxy resins before being cured at 60-70°C for 2 days. Dehydrated tissue samples were embedded in epon and araldite mixture. Polymerized resin blocks containing tissue samples were prepared for sectioning, first semi-thin sections which were stained with toluidine blue for purpose of orientation. Accordingly ultra sections (70 nm) were made and double stained with uranyl acetate and lead citrate. Ultra sections were mounted on carbon-coated grids, then examined and photographed by Transmission Electron microscope (JEOL-100 CX) at 80 KV[11].

Statistical analysis: Mean group differences for the dependent variables; WBC, RBC, Hb, Hct were evaluated using independent t-test. Multivariate Analysis of Variance (MANOVA) was used to evaluate the main effect of each group on the dependent variables. A multiple regression model for RBC versus Hb relationship was generated using least square linear regression model. Residual sum of squares criterion was used to evaluate the validity of the regression model.

RESULTS

Hematology changes: The results showed that there was significant ($p<0.01$) decrease in hemoglobin (Hb), hematocrit (Hct) and platelet (PLT) when negative-control and venom-treated groups were compared (Table 1). Similar changes were obtained when compared the difference between the negative control and positive-control groups (Table 1). Thus needle injection related injury had contributed significantly to these changes. Furthermore, the effects of venom alone caused a significant ($p<0.05$) increase in WBC, RBC, Hb and Hct (Table 1). In order to partition the net effects of each treatment condition, the analysis was replicated using Multivariance Analysis of Variance (MANOVA). The main effect of group membership on RBC, Hb and PLT was significant ($p<0.05$) which means that the difference between the overall mean and the means of all potential group means is different (Table 2). Thus needle injection related injury affected RBC, Hb and PLT effectively as effective as venom alone. On the contrary the main group effect of group membership on WBC was not significant implying the validity of the enhanced rise in WBC induced by venom (Table 1).

Table 1: Independent t-test that clear the independent effects of experimental conditions, venom and needle stick due to intraperitoneal (IP)

Variable	Negative control (Average)	Treated (Average)	Difference	p-value
Effects of Venom and IP				
WBC enumeration (10^3/mm)	12.49	15.61	+3.12	0.0540*
RBC enumeration (10^6/mm)	7.33	7.03	-0.30	0.0700
Hb concentration (gm/dL)	14.41	13.30	-1.21	0.0009**
HCT concentration (%)	43.85	41.19	-2.66	0.0130**
PLT enumeration (10^3/mm)	890.07	1245.00	+354.93	0.0006**
Effect of IP alone	**Negative control**	**Positive control**	**Difference**	**p-value**
WBC enumeration(10^3/mm)	12.49	13.57	+1.07	0.2900
RBC enumeration(10^6/mm)	7.33	6.29	-1.04	0.0030**
Hb concentration(gm/dL)	14.41	12.30	-2.11	0.0009**
HCT concentration(%)	43.85	37.58	-6.27	0.0020**
PLT enumeration(10^3/mm)	890.07	1019.56	+129.48	0.15NS
Effect of venom alone	**Positive control**	**Treated**	**Difference**	**p-value**
WBC enumeration(10^3/mm)	13.57	15.61	+2.04	0.04*
RBC enumeration(10^6/mm)	6.29	7.03	+0.74	0.05*
Hb concentration(gm/dL)	12.30	13.30	+0.90	0.15
HCT concentration (%)	37.58	41.19	+3.16	0.05*
PLT enumeration (10^3/mm)	1019.56	1245.00	+2.25	0.059

*-$p<0.05$, **-$p<0.01$

Table 2: Multi factor Analysis of Variance (MANOVA), using type-III sum of squares, that clear the main effects of venom and intraperitoneal

Source	Dependent variable	Type III Sum of Squares	df	Mean Square	F-value	Sig.
Group	WBC	51.989	2	25.994	1.724	0.197
	RBC	5.923	2	2.962	5.585	0.009
	Hb	24.388	2	12.194	8.139	0.002
	PLT	671511.242	2	335755.621	4.813	0.016
Error	WBC	422.138	28	15.076		
	RBC	14.848	28	.530		
	Hb	41.949	28	1.498		
	PLT	1953203.145	28	69757.255		
Total	WBC	6300.740	31			
	RBC	1513.704	31			
	Hb	5670.280	31			
	PLT	35557950.000	31			

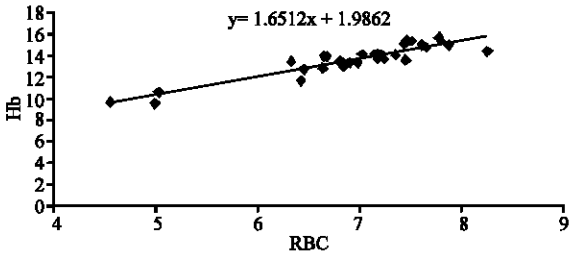

Fig. 1: The regression of hemoglobin (Hb) on red blood cell (RBC)

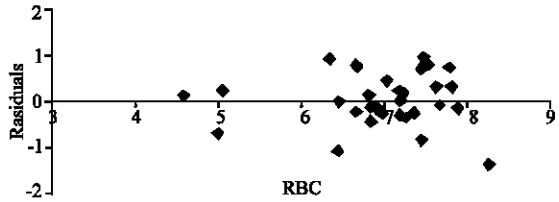

Fig. 2: Residual sum of squares plot showing that the unexplained variance departed symmetrically from zero

The relationship ($r=0.93$) between Hb and erythrocytes (RBC) was significant ($p<0.01$), with regression coefficient, $R^2=0.85$ (Fig. 1), implying the validity of automated blood cell count procedures. This regression model was evaluated using residual sum of squares which departed symmetrically from zero at all levels of RBC (Fig. 2).

Hepatocyte ultrastructure pathological changes: Figure 3 showed liver cell from the venom treated group in which cloudy swollen mitochondria associated with the damaged mitochondria membrane and cristae. The cloudy appearance relates to H_2O accumulation in the matrix that was secondary to H_2O_2 accumulation. Clearly this is an indication of mitochondria membrane failure in regulating

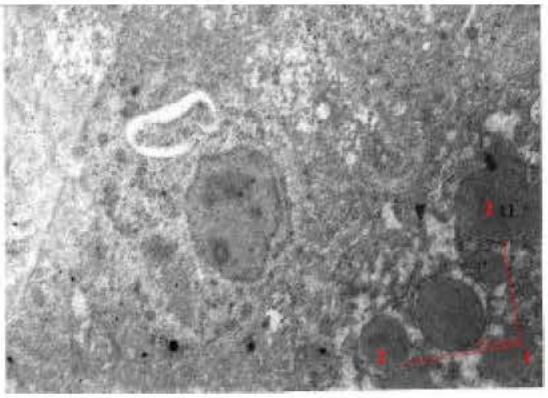

Fig. 3: Swollen mitochondrion; 1) hyperplasia , 2) cristae damage and irregular shaped densities x= 14,000

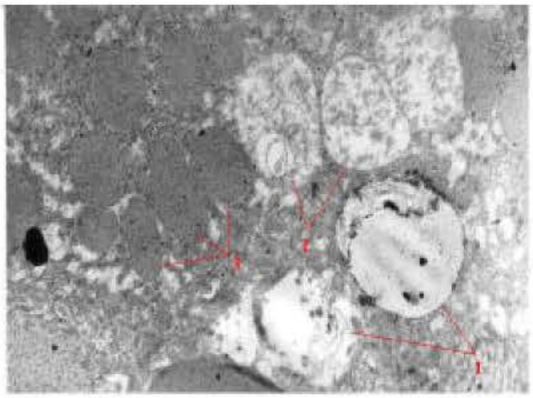

Fig. 4: Advanced mitochondria swelling associated with lamina formation; 1) large lipid droplet, 2) mitochondria swelling, 3) mitochondria hyperplasia x = 10,000

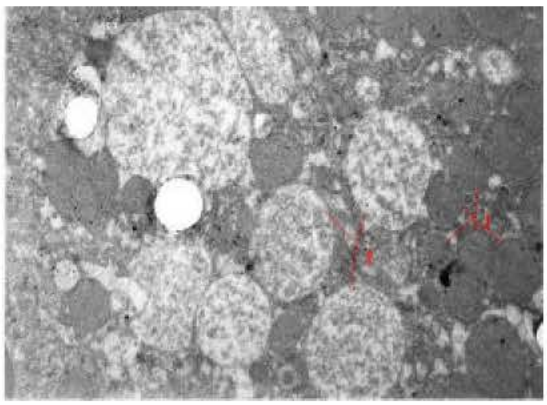

Fig. 5: Severe swelling o mitochondrion; 1) hyperplasia, 2) cystic structure x = 10,000

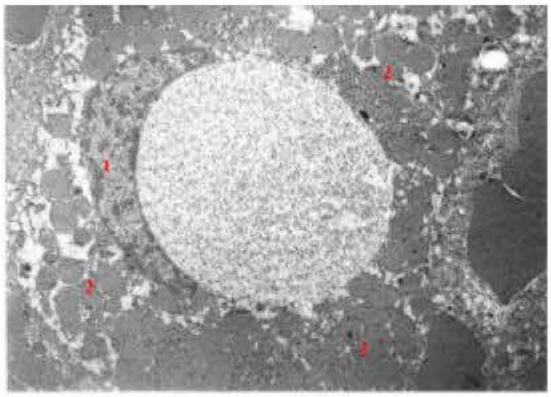

Fig. 6: Marked dilatation of SER causing compression of the nucleus attained a crescent shape x = 5,000

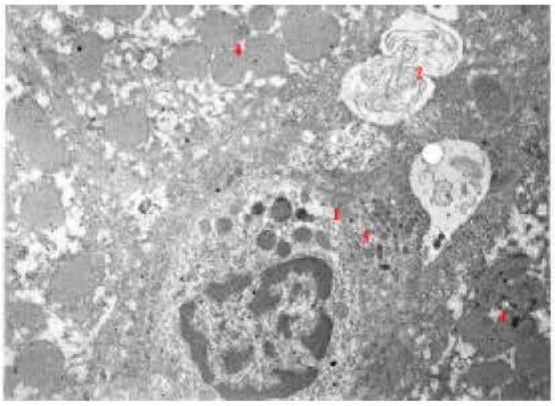

Fig. 7: Hypertrophied Kuffer cell containing lysosomal structures (hetrophagsomes); 1) ability of Kuffer cell to take up lamellar structures auto vacules x= 7,000

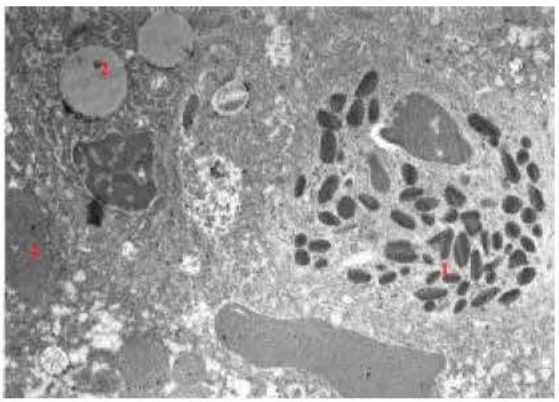

Fig. 8: Small size nucleus with dense chromatin; 1) esinophil cell infiltration; 2) lipid droplets within Kuffer cell x = 8,000

osmotic balance. It also indicates failure of various hydro and lipid peroxidase movement across the inner mitochondrial membrane leading to flooding of the inner and outer membrane.

Although the inner and outer mitochondria membrane maintained their normal structure in some, mitochondrial swelling with round shape was severe in some other wherein large lipid droplets were also observed (Fig. 4), which was due to destruction of respiratory chain enzymes and subsequently failure of oxidative phosphorylation. This was evident because severe swelling was accompanied by an increase in mitochondria mass and increased in the concentration, cristae dislocation, cristae fragmentation and cristae disappearance. In addition an advanced swelling, hyperplasia and lamina formation were also observed (Fig. 5). All together, these pathological changes were subsequent to impaired membrane permeability and membrane lipids overload and dissociation.

Furthermore a variety of pathological changes induced marked dilation of Smooth Endoplasmic Reticulum (SER), with elongated and crescent shape, in that resulted in compression of the nucleus (Fig. 6). Both nuclear and SER pathological changes are consistent with a decreased protein synthesis and corruption of amino acid residues transport. Moreover, the activity of Kuffer cell was increased as evident by the appearance of hetrophagosomes (Fig. 7) associated with small nucleus and eosinophil infiltration (Fig. 8).

DISCUSSION

The results of the present study showed that the combined effects of needle injection-related injury and *Cerastes cerastes* venom was associated with a decrease in RBC, Hb, HCT and PLT which was consistent with the findings of other studies[4,12]. However when needle injection effects is removed all the changes were reversed. The reversed change in RBC suggests that *Cerstaes cerastes* venom activate heam and globulin synthetic enzymes.

It has been shown that snake venom causes hemolysis and splitting of erythrocyte and that represent a potential source for error magnification in RBC count. The regression of Hb on RBC in the present study was significant, justifying minimum measurements error in RBC count. In fact the hemolytic activity was attributed to the presence of several factors found in snake venom such as phospholipase-A_2 and phospholipase-C[13-15]. These investigators were able to extracted phospholipase-A_2 (PL-A_2) from Cobra, *Vipra palestinae* and *Vipra russelli* but they all emphasized that PL-A_2 lytic capacity was not substantial in hydrolyzing RBC. This was consistent with Jiang *et al.*[16] who showed hemolysis by snake venom was dependent on RBC age, aged is more susceptible than fresh or viscosity. Moreover Other investigators had related RBC changes to availability of Ca^{++} concentration and to the level of pH as the increase in pH from 7.5 to 8.5 greatly increased the levels of hemolysis[17,18]. In support of this view Bultron *et al.*[19] reported that phopholipase-A2 is not directly hemolytic as evident by the inability of toxin venom *Brthros asper* to associate with the membrane of human or mouse erythrocytes *in vitro*.

Furthermore, it has been shown that venom constitutes a family of calcium-dependent enzymes which are important in regulating many physiological functions. Some investigators[20-22] have extracted Angiotensin Converting Enzyme (ACE) inhibitor like enzyme from venom. Thus the potential of extracting blood pressure lowering medication from venom is promising. As the present study examined hepatocyte mitochondrial ultrastructure, it is remarkable to mention here that liver cell also is the site of production of angiotensinogen, the inactive form of angiotensin-I which its conversion into angiotensin-II is mediated by ACE (angiotensin converting enzyme) to regulate blood pressure. Moreover toxicity of endothelial of blood vessels was damaged by cadmium toxicity[11] which interferes with ACE secretion.

The venom induced-platelet changes reported in the present study was consistent with previous studies[23-25] who purified cystein-rich peptide and halysin from venom. Clearly cystein and halysin are potent platelet aggregation inhibitors that slow down platelet aggregation stimulated via adenosine diphosphate mechanism.

The increase in WBC in the present study was further enhanced by CCV. When needle injection effect was removed by comparing results of positive control and treated group. These changes justify that *Cerastes cerastes* venom contains growth factor which stimulated WBC proliferation. This proposed molecular mechanism is consistent with the work of Navab *et al.*[26].

The present study is first to report the *Cerastes cerastes* - induced ultra mitochondria changes of hepatocyte which showed variety of mitochondrial pathological changes that were mainly manifested by dilution of the inner mitochondria membrane. The presence of phospholipase-A2 or phospholipase-C in venom can be a potential explanatory mechanism for the destruction of the mitochondria membrane. In addition it can be speculated that damaged mitochondria is

associated with metabolic defect which can cause excess blood clotting that is involved in PLT changes in the plasma. Moreover, from metabolic stand point it can be said that venom had caused mitochondria damage and delay in the reducing equivalent (NAD) turnover and hence an accumulation of oxidative modified- proteins and lipids in the cytoplasm awaiting degradation which aggravates cytosolic lipid peroxidation. It has been shown that induction of mitochondria oxidative stress elevates the progression of mitochondria swelling in myocytes[27-33]. Thus the combined effects of venom and snakebite mediate mitochondria oxidative stress observed in the present study is consistent with destruction of the inner and outer mitochondrial membrane.

CONCLUSIONS

Cerastes c. gasperettii venom causes destruction of the inner and outer mitochondria membranes destruction.

ACKNOWLEDGMENTS

This project was supported by College of Science, Research Center, Grant No. ZOO/2005/03. The authors thank Mr. Hassan Redaini for his assistant during data collection and Dr. M. Mubarak for ultrastructure production. Special appreciation is extended to the Director of the office of research and to the Dean of the College of Science, KSU, for their continuing support research funds.

REFERENCES

1. Al-Sadoon, M. and B.M. Jarrar, 1994. A study of the frequency and incidence of scorpion stings and snakebites in Riyadh city. J. King Saud Univ., 6: 217-266.
2. Chen, Y.H., R.F. Liou, C.T. Juan and J.T. Yang, Interaction of snake venom cardiotoxin with human erythrocyte. Mol. Cell Biochem., 37: 69-76.
3. Mebs, D. and F. Panholzer, Isolation of haemorragic principle from *Bitis arietans* snake venom. Toxicon, 20: 509-512.
4. Alhazza, I.M. and S.A. Bashandy, 2001. Effects *Walterinnesia aegyptia, Cerastes cerastes* and *Bitis arietans* venoms on Haemogram of male rats. J. King Saud Univ., 14: 45-57.
5. Mohamed, A.H., A.M. Saleh, S. Ahmed and M. El-Maghraby, 1977. Effect of *Cerastes vipra* snake venom on blood and bone marrow cells. Toxicon, 15: 35-40.
6. Abdulla, S., Y. Bilto and A. Disi, 1992. Effects of sand viper *Cerastes cerastes* venom isolated smooth muscle and heart and on haematological and cardiovascular parameters in guinea-pig. Toxicon, 30: 1247-1255.
7. Haffor, A.S.A. and M.I. Al-Ayed, 2003. The effect of lead bioaccumulation on haem biosynthetic enzymes in fish. J. Environ. Biol., 24: 271-280.
8. Al-Jammaz, I., M.K. Al-Sadoon and A.Fahim, 1998. Effects of LD50 Dose of *Echis coloratus* venom on serum and tissue metabolites and some enzymes of male albino rats. J. King Saud Univ., 11: 61-68.
9. Al-Jammaz, I., M.K. Al-Sadoon, A.Fahim and M.A. Attia, 1994. The effects of *Walterinnesia aegyptia* venom on the serum and tissue metabolites and on some enzyme activities in Albino rats. III-Effects on lipid metabolism and two dehydrogenases. J. King Saud Univ., 6: 207-215.
10. Al-Shammary, F.J., H.K. Ghnim, M.K. Al-Sadoon and A.M. Naseh, 1992. The effect of crude *cerastes cerastes gasprattii* venom on the activity of key metabolic enzymes in cultured human fibroblasts. Ann. Saudi Med., 12: 201-205.
11. Haffor, A.S.A. and O. Al-Dokhi, 2004. Endothelial cell toxicity of cadmium: Transmission electron microscopy examination. Pak. J. Biol. Sci., 7: 782-788.
12. Ali, S.A., F. Hamid, A. Abbasi, Z.H. Zaidi, D. Shehnaz, 1998. Pharmacological effects of the leaf-nosed viper snake (*Eristocophis macmahoni*) venom and its HPLC fractions. Toxicon, 37: 1095-1107.
13. Condrea, E. and A.D. Vries, 1963. Hemolysis and splitting of human erythrocyte phospholipids by snake venoms. Biochimica et Biophysica Acta (BBA), 84: 60-73.
14. Flachsenberger, W., C.M. Leigh and P.J. Mirtschin, 1994. Sphero-echinocytosis of human red blood cells caused by snake, red-back spider, bee and blue-ringed octopus venoms and its inhibition by snake sera. Toxicon, 33: 791-797.
15. Fletcher, J.E., M.S. Jiang, Q.H. Gong, M.L. Yudkowsky and S.J. Wieland, 1991. Effects of a cardiotoxin from *Naja kaouthia* venom on skeletal muscle: Involvement of calcium ion currents and phspholipases A2 and C. Toxicon, 29: 1489-1500.
16. Jiang, M.S., J.E. Fletcher and L.A. Smith, 1988. Factors influencing the hemolysis of human erythrocytes by cardiotoxins from *Naja kouthia* and *naja naja* atra venoms and a phospholipase A2 with cardiotoxin-like activities from *Bungarus fasciatus* venom. Toxicon, 27: 247-257.

17. Arthur, C.K., D. McCallum, D.J. Loveday, A. Collins, J.P. Isbister and M.M. Fisher, 1990. Effects of taipan (*Oxyuranus scutellatus*) venom on erythrocyte morphology and blood viscosity in a human victim *in vivo* and *in vitro*. Trans. Royal Soc. Trop. Med. Hyg., 28: 401-403.
18. Fletcher, J.E., M.S. Jiang, L. Trippolitis, L.A. Smith and J. Beech, 1990. Interactions in red blood cells between fatty acids and either snake venom cardiotoxin or halothane. Toxicon, 28: 657-667.
19. Bultron, E., M. Thelestam and J.M. Gutierrez, 1993. Effects on cultured mammalian cells of myotoxin III, a phospholipase A2 isolated from *Bothrops asper* (teriopelo) venom. Biochimica et Biophysica Acta (BBA) - Mol. Cell Res., 1179-253-259.
20. Beyer, K.H., 1977. Discovery of the Thiazides: Where biology and chemistry meet. Prespective in Biology and Medicine, 20: 410-420.
21. Dustan, H.P., E.J. Roccella and H.H. Garrison, 1996. Controlling hypertension: A research success story. Archives of Internal Medicine, 156: 1926-1935.
22. Vane, J.R., 1999. The history of inhibitors of Angiotensin-converting enzyme, J. Physiol. Pharmacol., 50: 489-498.
23. Muszbek, L. and M. Hauck, 1978. Fragmentation of actin by thrombin-like snake venom proteases. Biochemica et Biophysica Acta (BBA), 577: 34-43.
24. Navab, M., S.S. Imes, S.Y. Hama, G.P. Hough, L.A. Ross, R.A. Bork, A.J. Valente, J.A. Berliner, D.C. Drinkwater and H. Laks, 1991. Monocyte transmigration induced by modification of low density lipoproteins in co-cultures of human aortic wall cells is due to induction of monocyte chemotactic protein 1 synthesis and is abolished by high density lipoprotein. J. Clin. Invest., 88: 2039-2046.
25. Huang, T.F., C.Z. Liu, C. Quyang and C.M. Teng, 1991. Halysin, an antiplatlet arg-gly-asp-containing snake venom peptide, as fibrinogen receptor antagonist. Biochem. Pharmacol., 42: 1209-1219.
26. Petranka, J., J. Zhao, J. Norris, N.B. Tweedy, R.E. Ware, P.J. Sims and W.F. Rosse, 1996. Structure-Function relkatioships of the complement regulatory protein, CD59. Blood Cell, Mol. Dis., 22: 281-296
27. Hazell, L.J., L. Arnold, D. Flowers, G. Waeg, E. Malle and R. Stocker, 1996. Presence of hypochlorite-modified proteins in human atherosclerotic lesions. J. Clin. Invest., 97: 1535-1544.
28. Heinecke, J.W., 1997. Mechanisms of oxidative damage of low density lipoprotein in human atherosclerosis. Curr. Opin. Lipidol., 8: 268-274.
29. Nishio, E., S. Arimura and Y. Watanabe, 1996. Oxidized LDL induces apoptosis in cultured smooth muscle cells: A possible role for 7-ketocholesterol. Biochem Biophys. Res. Commun., 223: 413-418.
30. Steinberg, D., 1997. Oxidative modification of LDL and parthenogenesis. Circulation, pp: 1062-1071.
31. Kinscherf, R., R. Claus, M. Wagner, C. Gehrke, H. Kamencic, D. Hou, O. Nauen, W. Schmidt, G. Kovacs and J. Pill, 1998. Apoptosis caused by oidized LDL is manganese superoxide dismutase and p53 dependent. FASEB J., 12: 461-467.
32. Haffor, A.S.A., 2004. Effects of O2 breathing on cardiac mitochondrial, GOT and free radical production. J. Med. Sci., 4: 164-169.
33. Komori, Y., T. Nikai, C. Sekido, M. Fuwa and H. Sugihara, 1994. Biochemical characterization of hemorrhageic toxin from *Crotalus viridis viridis* venom. Intl. J. Biochem., 26: 1411-1418.