



# Journal of Medical Sciences

ISSN 1682-4474

**science**  
alert

**ANSI***net*  
an open access publisher  
<http://ansinet.com>

**JMS (ISSN 1682-4474) is an International, peer-reviewed scientific journal that publishes original article in experimental & clinical medicine and related disciplines such as molecular biology, biochemistry, genetics, biophysics, bio-and medical technology. JMS is issued four times per year on paper and in electronic format.**

**For further information about this article or if you need reprints, please contact:**

Gholam Reza Jahed Khaniki  
Department of Environmental  
Health Engineering,  
School of Public Health,  
Tehran University of Medical  
Sciences,  
Tehran, Iran

J. Med. Sci., 6 (1): 18-21  
January-March, 2006

## **Detection of *Sarcocystis* Cysts from Meat Supplied for Hamburger in Iran by Histological Method**

<sup>1</sup>Gholam Reza Jahed Khaniki and <sup>2</sup>Eshrat Beigom Kia

The skeletal muscle or meat is the most often eaten part of beef and may have some *Sarcocystis* cysts. Most portion of raw hamburger (about 70%) is made of meat. A study was made on 80 raw hamburger samples collected from retail food stores in Garmsar; Iran, for detection of *Sarcocystis* cysts by histological method. A total of 400 haematoxylin and eosin-stained tissue samples prepared from these 80 hamburgers were examined for the presence of *Sarcocystis*. *Sarcocystis* cysts were detected in five of the 80 hamburger examined. Therefore, the prevalence rate of *Sarcocystis* cysts in meat of hamburger was 6.25%. The *Sarcocystis* cysts contained numerous merozoites. Merozoites stained blue color and they have been detected from muscle tissues which stained red color. Some photomicrographs showed more than one cyst at a microscopy field and they had various size. The sizes of cysts were 8.4 to 39.2 × 14 to 75.6 μm.

**Key words:** Hamburger, meat, histological method, *Sarcocystis*, haematoxylin and eosin stain

<sup>1</sup>Department of Environmental Health Engineering, School of Public Health, Tehran University of Medical Sciences, Tehran, Iran

<sup>2</sup>Department of Medical Parasitology and Mycology, School of Public Health, Tehran University of Medical Sciences, Tehran, Iran

## INTRODUCTION

The parasites of genus *Sarcocystis* are among the most commonly found parasites in domestic ruminants in most countries of the world<sup>[1-11]</sup>. *Sarcocystis spp.* are obligate two host parasites, generally alternating between a herbivorous intermediate host and a carnivorous definitive host. After ingestion of *Sarcocystis*, merozoites subsequently released and enter muscle cells and neural tissue where they develop to mature *Sarcocystis*. Chronic *Sarcocystis* is apparently related to the encysted stage that occurs when immunity takes place. Heart, diaphragm and skeletal muscles are the preferred organs of *Sarcocystis spp.* location in the intermediate host and can persist through life in the hosts but many start to disappear after three months of inoculation<sup>[12]</sup>.

Man is the definitive host for *S. hominis* and *S. suihominis* with cattle and pigs as intermediate hosts for these species, respectively<sup>[13]</sup>. The infection of potential public health is important because man may acquire infection by consumption of under-cooked meat of infected cattle and pigs<sup>[14-16]</sup>. The skeletal muscle or meat is the most often eaten part of beef and may have a lot of *Sarcocystis* cysts<sup>[17-19]</sup>. In Iran meat is used in 70% of hamburger preparation (oval beef burger)<sup>[20]</sup>. In order to assess the infectivity of raw meat supplied for hamburger preparation in Garmsar, the current study was undertaken and *Sarcocystis* cysts were detected by histological method and haematoxyline-eosin staining.

## MATERIALS AND METHODS

**Sample collection:** Eighty raw hamburger (oval beef burger 70% lean) samples were collected from the retail food stores in Garmsar city of Semnan province of Iran from July 2002 to December 2002. The sampling was randomly taken.

**Preparation of tissue samples:** Five tissue samples (cube sections 1×1×0.8 cm in size) were prepared from each hamburger. Tissue samples were prepared and put on lace filiform textile. The samples were fixed in neutral-buffered 10% formalin solution, dehydrated in a graded ethanol, embedded in paraffin, sectioned as 6 µm thick sections and processed routinely for conventional Haematoxylin and Eosin staining as described by Culling *et al.*<sup>[21]</sup>.

## RESULTS AND DISCUSSION

Knowledge on prevalence of *Sarcocystis spp.* in domestic animals and meat products is necessary for the development of effective measures for prevention and

control of sarcocystiosis. A total of 400 haematoxylin and eosin-stained tissue samples from 80 hamburgers were examined for the presence of *Sarcocystis*. The stained samples were examined under a light microscope. Microscopic *Sarcocystis* cysts were observed per 10 cross-section microscope fields (using the 10 × objective). Each slide was examined for the presence of *Sarcocystis* and the slide was recorded as a positive slide when *Sarcocystis* were detected (Fig. 1). The results of the microscopic examination of the hamburger slides were showed some positive slide for *Sarcocystis* cysts, using the technique of Haematoxylin and Eosin staining. *Sarcocystis* cysts were observed elliptical bodies which had blue color in muscle tissues. These bodies are merozoites and a *Sarcocystis* cyst can be contained numerous merozoites. Merozoites stained blue color and they have been detected from muscle tissue which stained red color (Fig. 2). Some photomicrographs showed the presence of more than one cyst at a microscopy field (Fig. 1 and 3). The sizes of *Sarcocystis* cysts were 8.4 to 39.2×14 to 75.6 µm. Out of the 80 hamburgers examined, 5 (6.25%) were positive for *Sarcocystis* cysts.

Razmi reported that prevalence rates of microscopic *Sarcocystis* cysts in cattle, goat, sheep and buffalo of Iran are 73.79, 70.45, 60.93 and 40.90%, respectively<sup>[22]</sup>, while prevalence rate of microscopic *Sarcocystis* cysts is less in meat of hamburger (6.25%) at present study. This variation may be related to not using of whole beef meat in hamburger. The cysts varied in size from a few micrometers to several centimeters, depending on the host and species. *Sarcocystis* of some species grow so large that they are easily visible with naked eye. The presence of such *Sarcocystis* can cause condemnation of the carcass during meat inspection. *Sarcocystis* of some species remain microscopic even though tremendous numbers of cysts may be present in the muscles<sup>[23]</sup>. Latif *et al.*<sup>[5]</sup> reported that the macroscopic *Sarcocystis* appeared as milky-white coloured cysts embedded in the muscular tissues and their length ranged from 5 to 8 mm. The highest prevalence of macroscopic cysts was found in goats (33.6%) and the lowest in cattle (0.2%). The high prevalence rate of microscopic *Sarcocystis* (82.9 to 97.8%) in domestic animals indicates the importance of the infection for the intermediate host<sup>[5]</sup>. Man may also serve as an intermediate host and suffer myositis and vasculitis, but this tissue phase is rare and the source of such human infection has never been determined. Human intestinal illness, with clinical signs of nausea, abdominal pain and diarrhea lasted up to 48 h, has followed ingestion of *Sarcocystis* of *S. suihominis* in uncooked pork and *S. hominis* in uncooked beef. The extent of human illness from ingestion of infected meat has not been documented<sup>[24]</sup>.

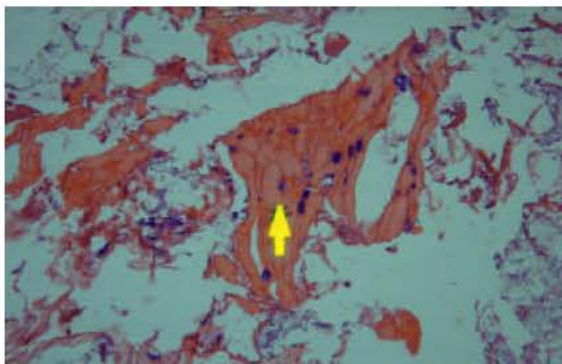


Fig. 1: Photomicrograph of *Sarcocystis spp.* cysts in a highly infected skeletal muscle utilized in hamburger production (Power, 20)

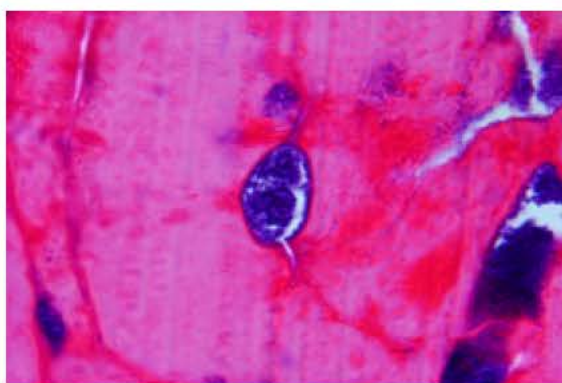


Fig. 2: Photomicrograph of *Sarcocystis spp.* cyst in skeletal muscle utilized in hamburger production (Power, 40)

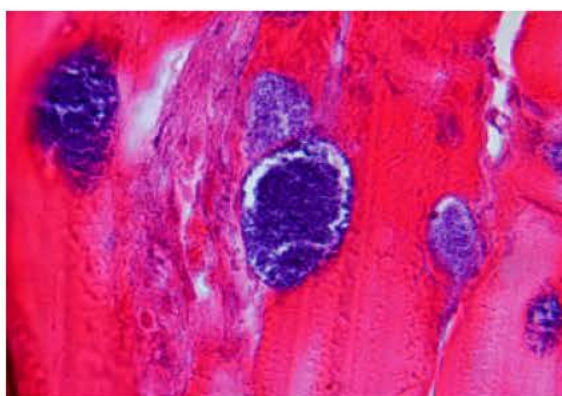


Fig. 3: Presence of several cysts of *Sarcocystis spp.* Cysts in skeletal muscle utilized in hamburger production (Power, 100)

The microscopic cysts are not detected on routine postmortem inspection of beef carcasses<sup>[2]</sup>. A method which recommended for detection of microscopic cysts is

histological sectioning of muscles that used in hamburger. Kia<sup>[26]</sup> applied a simple special protocol using semichon's acetic carmine stain for examination of muscles of some small mammals, naturally infected with *Sarcocystis spp.* According to this method, infected muscles fiber with *Sarcocystis* could easily be differentiated from muscle tissues. Some investigators believed that *Sarcocystis* does not infect human beings and is not harmful to human health. Because *Sarcocystis* is destroyed when meat is frozen at temperatures below  $-6^{\circ}\text{C}$  or cooked at  $60^{\circ}\text{C}$ <sup>[27]</sup>. However, there is a concern for existence of a strong endotoxin, sarcocystin, within cysts when *Sarcocystis* cysts were inactive by enough freezing and heating. Sarcocystin is a powerful toxin produced by zoitocysts of *Sarcocystis*. This toxin is effective on central nerves, heart, liver and adrenal glands of rabbit. It produces fever at low dose and produces severe diarrhea, collapse and death at high doses<sup>[17]</sup>. The symptoms of disease such as vomiting, diarrhea, muscle weakness and paralysis are produced by sarcocystin<sup>[28]</sup>. However, it should be noted that *Sarcocystis* cysts have sarcocystin and using of infected meat in hamburger may ill a susceptible person. Human can get *Sarcocystis* through eating under cooked meat and hamburger or ingested spores or getting sarcocystin through consuming meat and hamburger. Results of this study revealed the prevalence of *Sarcocystis* was 6.25% among used meat in hamburger in Garmsar, Iran. Also, present study showed that utilization of haematoxyline and eosin stain can help to ensure meat safety and quality of hamburger. However, application of immunohistochemical methods can improve the diagnosis and defect infected tissues with low intensity.

#### ACKNOWLEDGMENTS

The authors would like to thank Prof. Rezaian from the Department of Medical Parasitology and Mycology for his helpful advice. Also, thanks go to Mr. Fathi, Mrs. Zahabiun and Mrs. Hoseinpoor for their kind assistance.

#### REFERENCES

1. Botter, A., W.A. Charlston, W.E. Pomroy and M. Rommel, 1987. The prevalence and identify of *Sarcocystis* in beef cattle in New Zealand. Vet. Parasitol., 24: 157-168.
2. Dubby, J.P., C.A. Speer and R. Fayer, 1989. *Sarcocystis* in Cattle. In: Sarcocystosis in Animals and Man. CRC Press, Inc. Boca Raton, Florida, pp: 215.

3. Fayer, R. and J.P. Dubey, 1986. Bovine Sarcocystosis. Com. Contin. Edu. Pract. Vet., 8: 130-142.
4. Ginawi, M.A. and A.M. Shommein, 1977. Prevalence of sarcocystosis in sheep, goats, goats and camels in the Sudan. J. Vet. Sci. Anim. Husb., 18: 92-97.
5. Latif, B.M.A., J.K. Al-Delemi, B.S. Mohammed, S.M. Al-Bayati and A.M. Al-Amiry, 1999. Prevalence of *Sarcocystis spp.* in meat-producing animals in Iraq. Vet. Parasitol., 84: 5-90.
6. Ono, M. and T. Ohsumi, 1999. Prevalence of *Sarcocystis spp.* Cysts in Japanese and imported beef (Loin: *Musculus longissimus*). Parasitol. Intl., 48: 91-94.
7. Santosdasilva, M.R., R.J. Rodrigues, F.A.P. Dearaujo, C. Beck and A.T. Olicheskf, 2002. Detection of bovine *Sarcocystis cruzi* cysts in cardiac muscles: A new technique of concentration for diagnostic. Acta Sci. Vet., 30: 127-129.
8. Sobhani, M.M., 1998. Prevalence of *Sarcocystis* cysts in slaughtered animals in slaughter houses of Tehran province. DVM Thesis, No. 2459, Vet. Med. Fac. Tehran Univ., pp: 147.
9. Tenter, A.M., 1995. Current research on *Sarcocystis* species of domestic animals. Intl. J. Parasitol., 25: 1311-1330.
10. Vercruyssen, J., J. Franssen and M. van Goubergen, 1989. The prevalence and identity of *Sarcocystis* cysts in cattle in Belgium. Zentralbl Veterinarmed B., 36: 148-53.
11. Woldemeskel, M. and B. Gumi, 2001. Prevalence of *Sarcocystis* in One-humped Camel (*Camelus dromedarius*) from Southern Ethiopia. J. Vet. Med. Series B, 48: 223.
12. Mitchell, M.A., 1988. The prevalence of macroscopic *Sarcocystis* in New Zealand cattle at slaughter. New Zealand Vet. J., 36: 35-38.
13. Rommel, M., 1985. *Sarcocystosis* of domestic animals and humans. In Practice, pp: 158-160.
14. Dubey, J.P., 1976. A review of *Sarcocystis* of domestic animals and other coccidia of cats and dogs. J. Am. Vet. Med. Assoc., 169: 1061-1078.
15. Jay, J.M., 2000. Modern Food Microbiology. 6th Edn., An Aspen Publication, USA., pp: 679.
16. Kiel, R.J., 2005. Sarcosporidiosis. eMedicine continuing education. American College of Physicians-American Society of Internal Medicine, American Geriatrics Society, American Medical Association and American Medical Informatics Association. eMedicine.com, Inc. pp: 10. <http://www.emedicine.com/med/topic2066.htm>. Last visit date, 07/20/2005.
17. Gracey, J.F., 1992. Meat Hygiene. 9th Edn., Bailliere Tindall. London, pp: 635.
18. Saito, M., Y. Shibata, H. Azuma and H. Itagaki, 1998. Distribution of *Sarcocystis cruzi* cysts in bovine striated muscles. J. Jap. Vet. Med. Assoc., 51: 453-455.
19. Wang, M., H. Liu and W.F. Jia, 1966. A survey of *Sarcocystis* infection of animal carcasses in Beijing. Chinese J. Vet. Med., 22: 17-19.
20. Anonymous, 1991. Characteristics of freezing raw hamburger. Institute of Standard and Industrial Research of Iran National Standard. Standard No. 2304, pp: 17.
21. Culling, C.F.A., R.T. Allison and W.T. Barr, 1985. Cellular Pathology Technique. 4th Edn., Butterworth and Co. (Publishers) Ltd., pp: 553.
22. Razmi, Gh.R., 1989. Prevalence of *Sarcocystis spp.* in domestic ruminants of Iran. DVM Thesis, No. 1644, Vet. Med. Fac. Tehran Univ., pp: 175.
23. Herenda, D., P.G. Chambers, A. Ettriqui, P. Seneviratna and T.J.P. da Silva, 2000. Manual on meat inspection for developing countries. FAO Animal Production and Health - paper, pp: 119.
24. Susan, E. and B.S. Aiello, 2003. Merck Veterinary Manual. Sarcocystosis. Merck and Co., Inc. in Cooperation with Merial Ltd. Whitehouse Station, NJ, USA
25. Collins, G.H., W.A.G. Charleston and B.G. Wiens, 1980. Studies on *Sarcocystis spp.* A comparison of three methods for the detection of *Sarcocystis spp.* in muscles. New Zealand Vet. J., 28: 173.
26. Kia, E.B., 2003. A simple and large scale performing protocol for the detection of *Sarcocystis* in muscles of some small mammals. Iranian J. Pub. Health, 32: 28-30.
27. Fayer, R., 1975. Effects of refrigeration, cooking and freezing on *Sarcocystis* in beef from retail food stores. Proc. Helminthol. Soc. Wash., 42: 138-140.
28. Medical Glossary Organization, 2004. Coccidiosis. [http://www.medicalglossary.org/protozoan\\_infections\\_coccidiosis\\_definitions.html](http://www.medicalglossary.org/protozoan_infections_coccidiosis_definitions.html). Last visit date, 12/26/2004.