



# Journal of Medical Sciences

ISSN 1682-4474

**science**  
alert

**ANSI***net*  
an open access publisher  
<http://ansinet.com>

---

---

# Case Report

***JMS (ISSN 1682-4474) is an International, peer-reviewed scientific journal that publishes original article in experimental & clinical medicine and related disciplines such as molecular biology, biochemistry, genetics, biophysics, bio-and medical technology. JMS is issued eight times per year on paper and in electronic format.***

***For further information about this article or if you need reprints, please contact:***

Sadeghi Simin  
Department of Pediatrics,  
School of Medicine,  
Zahedan University of  
Medical Sciences,  
Zahedan, Iran

Tel: 98 4513411262  
Fax: 98 4513411251

J. Med. Sci., 7 (4): 707-709  
15th May, 2007

## **Scleroderma and Renal Crisis**

Sadeghi Simin and M. Aliakbarian

Systemic sclerosis (SSc) is a chronic multisystem disorder of unknown etiology characterized clinically by thickening of the skin caused by accumulation of connective tissue and by involvement of visceral organs, including the gastrointestinal tract, lungs, heart and kidneys. Vascular abnormalities, especially of the microvasculature are a prominent feature of SSc. This study introduces a rare scleroderma case report with renal involvement.

**Key words:** Nephrotic syndrome, scleroderma, renal crisis

**ANSI***net*  
Asian Network for Scientific Information

Department of Pediatrics, School of Medicine,  
Zahedan University of Medical Sciences, Zahedan, Iran

## INTRODUCTION

Systemic sclerosis (SSc) is a chronic multisystem disorder of unknown etiology characterized clinically by thickening of the skin caused by accumulation of connective tissue and by involvement of visceral organs, including the gastrointestinal tract, lungs, heart and kidneys. Vascular abnormalities, especially of the microvasculature are a prominent feature of SSc (Black, 1998; Haustein, 2002). The degree and rate of skin and internal organ involvement vary among patients. Two subsets, however, can be identified, even though there is some overlap. One subset is referred to as diffuse cutaneous scleroderma and is characterized by the rapid development of symmetric skin thickening of proximal and distal extremities, face and trunk (Tabata *et al.*, 1997). These patients are at greater risk for developing kidney and other visceral disease early in their course. The other subset is limited cutaneous scleroderma, which is defined by symmetric skin thickening limited to distal extremities and face. This subset frequently has features of the CREST syndrome, standing for calcinosis, Raynaud's phenomenon, esophageal dysmotility, sclerodactyly and telangiectasia. The prognosis in limited cutaneous scleroderma is better except for those patients who, after many years, develop pulmonary arterial hypertension or biliary cirrhosis (LeRoy *et al.*, 1988; Person, 2004). Involvement of visceral organs may also occur in the absence of any skin involvement, which is referred to as systemic sclerosis sine scleroderma (Table 1). Survival is determined by the severity of visceral disease, especially involving the lungs, heart and/or kidneys (Steen, 1994).

**Case report:** A 10 years old female was admitted for second time in October 2002 with diarrhea and generalized edema as her chief complaint. She had been discharged with nephritic syndrome diagnosis in her first admission. She had been treated with prednisolone. She had a history of weight loss without fever.

Examination revealed a pale lady with thick skin and restricted mouth opening (Fig. 1). There were sloughing ulcers over her extremities with contractures and

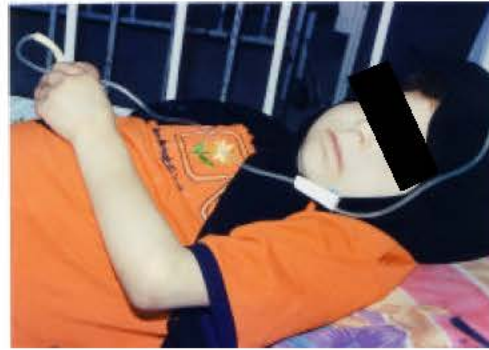

Fig. 1: The patient

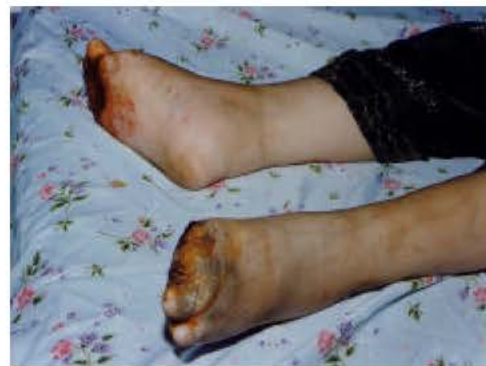

Fig. 2: Extremities gangrene

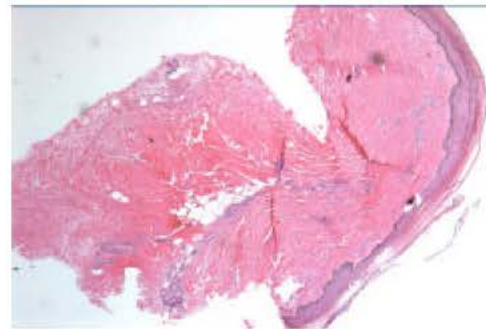


Fig. 3: Skin biopsy

Table 1: Diagnostic criteria of systemic sclerosis (scleroderma)

Major criteria

- Proximal scleroderma (skin thickening proximal to the metacarpophalangeal or metatarsophalangeal joints)

Minor criteria

- Sclerodactyly (cutaneous sclerosis distal to the metacarpophalangeal joints).
- Digital pitting scars or loss of subcutaneous tissue of the fingertips.
- Chronic interstitial pulmonary changes on chest radiographs.

For diagnosis-one major criterion or at least two minor criteria (American college of (Rheumatology, 1980)

gangrenous changes over her fingers (Fig. 2) and an abscess on her right thigh. She had also generalized pitting edema, livedoreticularis, rainode phenomenon, ascitis, no fever and a 100/60 blood pressure.

Laboratory investigations revealed a mild anemia, hypocalcemia, metabolic acidosis, hypothyroidism, proteinuria and hematuria. Liver function tests were normal. Decreased C3 and CH50 and increased triglyceride

and cholesterol, total serum albumin 2.1 g dL<sup>-1</sup> and protein 4.2 g dL<sup>-1</sup> and ESR = 100, were other findings.

Imaging evaluation showed free water in abdomen and hyper echo in both kidneys in sonography. Renal biopsy showed a focal and segmental pathology, skin biopsy revealed scleroderma (Fig. 3).

She treated with antibiotic for her abscess and hypothyroidism and nephritic syndrome, unfortunately two months later she died in her village.

## DISCUSSION

The outstanding feature of SSc is overproduction and accumulation of collagen and other extracellular matrix proteins, including fibronectin, tenascin and glycosaminoglycans, in skin and other organs. The disease process involves immunologic mechanisms, vascular endothelial cell activation and/or injury and activation of fibroblasts resulting in production of excessive collagen (Bennett, 1997; Person, 2004).

The injury to the endothelium leads to a state favoring vasoconstriction and ischemia. The damaged endothelium produces decreased amounts of prostacyclin, which is an important vasodilator and inhibitor of platelet aggregation. Platelets are activated on binding to the damaged endothelium and release thromboxane, a potent vasoconstrictor. Activated platelets also release Platelet-derived Growth Factor (PDGF), which is chemotactic and mitogenic for both smooth-muscle cells and fibroblasts and Transforming Growth Factor (TGF) $\beta$ , which stimulates fibroblast collagen synthesis. These and other cytokines stimulate intimal fibrosis and with their passage through the injured endothelium, may produce adventitial and perivascular fibrosis. Endothelin-1, a vasoconstricting factor released from endothelial cells on cold exposure, is also increased in SSc patients. In addition, it stimulates fibroblasts and smooth-muscle cells. The vasoconstriction action of endothelin-1 is normally opposed by Endothelium-derived Relaxation Factor (EDRF, nitric oxide), also secreted by endothelial cells (Harvey and McHugh, 1999; Renaudineau *et al.*, 1999). The normal compensatory increase in EDRF is not seen in some patients with SSc, suggesting impairment of its synthesis. A deficiency of vasodilatory neuropeptides resulting from sensory system nerve damage may also produce a condition favoring vasoconstriction. Vasoconstriction itself also contributes to endothelial damage through a mechanism of reperfusion injury, resulting in vascular occlusion and fibrosis (LeRoy *et al.*, 1988; Person, 2004).

Renal involvement is found in over half the patients and consists of intimal hyperplasia of the interlobular arteries; fibrinoid necrosis of the afferent arterioles, including the glomerular tuft and thickening of the

glomerular basement membrane. Small cortical infarctions and glomerulosclerosis may be present. The renal pathologic change is often indistinguishable from that observed in malignant hypertension. Renal vascular lesions, however, may be present in the absence of hypertension. Immunofluorescence studies of kidney have shown IgM, complement components and fibrinogen in the walls of affected vessels (Horn *et al.*, 2001; Steen, 1994). Angiographic renal studies in patients with SSc may show constriction of the intralobular arteries, a finding that simulates the vasospasm of the digital arteries observed in Raynaud's phenomenon. Cold-induced Raynaud's phenomenon has been shown to decrease renal blood flow (Kahaleh and Matucci-Cerinic, 1995).

## REFERENCES

- Bennett, R.M., 1997. Mixed Connective Tissue Disease and Other Overlap Syndromes. In: Textbook of Rheumatology. 5th Edn., Kelley, W.N. *et al.* (Eds.), Philadelphia, Saunders, pp: 1065.
- Black, C.M., 1998. Systemic Sclerosis: Management, in Rheumatology. 2nd Edn., Klippel, J.H. and P.A. Dieppe (Eds.), London, Mosby International, 7: 11.
- Harvey, G.R. and N.J. McHugh, 1999. Serologic abnormalities in systemic sclerosis. *Curr. Opin. Rheumatol.*, 11: 495-502.
- Haustein, U.F., 2002. Systemic sclerosis-scleroderma. *Dermatol. Online J.*, 8: 3.
- Horn, H., P. Ottosen and P. Junker, 2001. Renal crisis in asclerodermic scleroderma-lppus overlap syndrome. *Lupus*, 10: 886-888.
- Kahaleh, B. and M. Matucci-Cerinic, 1995. Raynaud's phenomenon and scleroderma. Dysregulated neuroendothelial control of vascular tone. *Arthritis Rheum*, 38: 1-4.
- LeRoy, E.C., C. Black, R. Fleischmajer, S. Jablonska, T. Krieg, T.A. Medsger Jr., N. Rowell and F. Wollheim, 1988. Scleroderma (systemic sclerosis): Classification, subsets and pathogenesis. *J. Rheumatol.*, 15: 202-205.
- Person, D.A., 2004. Systemic Sclerosis. <http://www.emedicine.com/ped/topic 219.htm>.
- Renaudineau, Y., R. Revelen, Y. Levy, K. Salojin, B. Gilburg, Y. Shoenfeld and P. Youinou, 1999. Anti-endothelial cell antibodies in systemic sclerosis. *Clin. Diagn. Lab. Immunol.*, 6: 156-160.
- Steen, V.D., 1994. Renal involvement in systemic sclerosis. *Clin. Dermatol.*, 12: 253-258.
- Tabata, H., S. Ohtsuka, A. Yamakage and S. Yamazaki, 1997. Cutaneous electron microscopic study of scleroderma diffusa in childhood. *Int. J. Dermatol.*, 36: 764-776.