



Journal of Medical Sciences

ISSN 1682-4474

science
alert

ANSI*net*
an open access publisher
<http://ansinet.com>

JMS (ISSN 1682-4474) is an International, peer-reviewed scientific journal that publishes original article in experimental & clinical medicine and related disciplines such as molecular biology, biochemistry, genetics, biophysics, bio-and medical technology. JMS is issued eight times per year on paper and in electronic format.

For further information about this article or if you need reprints, please contact:

Biezhan Arya
Department of General Surgery,
Gorgan University of
Medical Sciences,
P.O. Box: 49175-553
Gorgan, Iran

Meckel's Diverticulitis Due to Actinomycosis

¹Biezhan Arya, ²Ramin Azarhoush and ³Mohammad Jafar Golalipour

The patient was 36 years old female admitted due to periumbilical pain and anorexia since about 24 h prior to hospitalization. She underwent laparotomy with impression of acute appendicitis. Operative finding was Meckel's diverticulitis, so appendectomy and resection of diverticular bearing Ileum with end to end anastomosis was performed. Post operation course was uneventful and she discharged 5 days later. Pathological study confirmed the diagnosis of Meckel's diverticulitis due to actinomycosis as the cause of diverticular obstruction. The relatively rare incidence and preoperative diagnosis difficulties make publication of this case worthwhile.

Key words: Actinomycosis, Meckel's diverticulitis

INTRODUCTION

Actinomycosis is a localized inflammatory mass, usually of the jaw area. The most common site of involvement is oral cavity and cervicofacial area 50-60% followed by thoracic 15-25% and abdominal involvement 20% (Sarker *et al.*, 2004; Colon-Candelaria *et al.*, 2005).

Abdominal infection most frequently involves cecal area (usually following appendectomy), Appendix and left colon flexure (Solecki and Czupryna, 2001; Habib *et al.*, 2002; Hohenbleicher *et al.*, 2002; Lukacs *et al.*, 1992).

Meckel's diverticulum involves relatively rare.

Case report: The patient was 36 years old lady who admitted due to steady periumbilical pain, anorexia, nausea and vomiting since about 24 h prior to hospital admission. On physical examination, she had tenderness of periumbilical and right lower quadrant area. On laboratory studies there was leukocytosis of 11200 with 83% PMN and 17% lymphocytes and normal urinalysis. With impression of acute appendicitis she underwent laparotomy via McBurney abdominal incision, operative finding was normally looking appendix and Meckel's diverticulitis, so appendectomy and resection of diverticulum bearing Ileum with end to end Ileo-ileostomy performed. Pathological study was consistent with

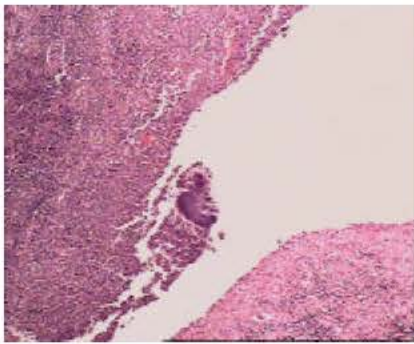


Fig. 1: Inflamed small bowel wall with presence of actinomycosis elements (H & E, X300)

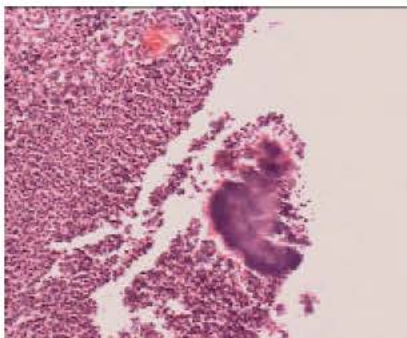


Fig. 2: Actinomycosis in small bowel wall with prominent PMN infiltrates (H & E, X400)

Meckel's diverticulitis and Actinomycosis as the etiology of diverticular obstruction (Fig. 1 and 2). There was no data for DM or any other type of immunosuppression and no additional further antibiotic therapy prescribed.

Post-op course was uneventful and she discharged 5 days later. She was well in one year post op follow up.

DISCUSSION

Meckel's diverticulum, the most common true and congenital GI tract diverticulum results from incomplete closure of the omphalomesenteric (vitelline) duct (Ciardo *et al.*, 2004). Complications of Meckel's diverticulum including intestinal obstruction, bleeding, acute diverticulitis, or the presence of it in hernial sac Littre's hernia (Stone *et al.*, 2004).

On the other hand, actinomycosis is characterized by chronic inflammatory induration and sinus formation.

The causative agent is *Actinomyces israelii*, a gram positive anaerobic microaerophilic bacterium, a normal resident of the mouth and the cervicofacial region (Sarker *et al.*, 2004; Cirafici *et al.*, 2002).

The most frequently involved site is cervicofacial and oral cavity 50-60% followed by thoracic 15-25% and abdomen 20% (Sarker *et al.*, 2004; Colon-Candelaria *et al.*, 2005).

Abdominal infection most frequently involves the cecal area (usually following appendectomy) and left colon flexure (Solecki and Czupryna, 2001; Habib *et al.*, 2002; Hohenbleicher *et al.*, 2002; Lukacs *et al.*, 1992).

The diagnosis of abdominal Actinomycosis should be suspected if an indolent mass or chronic sinus follows an appendectomy (Castillenti and Conklin, 1990; Campo *et al.*, 2001).

Meckel's diverticulum involvement is very rare (Lukacs *et al.*, 1992).

Actinomycosis rarely involves pelvis (Elsayed *et al.*, 2006; Bercovich *et al.*, 2003; Michel, 2004), liver (Chen *et al.*, 2006; Buyukavci *et al.*, 2004), omentum (Schultheisz and Gyorgy, 1994), urachus (Jalon Monzon *et al.*, 2002), Thyroid (Park *et al.*, 2005), mediastinum (Alborzi *et al.*, 2006), spinal cord (Gaini *et al.*, 2006), ovaries (Valko *et al.*, 2006; Koren *et al.*, 2002), kidneys, ureters, bladder (Hohenbleicher *et al.*, 2002; Michel, 2004; Gidwani *et al.*, 2005), retroperitoneum (Castillenti and Conklin, 1990; Gidwani *et al.*, 2005), bones (Pinilla *et al.*, 2006), orbit (Pagliani *et al.*, 2006) and abdominal wall (Hefny *et al.*, 2006), perineal (Bauer *et al.*, 2006), cutaneous (Sardana *et al.*, 2001).

Actinomyces israelii is a normal commensal inhabitant of the oral cavity and tonsillar crypts may become invasive pathogen due to unknown causes but in 75% immuno suppression or local tissue barriers break down predisposingly.

Diagnosis could be made by finding of characteristic sulfur granules on microscopic examination (Sarker *et al.*, 2004).

Special stains should be used to exclude fungal infection.

Treatment consists of medical therapy with antibiotics including: Penicillin, Sulfonamides, or Tetracycline and surgery for abscesses and areas of chronic scarring (Sarker *et al.*, 2004; Michel, 2004; Sardana *et al.*, 2001).

Clinical picture, complications and surgical incision are the same in appendicitis and Meckel's diverticulitis patients, so pre-op differentiation is academic and unnecessary. During laparotomy if the diverticulum is broaden base, simple diverticulectomy would compromise the Ileal lumen, then Ileal resection and end to end ileo-ileal anastomosis is mandatory.

CONCLUSIONS

Actinomycosis most frequently involves cervicofacial, thoracic and abdominal area including appendix and left colon flexure and Meckel's diverticulum (rarely) where stasis of fecal material is present. Diabetes Mellitus or any other type of immuno suppression may be as predisposing factor and must be included in mind.

Treatment of Meckel's diverticulitis due to any etiology is the same, diverticulectomy or ileal resection and ileo-ileostomy. The important question is that in the case of Meckel's diverticulitis and Actinomycosis what antibiotic/S and how long is necessary? In our case we used cephalothin for 3 doses (1 pre-op and 2 post up), because pathologic report took about one week time, when the patient had discharged and no additional antibiotic therapy prescribed. In one year follow up she was doing well.

REFERENCES

Alborzi, A., N. Pasyar and J. Nasiri, 2006. Actinomycosis as a neglected diagnosis of mediastinal mass. *Jpn. J. Infect. Dis.*, 59: 52-53.

Bauer, P., S. Sultan and P. Atienza, 2006. Perineal actinomycosis: Diagnostic and management considerations: A review of six cases. *Gastroenterol. Clin. Biol.*, 30: 29-32.

Bercovich, A., M. Guy, A.J. Karayiannakis, M. Gdalia, E. Muriel, R. Dgani and A.P. Zbar, 2003. Ureteral obstruction and reconstruction in pelvic actinomycosis. *Urology*, 61: 224.

Buyukavci, M., I. Caner, S. Eren, O. Aktas and R. Akdag, 2004. A childhood case of primary hepatic actinomycosis presenting with cutaneous fistula. *Scand. J. Infect. Dis.*, 36: 62-63.

Campo, J.M., T.T. Rubio, R.B. Churchill and R.G. Fisher, 2001. Abdominal actinomycosis with hydronephrosis in childhood. *Pediatr. Infect. Dis. J.*, 20: 901-903.

Castillenti, T.A. and C.R. Conklin, 1990. Actinomycosis: An unusual complication following appendicitis. *J. Am. Osteopath. Assoc.*, 90: 269-273.

Chen, L.W., L.C. Chang, S.S. Shie and R.N. Chien, 2006. Solitary Actinomycotic abscesses of liver: Report of two cases. *Int. J. Clin. Pract.*, 60: 104-107.

Ciaro, L.F., F. Agresta and N. Bedin, 2004. Meckel's diverticulum: A neglected (or deliberately ignored) entity. *Chir. Ital.*, 56: 689-692.

Cirafici, L., M. Worreth and F. Froehlich, 2002. Pelvic and abdominal actinomycosis. Case report and review of the literature. *Rev. Med. Suisse. Romande.*, 122: 535-537.

Colon-Candelaria, M.M., L. Duharte-Vidaurre, C. Sanchez-Sergenton, G. Gonzalez-Claudio and S. Saavedra, 2005. An unusual presentation of actinomycosis in a young woman, after surgery. *Biol. Asic. Med. Pr.*, 97: 209-213.

Elsayed, S., A. George and K. Zhang, 2006. Intrauterine contraceptive-device-associated pelvic Actinomyces caused by Actinomyces urogenitalis. *Anaerobe*, 12: 67-70.

Gaini, S.H., B.T. Roge, C. Pedersen, S.S. Pedersen and A.S. Brenoe, 2006. Severe Actinomyces Israelii infection involving the entire spinal cord. *Sou. J. Infect. Dis.*, 38: 211-213.

Gidwani, A.L., D. Connolly, A. Khan, R. Kemohan, M. Brown and B. Kenny, 2005. Renal, colonic and retroperitoneal Actinomycosis: A case report. *West. Afr. J. Med.*, 24: 343-345.

Habib, E., T. Aoura, M. Mekkaoui and A. Elhadad, 2002. Actinomycosis of the appendix. Report of two cases. *Rev. Med. Interne.*, 23: 638-641.

Hefny, A.F., S. Joshi, Y.A. Saadeldin, H. Fadlalla and F.M. Abu-Zidan, 2006. Primary anterior abdominal wall actinomycosis. *Singapore Med. J.*, 47: 419-21.

Hohenbleicher, F., R. Hohenbleicher and K.H. Hallfeldt, 2002. Actinomycosis of the sigmoid as obstructive space-occupying lesion of the pelvis a case report. *Chirurg*, 73: 733-735.

Jalon Monzon, A., O. Rodriguez Faba, J. Garcia Rodriguez, M. Diaz Sotres and J. Fernandez Gomez, 2002. Urachal actinomycosis: Apropos of a case. *Actasurol. Esp.*, 26: 519-522.

Koren, R., Y. Dekel, E. Ramadan, V. Veltman and Z. Dreznik, 2002. Periappendiceal actinomycosis mimicking malignancy report of a case. *Pathol. Res. Pract.*, 198: 441-443.

Lukacs, L., T. Kiss, G. Gobel, Z. Fazekas and G. Csanaky, 1992. Actinomycosis with abdominal manifestation. *Orvostudományi. Hetil.*, 24: 1309-1311.

- Michel, P., 2004. Pelvic Actinomycosis revealed by pelvic peritonitis. *Ann. Chir.*, 129: 96-99.
- Pagliani, L., L. Campi and G.M. Cavallini, 2006. Orbital Actinomycosis associated with painful ophthalmoplagia. *Ophthalmologica*, 220: 201-205.
- Park, Y.H., J.H. Baik and J. Yoo, 2005. Acute thyroiditis of Actinomycosis. *Thyroid.*, 15: 1395-1396.
- Pinilla, I., C. Martin-Hervas and E. Gil-Garay, 2006. Primary sternal osteomyelitis caused by *Actinomyces israelii*. *South. Med. J.*, 99: 96-97.
- Sardana, K., V. Mendiratta and R.C. Sharma, 2001. A suspected case of primary cutaneous actinomycosis on the buttock. *J. Dermatol.*, 28: 276-278.
- Sarker, C.B., S. Rahman, N.I. Siddiqui, M.H. Huq, A.K. Musa, S.I. Talukder, K.S. Alam, C.R. Debnath, A.K. Kabir and F.M. Saleh, 2004. Thoracic Actinomycosis. *Med. J.*, 13: 88-90.
- Schulteisz, F. and A. Gyorgy, 1994. Isolated actinomycosis of the omentum simulating appendicitis. *Orv. Hetil.*, 135: 973-975.
- Solecki, R. and A. Czupryna, 2001. A case of acute appendicitis with abdominal Actinomycosis. *Przegl. Lek.*, 58: 466-467.
- Stone, P.A., M.J. Hofeldt, J.E. Campbell, G. Vedula, J.A. DeLuca and S.K. Flaherty, 2004. Meckel's diverticulum: Ten-year experience in adults. *South. Med. J.*, 97: 1038-1041.
- Valko, P., E. Busolini, N. Donati, S. Chimchila Chevili, T. Rusca and E. Bernasconi, 2006. Severe large bowel obstruction secondary to infection with *Actinomyces israelii*. *Scand. J. Infect. Dis.*, 38: 231-234.