



Journal of Medical Sciences

ISSN 1682-4474

science
alert

ANSI*net*
an open access publisher
<http://ansinet.com>

JMS (ISSN 1682-4474) is an International, peer-reviewed scientific journal that publishes original article in experimental & clinical medicine and related disciplines such as molecular biology, biochemistry, genetics, biophysics, bio-and medical technology. JMS is issued eight times per year on paper and in electronic format.

For further information about this article or if you need reprints, please contact:

Dr. Nadia A. Louca
Department of Hormones,
Medical Research Division,
National Research Centre,
El-Buhouth Street, Dokki,
Cairo, Egypt

Tel: +202 27942619
Fax: +202 27941211

Sleep Apnea Impact on Heart Diseases and Hormone Level

Nadia A. Louca

The aim of this research was to study the effect of Obstructive Sleep Apnea (OSA), snoring and the episodes of cessation of breathing on heart failure, cardiac arrhythmia and coronary artery diseases. Thirty patients has been suffering from OSA since 7 years were subjected to scintigraphic study using the radiopharmaceutical (Thalium²⁰¹) and Tc^{99m} MIBI) using General Electric-Infinit Hawkeye 4' gamma camera. Present study showed that apnea causes obstruction of right coronary arteries, ischemia of the lower part of posterior wall of left ventricle, infarction of postero-lateral wall of left ventricle, ischemia in the apico-septal wall and infarction of the infero-septal wall of left ventricle. In conclusion, OSA increases the risk of stroke and death, disturb sleep level, accompanied with hypertension, atrial fibrillation and erectile dysfunction. Treatment by the aid of Continuous Positive Airway Pressure (CPAP) resulted in improvement. Comparing the hormone level and scintigraphy is under investigation.

Key words: Obstructive sleep apnea, hormone levels, heart diseases

INTRODUCTION

Sleep apnea is a respiratory disorder that affects 4-9% of adult males. Its most common manifestation is loud snoring and it may occur several hundred times throughout the night, resulting in sleep fragmentation and excessive daytime sleepiness (Young *et al.*, 2002).

Sleep apnea is a serious sleep disorder that occurs when a person's airway collapses and breathing is interrupted during sleep. People with untreated sleep apnea stop breathing repeatedly during their sleep, sometimes hundreds of times during the night. Loud snoring a hallmark of the condition occurs when the airway collapses (Kuniyoshi and Somers, 2006). More than 18 millions of American women and men of all age groups are affected by such disorder.

Blood pressure fluctuates widely and suddenly in response to episodes of apnea and hypopnea (Chobanian *et al.*, 2003). Such fluctuations are possibly due to a sudden surge in the sympathetic nervous system, which has also been associated with sleep apnea. The sympathetic nervous system controls involuntary muscles, importantly those in the blood vessels and heart (Francis and Tang, 2003).

Researches observed that the higher the number of apneas and hypopneas a patient had, the higher his risk for heart attack. Many of the factors associated with stroke and sleep apnea (a risk for blood clots and narrowing of the arteries) may also increase the risk for heart attacks. Evidence suggests, however, that the effect of apneas on coronary artery disease and heart attack is not as significant as it is on heart failure and stroke (Shamsuzzaman *et al.*, 2003; Olson and Somers, 2006).

There are types of sleep apnea. There is centralized sleep apnea in which the brain forgets to tell the body to breathe. Secondly, there is obstructive sleep apnea, the most common of the two, it is caused by a blockage of the airway. Usually when the soft tissue in the back of the throat blocks the airway causing the obstruction.

Degree of severity: mild, moderate or severe, will depend on the Apnea Hypopnea Index (AHI). The AHI describes the number of respiratory arrests and periods of clearly diminished respiratory lows accompanied by oxygen decreases per hour. For instance: 20 apnea and 10 hypopnea equal an AHI of 30.

Congestive Heart Failure (CHF) is one of leading heart diseases. As blood vessel supplying oxygen to the heart itself is blocked, some of heart muscles start to die. Once heart muscle is dead, it is irreversible. Now

remaining heart muscle must work harder. As a result, heart muscle become thicker and the size of heart enlarged. This enlarged heart cannot pump out blood effectively (Usui *et al.*, 2005).

This is probably the best data available now in that obstructive sleep apnea, indicate increased risk for stroke or death. Obstructive sleep apnea, which involves frequent stoppages of breathing caused by narrowing of the upper airways, can increase risks for stroke and death, according to groundbreaking research (Azevedo *et al.*, 2001).

Hypopnea is a decrease in breathing that is not as severe as an apnea. So, if narrow breath airflow is 100 to 70%, hypopnea is 69 to 26% of a normal breath. Like apnea, hypopneas are associated with a 4% or greater drop in the saturation of oxygen in the blood and usually occur during sleep. Also like apneas, hypopneas usually disturb level of sleep. A Hypopnea Index (HI) can be calculated by dividing the number of hypopneas by the number of hours of sleep (Kiely *et al.*, 1998).

There is an association between obstructive sleep apnea and various kinds of heart disease-hypertension, atrial fibrillation, stroke and heart failure (Gami and Somers, 2004). When breathing stops during apneas, carbon dioxide levels in the blood increase and oxygen levels drop (Usui *et al.*, 2005; Hussain and Karnath, 2004).

Preliminary study on male testosterone level in plasma ed no significant decrease, although some of the patients suffered form Erectile Dysfunction (ED).

After using the improvement device (CPAP) continuous positive airway pressure where there is an air blower, forces air through the upper airway which prevents the upper airway tissue form collapsing during sleep (Usui *et al.*, 2005).

The aim of this research was to study the effect of Obstructive Sleep Apnea (OSA), snoring and the episodes of cessation of breathing on heart failure, cardiac arrhythmia and coronary artery diseases.

MATERIALS AND METHODS

- This study was carried on 30 individuals suffering form Obstructive Sleep Apnea (OSA), for more than 7 years, their ages ranged from 62-75, 25 males and 5 females.
- **Cardiac radiopharmaceuticals:** The injected activities were adapted to the weight of the patient. The radiopharmaceutics was linked with Tc^{99m}

- (a) Sestamibi = Methoxy-isobutyl isonitrile: Stress 11 MBq kg⁻¹; Rest 11 MBq kg⁻¹
- (b) Thallium ²⁰¹: Stress-Redistribution 1,5 MBq kg⁻¹; Reinjection 0.5 MBq kg⁻¹
Rest-Redistribution 1,5-2 MBq kg⁻¹; Standard injected activity for an adult 70 kg.
- Radiopharmaceutics ^{99m}Tc (MIBI): Stress 750 MBq; Rest 750 MBq
- For Thallium ²⁰¹: Stress-redistribution 110 MBq; Reinjection 40 MBq
Rest-redistribution 110 to 150 MBq

Herein we studied heart scintigraphy of 30 individuals (25 males and 5 females) with clinically significant OSA for explaining, heart failure, cardiac arrhythmia and coronary artery disease. The pictures and data were recorded with General Electric (GE)-Infinia Hawkeye 4' gamma camera, integrated with xeleris™ work station to enhance productivity using Ignite™ technology, it contains Picture Archiving and Communications Systems (PACS).

Case 1: Male patient of 69 years old was followed for hypertension and apnea of sleep. cardiovascular risks: Obesity, smoker, brother and mother hypertension.

First acquisition of scintigraphic myocardial images after injection of 0.56 mg kg⁻¹ of persantine stress images synchronized with ECG found hypofixation of apico-inferior wall of left ventricle. There was pulmonary stains and dilated left ventricular cavity.

Rest images 4 h later synchronized with ECG there was ameliorated perfusion of the Apico-inferior wall of left ventricle. In both stress and rest the ejection fraction of left ventricle were deteriorated with increased end systolic and end diastolic volumes. Stress: EF (Ejection Fraction) 32%; ESV (End Systolic Volume) 141 mL; EDV (End Diastolic Volume) 208 mL. Rest: EF 32%; ESV 145 mL; EDV 213 mL.

Conclusion: There is ischemia in the Apico-inferior wall of left ventricle associated with lung strains and dilated left ventricular cavity where are indirect signs for more than one coronary artery obstruction which was confirmed by coronarography there were obstruction of right coronary and left artery (Fig. 1a, b).

Case 2: A male patient of 73 years old complaining of pain and dyspnea with effort, sleep, apnea was discovered and was treated with the +ve pressure. Cardiovascular risks: obesity, hypertension, dyslipidemia and diabetes. Effort test: by ergometric bicycle arrest for pain without changes

in ECG. Stress images: Synchronized with ECG found defect of perfusion in posterior part of inferior wall. EF was normal 65% and ESV 50 mL. There was no pulmonary stasis but transitory dilated left ventricular cavity which disappears 4 h later on rest. Four hours later there was normalization of perfusion of lower wall of left ventricle.

Conclusion: There was ischemic of post part of lower wall of left ventricle (Fig. 2a, b).

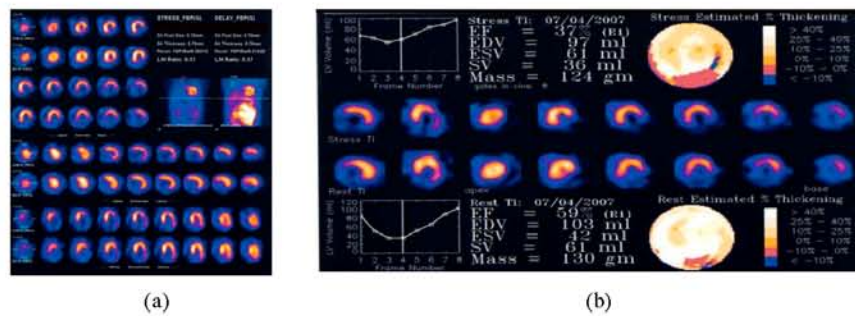
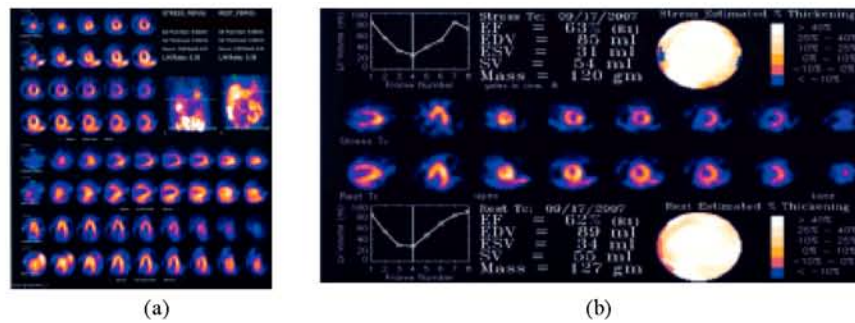
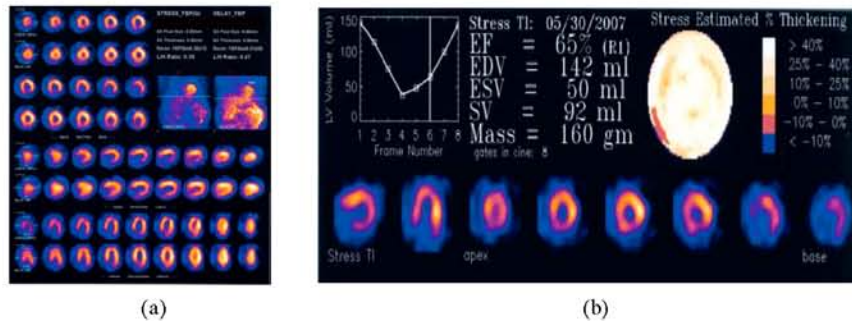
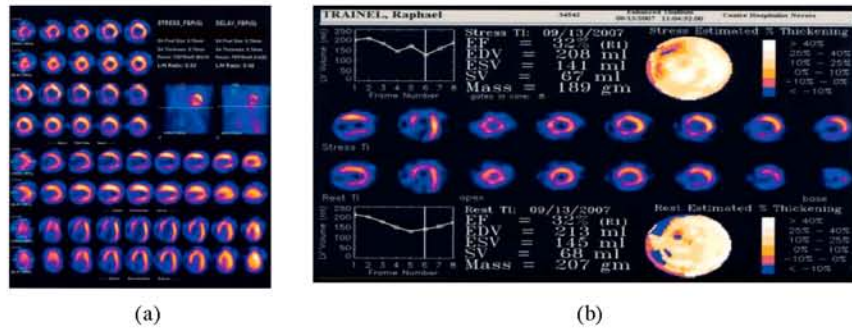
Case 3: A female patient of 60 years old complaining of dyspnea with effort and apnea of sleep. Cardiovascular risks: diabetes, cholesterol, hypertension, vascular disease of lower limbs. Effort test by ergometric bicycle arrest for chest pain. Stress images synchronized with ECG faint hypofixation of anterior wall of left ventricle with normal ejection fraction 63% end systolic volume 31 mL. Rest images 4 h later indicate normalization of perfusion in the anterior wall. EF normal 62% and ESV 34 mL.

Conclusion: Ischemia of anterior wall coronarography found obstruction of anterior interventricular artery which was dilated by start (Fig. 3a, b).

Case 4: A male 54 years old complaining of myocardial infarction since one year recurrence of chest pain since two months. Cardiovascular risks: hypertension, smoking, diabetes. Persantine test 0.56 mg kg⁻¹ intravenous injection there were tachycardia cardio and increase of arterial tension. Images acquisition synchronized with ECG. Perfusion: Lacunar defect of perfusion in the postero-lateral wall of left ventricle. Function: decreased EF 37%, little increase of ESV 61 mL and EDV 97 mL. Rest: Four hours later images acquisition synchronized with ECG. Persistence of posterior lateral perfusion defect with amelioration of perfusion in the lateral wall. Function: Normalization of EF of left ventricle 59% and normalization of ESV 42 mL.

Conclusion: Infarction of posterior-lateral wall of left ventricle associated with residual ischemia in the lateral wall (Fig. 4a, b).

Case 5: Female patient of 59 years old complaining of pain associated with big physical effort. Cardiovascular risks: obesity, hypertension, smoking, dyslipidemia, hereditary factors (father and aunt died from infarction of heart). Persantine test: injection intravenous 0.56 mg kg⁻¹ with no variation of arterial tension or cardiac rhythm.



Stress acquisition of images synchronized with ECG perfusion: Lacunar perfusion defect posterior-inferior wall of left ventricle with hypoperfusion apico septal wall. Function: EF of left ventricle normal 54%, ESV = 37 mL, EDV = 80 mL. Rest: Four hours later images acquisition. Perfusion: Persistence of lacunars perfusion defect in the posterior part of inferior wall and amelioration of perfusion in the apico-septal wall.

Conclusion: Infarction in the posterior part of inferior wall of left ventricle associated with ischemia in the apico-septal wall (Fig. 5a, b).

Case 6: Male patient of 80 years old complaining of dyspnea and pain on rest. Cardiovascular risks: Age, hypertension, dyslipidemia diabetes, hereditary factors. Persantine test: 0.5 mg kg⁻¹ IV. Stress images acquisition synchronized with ECG: Hypofixation in Anterio-Apico infero-septal wall with normal perfusion of anterior wall. Function: EF 54%, ESV: 53 mL, EDV: 115 mL. No pulmonary stasis (stagnation) of radiotracer transitional Dilated left ventricular cavity. Rest acquisition of image

4 h later: Perfusion: Normalization of perfusion in Anterior-Apico-infero-septal walls of left ventricle. Function: EF = 54%, ESV = 38 mL EDV 82 mL.

Conclusion: Left ventricle anterior-apico-infero septal wall ischemia, coronarography ed obstruction in anterior interventricular artery, right coronary (Fig. 6a, b).

Case 7: Male patient of 47 years old. Hospitalized for sever pain in chest dyspnea. Cardiovascular risks: hypertension, diabetes, smoking, dyslipidemia. Persantine test 0.56 mg kg⁻¹ intra-venous injection. Stress acquisition of images synchronized with ECG. Perfusion: lacunan perfusion defect in the infero septal wall of left ventricle. Function: Alteration of ejection fraction of left ventricle 32%. Normal volumes: ESV 45 mL EDV 66 mL, dilated left ventricular cavity. Rest: Images acquisition 4 h later synchronization with ECG. Perfusion: persistence of the lacunar perfusion defect in the infero-septal wall associated with little perfusion in the anterior part of inferior wall of left ventricle.

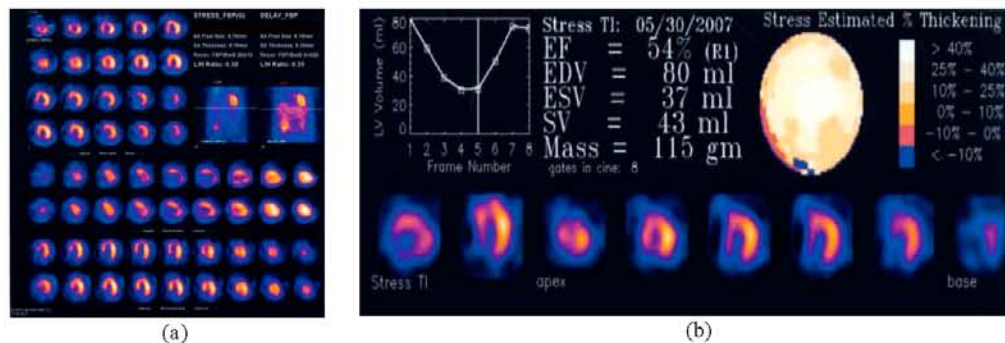


Fig. 5a, b: Infarction in the posterior part of inferior wall of left ventricle

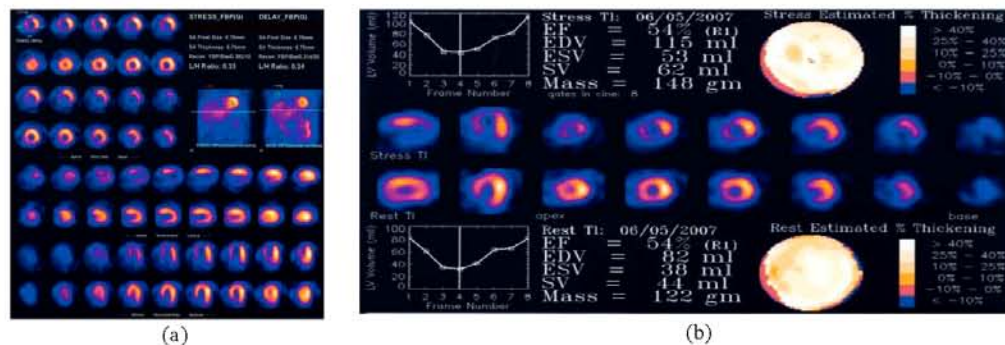


Fig. 6a, b: Left ventricular antero-apico-infero septal wall ischemia

Function: Normalization of EF of left ventricle 48%, ESV 41 mL, EDV 79 mL.

Conclusion: Myocardial infarction in the infero-septal wall of left ventricle associated with residual ischemia in the anterior part of inferior wall (Fig. 7a, b).

Case 8: Male patient of 75 years old, presenting sleep apnea since 2 years treated with positive pressure (CPAP) no symptoms. Cardiovascular risks: Age, sex, hypertension, smoking effort test with ergometric bicycle stop of test for fatigue stress acquisition images synchronization with ECG. Perfusion: Localized defect of perfusion in the posterior part of inferior wall of left ventricle. Function: EF of left ventricle 53%, ESV = 62 mL, EDV = 130 mL. Pulmonary stasis (stagnation): Transitory dilatation of left ventricular cavity. Rest: acquisition images 4 h later without synchronization with ECG:

Perfusion: Normalization of perfusion in the posterior part of lower wall of left ventricle. Coronarography found 15% obstruction of right coronary.

Conclusion: Small myocardial localized ischemic in the posterior part of lower wall of left ventricle (Fig. 8a, b).

Case 9: Male patient 62 years old diabetic, presenting pain and dyspnea with effort. Cardiovascular risks: Age, diabetic, dyslipidemia. Effort test: by ergometric bicycle stress acquisition of images with synchronization with ECG. Perfusion: Hypofixation localized in the posterolateral wall of left ventricle. Function: EF of left ventricle 63%, ESV = 37 mL, EDV = 99 mL slightly transitory dilatation of left ventricle. Rest: Images acquisition 4 h later. Perfusion: Normalization of perfusion in the postero-lateral wall of left ventricle.

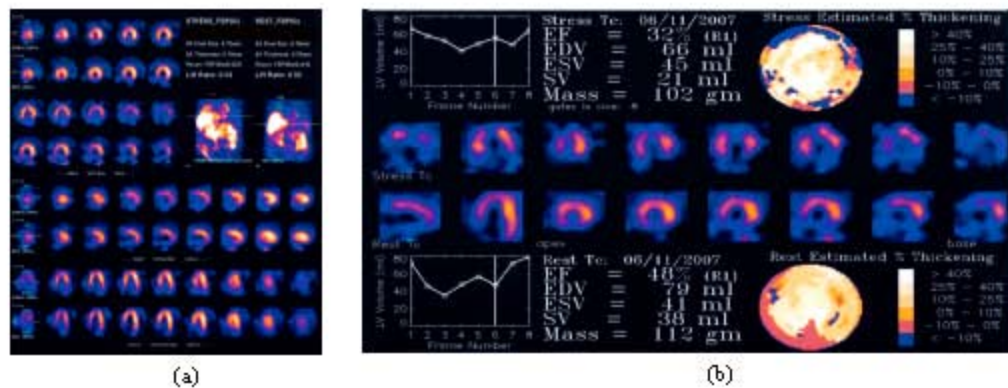


Fig. 7a, b: Myocardial infarction in the infero-septal wall of left ventricle

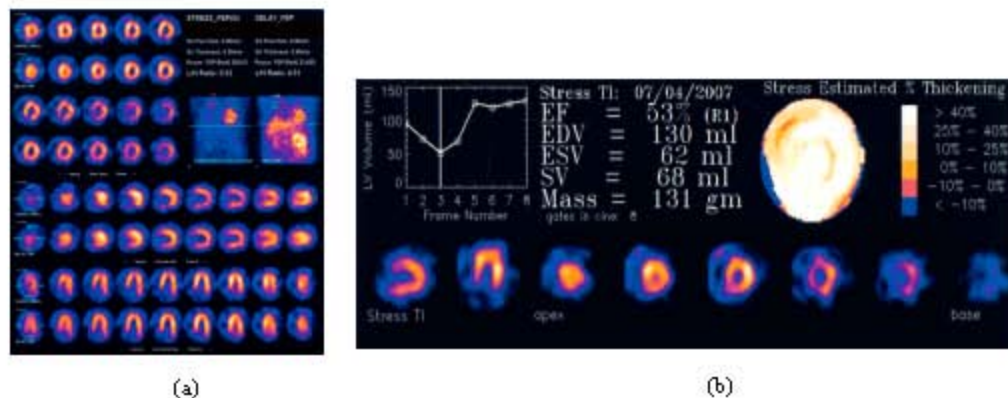


Fig. 8a, b: Small myocardial localized ischemia lower posterior wall of left ventricle

Conclusion: Myocardial ischemia in the postero-lateral wall of left ventricle. Coronarography ed 10-15% obstruction of left circumflex coronary artery with 20% obstruction of Right coronary artery (Fig. 9a, b).

Case 10: Female patient 61 years old, diabetic, hypertension, dyspnea and chest pains. Cardiovascular risks factors: diabetic, hypertension, smoking hypercholesterolemia. Effort test by ergometric bicycle stop for fatigue. Positive ECG. Stress acquisition images synchronized with ECG. Perfusion: Apical hypofixation. Function: Normal EF of left vertical 72%, ESV = 27 mL, EDV = 97 mL. Persistent dilated left ventricular cavity.

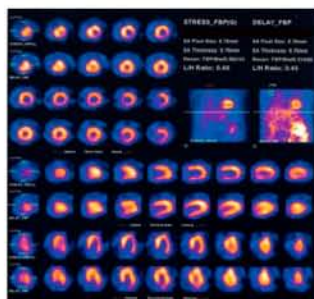
Rest images acquisition 4 h later with synchronization with ECG. Perfusion: Persistence of localized apical hypofixation. Function: EF of left vertical 80%, ESV = 22 mL, EDV = 111 mL. The values of EF of left ventricle in both stress and rest are over estimated due to small sized heart.

Conclusion: Localized stable apical hypofixation in both stress and rest are due to dense hypertrophied breast which attenuate γ -rays. The presence of indirect signs dilated left ventricular cavity associated with positive

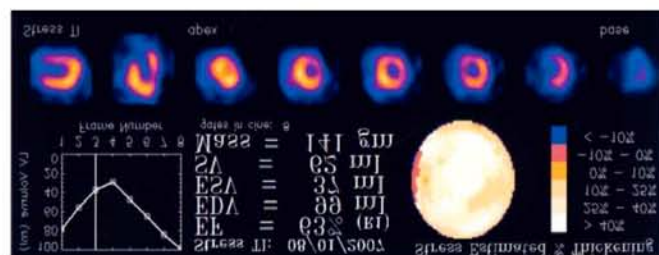
clinical and electrical test orient to obstruction of more than one coronary artery. Coronarography found diffuse obstruction by atheromatous plaques in right coronary and circumflex anterior (Fig. 10a, b).

Case 11: Male patient of 67 years old complaining of cardiopathography since many years with recent aggravation. Cardio-vascular risk: cardiomyopathic, hypertension, dyslipidemia. Persantine test 0.56 mg kg⁻¹ intravenous injection, drop of blood pressure.

Stress images acquisition with synchronization with ECG. Perfusion: Apico-infero-septal hypofixation. Homogeneous perfusion in the anterior and lateral walls of left ventricle. Function: Deteriorated ejection fraction of left ventricle with increased volume. EF: 24%, ESV = 350 mL EDV = 458 mL. Pulmonary stasis: Very dilated left ventricular cavity rest acquisition images 4 h later with synchronization with ECG. Perfusion: Little amelioration of perfusion in posterior part of lower wall persistence of hypofixation in Apico. Inferio-spetal walls of left ventricle. Function: Persistence of deteriorated left ventricular EF 22% with big volumes ESV 369 mL; EDV 425 mL.

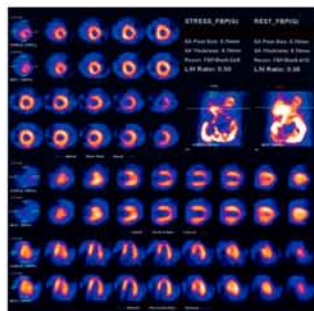


(a)

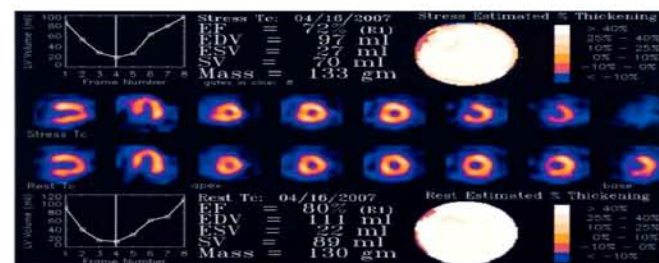


(b)

Fig. 9a, b: Myocardial ischemia in the postero-lateral wall of left ventricle



(a)



(b)

Fig. 10a, b: Presence of indirect signs of dilated left ventricle

Conclusion: Hypertrophic cardiomyopathy associated with ischemia and pulmonary stasis with dilated left ventricular cavity. All this signs contribute to an obstruction of more than one coronary artery. Coronarography confirms obstruction of right coronary. Anterior inter ventricular artery (Fig. 11 a, b).

Case 12: Male patient of 60 years old hospitalized for pain in chest indicated to the lower mandible associated with dyspnea. Cardiovascular risks: Hypertension, smoking, diabetic obesity. Effort test with ergometric bicycle stop for faint. Stress acquisition images synchronized with ECG: Perfusion: lacunar infero lateral hypofixation of wall of left ventricle. Function: EF 67%, ESV = 27 mL, EDV = 83 mL. No pulmonary stasis. Transitory dilatation of left ventricular cavity.

Rest images acquisition 4 h later with synchronization with ECG. Perfusion: Normalization of perfusion in the infero-lateral wall of left ventricle. Function: EF 65%, ESV = 35 mL, EDV = 100 mL.

Conclusion: Myocardial ischemia of infero-lateral wall of left ventricle. Coronarography: Obstruction of right coronary artery and left circumflex artery (Fig. 12 a, b).

Case 13: Male patient of 69 years old complaining of dyspnea with effort. Cardiovascular risks: Age, obesity, Hypertension, effort test by ergometric bicycle stopped for fatigue stress acquisition images synchronized with ECG. Perfusion: anteroseptal hypofixation of the wall of left ventricle. Function: Normal EF of left ventricle 65% with normal volumes, ESV = 33 mL, EDV = 95 mL absence of pulmonary stasis. Absence of dilatation of left ventricular cavity.

Rest acquisition images 4 h later with synchronization with ECG. Perfusion: Normalization of perfusion in anterior septal wall of left ventricle. Function: Normal left ventricular ejection EF 79% and normal ESV = 18 mL and EDV = 84 mL.

Conclusion: Myocardial Ischemia in antero-septal wall coronarography ed obstruction in anterior interventricular artery (Fig. 13 a, b).

Case 14: A male patient of 49 years old complaining of pain in chest irradiated to left shoulder. Cardiovascular risks: Diabetes, hypertension, hyperlipidemia, smoking. Effect test with ergometric bicycle. Stress acquisition images synchronized with ECG. Perfusion: Diffuse

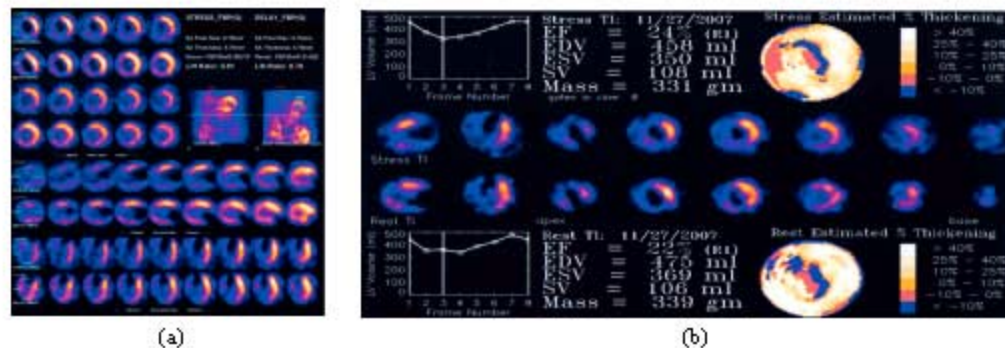


Fig. 11 a, b: Cardiomyopathy associated with ischemia and pulmonary stasis

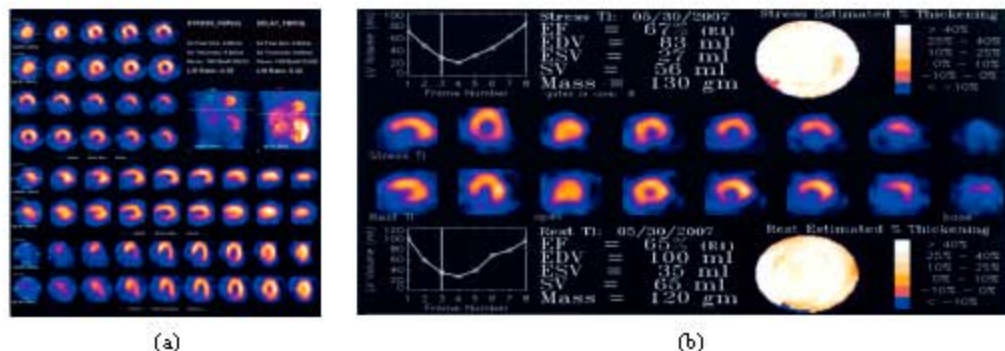


Fig. 12 a, b: Ischemia of infero-lateral wall of left ventricle

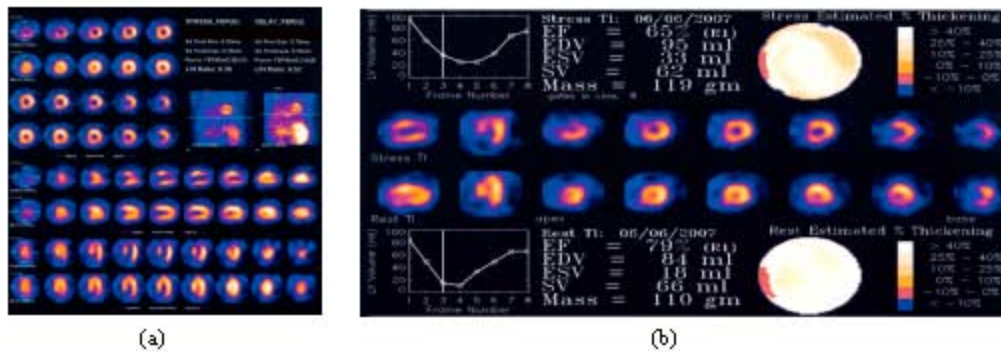


Fig. 13a, b: Myocardial ischemia of antero-septal wall

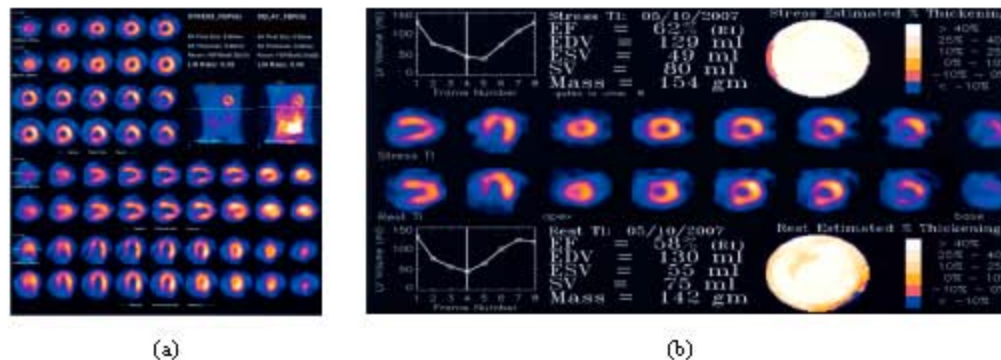


Fig. 14a, b: Ischemia of myocardium without localized perfusion

heterogeneous fixation of all walls of left ventricle. Function: EF of left ventricle 62%, ESV = 49 mL and EDV = 199 mL.

Absence of pulmonary stasis dilated left ventricular cavity rest images acquisition 4 h later with synchronization with ECG. Perfusion: Homogeneous fixation in all walls of left ventricle. Function: Normal EF 58%, ESV = 55 mL, EDV = 130 mL.

Conclusion: Stress heterogeneous fixation of myocardium without localized perfusion defect not significant to retain the diagnosis of ischemia. This patient must be followed up with control by coronarography if pain is present. (Fig. 14a, b).

CONCLUSION

It is postulated from the results of each scintigraphy that obstructive sleep apnea causes an overgrowth of the heart's left ventricle which impairs the heart's pumping action during sleep causing heart failure. Obstructive sleep apnea is linked with erectile dysfunction, more studies on male hormone levels are under investigation.

ACKNOWLEDGMENTS

The authors thank Professor Doctor P. Jallé and Professor Doctor J.J. Lejeune for facilities provided and research grant at CHU Angers Université Angers France.

REFERENCES

- Azevedo, E.R., T. Kubo and S. Mak *et al.*, 2001. Nonselective versus selective beta-adrenergic receptor blockade in congestive heart failure: Differential effects on sympathetic activity. *Circulation*, 104: 2194-2199.
- Chobanian, A.V., G.L. Bakris and H.R. Black *et al.*, 2003. National heart, lung and blood institute joint national committee on prevention, detection, evaluation and treatment of high blood pressure; national high blood pressure education program coordinating committee. The 7th report of the joint national committee on prevention, detection, evaluation and treatment of high blood pressure: The JNC 7 report. *J. Am. Med. Assoc.*, 289: 2560-2572.

- Francis, G.S. and W.H. Tang, 2003. Pathophysiology of congestive heart failure. *Rev. Cardiovasc. Med.*, 4: S14-S20.
- Gami, A.S. and V.K. Somers, 2004. Obstructive sleep apnoea, metabolic syndrome and cardiovascular outcomes. *Eur. Heart. J.*, 25: 709-711.
- Hussain, N. and B. Karnath, 2004. Mechanisms and treatment of obstructive sleep apnea. *J. Am. Med. Assoc.*, 291: 557-558.
- Kiely, J.L., P. Deegan, A. Buckley, P. Shiels, B. Maurer and W.T. McNicholas, 1998. Efficacy of nasal continuous positive airway pressure therapy in chronic heart failure: Importance of underlying cardiac rhythm. *Thorax*, 53: 957-962.
- Kuniyoshi, F.H. and V.K. Somers, 2006. Sleep apnea in hypertension: When, how and why should we treat? *Hypertension*, 47: 818-819.
- Olson, L.J. and V.K. Somers, 2006. Modulation of cardiovascular risk factors by obstructive sleep apnea. *Chest*, 129: 218-220.
- Shamsuzzaman, A.S., B.J. Gersh and V.K. Somers, 2003. Obstructive sleep apnea: Implications for cardiac and vascular disease. *J. Am. Med. Assoc.*, 290: 1906-1914.
- Usui, K., T.D. Bradley, J. Spaak, C.M. Ryan, T. Kubo, Y. Kaneko and J.S. Floras, 2005. Inhibition of awake sympathetic nerve activity of heart failure patients with obstructive sleep apnea by nocturnal continuous positive airway pressure. *J. Am. Coll. Cardiol.*, 45: 2008-2011.
- Young, T., P.E. Peppard and D.J. Gottlieb, 2002. Epidemiology of obstructive sleep apnea: A population health perspective. *Am. J. Respir. Crit. Care. Med.*, 165: 1217-1239.