



Journal of Medical Sciences

ISSN 1682-4474

science
alert

ANSI*net*
an open access publisher
<http://ansinet.com>

Case Report

JMS (ISSN 1682-4474) is an International, peer-reviewed scientific journal that publishes original article in experimental & clinical medicine and related disciplines such as molecular biology, biochemistry, genetics, biophysics, bio-and medical technology. JMS is issued six times per year on paper and in electronic format.

For further information about this article or if you need reprints, please contact:

Mohammad Hasan Larizadeh
Department of
Radiation Oncology,
Shafa Hospital,
Shafa Street,
Kerman, Iran

Tel: +98-341-2115810
Fax: +98-341-2115803

J. Med. Sci., 8 (3): 329-331
1st April, 2008

Malignant Fibrous Histiocytoma Arising from Nasal Cavity

¹Mohammad Ali Damghani and ²Mohammad Hasan Larizadeh

The present aim is to report a case of malignant fibrous histiocytoma of the nasal cavity in a 64-year-old woman. This is a rare entity in the head and neck region. The patient referred with nasal obstruction and underwent wide surgical resection with negative margin. He is well with no evidence of disease for 36 months after surgery.

Key words: Soft tissue sarcoma, malignant fibrous histiocytoma, head and neck, radiotherapy

INTRODUCTION

A 64-year old woman presented with a 2 month history of nasal obstruction and one month history of mild nasal bleeding. Physical examination revealed a nontender mass in left nasal cavity with pink to red color and ulceration and crust over its surface. Pressure effect of this mass has been seen externally. Chest x-Ray was normal. Computed tomographic examination demonstrated a soft tissue density in left nasal cavity without bone or cartilage invasion (Fig. 1). Initial clinical diagnosis was pyogenic granuloma. With this diagnosis, mass excision was done under general anesthesia, but pathologic study showed the storiform-pleomorphic type of malignant fibrous histiocytoma (Fig. 2). She underwent re-operation for obtaining safe margins. There has been no evidence of local recurrence or distant metastasis for 36 months following the final surgery.

Soft Tissue Sarcomas (STS) are rare solid tumors accounting for less than 1% of all malignancies and are very unusual in the head and neck region (Pandey *et al.*, 2003). Three percent to 10% of all MFHs occur in the head and neck and MFH constitutes approximately 5% of head and neck sarcomas (Leon and Amal, 1988; Philip *et al.*, 2003). In a patients group reported by Sabesan and his colleagues, nasal cavity accounted for 3 of 54 MFH (6%), arisen from head and neck region (Sabesan *et al.*, 2006). In another series, ethmoid sinus and nasal cavity accounted for 1 of 12 MFH, arisen from head and neck (Leon and Amal, 1988). Another report mentioned that 3 out of 22 cases (13.6%) of STS of the head and neck were MFH. However, none of the reported cases occurred in nasal cavity (Pandey *et al.*, 2003). For patient with resectable STS, wide local excision with optimal margins of normal tissue represents the primary modality of treatment (Philip *et al.*, 2003; Nicolas *et al.*, 2004). In most sarcomas involving the nose, the surgical procedures employed do not significantly differ from those used for other malignancies of this region. Rhinectomy with palatectomy and possibly maxillectomy/ethmoidectomy may be required for obtaining wide margin (Philip *et al.*, 2003). Unlike extremity sarcomas, head and neck sarcomas usually are not amenable to wide resection with generous margins. The use of adjuvant radiation is more liberal in this site. Post-operative radiotherapy may be used in the following conditions: high-grade lesions and/or positive surgical margins, lesions larger than 5 cm and recurrent lesions (Philip *et al.*, 2003). Little is known about prognostic factors and treatment results of MFHs of the head and neck (Nicolas *et al.*, 2004). Literature data shows that 20 to 42% of individuals with MFHs of the head and neck

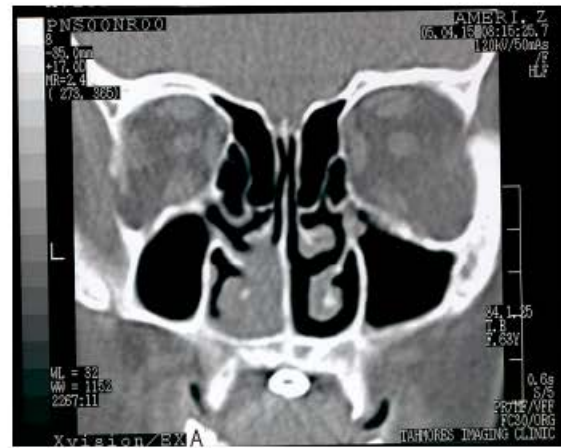

Fig. 1: Preoperative coronal CT Scan showing nasal cavity mass

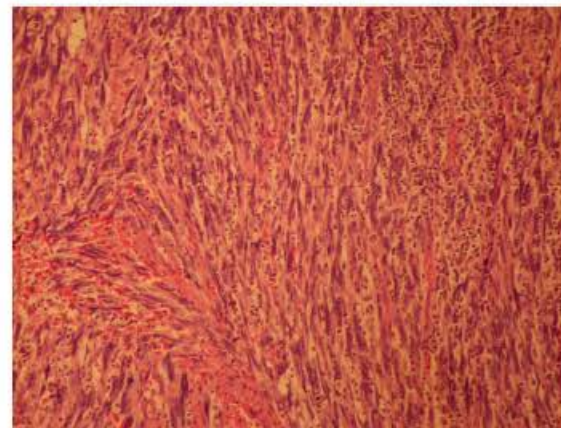


Fig. 2: MFH, plump and spindle cells arranged in short fascicles in storiform pattern around small vessels. (HandE, x100)

will experience local recurrence due to difficulties to obtain wide resection. At least 25 to 35% of these patients will develop systemic metastases, most often to the lung. The overall 5-year survival has been reported to be between 25 and 60% (Leon and Amal, 1988; Sabesan *et al.*, 2006). We did not use adjuvant treatment in this case and she is alive with no evidence of recurrence after 36 months from the last surgery.

REFERENCES

- Leon, B. and K. Amal, 1988. Malignant fibrous histiocytoma of the head and Neck: A report of 12 cases. Arch. Otolaryngol. Head Neck Surg., 114 (10): 1149-1156.

- Nicolas, P., V.H. Christophe, L. Eric, V. Marie-Odile, T.V. Jean, M. Yann and L. Jean-Louis, 2004. Head and neck soft tissue sarcomas of adult: Prognostic value of surgery in multimodal therapeutic approach. *Oral. Oncol.*, 40 (90): 890-897.
- Pandey, M., K. Chandramohan, G. Thomas, A. Mathew, E.K. Abraham, K. Somanathan, E.M. Iype, I.M. Ahamed, P. Sebastian and M.K. Nair, 2003. Soft tissue sarcoma of the head and neck region in adults. *Int. J. Oral. Surg.*, 32 (1): 43-48.
- Philip, K., F. Alfio, J. Patrick, R. Ashok and R. Alessandra, 2003. Management of sarcomas of the head and neck in adults. *Oral. Oncol.*, 39 (1): 2-12.
- Sabesan, T., W. Xuexi, Q. Yongfa, T. Pingzhang and V. Ilankovan, 2006. Malignant fibrous histiocytoma: Outcome of tumours in the head and neck compared with those in the trunk and extremities. *Br. J. Oral. Maxillofac. Surg.*, 44 (3): 209-212.