



Journal of Medical Sciences

ISSN 1682-4474

science
alert

ANSI*net*
an open access publisher
<http://ansinet.com>

JMS (ISSN 1682-4474) is an International, peer-reviewed scientific journal that publishes original article in experimental & clinical medicine and related disciplines such as molecular biology, biochemistry, genetics, biophysics, bio-and medical technology. JMS is issued eight times per year on paper and in electronic format.

For further information about this article or if you need reprints, please contact:

G. Ansari
Department of Paedodontics,
Dental School,
Shahid Beheshti University M.C.,
Tehran, Iran

Tel: 0098 21 22 666 174,
0098 912 1582527
Fax: 0098 21 222 555 37,
0098 21 22 666 330

Assessing Periodontal Status of Patients with Active Caries or Faulty Restorations

¹G.A. Gholami, ²A. Ghassemi, ¹H. Gholami, ¹G.A. Rad and ³G. Ansari

The aim of this study was to compare clinical as well as radiographic status of periodontal tissue of carious or badly restored teeth in comparison to healthy adjacent ones. A group of 50 individuals aged 20-50 years were selected from those referred to periodontics department at Shahid Beheshti Medical University for their periodontal complications including bleeding and recession. Clinical and radiographic examinations were performed on cases including Bleeding on Probing (BOP) pocket depth, attachment and bone loss level. All posterior teeth were looked at for presence of caries or faulty restorations. Similar number of cases were also assessed from the adjacent sound teeth as control. Collected data were then analyzed using χ^2 -test. There was a significant association between the presences of defective restoration and periodontal disease. A similar finding was corresponded to the presence of active carious lesion. This change of the periodontal tissue status was not observed on the sound adjacent teeth. Comparing the different groups for their power of difference, the sound and either carious or faulty restored teeth showed no significant difference between periodontal status of carious and restored teeth ($p < 0.05$). Results of this investigation revealed that faulty restored and carious teeth could develop periodontal disease through out time and any delay in treating such cases would further complicate the case.

Key words: Defective, faulty, restoration, carious lesion, periodontal disease

INTRODUCTION

Dental plaque is known to be the prime factor in causing chronic gingivitis and help in progression towards more severe periodontal disease (Silness, 1964). It is therefore, logical to believe that local factors responsible for plaque aggregation have an important role in the pathogenesis of periodontal disease. Several local causes including the faulty margins of defective restorations could directly influence the reduction of gingival support for the teeth (Finkelman, 1997). There are many reports on the close relationship between over hanged restorations and the development of periodontal disease. This has even gone further with the involvement of periodontium at the sound adjacent teeth (Schoeder and Attstrom, 1979). Untreated and unattended carious teeth have also been shown to be associated with the plaque accumulation at the site, predisposing the development of periodontal disease (Listgarten, 1986). Surprisingly, it is widely believed that the progression of the periodontal disease in such cases is very slim with long term presence of the disease at the same level (Schoeder and Attstrom, 1979). Bransvold and Lane (1990) found that over hanged margin in faulty restorations could change the pathogenic status of the subgingival microflora. In the other hand, Eid (1986) stated that over hanged amalgam restorations are responsible for plaque accumulation and in turn periodontal problem. It was argued that this could be the case regardless of the type of restoration material used with the presence of overhang (Eid, 1986; Hakkarainen and Ainamo, 1980). According to Elter *et al.* (1999) carious lesion would reduce the level of gingival adhesion to the tooth substance dramatically. These will in turn, cause attachment loss at the involved sites (Elter *et al.*, 1999). Albandar (1990), Bjorn *et al.* (1969), Gaudie (1995) and Pack *et al.* (1990) have reported that there is a clear relationship between the presence of untreated progressive carious lesion, fault restoration or over hangs with the level of reduction in gingival support around the involved teeth. The aim of this study was therefore, to assess the level of relation between caries presence and faulty restorations on surrounding periodontal structures in a group of adult Iranians referred to Shahid Beheshti Medical University (SBMU) in 2007.

MATERIALS AND METHODS

This cross sectional investigation was performed on a group of adult individuals selected from cases referred to periodontal department at Shahid Beheshti Medical University (SBMU) during 2006-2008. Patients were

examined clinically and radiographically for the presence of carious lesions at inter proximal areas. In total, 109 teeth in 50 patients with carious cavities or cases with defective restorations were selected during an initial investigation for a further periodontal status. Another 191 adjacent sound teeth were also subjected to the same periodontal assessment for a comparison. Selected cases included both male and female cases of 20-50 years who had complaints on periodontal problems. A wide age range was to eliminate age effect on the outcome due to the age dependency of periodontal disease. Clinical as well as radiographic examination of each case was performed by two independent clinicians who were calibrated for their assessment criteria. Each quadrant was thoroughly assessed for the presence of restoration faults or carious lesions. The degree of caries progress was also recorded in two categories of: early (white spot) to frank cavities. A dental explorer was used to identify any over/under filled restoration at the gingival level in addition to the secondary caries, open contacts, close (tight) contacts and over countered. A periodontal probe was used in conjunction with other instruments to assess the pocket depth, bleeding, attachment and bone loss levels. Bite wing radiographs were obtained from both sides of each patient's dentition to further evaluate the status of the periodontal tissue and the tooth surface condition at the inter-proximal level. Signs of BOP were recorded on prepared forms in addition to the readings from the pocket depths of over 3 mm. Any evidence of gingival recession and attachment loss were also recorded on the same recording sheet. Bone resorption was judged radiographically as present when the level of bone was observed 1 mm below the Cemento-Enamel Junction (CEJ). Periodontal record of all adjacent teeth was recorded for control and comparison. Collected data was analyzed using basic statistics and a further comparison between groups were made using χ^2 test (Bransvold and Lane, 1990).

RESULTS

Initial findings of this investigation revealed that 98% of teeth with faulty restorations represented some degrees of periodontal problem. This values was at 96% for cases with caries. This high percentage of involvement stands in the 95% confidence intervals indicating a direct relationship between the defect and associated periodontal disease. From the total 109 teeth with carious cavities, only two showed no sign of periodontal problem (1.74%). Overall 98.2% represented with Bleeding on Probing (BOP), 63.3% periodontal pocket, 68.8% attachment loss and 38.5% showed signs of bone

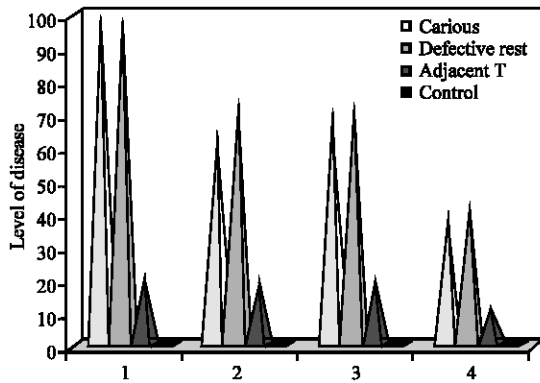


Fig. 1: Shows the level of different periodontal problems in presence of caries and overhanged restoration. 1: BOP, 2: PD, 3: AL, 4: BL

resorption. Thirty nine of the 191 adjacent teeth investigated had also revealed signs of periodontal problems (20.4%). The rate of BOP on these neighboring teeth was 20.4%, with 18.8% pocket development, 19.6% attachment loss and 12.6% bone resorption to varying degrees (Fig. 1).

Chi square test did not show any significant difference between the two groups of carious and badly restored teeth when the periodontal changes were compared ($p > 0.05$). This difference was however, significant when bone resorption was assessed, with faulty restored teeth having a 20% higher incidence of the problem (OR = 1.2). There was a clear difference between the two levels of BOP in carious and healthy adjacent teeth ($p < 0.05$). Same results were observed when teeth with faulty restoration were compared in their overall gingival status to that of healthy adjacent ones ($p < 0.05$).

DISCUSSION

Based on the current data in the literature, it seems that there are still concerns over the exact influence of carious lesions and faulty restorations on the development of periodontal disease. Findings of this investigation has illustrated an association between various periodontal problems and the presence of caries and faulty restorations on teeth. These result also revealed that cases with dental caries clearly developed more periodontal complications than that of the sound adjacent teeth. This was confirmed by χ^2 -test which appeared to have a significant difference between groups ($p < 0.05$). However, inter groups test did not show any significant difference ($p > 0.05$). A higher rate of 20% for bone loss was noted on badly restored teeth in comparison to their adjacent teeth. It is emphasized that

due to the nature of the periodontal disease as being multi factorial in origin, the presence of plaque alone could not cause a reduced periodontal support for the teeth. However, predisposing factors such as dental caries and faulty restoration bulges are proved to predominantly provide the ground for the disease. Plaque accumulation can be accelerated by the defects and overhangs leading to onset of periodontal disease (Jansson, 2006; Albandar *et al.*, 1995; Sheets, 1999). This is in agreement to the findings of the current investigation. The presence of any level of overhang filling could influence the sub gingival normal micro flora to a viable harm full flora (Bransvold and Lane, 1990; Rodriguez-Ferrer *et al.*, 1980). The chemical compositions of the filling materials are believed to have an extra adverse effect on periodontium with a further influence by its surface roughness and faulty shape (Rodriguez-Ferrer *et al.*, 1980; Lang *et al.*, 1983; Page, 1986; Corbat and Davis, 1993). Full crown restorative margins are also believed to be responsible for the development of periodontal disease (Lang *et al.*, 1983; Sorensen *et al.*, 1986). Earlier studies of the same field have indicated rates of 41-62% association of the overhanged restorations with periodontal disease (Pack *et al.*, 1990; Albandar *et al.*, 1995) close to the values shown in Fig. 1.

CONCLUSION

It seems that both carious and restorative defects have direct links to the level of BOP, attachment loss, pocket formation and bone loss to a considerable level. Caries however, had a lower influence than faulty restorations.

REFERENCES

- Albandar, J.M., 1990. Some predictors of Radiographic alveolar bone height reduction over 6 years. *J. Periodontal. Res.*, 25: 186-192.
- Albandar, J.M., Y.A. Buischi and P. Axelsson, 1995. Carious lesions and dental restorations as predisposing factors in the progression of periodontal disease in adolescents. A 3 year longitudinal study. *J. Periodontol.*, 66: 249-254.
- Bjorn, A.L., H. Bjorn and B. Grokovic, 1969. Marginal fit of restorations and its relation to periodontal bone level I: Metal filling. *Odontol. Revy*, 20: 311-321.
- Bransvold, M.A. and J.J. Lane, 1990. The prevalence of overhanging dental restorations and their relationship to periodontal disease. *J. Clin. Periodontol.*, 17: 67-72.
- Corbat, E.F. and W.I.R. Davis, 1993. The role of *Supragingival plaque* in control of progressive periodontal disease. *J. Clin. Periodontol.*, 20: 307-311.

- Eid, M., 1986. Relationship between overhanging Amalgam restorations and periodontal disease. *Odontostomatol. Trop.*, 9: 220-225.
- Elter, J.R., J.D. Beck, G.D. Slade and S. Offenbacher, 1999. Etiologic models for incident periodontal attachment loss in older adults. *J. Clin. Periodontol.*, 26: 113-123.
- Finkelman, R.D., 1997. Prevalence of periodontal disease. *J. Periodontol.*, 68: 804-804.
- Gaudie, W.M., 1995. Pathogenesis of periodontal disease. Over hanging margins of dental restorations. *J. N. Z. Soc. Periodontol.*, 60: 6-7.
- Hakkarainen, K. and J. Ainamo, 1980. Influence of overhanging posterior tooth restorations on alveolar bone height in adults. *J. Clin. Periodontol.*, 7: 114-120.
- Jansson, H., 2006. Studies on periodontitis and analysis of individuals at risk for periodontal diseases. *Sweden Dent. J. Suppl.*, 2006: 5-49.
- Lang, N.P., R.A. Kiel and K. Anderhalden, 1983. Clinical and microbiological effects of Subgingival restorations with over hanging or clinically perfect margins. *J. Clin. Periodontol.*, 10: 563-578.
- Listgarten, M.A., 1986. Pathogenesis of *Periodontitis*. *J. Clin. Periodontol.*, 13: 418-425.
- Pack, A.R., L.J. Coxhead and B.W. McDonald, 1990. The prevalence of over hanging margins in Posterior amalgam restorations and periodontal consequences. *J. Clin. Periodontol.*, 17: 153-158.
- Page, R.C., 1986. Current understanding of the aetiology and progression of periodontal disease. *Int. Dent. J.*, 36: 153-161.
- Rodriguez-Ferrer, H.J., J.D. Strahan and H.N. Newman, 1980. Effect of gingival health of removing overhanging margins of Interproximal subgingival amalgam restorations. *J. Clin. Periodontol.*, 7: 457-462.
- Schoeder, H.E. and R. Attstrom, 1979. Effect of mechanical plaque control on development of subgingival plaque and initial gingivitis in neutropenic dogs. *Scandinavia J. Dent. Res.*, 87: 279-287.
- Sheets, C.G., 1999. The periodontal restorative interface: Enhancement through magnification. *Pract. Periodontic Aesthetic Dent.*, 11: 925-931.
- Silness, J.L.H., 1964. Periodontal disease in pregnancy (II). Correlation between oral hygiene and periodontal condition. *Acta Odontologica Scandinavia*, 22: 21-35.
- Sorensen, S.E., I.B. Larsen and K.D. Jorgensen, 1986. Gingival and alveolar bone reaction to marginal fit of Subgingival crown margins. *Scandinavia J. Dent. Res.*, 94: 109-114.