



Journal of Medical Sciences

ISSN 1682-4474

science
alert

ANSI*net*
an open access publisher
<http://ansinet.com>

JMS (ISSN 1682-4474) is an International, peer-reviewed scientific journal that publishes original article in experimental & clinical medicine and related disciplines such as molecular biology, biochemistry, genetics, biophysics, bio-and medical technology. JMS is issued eight times per year on paper and in electronic format.

For further information about this article or if you need reprints, please contact:

R.K. Sharma
Reproductive Physiology
Laboratory,
Department of Zoology,
Kurukshetra University,
Kurukshetra-136119, India

Antioxidant (Ascorbic Acid): An Approach to Ameliorate the Atrazine Induced Testicular Toxicity

R.K. Sharma, A. Fulia and P.K. Chauhan

The aim of the present study was to investigate the ameliorating effect of vitamin C on atrazine induced testicular toxicity in *Capra hircus* *in vitro*. Small pieces (approximately 1 mm³) of testicular tissue were divided into three groups (One control and two experimental groups). One experimental group was supplemented with 100 nmol mL⁻¹ atrazine concentrations and another experimental group was treated with 100 nmol mL⁻¹ atrazine and simultaneously supplemented with 1000 µmol L⁻¹ concentration of vitamin C (Ascorbic acid). Controls were run simultaneously along with all the experimental groups. Harvesting of tissue was carried out after 1, 4 and 8 h of exposure. In the experimental group treated with atrazine at dose level 100 nmol mL⁻¹, several alterations were observed in the seminiferous tubule. After 1 h of exposure duration there was degeneration in germ cells and somatic cells. Pycnotic nuclei which stained darkly with the eosin were clearly observed after 1 h of exposure duration. The numbers of atretic spermatogonia were increased from 24% in control group to 60% after 1 h, from 30 to 66% after 4 h and from 36 to 76% after 8 h of exposure duration. Similar atretogenic changes were also observed in the testicular slices cultured in atrazine+ vitamin C but were milder as compared to atrazine treatment exclusively. Reduction in atretic spermatogonia was recorded from 60 to 32% after 1 h, from 66 to 42% after 4 h and from 76 to 50% after 8 h of supplementation of vitamin C.

Key words: Antioxidant, ascorbic acid, atrazine, testis, histomorphology, *Capra hircus*

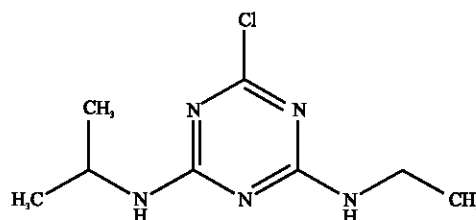
INTRODUCTION

Synthetic chemicals are the quickest and surest method of pest control in agriculture. Excessive use of these pesticides has resulted in serious ecological and environmental problems as well as the health hazards (Toppari *et al.*, 1996; Abdollahi *et al.*, 1997; Olea and Fernandez, 2007). In recent years, there have been growing concerns about the toxicity of a number of pesticides on the reproductive system. There are pronounced structural defects in histological examinations of ovarian tissues in rats which were administered endosulphan and malathion (Koc *et al.*, 2009). Vinclozolin, DDT (De Jager *et al.*, 2006; Turusov *et al.*, 2002; Wade *et al.*, 2002) and its metabolites, methoxychlor, permethrin and phthalates (Mylchreest *et al.*, 2002; Zhang *et al.*, 2007) interfere with androgen production and functioning resulting in serious impairment of male performance. Endosulphan induced alterations in male fertility. Endosulphan exposure resulted in degenerative changes in fine morphology of goat spermatogonia (Sharma *et al.*, 2010). Chlorpyrifos (CPF) is a widely used organophosphate insecticide having known properties of cholinesterase inhibition and the production of Reactive Oxygen Species (ROS) (Getter *et al.*, 2008). Pesticides may induce oxidative stress leading to generation of free radicals and impede the natural antioxidant or oxygen free radical scavenging enzyme system. Pesticides have been established to disturb the pro-oxidant-anti-oxidant system of the cells, thereby leading to generation of oxygen free radical and Reactive Oxygen Species (ROS) (El-Gendy *et al.*, 2010). Biological complex antioxidant system includes antioxidant enzymes (superoxide dismutase, catalase, glutathione reductase and glutathione transferase) and non-enzymatic antioxidants such as carotenoids, vitamin E, vitamin C and glutathione acting against intracellular oxidative stress (Pierce *et al.*, 2004; Szczepanska *et al.*, 2003; VanLangendonck *et al.*, 2002; Agarwal *et al.*, 2003). Significant interaction takes place between water and lipid-soluble molecules at the membrane-cytosol interface and vitamin C may function *in vivo* to repair the membrane-bound oxidized vitamin E (Chan, 1993). Oral supplementation of vitamin C on various semen parameters in oligospermic, infertile, showed that the mean sperm count, sperm motility and sperms with normal morphology increased significantly after 2 months of vitamin C intake (Akmal *et al.*, 2006). Ascorbic acid also prevents free-radicals-induced DNA damage (Dawson *et al.*, 1990). Atrazine is one of the most widely used agricultural pesticides and recognized to have disrupting effects on the reproductive system of mammals

(Rhind, 2002). Antiandrogenic effects of gestational atrazine exposure on male offspring in Sprague-Dawley rat have been observed (Rosenberg *et al.*, 2008). Atrazine induced atretogenic changes in spermatogenic cells of goat *Capra hircus* has been documented (Sharma and Chauhan, 2009). Keeping in view the effect of atrazine on male fertility, the present study investigates the propensity of atrazine to induce oxidative stress and its possible attenuation by vitamin C in goat testis which is a convenient model to understand the oxidative damage induced by various xenobiotics and provide the ways to prevent the increasing infertility problems due to the hazardous effect of different pesticides used in the agriculture.

MATERIALS AND METHODS

Testis of mature goat (*Capra hircus*) were procured from slaughter houses around Kurukshetra (29°6'N, 76°50'E), Haryana, India. The material was brought to the Reproductive Physiology Laboratory, Department of Zoology, Kurukshetra University Kurukshetra at 4°C in normal saline during year 2009. After decapsulation, the testis was cut into small pieces (approximately 1 mm³) for culture.

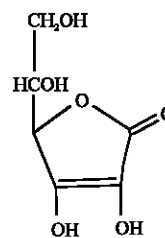


Atrazine (Structure-I)

IUPAC name: 6-chloro-N-ethyl-N'-isopropyl-1,3,5-triazine-2,4-diamine

Chemical formula: C₈H₁₄ClN₅

Molecular mass: 215.7 g mol⁻¹



Ascorbic acid (Structure-II)

Chemical formula: C₆H₈O₆

Molecular mass: 176.13 g mol⁻¹

After washing three times with TCM-199, small pieces of testicular tissue were immediately placed on nucleopore filter and floated on medium. The medium was prepared by mixing TCM-199 and antibiotics (200-unit penicillin 100 IU mL⁻¹ and streptomycin 100 g mL⁻¹). The tissue was divided into three groups (one control group + two experimental groups). Experimental group (A) was supplemented with 100 nmol mL⁻¹ concentration of atrazine (Structure-I) and experimental group (B) was supplemented with 100 nmol mL⁻¹ atrazine and 1000 µmol L⁻¹ concentrations of vitamin C (Ascorbic acid) (Structure-II) and harvesting was carried out after 1, 4 and 8 h of exposure. The culture petri plates were kept at 39°C in 5% CO₂ level in CO₂ incubator for specified duration. Tissue from all the groups was processed for the histomorphological studies. Paraffin embedded tissue from all experimental and control was cut at 5 µm thickness and after dewaxing in xylene, the sections were passed through decreasing grades of alcohol and stained with haematoxyline. After that the sections were gradually dehydrated up to the 70% alcohol and stained with eosin, after further dehydration up to absolute alcohol the sections were cleared with clearing agent (xylene) and finally mounted with DPX (Pearse, 1968).

RESULTS

During the present investigation vitamin C (Ascorbic acid) at 1000 µmol L⁻¹ concentration, induced protective effect against the testicular damage induced by the atrazine at dose level 100 nmol mL⁻¹. Light microscopic examination of 5 µm thin sections of the testicular tissue stained with haematoxyline and eosin of control group revealed normal histological appearance of seminiferous tubules packed with loose connective tissue. Somatic cells and germ cells were arranged in a specific manner, Sertoli cells were present at the basal part of seminiferous epithelium. Sertoli cell nucleus was irregular in shape and cytoplasmic processes were extended in between the germ cells. Different types of germ cells were recognized by their round nucleus. Elongated spermatids were present toward the lumen of the seminiferous tubule (Fig. 1).

In the experimental group (A) treated with atrazine with dose level 100 nmol mL⁻¹, revealed alterations in the seminiferous tubule. After 1 h of exposure duration there was degeneration in both the germ cells and the somatic cells. Darkly stained pycnotic nuclei were clearly observed after 1 h of exposure duration. Vacuoles in the cytoplasm of spermatogonia, spermatid and Sertoli cells were seen. As the exposure duration enhanced from 1 to 4 h, these atretogenic changes were enhanced. Number of pycnotic nuclei was increased. Chromolysis

and fragmentation were also observed after 4 h of exposure durations. Shrinkage in cytoplasm was noticed. Size of vacuoles was also enhanced. Hyalinization in the different germ cells was observed. Some of the germ cells of seminiferous tubules were detached from the basal lamina at certain places. As the exposure duration increased up to 8 h, associations between different germ cells and somatic cells were disrupted to very large extent. Number of pycnotic nuclei, fragmented nuclei, chromolysis, hyalinization and condensation was increased as the exposure duration enhanced (Fig. 1a, b). Atrazine exposure at dose level 100 nmol mL⁻¹ induced an increase in atretic spermatogonia and this increase was further enhanced in time dependent manner. The number of atretic spermatogonia was increased from 24% in control group to 60% after 1 h, from 30 to 66% after 4 h and from 36 to 76% after 8 h of exposure duration. Chi-square values between control and atrazine treated group [experimental group (A)] were analyzed after 1, 4 and 8 h of exposure durations and all the variations recorded were statistically significant (χ^2 0.05) (Table 1).

The number of atretic Sertoli cells after exposure of atrazine was elevated from 18% in control to 58%, from 24 to 62% and 32 to 70% after 1, 4 and 8 h, respectively. Chi-square values between control and atrazine treated group [experimental group (A)] were analyzed after 1, 4 and 8 h of exposure durations and all the variations recorded were statistically significant (χ^2 0.05) (Table 2).

Atrazine induced impairments in testicular structure but supplementation of vitamin C drastically reduced the degenerative changes. Although the atretogenic changes in the seminiferous tubules were also observed in the atrazine treated testicular tissue supplemented with vitamin C [experimental group (B)] but these changes were milder as compared to testicular tissue treated with

Table 1: The comparison of a number of atretic spermatogonia between control versus atrazine (100 nmol mL⁻¹) treated group (A) and atrazine (100 nmol mL⁻¹) treated group (A) versus atrazine supplemented with vitamin C group (B) showing Chi-square values after 1, 4 and 8 h of exposure durations

Parameters	Atrazine	Atrazine + Vitamin C
1 h	13.30*	7.8905*
4 h	12.98*	5.7971*
8 h	17.99*	7.250*

*Statistically significant difference from control ($p \leq 0.05$)

Table 2: Chi-square values between atretic Sertoli cells observed in control versus atrazine (100 nmol mL⁻¹) treated group (A) and atrazine (100 nmol mL⁻¹) treated group (A) versus atrazine supplemented with vitamin C group (B) after 1, 4 and 8 h of exposure durations

Parameters	Atrazine	Atrazine + Vitamin C
1 h	16.97*	9.1799*
4 h	14.728*	6.7627*
8 h	14.44*	10.3059*

*Statistically significant difference from control ($p \leq 0.05$)

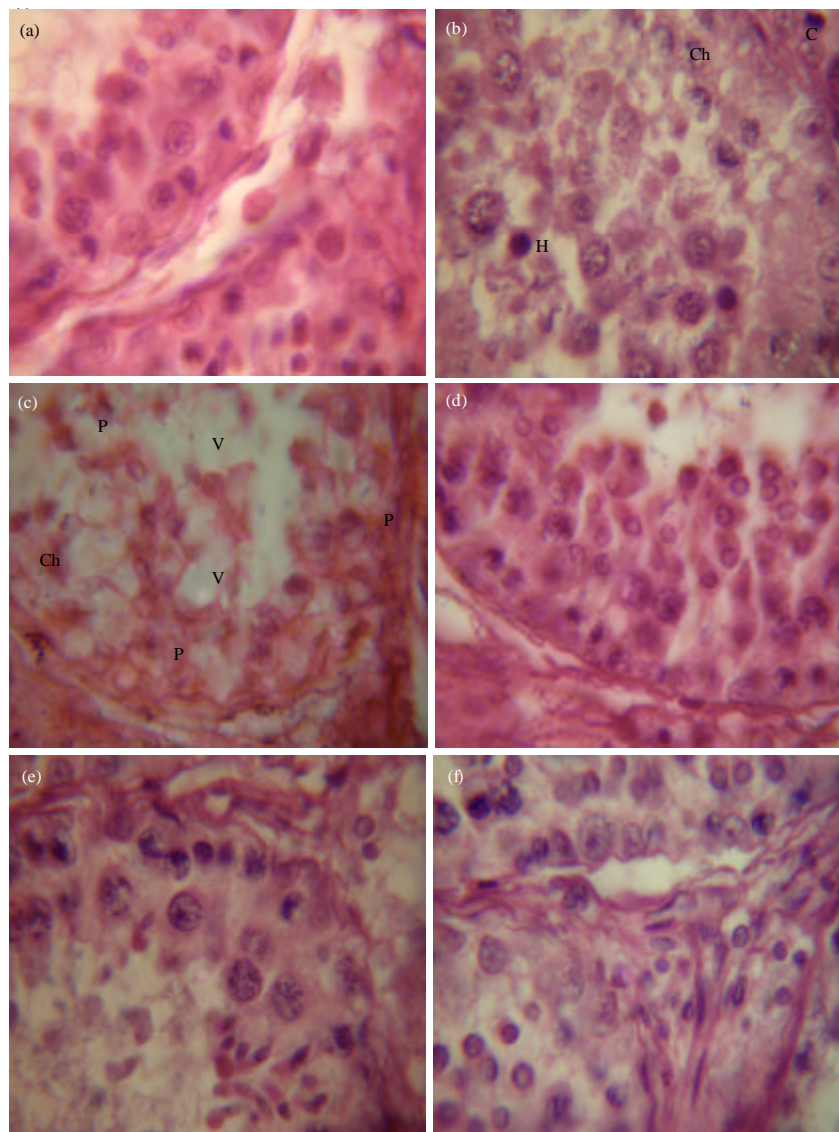


Fig. 1: (a) Microphotograph of testicular tissue of goat *Capra hircus* stained with haematoxyline and eosine showing normal contour in control group. (X 1000), (b) Portion of atrazine (100 nmol mL^{-1}) treated testicular section showing hyalinization (H), condensed nuclei (C), chromolysis (Ch) after exposure duration of 1 h. (X 1000), (c) Testicular section treated with atrazine (100 nmol mL^{-1}) showing increased degeneration of seminiferous tubule. Pycnosis (P) and chromolysis (Ch) were increased. Size of vacuoles (V) was enhanced as the exposure duration was increased to 8 h. (X 1000), (d) Microphotograph of testicular tissue treated with atrazine (100 nmol mL^{-1}) supplemented with vitamin C showing improvement in degeneration of seminiferous tubule after 1 h of exposure duration. (X 1000), (e) Portion of testicular tissue treated with atrazine (100 nmol mL^{-1}) and supplemented with vitamin C for 4 h showing decrease in number of atretic spermatogenic cells and Sertoli cells. (X 1000) and (f) Testicular tissue treated with atrazine (100 nmol mL^{-1}) and supplemented with vitamin C for 8 h showing ameliorating effect on testicular toxicity induced by atrazine. (X 1000)

atrazine only [experimental group (A)]. The degeneration was minimized and most of the testicular portion showed normal architecture of seminiferous tubule and interstitium. There was decline in number of pycnotic

nuclei, fragmented nuclei and chromolysis, condensation in various germ cells and somatic cells in vitamin C supplemented group [experimental group (B)] as compared with the atrazine exposed group [experimental

group (A)] (Fig. 1c-e). There was reduction in atretic spermatogonia and was noticed from 60% in experimental group (A) to 32% in experimental group (B) at 1 h, from 66 to 42% after 4 h and from 76 to 50% after 8 h of supplementation duration and Chi-square values were 7.8905, 5.7971 and 7.250 after 1, 4 and 8 h of exposure durations. All the values recorded were statistically significant (χ^2 0.05) (Table 1). All these atretogenic changes significantly improved by the treatment with vitamin C. A decline in atretic Sertoli cells from 58% in experimental group (A) to 28% in experimental group (A) at 1 h, from 62 to 36% after 4 h and from 70 to 38% after 8 h of supplementation duration and Chi-square values between atrazine treated [experimental group (A)] and atrazine supplemented with vitamin C [experimental group (B)] were 9.1799, 6.7627 and 10.3059 after 1, 4 and 8 h of exposure durations, respectively. Chi-square values revealed that all the variations recorded were statistically significant (χ^2 0.05) (Table 2).

DISCUSSION

During the present investigation, vitamin C (Ascorbic acid) at 1000 $\mu\text{mol L}^{-1}$ concentration induced ameliorating effect against the testicular damage induced by the atrazine at dose level 100 nmol mL^{-1} . The results of the present study strongly supports the earlier studies of Semercioz *et al.* (2003) concerning the effects of increased seminal Reactive Oxygen Species (ROS) and the role of Nitric Oxide (NO) in infertile patients with varicocele and antioxidants have been used successfully to decrease oxidative stress in testis. The results of the present study showed that there was decline in number of pyknotic nuclei, fragmented nuclei and chromolysis, condensation in various germ cells and somatic cells in vitamin C supplemented group [experimental group (B)] as compared with the atrazine exposed group [experimental group (A)]. These results are in agreement with the findings of Hughes *et al.* (1998), who have reported that the supplementation of antioxidants ascorbate, urate and alpha-tocopherol separately has beneficial effects on sperm DNA integrity *in vitro*. The present findings also supports the earlier study of Fraga *et al.* (1991) that antioxidants may play a critical role in protecting male germ cells against oxidative damage. The antioxidant ascorbic acid plays an important role in various physiological processes in the body including detoxification of different toxic materials (Yousef *et al.*, 2005). During the present investigation there was reduction in atretic spermatogonia and was noticed from

60 to 32% at 1 h, from 66 to 42% after 4 h and from 76 to 50% after 8 h of supplementation duration. These results strongly endorse the finding of Wenzel *et al.* (2004), who have reported that ascorbic acid dose-dependently inhibited the apoptotic response of cells. Apoptosis was assessed based on caspase-3-like activity, plasma membrane disintegration and finally nuclear fragmentation and chromatin condensation. Dietary supplementation, particularly antioxidants, such as vitamin C, vitamin E and beta-carotene has the potential to improve the male reproductive outcomes by reducing the extent of oxidative damage (Wong *et al.*, 2000). The observations of the present experiment strongly supports the Bentivoglio *et al.* (1993) who have noticed a consistent improvement in the histological structure of the rat tubular epithelium induced by the supplementation of micronutrient, folic acid, the other anti-oxidative antidotes. The results of present investigation endorse the finding of earlier researchers who observed that zinc administration counteracts the oxidative stress created in the testes by lead exposure (Khan *et al.*, 1991; Batra *et al.*, 1998). The present investigation is in agreement with the observations of (Acharya *et al.*, 2002) who noticed the ameliorating effect of antioxidant vitamin C in Swiss mice testes. Supplementation of vitamin C and E to Cd-treated mice drastically reduced the generation of ROS, thereby significantly escalating sperm count and declining the frequency of abnormal sperm. The study emphasises the possible role of the ROS in inducing sperm abnormality by way of altering specific gene loci in germ cell chromosomes (Acharya *et al.*, 2002).

ACKNOWLEDGMENT

Authors are thankful to Department of Zoology, Kurukshetra University, Kurukshetra for providing all the facilities throughout the study.

REFERENCES

- Abdollahi, M., N. Jalali, O. Sabzevari, R. Hosseini and T. Ghanea, 1997. A retrospective study of poisoning in Tehran. *J. Toxicol. Clin. Toxicol.*, 35: 387-393.
- Acharya, U.R., S.S. Das and M. Mishra, 2002. Role of vitamin C and E on sperm abnormality and sperm count in cadmium treated swiss mice. *Cytologia*, 67: 47-52.
- Agarwal, S., R.A. Saleh and M.A. Bedaiway, 2003. Role of reactive oxygen species in the pathology of human reproduction. *Fertil. Steril.*, 79: 829-843.

- Akmal, M., J.Q. Qadri, N.S. Al-Waili, S. Thangal, A. Haq and K.Y. Saloom, 2006. Improvement in human semen quality after oral supplementation of vitamin C. *J. Med. Food*, 9: 440-442.
- Batra, N., B. Nehru and M.P. Bansal, 1998. The effect of zinc supplementation on the effects of lead on the rat testis. *Reprod. Toxicol.*, 12: 535-540.
- Bentivoglio, G., F. Melica and P. Cristoforoni, 1993. Folinic acid in the treatment of human male infertility. *Fertil. Steril.*, 60: 698-701.
- Chan, A.C., 1993. Partners in defense, vitamin E and vitamin C. *Can. J. Physiol. Pharmacol.*, 71: 725-731.
- Dawson, E.B., W.A. Harris and L.C. Powell, 1990. Relationship between ascorbic acid and male fertility. *World Rev. Nutr. Diet.*, 62: 1-26.
- De Jager, C., P. Farias, A. Barraza-Villarreal, M.H. Avila and P. Ayotte *et al.*, 2006. Reduced seminal parameters associated with environmental DDT exposure and p,p-DDE concentrations in men in Chiapas, Mexico: A cross-sectional study. *J. Androl.*, 27: 16-27.
- El-Gendy, K.S., N.M. Aly, F.H. Mahmoud, A. Kenawy and A.K.H. El-Sebae, 2010. The role of vitamin C as antioxidant in protection of oxidative stress induced by imidacloprid. *Food Chem. Toxicol.*, 48: 215-221.
- Fraga, C.G., P.A. Mmotchnik, M.K. Shigenaga, H.J. Helbeck, R. A. Jacob and B.N. Ames, 1991. Ascorbic acid protects against endogenous oxidative DNA damage in human sperm. *Proc. Natl. Acad. Sci. USA.*, 88: 11003-11006.
- Geter, D.R., H.L. Kan, E.R. Lowe?, D.L. Rick?, G.D. Charles?, B.B. Gollapudi and J.L. Mattsson, 2008. Investigations of oxidative stress, antioxidant response and protein binding in chlorpyrifos exposed rat neuronal PC12 cells. *Toxicol. Mech. Methods*, 18: 17-23.
- Hughes, C.M., S.E. Lewis, V.J. McKelvey-Martin and W. Thompson, 1998. The effects of antioxidant supplementation during Percoll preparation on human sperm DNA integrity. *Hum. Reprod.*, 13: 1240-1247.
- Khan, S., M.A. Khan, D. Bhatnagar, P. Yadav and S. Sarkar, 1991. Zinc protection against lipid peroxidation from cadmium. *Indian J. Exp. Biol.*, 29: 823-825.
- Koc, N.D., F.E. Kayhan, C. Sesal and M.N. Muslu, 2009. Dose-dependent effects of endosulfan and malathion on adult wistar albino rat ovaries. *Pak. J. Biol. Sci.*, 12: 498-503.
- Mylchreest, E., M. Sar, D.G. Wallace and P.M.D. Foster, 2002. Fetal testosterone insufficiency and abnormal proliferation of Leydig cells and gonocytes in rats exposed to di (n-butyl) phthalates. *Reprod. Toxicol.*, 16: 19-28.
- Olea, N. and M.F. Fernandez, 2007. Chemicals in the environment and human male fertility. *Occup. Environ. Med.*, 64: 430-431.
- Pearse, A.G.E., 1968. *Histochemistry: Theoretical and Applied*. Churchill, London.
- Pierce, J.D., A.B. Cackler and M.G. Arnett, 2004. Why should you care about free radicals. *RN*, 67: 38-42.
- Rhind, S.M., 2002. Endocrine disrupting compounds and farm animals: Their properties, actions and routes of exposure. *Domest. Anim. Endocrinol.*, 23: 179-187.
- Rosenberg, B.G., H. Chen, J. Folmer, J. Liu, V. Papadopoulos and B.R. Zirkin, 2008. Gestational exposure to atrazine: Effects on the postnatal development of male offspring. *J. Androl.*, 29: 304-311.
- Semercoz, A., R. Onur, S. Ogras and I. Orhan, 2003. Effects of melatonin on testicular tissue nitric oxide level and antioxidant enzyme activities in experimentally induced left varicocele. *Neuro. Endocrinol. Lett.*, 24: 86-90.
- Sharma, R.K. and P.K. Chauhan, 2009. Atrazine induced changes in histoarchitecture of the goat testis. *Adv. Pharmacol. Toxicol.*, 10: 35-40.
- Sharma, R.K., P.K. Chauhan and A. Fulia, 2010. Endosulphan induced changes in fine morphology of goat spermatogonia *in vitro*. *Res. J. Environ. Toxicol.*, 4: 214-222.
- Szczepanska, M., J. Kozlik, J. Skrzypczak and M. Mikolajczyk, 2003. Oxidative stress may be a piece in the endometriosis puzzle. *Fertil. Steril.*, 79: 1288-1293.
- Toppiari, J., J.C. Larsen, P. Christiansen, A. Giwerman and P. Grandjean *et al.*, 1996. Male reproductive health and environmental xenoestrogens. *Environ. Health Perspect.*, 104: 741-803.
- Turusov, V., V. Rakitsky and L. Tomatis, 2002. Dichlorodiphenyltrichloroethane (DDT): Ubiquity, persistence and risks. *Environ. Health Perspect.*, 110: 125-128.
- Van Langendonck, A., F. Casanas-Roux and J. Donnez, 2002. Oxidative stress and peritoneal endometriosis. *Fertil. Steril.*, 77: 861-870.
- Wade, M.G., S. Parent, K.W. Finnson, W. Foster and E. Younglai *et al.*, 2002. Thyroid toxicity due to subchronic exposure to a complex mixture of 16 organochlorines, lead and cadmium. *Toxicol. Sci.*, 67: 207-218.

- Wenzel, U., A. Nickel, S. Kuntz and H. Daniel, 2004. Ascorbic acid suppresses drug-induced apoptosis in human colon cancer cells by scavenging mitochondrial superoxide anions. *Carcinogenesis*, 25: 703-712.
- Wong, W.Y., C.M. Thomas, J.M. Merkus, G.A. Zielhuis and R.P. Steegers-Theunissen, 2000. Male factor subfertility: Possible causes and the impact of nutritional factors. *Fertil Steril.*, 73: 35-42.
- Yousef, M.I., A.M. El-Morsy and M.S. Hassan, 2005. Aluminium-induced deterioration in reproductive performance and seminal plasma biochemistry of male rabbits: Protective role of ascorbic acid. *Toxicology*, 215: 97-107.
- Zhang, S.Y., Y. Ito, O. Yamanoshita, Y. Yanagiba and M. Kobayashi *et al.*, 2007. Permethrin may disrupt testosterone biosynthesis via mitochondrial membrane damage of leydig cells in adult male mouse. *Endocrinology*, 148: 3941-3949.