



# Journal of Medical Sciences

ISSN 1682-4474

**science**  
alert

**ANSI***net*  
an open access publisher  
<http://ansinet.com>

*JMS (ISSN 1682-4474) is an International, peer-reviewed scientific journal that publishes original article in experimental & clinical medicine and related disciplines such as molecular biology, biochemistry, genetics, biophysics, bio-and medical technology. JMS is issued eight times per year on paper and in electronic format.*

*For further information about this article or if you need reprints, please contact:*

O.T. Salawu,  
Department of Zoology,  
University of Ibadan, Nigeria,  
Tel: +2348163546787

## Variations in the Mandibular Foramina of Yoruba Ethnic Group of Nigeria

<sup>1</sup>S.A. Adejuwon, <sup>1</sup>Femi-Akinlosotu, <sup>1</sup>M. Omowunmi and <sup>2</sup>O.T. Salawu

The identification and actual position of mental foramen is of high significance to the field of clinical dentistry as well as evaluation of the morphology and maturity of human mandible. Several reports have revealed varied positions of mental foramen in different ethnic groups. The aim of this study was to assess the shape and position of mental foramen of human mandibles of known sex. Forty dry human hemimandibles were examined and out of which were 22 male and 18 female mandibles. The most common shape of the foramen was round (65.5%), with most of them also being round shaped both at the left and right sides of the examined jaws. The most common position of the MF as related to the lower set of teeth was in line with the second premolar (61.5%). The positions of MF situated anterior to the second premolar, anterior to the first molar and in line with first premolar were all found to be the least positions (1.3%). The study therefore may provide more detailed information to predict the position and shape of the mental foramen of the selected population.

**Key words:** Mental foramen, shape, position, frequency, yoruba

## INTRODUCTION

The mandibles of human jaws contain small foramen called mental foramen. These foramens are located at the anterolateral region of the mandibles. Sensory innervations and blood supply to the body soft tissues in the chin, lower lip and gingival are as a result of the mental nerve and vessels which emerge through the mental foramen (Simmathamby, 1999; Berry *et al.*, 2000). Its anatomical importance is underscored in periapical surgery in the mental region of mandible. An atypical radiographic appearance of the mental foramen may be mistaken for radiolucent lesion in the apical area of mandibular premolar teeth. Damage incurred in the mental neurovascular bundle during surgical procedures has been implicated in paraesthesia or anesthesia of the chin (Ngeow and Yuzawati, 2003).

The average dimension of mental foramen is 3.4 mm by 4.6 mm on the lateral surface of the mandible (Ngeow and Yuzawati, 2003). Direct measurements on dry mandibles or the use of radiographs are often employed in the study of the position, orientation and size of the foramen. Visual inspection in relations to the first and second premolar teeth is also used to analyze the location of MF (Osunwoke *et al.*, 2012). There have been conflicting reports regarding the positions and shapes of mental foramen (Ngeow and Yuzawati, 2003; Neiva *et al.*, 2004; Ilayperuma *et al.*, 2009).

The shape of the mental foramen in adult black Zimbabwean mandibles has been reported to be round and oval in 34.48 and 65.52% of the population respectively (Mbajjorgu *et al.*, 1998). The positions of mental foramen vary among racial groups and genders (Cutright *et al.*, 2003). The position which is in-line with the longitudinal axis of the 2nd premolar tooth and the location between the 1st and 2nd premolar tooth have always been reported as the most frequent occurring positions of MF (Mbajjorgu *et al.*, 1998).

The mandibles could have more than one mental foramen (Shankland, 1994; Sawyer *et al.*, 1998). The frequency of accessory mental foramina in skulls varies with races. The prevalence 1.4, 1.5, 5.7 and 9.0% were reported among American Whites, Asian Indians, African Americans and pre-Columbian Nazca Indians, respectively (Greenstein and Tarnow, 2006). Two mental foramina have been observed in 1.8% of Asian skulls (Agthong *et al.*, 2005) while no foramina was observed in the 1,435 dry human mandibles examined by De Freitas *et al.* (1979). These therefore suggest that a variety of patterns occurs and it should not be concluded that there is only one mental foramen on each side (Greenstein and Tarnow, 2006).

Despite the significance of mental foramen, little attention has been drawn towards the study of the morphology, most common position of foramen and associated anatomical characteristics in Southwestern Yoruba ethnic group of Nigeria, hence this study has been conducted to investigate the number, shape and position of MF with respect to the surgically encountered anatomical landmarks.

## MATERIALS AND METHODS

**Sources of mandibles:** Forty dried adult human mandibles with complete molar and premolar dentition and intact alveolar margin of known sex from the Department of Anatomy, University of Ibadan, Nigeria, were used for this study. The mandibles were parts of the cadavers sourced from Lagos, Sagamu, Ijebu-ode, Ile-Ife, Ibadan and other cities within Southwest region of Nigeria predominantly inhabited by the Yoruba ethnic group.

**Position of mental foramen in relation to the mandibular teeth:** The shapes of the Mental Foramen (MF) were determined by visual examinations. The position of the MF was measured in relation to the lower jaw teeth. The position of the mental foramen was recorded as lying in line with the long axis of a tooth or interdental space in one of the following relations: (1) anterior to 2nd premolar (Mesial), (2) posterior to 2nd premolar (Distal), (3) anterior to 1st molar (Mesial), (4) in line with 1st premolar, (5) between the 1st and 2nd premolar, (6) between 2nd and 1st molar and (7) In line with 2nd premolar. The position of MF in relation to the mandibular teeth was determined by visual examination.

**Position of mental foramen in relation to the body of the mandible:** The positions of MF were measured on both sides of the mandibles using a vernier caliper. To determine this relation, the mandible was placed on a horizontal surface, to which the lower border of the mandible comes into greatest contact when vertical pressure is applied to the second molar teeth. The position of MF was identified by using the following parameters: (1) Distance from mental foramen to mental symphysis; (2) Distance from mental foramen to alveolar margin and (3) Distance from mental foramen to inferior border of the mandible (Fig. 1).

**Statistical analysis:** Data were entered into an Excel spreadsheet, checked for entry errors and transferred into SPSS for Windows (version 17.0, SPSS Inc, Chicago, USA) for analysis. Percentage evaluation was used to determine the frequency of MF in relation to shapes and

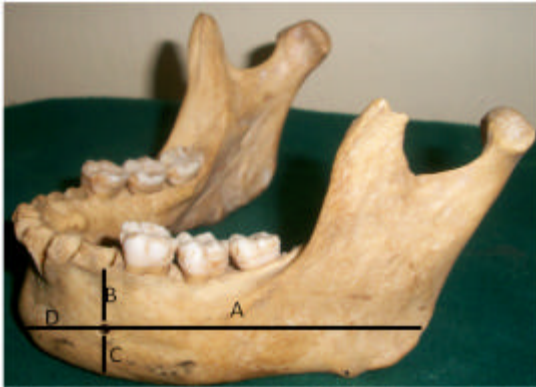


Fig. 1: Measurement of position of MF, A: Distance from mental foramen to posterior border of the ramus, B: Distance from mental foramen to alveolar margin, C: Distance from mental foramen to inferior border of mandible, D: Distance from mental foramen to mental symphysis

positions. Chi square analysis was used to test for significant difference in shape and position of MF in relation to sex. The p-value <0.05 was considered statistically significant.

**RESULTS**

Round shaped MF were more predominant while the most dominant position was the one in which the foramina is in line with the 2nd premolar. The shape of MF was not sex dependent, however, a significant difference occurred in the occurrence of the two shapes.

Of the total number of 80 MF observed in the 40 human hemimandibles used for the study, 44 and 36 MF were observed in the male and female mandibles, respectively. The shape of the foramen was oval in 32.5% and rounded in 65.5% of the dried human hemimandibles as seen in Table 1. Variations in the occurrence of round and oval shaped MF on the left and right sides of the hemimandibles were shown in Fig. 2. The highest frequency of occurrence (60%) was the case where round shaped MF was observed on both sides of the mandible (i.e., RR). The least were those in which the left side of the foramen were oval shaped and right side rounded shaped (OR) and vice versa (RO).

The positions of mental foramen in relation to mandibular teeth on the two sides are shown in Table 2. The most frequent position of foramen in relation to the mandibular teeth was in line with the longitudinal axis of 2nd premolar for both male (64.3%) and female (58.3%) human dried jaws. The second most frequent position was

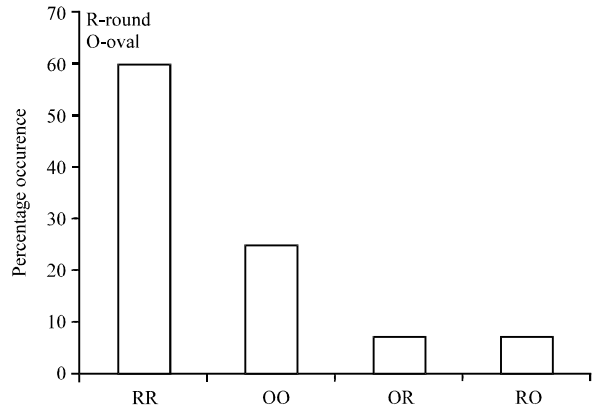


Fig. 2: Variation in shapes in relation to the left and right sides MF

Table 1: Proportion of round and oval shaped MF

Sex	Mental foramina	Round	Oval
Male	Left	15.0	07.0
	Right	16.0	06.0
Female	Left	12.0	06.0
	Right	11.0	07.0
Total		54.0	26.0
Percentage		65.5	32.5

Table 2: Frequency of the position of MF in relation to mandibular teeth between the two sides

Position	Male		Female		Total	
	No.	%	No.	%	No.	%
Anterior to 2nd premolar (mesial)	-	-	1	2.8	1	1.3
Anterior to 1st molar (mesial)	1	2.4	-	-	1	1.3
Posterior to 2nd premolar (distal)	4	9.5	3	8.3	7	9.0
In line with 1st premolar	1	2.4	0	-	1	1.3
Between the 1st and 2nd premolar	3	7.1	0	-	3	3.9
Between 2nd and 1st molar	6	14.3	11	30.6	17	21.8
In line with 2nd premolar	27	64.3	21	58.3	48	61.5
Total	42	100.0	36	100.0	78	100.0

between the 2nd premolar and the 1st molar constituting about 21.8% of the total foramen. The least occurring positions were; MF anterior to the 2nd premolar and molar, then in line with the 1st premolar, all of which have a total occurrence percentage of 1.3% each.

**DISCUSSION**

The present study provides new information on the position of the mental foramen in human dried hemimandibles of Southwestern Yoruba ethnic group of Nigeria. The exact position of the mental foramen is important in diagnosis and clinical procedures involving the mandible. The injury incurred by the mental nerve bundle emerging from the mental foramen during surgical operations could result in paraesthesia and anaesthesia (Phillips *et al.*, 1990).

Most of the readily available standard textbooks on dental analgesia have reported the most frequently found position of the mental foramen to be between the apices of the 1st and 2nd premolar. Since the positions of mental foramen vary in different racial groups, this could not be true for all population. For examples, the most frequently occurring position of the mental foramen among the Chinese was in line with the 2nd premolar (Santini and Land, 1990), while it was more posteriorly located in Blacks than in Whites (Cutright *et al.*, 2003).

In the analysis of 80 dried human hemimandibles used for this study, the most frequent occurring position was in line with the longitudinal axis of the 2nd premolar tooth. This is in consonance with reports in other populations (Ngeow and Yuzawati, 2003; Prabodha and Nanayakkara, 2006; Agarwal and Gupta, 2011). During the early prenatal life, mental foramen is located in the in the alveolar bone between the primary canine and the first molar (Kjaer, 1989), therefore, the position other than the most common ones is speculated to be due to a lag in prenatal development (Agarwal and Gupta, 2011).

Most of the shapes of the mental foramen in this study was round (65.5%). Other reports however, have reported the dominance of oval shaped mental foramen (Mbajjorgu *et al.*, 1998; Prabodha and Nanayakkara, 2006). The reported frequency of occurrence of oval mental foramen in this study (32.5%) varied significantly with other studies.

### CONCLUSION

This study gives information on the positions and shapes of mental foramen of Yoruba ethnic group of Nigeria. The position and shape of MF vary in different regions and this has been attributed to differences in feeding habits which may subsequently affect mandibular development. This therefore provides awareness on the likely morphology of the foramen of the population and thus becomes useful in planning surgery and when viewing the pre-operative radiological examination.

### ACKNOWLEDGMENTS

The authors wish to thank the Department of Human Anatomy, College of Medicine, University of Ibadan, Nigeria, for their kind support in providing cadaveric bone specimens for the study. Also, we wish to thank the Departmental Chief Technologist, Mr. Adeniyi for his help in sourcing the skulls and providing historic information on the samples.

### REFERENCES

- Agarwal, D.R. and S.B. Gupta, 2011. Morphometric analysis of mental foramen in human mandibles of South Gujarat. *People J. Sci. Res.*, 4: 15-18.
- Agthong, S., T. Huanmanop and V. Chentanez, 2005. Anatomical variations of the supraorbital, infraorbital and mental foramina related to gender and side. *J. Oral Maxillofac. Surg.*, 63: 800-804.
- Berry, M.M., L.H. Bannister and S.M. Standring, 2000. Nervous System. In: *Gray's Anatomy-The Anatomical Basis of Medicine and Surgery*, Williams, P.L., L.H. Bannister, M.M. Berry, P. Collins, M. Dyson, J.E. Dussek and M.W.J. Feruson (Eds.). 38th Edn., Churchill Livingstone, New York, pp: 1230-1249.
- Cutright, B., N. Quillopa and W. Schubert, 2003. An anthropometric analysis of the key foramina for Maxillofacial surgery. *J. Oral Maxillofacial Surg.*, 61: 354-357.
- De Freitas, V., M.C. Madeira, J.L.T. Filho and C.F. Chagas, 1979. Absence of the mental foramen in dry human mandibles. *Acta Anat.*, 104: 353-355.
- Greenstein, G. and D. Tarnow, 2006. The mental foramen and nerve: Clinical and anatomical factors related to dental implant placement: A literature review. *J. Periodontol.*, 77: 1933-1943.
- Ilayperuma, I., G. Nanayakkara and N. Palahepitiya, 2009. Morphometric analysis of the mental foramen in adult Sri Lankan mandibles. *Int. J. Morphol.*, 27: 1019-1024.
- Kjaer, I., 1989. Formation and early prenatal location of the human mental foramen. *Scand. J. Dent. Res.*, 97: 1-7.
- Mbajjorgu, E.F., G. Mawera, S.A. Asala and S. Zivanovic, 1998. Position of the mental foramen in adult black Zimbabwean mandibles: A clinical anatomical study. *Cent. Afr. J. Med.*, 44: 24-30.
- Neiva, R.F., R. Gapski and H.L. Wang, 2004. Morphometric analysis of implant-related anatomy in *Caucasian skulls*. *J. Periodontol.*, 75: 1061-1067.
- Ngeow, W.C. and Y. Yuzawati, 2003. The location of the mental foramen in a selected Malay population. *J. Oral Sci.*, 45: 171-175.
- Osunwoke, E., F. Amah-Tariah, M. Sapira and C. Okwuone, 2012. Position, direction and size of the mental foramina of the mandibles of Adult Male Southern Nigerians. *Int. J. Biol. Anthropol.*, Vol. 5.
- Phillips, J.L., R.N. Weller and J.C. Kulild, 1990. The mental foramen: Part 1. size, orientation and positional relationship to the mandibular second premolar. *J. Endodon.*, 16: 221-223.

- Prabodha, L.B.L. and B.G. Nanayakkara, 2006. The position, dimensions and morphological variations of mental foramen in mandibles. *Galle Med. J.*, 11: 13-15.
- Santini, A. and M.A. Land, 1990. Comparison of the position of the mental foramen in Chinese and British mandibles. *Acta Anat.*, 137: 208-212.
- Sawyer, D.R., M.L. Kiely and M.A. Pyle, 1998. The frequency of accessory mental foramina in four ethnic groups. *Arch. Oral Biol.*, 43: 417-420.
- Shankland, W.E. 2nd, 1994. The position of the mental foramen in Asian Indians. *J. Oral Implantol.*, 20: 118-123.
- Sinnathamby, C.S., 1999. *Last's Anatomy: Regional and Applied*. 10th Edn., Churchill Livingstone, Edinburgh, Pages: 506.