



# Journal of Medical Sciences

ISSN 1682-4474

**science**  
alert

**ANSI***net*  
an open access publisher  
<http://ansinet.com>

*JMS (ISSN 1682-4474) is an International, peer-reviewed scientific journal that publishes original article in experimental & clinical medicine and related disciplines such as molecular biology, biochemistry, genetics, biophysics, bio-and medical technology. JMS is issued eight times per year on paper and in electronic format.*

*For further information about this article or if you need reprints, please contact:*

Bram Pradipta  
Department of Obstetrics and Gynecology,  
Faculty of Medicine,  
Syiah Kuala University,  
Banda Aceh, Jakarta, Indonesia

## **Cesarean Myomectomy: A Case Report in Zainoel Abidin General Hospital, Banda Aceh**

<sup>1</sup>Mohd Andalas and <sup>1,2</sup>Bram Pradipta

Uterine myomas are the most common pelvic tumors over the age of 30 and it is now more frequently seen as many women delaying childbearing which is the time for greatest risk of myoma growth. Myomectomy during cesarean section has traditionally been discouraged because of the risk of uncontrollable hemorrhage. But as more knowledge about it is gained throughout times, it can now give different decision regarding it. This is a one case report study in Zainoel Abidin General Hospital in Banda Aceh about cesarean myomectomy. Hopefully, it can improve skill and knowledge of medical staff in making a cesarean myomectomy decision, its complications and its post operative care. The case is about a 32 year old, gravida 3 para 2, Indonesian woman presented with postterm-pregnancy and 20 cm intra mural-uterine myoma. Cesarean myomectomy was done to her with little to none intraoperative hemorrhage. Post C-section we found complications shown by uterine atony, profuse bleeding seen at the drainage through the peritoneum and marked changes in hemoglobin value. It is then carefully evaluated and managed using extensive follow up, high dose oxytocin and blood transfusion. In conclusion, cesarean myomectomy is now considered by many not always as a hazardous procedure and can be performed in experienced hands, in a well equipped tertiary institution, with the advent of better anesthesia, with availability of blood, in selected patients and according to site and size of myomas. It is always important to have a good informed consent beforehand and post operative care of cesarean myomectomy.

**Key words:** Myoma, pregnancy, cesarean-myomectomy, pelvic tumor

## INTRODUCTION

Uterine myomas are the most common pelvic tumors in women over the age of 30, with incidence during pregnancy ranging from 0.5-5% (Breech and Rock, 2003; Depp, 2002). Myomas are now more frequently seen as many women are delaying childbearing which is the time for increased risk of myoma growth. The advancement of ultrasonography has also improved the capability of diagnosing and detecting small myomas hence increased our knowledge of myomas in pregnancy (Anita *et al.*, 2007). With its growth during pregnancy, it gives many complications for pregnancy, labor and the puerperium (Dandade *et al.*, 2003).

It is not common to perform myomectomy during cesarean section due to increased risk of bleeding and the difficulty to stop it (Sudhir and Sebanti, 2006). Practitioners, are against cesarean myomectomy due to high morbidity because of postpartum bleeding (Davi *et al.*, 1990).

It is known that myomectomy during cesarean increases the hemorrhage by about 10% (Anita *et al.*, 2007).

There are still controversies in medical world about cesarean myomectomy, most of them are against it because of the increasing risk of postpartum hemorrhage and post operative morbidity (Roman and Tabsh, 2004). The opposing group opinion is that it is considered easier to enucleate fibroid in the gravid uterus because of the looseness of the fibroid capsule (Kwawukume, 2002). Bleeding can also stop by contractions and retractions of muscle fibers and the onset of vascular changes for clot formation in placental bed. Uterine muscles retraction is supposedly helped by oxytocic agents to achieve hemostasis (Anita *et al.*, 2007). This study has presented a case of an intra mural uterine myoma diagnosed during pregnancy which was successfully managed by cesarean myomectomy.

## CASE PRESENTATION

**History, examination and management:** A 32 year old Indonesian woman, Gravida 3 Para 2 presented to our center with a postterm pregnancy and an intramural myoma. It was diagnosed during pregnancy on the rural hospital and therefore referred to the tertiary level hospital. There were minimal symptoms associated with myomas during the pregnancy. The patient was well-looking but clinically pale. The pulse rate was 80 beats per minute and the blood pressure was 120/80 mm Hg. The respiratory rate was 24 cycles per minute. The abdomen was distended according to gestational age. Abdominal sonography showed an intra-uterine viable singleton fetus of 42 weeks gestation. It also showed a 20×20×15 cm tumor with a thick capsule located at the right superior aspect of the uterus. Blood tests showed normal levels. The patient's blood group was 0 rhesus positive. Cesarean myomectomy was proposed, planned and discussed with the patient. Surgery was performed under general anaesthesia with endotracheal intubation. Operative findings included normal liver, spleen, kidneys, diaphragm, ovaries and fallopian tubes. The uterus was soft and the size was adequate for term pregnancy with palpable myoma in the right superior uterus. With C-section born baby boy 3100 g<sup>-1</sup>, body length 49 cm, APGAR score 9/10. After the sutures on the uterine low segment, we then performed the myomectomy.

An intramural myoma was situated at the right superior aspect of the uterus (Fig. 1). It was removed and the myoma bed was quickly closed with 2-0 polyglactin sutures and hemostasis was easily achieved. The estimated blood loss was 600 mL and 1 units of packed red cells were transfused intra-operatively. The tumor weighing approximately 750 g was sent for histology (Fig. 2). We then put a peritoneum drainage

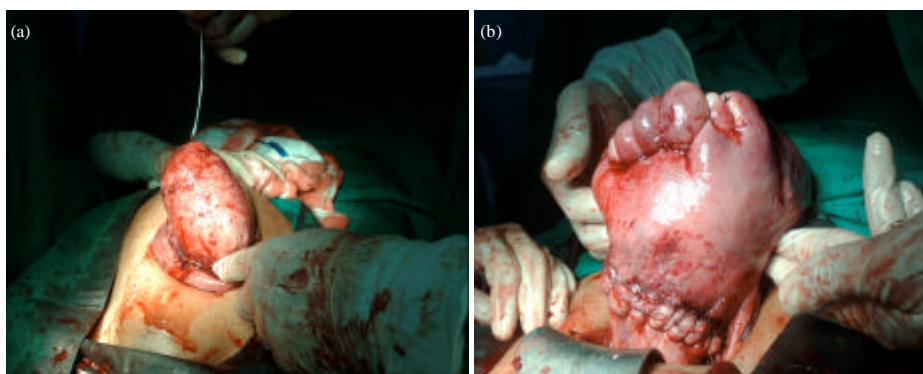


Fig. 1(a-b): Myomectomy after delivery of the baby

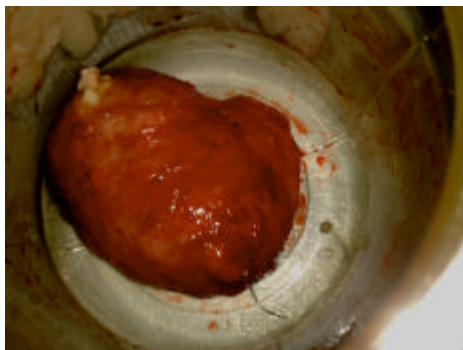

Fig. 2: Intra mural myoma

to evaluate any bleeding. Post operative, we found uterine atony, profuse bleeding at the drainage through the peritoneum and marked changes in hemoglobin value. Then we performed postpartum hemorrhage therapy by using 2 intravenous lines with 20 IU oxytocin on 500 cc ringer lactate and blood transfusion. The atony was then managed and the patient was stable. The post-operative treatment was remarkable and the woman was discharged from the hospital 4 days after the operation. The histology report showed sections of interlacing bundles of smooth muscles with no evidence of malignancy. The 6 weeks post-operative visit was unremarkable.

## DISCUSSION

Myomectomy during cesarean section has traditionally been discouraged throughout the time. The debate concentrate mostly on the uterine atony and postpartum hemorrhage caused by it. There are increasing studies nowadays that myomectomy performed at time of cesarean delivery does not increase the risk of hemorrhage, postoperative fever, or prolong hospital stay particularly in special cases (Ortac *et al.*, 1999; Michalas *et al.*, 1995; Ehigiegba *et al.*, 2001; Kaymak *et al.*, 2005; Kiran *et al.*, 2011). There is also no difference in hemoglobin value and blood transfusion. (Park and Kim, 2009).

There are lot of case reports and case series that shows in certain patients, it is safe to perform cesarean myomectomy by skilled practitioner.

Burton *et al.* (1989) reported 13 cases of cesarean myomectomy. In this study only one case was complicated by intraoperative hemorrhage. They concluded that myomectomy during cesarean section may be safe in carefully selected patients. Ortac *et al.* (1999) reported 22 myomectomies performed for large myomas (>5 cm). They advocate myomectomy in order to minimize

postoperative sepsis. In this study there was no difference in the incidence of post operative fever between the myomectomy groups and the controls. Roman and Tabsh (2004) performed 111 myomectomy at time of cesarean delivery compared to 257 patients with cesarean delivery alone and found no difference in the incidence of intra and post operative complications. The lack of size in the myoma in the study make it an indecisive conclusion about it complications. In their study, Kaymak *et al.* (2005) showed that there was no difference in hemorrhage incidence between the myomectomy groups and the controls. The longer operative time is said to be found in myoma larger than 6 cm (Park and Kim, 2009).

Another important point was that despite the high rate of large myomas, no hysterectomy or other procedures to control bleeding was performed in any case. Cobellis *et al.* (2002) have reported removal of multiple fibroids by electrocautery during LSCS. In a comparative study of cesarean myomectomy on 16 women Brown *et al.* (1999) showed that the mean blood loss in cesarean myomectomy was 495 mL (range 200-1000 mL) compared with 355 mL (range 150-900 mL) in the control group. This does not justify discouraging cesarean myomectomy.

In a study conducted on 24 women in Ghana, the average duration of operation was longer in cases having myomectomy with LSCS (62.08 min) than in those who had LSCS only (50.83 min) (Kwawukume, 2002). There are no statistically significant difference between intramural myomectomy or myomectomy of a fibroid greater than 6 cm in diameter and the control group, this lack of a difference may be attributed to a small sample size and therefore insufficient power to detect such a difference. Thus, intramural myomectomy should be performed with caution (Roman and Tabsh, 2004).

Though myomectomy during pregnancy is still not encouraged, cesarean myomectomy is a feasible undertaking. The reasoning behind this is that a uterus in the immediate postpartum phase is better adapted physiologically to control hemorrhage than in any other stage in a women's life (Fletcher and Frederick, 2005). Bleeding can also stops by contractions and retractions of muscle fibers and the onset of vascular changes for clot formation in placental bed (Anita *et al.*, 2007).

Regardless of the factors that taken into account to perform cesarean myomectomy, communication and information sharing with the patient regarding the procedure and the risk behind it is as important as the procedure itself. Along with it, good post operative care should also be done to observe any unusual complication that may happen.

## CONCLUSIONS

Cesarean myomectomy is now considered by many not always as a hazardous procedure and can be performed in experienced hands, in a well equipped tertiary institution, with the advent of better anesthesia, with availability of blood, in selected patients and according to site and size of myomas. It is always important to have a good informed consent beforehand and post operative care of cesarean myomectomy.

## REFERENCES

- Anita, K., M. Seema and P. Richa, 2007. Cesarean myomectomy. *J. Obstet. Gynecol.*, 57: 128-130.
- Breech, L. and J. Rock, 2003. Leiomyomata Uteri and Myomectomy. In: *Te Linde's Operative Gynecology*, Rock, J. and H. Jones (Eds.). Lippincott Williams and Wilkins, USA., pp: 753-798.
- Brown, D., H.M. Fletcher, M.O. Myrie and M. Reid, 1999. Cesarean myomectomy: A safe procedure. A retrospective case controlled study. *J. Obstetrics Gynaecol.*, 19: 139-141.
- Burton, C.A., D.A. Grimes and C.M. March, 1989. Surgical management of leiomyomata during pregnancy. *Obstet. Gynecol.*, 74: 707-709.
- Cobellis, L., P. Florio, L. Stradella, E. de. Luciab, E.M. Messallib, F. Petragliaa and G. Cobellisb, 2002. Electro-cautery of myomas during caesarean section-two case reports. *Eur. J. Obstetrics Gynecol. Reprod. Biol.*, 102: 98-99.
- Dandade, D., L. Malinak and J. Wheeler, 2003. Therapeutic Gynecologic Procedures. In: *Current Obstetric and Gynecologic, Diagnosis and Treatment*, DeCherney, A. and L. Nathan (Eds.). McGraw-Hill Companies, USA.
- Davi, J.L., S. Ray-Mazumder, C.J. Hobel, K. Baley and D. Sassoon, 1990. Uterine leiomyomas in pregnancy: A prospective study. *Obstet. Gynecol.*, 75: 41-44.
- Depp, R., 2002. Cesarean Delivery. In: *Obstetrics: Normal and Problem Pregnancies*, Gabbe, S.G., J.R. Niebyl and J.L. Simpson (Eds.). 4th Edn., Churchill Livingstone, New York, pp: 599.
- Ehigiegba, A.E., A.B. Ande and S.I. Ojobo, 2001. Myomectomy during cesarean section. *Int. J. Gynecol. Obstetrics*, 75: 21-25.
- Fletcher, H. and J. Frederick, 2005. Abdominal Myomectomy Revisited. In: *Progress in Obstetrics and Gynecology*, Studd, J. (Ed.). Elsevier, New Delhi, India, pp: 277-286.
- Kaymak, O., E. Ustunyurt, R.E. Okyay, S. Kalyoncu and L. Mollamahmutoglu, 2005. Myomectomy during cesarean section. *Int. J. Gynecol. Obstetrics*, 89: 90-93.
- Kiran, A., A. Lata, A. Ashok, V.K. Agrawal and A. Kanupriya, 2011. Cesarean myomectomy: Prospective study. *NJIRM*, 2: 11-14.
- Kwawukume, E., 2002. Cesarean myomectomy. *Afr. J. Reprod. Health*, 6: 38-43.
- Michalas, S.P., F.V. Oreopoulou and J.S. Papageorgiou, 1995. Myomectomy during pregnancy and caesarean section. *Hum. Reprod.*, 10: 1869-1870.
- Ortac, F., M. Gungor and M. Sonmezer, 1999. Myomectomy during cesarean section. *Int. J. Gynecol. Obstetrics*, 67: 189-190.
- Park, B.J. and Y.W. Kim, 2009. Safety of cesarean myomectomy. *J. Obstet. Gynaecol. Res.*, 35: 906-911.
- Roman, A.S. and K.M. Tabsh, 2004. Myomectomy at time of cesarean delivery: A retrospective cohort study. *BMC Pregnancy Childbirth*, Vol. 4. 10.1186/1471-2393-4-14
- Sudhir, A. and G. Sebanti, 2006. Cesarean myomectomy: A study of 14 cases. *J. Obstetrics Gynecol.*, 56: 486-488.