



Journal of Medical Sciences

ISSN 1682-4474

science
alert

ANSI*net*
an open access publisher
<http://ansinet.com>

JMS (ISSN 1682-4474) is an International, peer-reviewed scientific journal that publishes original article in experimental & clinical medicine and related disciplines such as molecular biology, biochemistry, genetics, biophysics, bio-and medical technology. JMS is issued eight times per year on paper and in electronic format.

For further information about this article or if you need reprints, please contact:

Attalla Farag El-Kott
Department of Zoology,
Faculty of Science,
Damanhour University, Egypt

Amelioration of Nitrate-induced Hepatotoxicity by *Allium sativum* in Mice

¹Attalla Farag El-Kott, ²Ayman M. Abdel-Aziz, ^{2,3}Abd El-Karim M. Abd El-Latif, ⁴Ezz Mohie El-Gamal and ⁴Abdalla Mohamed Khalil

The liver plays a vital role in transforming and clearing chemicals and is susceptible to the toxicity from such agents. The aim of the present study was investigation of the hepatoprotective effect of garlic on Nitrate-induced oxidative damage of liver in mice. Mice were divided into six groups. Control group 1 received tap water. Group 2 received garlic solution at dose 200 mg kg⁻¹ b.wt. Group 3 and group 4 received sodium nitrate at doses 500 and 900 ppm kg⁻¹ b.wt. in drinking water freshly prepared daily. Group 5 and group 6 received sodium nitrate at doses 500 and 900 ppm kg⁻¹ b.wt. and treated with garlic 200 mg kg⁻¹ b.wt. The animals were sacrificed by cervical dislocation on the end of the experiment. Nitrate caused a marked (p<0.001) increase in the levels of lipid peroxidation and superoxide dismutase in the liver. We also observed an increase in the hepatic Activity of Alanine Transaminase (ALT), Aspartate Transaminase (AST). Garlic significantly attenuated these adverse effects of nitrate and proffered a dose-dependent hepatoprotection. The present study showed that nitrate-induced oxidative damage in mice liver was amenable to attenuation by moderate dose of garlic extracts possibly via reduced lipid peroxidation and enhanced antioxidant defense system that was insufficient to prevent and protect Nitrate-induced hepatotoxicity. The 200 mg garlic dose was more effective in treatment of hepatotoxicity-induced by sodium nitrate and decrease the Bax expression. In conclusion, garlic can be given as a dietary supplement to human population exposed to environmental toxicants and can provide protection against toxic effects without being appreciably harmful itself.

Key words: Nitrate, garlic, Bax, hepatotoxicity, superoxide dismutase, liver enzymes

¹Department of Zoology, Faculty of Science, Damanhour University, Egypt

²Department of Zoology, Faculty of Science, Fayoum University, Egypt

³Faculty of Applied Medical Sciences, Taif University, Kingdom of Saudi Arabia

⁴Department of Laboratories, Urology and Nephrology Center, Mansoura University, Mansoura, Egypt

INTRODUCTION

Nitrate is widely present in the environment. It is part of the nitrogen cycle which is essential to life (Gilchrist *et al.*, 2010). Nitrate is made indirectly from the fixation of atmospheric N₂ gas by bacteria and, to a lesser extent, from combination of atmospheric nitrogen and oxygen by lightning. Plants depend on the uptake of nitrate to make amino acids and then protein, a process which involves the reduction of nitrate which uses energy provided by photosynthesis. Green, leafy plants tend to have high concentrations of nitrate in their leaves and plants grown in low-light conditions tend to have higher nitrate concentrations as the nitrate is stored and not reduced to form amino acids. Some plants such as beet root store nitrate in their swollen roots in very high concentrations (Gilchrist *et al.*, 2010).

Nitrate is the most common chemical contaminant in the world's groundwater aquifers (Spalding and Exner, 1993). Groundwater is the source for >50% of drinking water supplies, 96% of private water supplies and an estimated 39% of public water supplies (USGS, 1996). An estimated 42% of the U.S. population uses groundwater as their drinking water supply (Hutson *et al.*, 2004). However, the World Health Organization drinking water guideline value for nitrate has been set at 45 mg L⁻¹ (WHO, 1985). Ingested nitrate is reduced to nitrite, which reacts to haemoglobin to form methemoglobin. Infants are particularly susceptible to developing methemoglobinemia (Manassaram *et al.*, 2006). Nitrate is a precursor in the formation of N-nitroso compounds (NOC), a class of genotoxic compounds, most of which are animal carcinogens (Bogovski and Bogovski, 1981). Nitrate contamination of drinking water may increase cancer risk, because nitrate is endogenously reduced to nitrite and subsequent nitrosation reactions give rise to N-nitroso compounds; these compounds are highly carcinogenic and can act systemically (Weyer *et al.*, 2001).

Recently accumulating evidences have indicated that nitrates are oxidation products and ready sources of Nitric Oxide (NO), that NO reacts rapidly with superoxide to form highly reactive peroxynitrite (ONOO⁻) (Chow and Hong, 2002). Reactive metabolites, such as superoxide and peroxynitrite, may cause extensive lipid peroxidation in biological membranes (Salvemini and Cuzzocrea, 2002).

The use of garlic (*Allium sativum*) as a medical agent for treatment of several of diseases has been advocated for thousands of years (Rivlin, 2001). During the past decade, there has been increasing awareness of the potential medicinal uses of garlic; known for its free

radical scavenging effects, immune stimulation, curing of cardiovascular diseases, anti-thrombotic, anti-hypertensive, anti-hyperglycemic, anti-hyperlipidemic, anti-cancer and anti-infectious properties (Wojcikowski *et al.*, 2007; Kook *et al.*, 2009).

It is known that nitrates may react in the gastrointestinal tract synthesizing the powerful hepatotoxic compounds (Garcia Roche *et al.*, 1987). The purpose of this study was to aimed to investigate hepatotoxicity due to the daily intake of sodium nitrates administered to mice during 10 weeks in drinking water and treatment with *Allium sativum*.

MATERIALS AND METHODS

Sodium nitrate (98.5% pure) was procured from Merck Chemicals, Germany. A test solution in drinking water was prepared daily 24 h prior to feeding at a concentration of 500 and 900 ppm Sodium nitrate (Pant and Srivastava, 2002). Sexually mature (7 weeks) white Swiss male mice weighing 20±2 g bred at Damanhour faculty of science animal house colony were used. They were fed *ad libitum* on a pellet diet and maintained under standard laboratory conditions. Mice were divided into six groups (20 mice in each group). Control group received tap water. Group 2 received garlic (TOMEX, ATOS Pharma, Egypt) at dose 200 mg kg⁻¹ of Body Weight (b.wt.). Group 3 and 4 received sodium nitrate at doses 500 and 900 ppm kg⁻¹ b.wt. in drinking water freshly daily prepared. Group 5 and 6 received sodium nitrate at doses 500 and 900 ppm kg⁻¹ b.wt. and treated with garlic 200 mg kg⁻¹ b.wt. The animals were sacrificed by cervical dislocation on the end of the experiment. The experiment was carried out in 2012 and the animal experiments were approved and conducted in accordance with the institutional guidelines of the Animal Care and Use Committee of the Damanhour University, Egypt.

Biochemical assays: At the end of the period, the mice were anesthetized with ether, blood samples were collected by cardiac puncture and serum was obtained by centrifugation (3000 rpm, 12 min). Liver tissues were washed quickly in situ with ice-cold isotonic saline. Serum alanine aminotransferase (ALT) and aspartate aminotransferase (AST) activities were then determined under the manufacturer's instruction spectrophotometrically at 37°C using (Biovision, US). Serum was collected and the Super Oxide Dismutase (SOD) activity was measured spectrophotometrically at 37°C using the manufacturer's instruction (Biovision, US).

Histological examinations: Liver tissues were collected from the animals in different groups and were fixed in 10% buffered formaldehyde solution for 24 h. The paraffin sections were then prepared and cut into 5 µm thick sections by a Leica RM 2016 rotary microtome (Leica Instruments Ltd., Shanghai, China). The sections were stained with hematoxylin and eosin staining (H and E staining) and then mounted with Canada balsam. The degree of liver damage was examined under the microscope. Chronic liver injury was then evaluated by their histological features. Fat vacuoles, nuclei, necrotic hepatocytes, inflammation and central vein dilation were used as criteria for each liver section.

Bax immunohistochemistry: Five micron thick, paraffin-embedded tissue sections were floated onto coated slides (Sigma). Slides were deparaffinised with xylene and dehydrated in graded series of ethanol. Endogenous peroxidase was quenched with 3% H₂O₂: Methanol (1:1) for 30 min at room temperature. Staining of formalin fixed liver sections required boiling in 10 mM citrate buffer, pH 6.0 for 20 min followed by cooling at room temperature for 20 min. Sections were rinsed in Phosphate Buffer Saline (PBS) and then blocked with 6% horse serum and 4% Bovin Serum Albumin (BSA) in PBS for 1 h at room temperature. Primary antibody was mice polyclonal anti-Bax (1:150; Santa Cruz Biotechnology). It was diluted in 1% horse serum and 4% BSA in PBS and left one hour at room temperature.

Sections were washed twice for 5 min in PBS. Immune-histochemical staining was performed using an avidin-biotin peroxidase complex (ABC). Bax antibody location was determined with the addition of 3,3'-Diaminobenzidine (DAB) chromogen (Dako, Denmark): 3% H₂O₂ for 3 min and washing with water stopped color development. Sections were counter stained with hematoxylin, dehydrated and mounted in Canada balsam (DPX, Poole, UK). As the negative control, non-specific mice and goat IgG was used instead of the primary antibody.

Statistical analysis: The data obtained were analysed by One-way of Variance (ANOVA) for the significant interrelation between the groups. Data were expressed as Mean±SD of the mean and values of p<0.05 were considered to be statistically significant.

RESULTS

According to Table 1, serum SOD, ALT and AST levels, 1.98±0.18, 54.75±14.31 and 60.01±13.32, respectively

Table 1: Blood super oxide dismutase (SOD), alanine transaminase (ALT) and aspartate transaminase (AST) in different experimental animals groups

Groups	SOD	ALT	AST
Groups 1: Control	2.99±0.29	12.00±2.310	14.33±2.880
Groups 2: Garlic	3.01±0.30	14.01±2.010	22.13±5.510
Groups 3: 500 ppm nitrate	1.98±0.18*	54.75±14.31*	60.01±13.32*
Groups 4: 900 ppm nitrate	1.14±0.11*	70.03±13.92*	75.23±12.10*
Groups 5: 500 ppm Nitrate+200 mg garlic	3.00±0.71**	26.25±8.08**	39.33±5.51**
Groups 6: 900 ppm Nitrate+200 mg garlic	2.89±0.22**	36.81±6.62**	48.98±8.49**

*Highly significant at p≤0.01, **Weakly significant at p≤0.05

for 500 ppm sodium nitrate and 1.14±0.11, 70.03±13.92 and 75.23±12.10, respectively for 900 ppm sodium nitrate were significantly elevated (p≤0.01) than the control group. On the other hand, nitrate-induced hepatotoxicity groups and treated with garlic extract showed significant decrease (p≤0.05) in AST, ALT and serum SOD levels compared to the control group.

Histopathological observations: The liver sections of both control and garlic-treated groups exhibited normal architecture where it consists of a roughly hexagonal arrangement of plates of hepatocytes radiating outward from a central vein in the centre (Fig. 1a, b). After nitrate administration, there was hepatocellular degeneration with increased intercellular space of the hepatocytes in group 3 and 4. Hepatocellular degeneration and increased intercellular space in group 4 are more pronounced than group 3. In groups which were induced hepatotoxicity with 500 and 900 ppm sodium nitrate, hepatocytes showed cloudy swelling, vacuolar, hydropic as well as congestion. Some other specimens showed apoptotic and necrotic changes, multifocal to diffuse type of coagulative necrosis, that replaced by inflammatory lymphocytes infiltration (Fig. 1c-d). In case group 4 (900 ppm nitrate), the portal area showed congested, perivascular edema, mild fibrosis and apoptotic necrotic cells, where this animals group was showing more sever of hepatotoxicity than group 3 (500 ppm nitrate). The liver of the 200 mg of garlic+500 ppm nitrate group showed marked improvement in its histological structure in comparison to group treated with sodium nitrate alone and represented by the bi-nucleated cells that indicate the proliferation and regeneration but some hepatotoxicity markers remained as dilated central vein and some inflammatory lymphocytes infiltration (Fig. 1e). The liver of the garlic+900 mg nitrate group showed less marked improvement in its histological structure in comparison to group treated with sodium nitrate alone, where the vacuolation, intercellular space of hepatocytes (Fig. 1f).

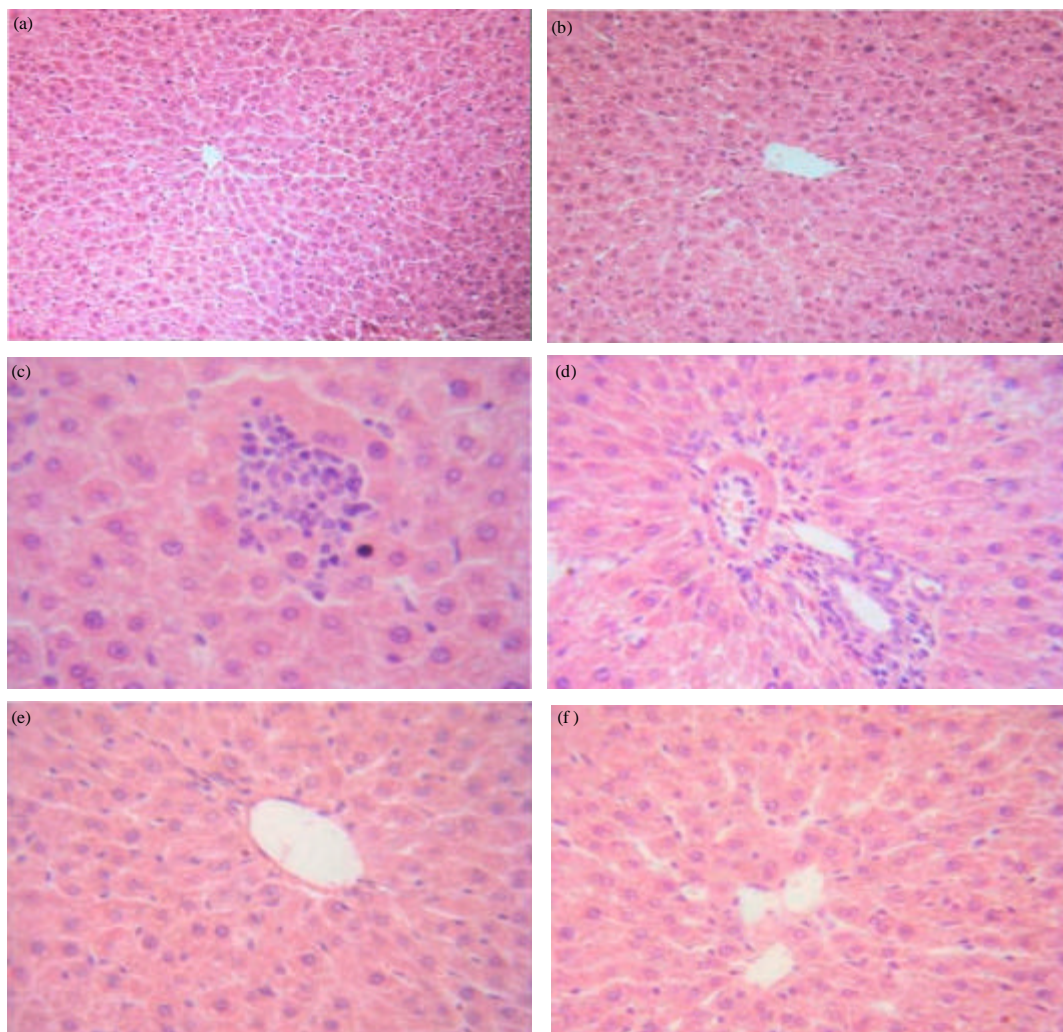


Fig. 1(a-f): (a) Microphotograph of mouse liver (control group) showing the central vein and normal cord pattern of hepatocytes, (b) Microphotograph of mouse liver (garlic group) showing the central vein and normal hepatocytes arranged radially around the central vein and normal hepatocytes with centrally located nuclei, (c) Microphotograph of mouse liver (500 ppm nitrate group) showing vacuolization, leucocytic infiltration, pyknotic nuclei and loss of radial arrangement of hepatocytes, (d) Microphotograph of mouse liver (900 ppm nitrate group) showing congestion of central vein, hepatocytic degeneration and necrosis with increased cytoplasmic eosinophilic granularity, (e) Microphotograph of mouse liver (500 ppm nitrate treated with garlic group) showing improvement of hepatic tissue and (f) Microphotograph of mouse liver (900 ppm nitrate treated with garlic group) showing improvement of hepatic tissue with mild dilated central vein

Immunohistochemistry of Bax: The liver sections of garlic-treated group immune-stained for Bax-proapoptotic protein showed normal expression with respect to the control group (Fig. 2a-b). Otherwise, nitrate-treated groups (group 3 and 4) displayed patchy expression of Bax proapoptotic protein in most of the

hepatocytes cytoplasm (Fig. 2c-d), where the group 4 (900 ppm nitrate) was more Bax expression than group 3 (500 ppm nitrate). Liver of Garlic/Nitrate combined groups (group 5 and 6) demonstrated a marked improvement in the Bax-proapoptotic protein expression (Fig. 2e-f).

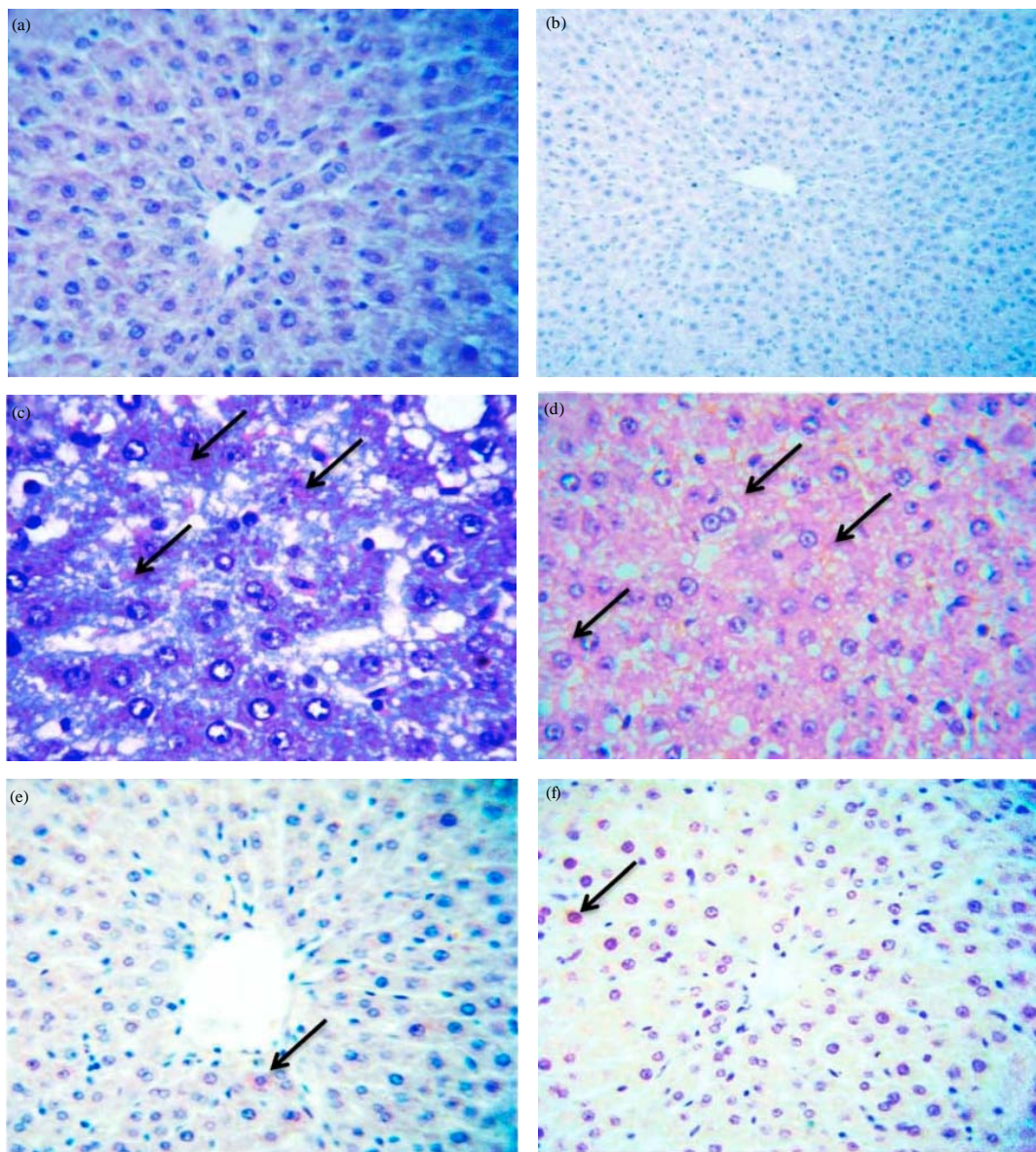


Fig. 2(a-f): Microphotograph of mouse liver (a) control group; showing the weak immunostaining of Bax, (b) garlic group; showing the weak immunostaining of Bax, (c) 500 ppm nitrate group; showing moderate expression of Bax (arrows), (d) 900 ppm nitrate group showing severe expression of Bax (arrows), (e) 500 ppm nitrate treated with garlic group; showing improvement of Bax expression as similar as control group (arrows) and (f) 900 ppm nitrate treated with garlic group; showing the weak immunostaining of Bax (arrows)

DISCUSSION

The sodium nitrate may react with amines of the foods in the stomach and produce nitrosamines and free radicals. Such products may increase lipid peroxidation, which can be harmful to different organs including liver and kidney (Choi *et al.*, 2002). On the other hand, these free radicals, known to cause

oxidative stress, can be prevented or reduced by dietary natural anti-oxidants through their capacity to scavenge these products (Aruoma, 1998). The present study was undertaken to determine whether garlic oil can prevent and/or reduce NaNO_2 induced oxidative stress by examining different biochemical parameters of oxidative damage in the serum of the liver in the mice.

We investigated the efficacy of garlic, which is considered both a traditional natural medicine and an edible vegetable, against the toxic disorders induced by sodium nitrate using a mice model. The liver is an important organ in the body. Aside from creating functional molecules and chemicals for the body, it also removes compounds that could possibly poison other organs. Understanding the liver's functions will help prevent liver ailments by learning how to eat better to protect the liver and avoid disease.

The substrate of SOD is the superoxide radical anion (O_2^-) which is generated by the transfer of one electron to molecular oxygen. This is responsible both for the direct damage of biological large molecules and for generating other reactive oxygen species. SOD keeps the concentration of superoxide radicals at low levels and therefore plays an important role in the defense against oxidative stress (Fridovich, 1997).

The higher concentration of nitrate in liver, following experimental exposure was associated with increased oxidative reaction, which might be responsible, at least in part, for nitrate-induced toxic effects. Oxidative stress induced by sodium nitrate may partly be attributed to the inhibited activities of SOD. Thus the study provides further evidence to dysregulation of anti-oxidant/oxidant balance by sodium nitrate. Garlic reduced tissue nitrate burden, the oral supplementation of nitrate to sodium nitrate-intoxicated mice augmented the anti-oxidant potential by affecting the anti-oxidant enzyme activities besides reducing the tissue injury of liver cells.

In the present study, sodium nitrate caused a marked increase in serum levels of ALT and AST indicating liver injury in groups 3 (54.75 ± 14.31 and 60.01 ± 13.32 , respectively) and 4 (70.03 ± 13.92 and 75.23 ± 12.10 , respectively). AST and ALT levels act as indicators of liver function, hence rehabilitation of normal level of these enzymes indicate the normal functioning of liver. However, the increase in AST, ALT and ALP enzymes in the serum of $NaNO_3$ -treated mice could be attributed to the toxic effect of nitroso-compounds, formed in the acidic environment of the stomach, in causing severe hepatic necrosis (Kalantari and Salehi, 2001). These enzymes abnormalities were ameliorated by supplementation of garlic, perhaps due to its role in stabilizing the cell membrane and protecting the liver from free radical-mediated liver cell toxicity.

Histopathological analysis showed that lesions of periportal hepatic cells with periportal necrosis and macrophage infiltration in the nitrate groups were ameliorated in mice receiving garlic following the induction of liver damage. The role of garlic compounds in free radical scavenging has been investigated by

numerous investigations. Several studies obviously showed antioxidant activity of garlic compositions against oxidative stress in tissues (Leelarungrayub *et al.*, 2006). Garlic both dose levels produced protective effects on histological structure of the liver against nitrate toxicity. When garlic doses were administered with nitrate, the liver retained its normal architecture and was also able to diminish fibrosis, congestion and hepatocyte vacuolation. These results are in accordance with Banerjee *et al.* (2001).

Administration of garlic doses with nitrate modified the pattern of immunolocalization and intensity of the expression of Bax protein in hepatic tissue leading to a highly significant decrease in the percentage of Bax positivity with respect to the Nitrate-treated group. This result is in a good agreement with previous studies of Borrego *et al.* (2004) and Gonzalez *et al.* (2004) who demonstrated the ability of free radical scavengers in modulating of apoptosis. Li *et al.* (2004) revealed that large amounts of ROS suppressed the expression of Bcl-2, increasing the expression of Bax and the heterodimerization between pro and anti-apoptotic proteins, decreasing the degradation of proapoptotic proteins. So, in the present study, the 200 mg garlic dose was the more effective in treatment of hepatotoxicity-induced by sodium nitrate and decrease the Bax expression.

CONCLUSIONS

From the results, it can be concluded that administration of garlic has an extremely beneficial role in overcoming the occurred adverse effects of chronic ingestion of sodium nitrate, which is probably through its excellent antioxidant properties and highly nutritional values. So, garlic can be given as a dietary supplement to human population exposed to environmental toxicants and can provide protection against toxic effects without being appreciably harmful itself. Moreover, efforts are needed for the choice of appropriate dose, duration of treatment and possible side-effects on major organs.

REFERENCES

- Aruoma, O.I., 1998. Free radicals, oxidative stress and antioxidants in human health and diseases. *J. Am. Oil Chem. Soc.*, 75: 199-212.
- Banerjee, S.K., M. Maulik, S.C. Manchanda, A.K. Dinda, T.K. Das and S.K. Maulik, 2001. Garlic-induced alteration in rat liver and kidney morphology and associated changes in endogenous antioxidant status. *Food Chem. Toxicol.*, 39: 793-797.

- Bogovski, P. and S. Bogovski, 1981. Animal species in which N-nitroso compounds induce cancer. *Int. J. Cancer*, 27: 471-474.
- Borrego, A., Z.B. Zamora, R. Gonzalez, C. Romay and S. Menendez *et al.*, 2004. Protection by ozone preconditioning is mediated by the antioxidant system in cisplatin-induced nephrotoxicity in rats. *Mediators Inflamm.*, 13: 13-19.
- Choi, S.Y., M.J. Chung and N.J. Sung, 2002. Volatile N-nitrosamine inhibition after intake of Korean green tea and Maesil (*Prunus mume* SIEB. et ZACC.) extracts with an amine-rich diet in subjects ingesting nitrate. *Food Chem. Toxicol.*, 40: 949-957.
- Chow, C.K. and C.B. Hong, 2002. Dietary vitamin E and selenium and toxicity of nitrite and nitrate. *Toxicol.*, 180: 195-207.
- Fridovich, I., 1997. Superoxide anion radical ($O^{\bullet-}_2$), superoxide dismutases and related matters. *J. Biol. Chem.*, 272: 18515-18517.
- Garcia Roche, M.O., A. Castillo, T. Gonzalez, M. Grillo, J. Rios and N. Rodriguez, 1987. Effect of ascorbic acid on the hepatotoxicity due to the daily intake of nitrate, nitrite and dimethylamine. *Nahrung*, 31: 99-104.
- Gilchrist, M., P.G. Winyard and N. Benjamin, 2010. Dietary nitrate-good or bad?. *Nitric Oxide.*, 22: 104-109.
- Gonzalez, R., A. Borrego, Z. Zamora, C. Romay and F. Hernandez *et al.*, 2004. Reversion by ozone treatment of acute nephrotoxicity induced by cisplatin in rats. *Mediators Inflamm.*, 13: 307-312.
- Hutson, S.S., N.L. Barber, J.F. Kenney, K.S. Linsey, D.S. Lumia and M.A. Maupin, 2004. Estimated use of water in the United States in 2000. USGS Circular 1268. U.S. Geological Survey, Denver, CO.
- Kalantari, H. and M. Salehi, 2001. The protective effect of garlic oil on hepatotoxicity induced by acetaminophen in mice and comparison with N-acetylcysteine. *Saudi Med. J.*, 22: 1080-1084.
- Kook, S., G.H. Kim and K. Choi, 2009. The antidiabetic effect of onion and garlic in experimental diabetic rats: Meta-analysis. *J. Med. Food*, 12: 552-560.
- Leelarungrayub, N., V. Rattanapanone, N. Chanarat and J.M. Gebicki, 2006. Quantitative evaluation of the antioxidant properties of garlic and shallot preparations. *Nutrition*, 22: 266-274.
- Li, D., E. Ueta, T. Kimura, T. Yamamoto and T. Osaki, 2004. Reactive Oxygen Species (ROS) control the expression of Bcl-2 family proteins by regulating their phosphorylation and ubiquitination. *Cancer Sci.*, 95: 644-650.
- Manassaram, D.M., L.C. Backer and D.M. Moll, 2006. A review of nitrates in drinking water: Maternal exposure and adverse reproductive and developmental outcomes. *Environ. Health Perspect.*, 114: 320-327.
- Pant, N. and S.P. Srivastava, 2002. Testicular and spermatotoxic effect of nitrate in mice. *Hum. Exp. Toxicol.*, 21: 37-41.
- Rivlin, R.S., 2001. Historical perspective on the use of garlic. *J. Nutr.*, 131: 951S-954S.
- Salvemini, D. and S. Cuzzocrea, 2002. Superoxide, superoxide dismutase and ischemic injury. *Curr. Opin. Investig. Drugs*, 3: 886-895.
- Spalding, R.F. and M.E. Exner, 1993. Occurrence of nitrate in groundwater. A review. *J. Environ. Qual.*, 22: 392-402.
- USGS, 1996. Nitrate in ground waters of the US-assessing the risk. FS-092-96. U.S. Geological Survey, Reston, VA., USA.
- WHO, 1985. Health hazards from nitrates in drinking water. Report on a WHO Meeting, WHO Regional Office for Europe, Copenhagen.
- Weyer, P.J., J.R. Cerhan, B.C. Kross, G.R. Hallberg and J. Kantamneni *et al.*, 2001. Municipal drinking water nitrate level and cancer risk in older women: The Iowa women's health study. *Epidemiology*, 12: 327-338.
- Wojcikowski, K., S. Myers and L. Brooks, 2007. Effects of garlic oil on platelet aggregation: A double blind placebo controlled crossover study. *Platelets*, 18: 29-34.