



Journal of Medical Sciences

ISSN 1682-4474

science
alert

ANSI*net*
an open access publisher
<http://ansinet.com>



JMS (ISSN 1682-4474) is an International, peer-reviewed scientific journal that publishes original article in experimental & clinical medicine and related disciplines such as molecular biology, biochemistry, genetics, biophysics, bio-and medical technology. JMS is issued eight times per year on paper and in electronic format.

For further information about this article or if you need reprints, please contact:

Mina Eslami-Moayed
Department of Radiology,
Atherosclerosis Research Center,
Ahvaz Jundishapur University of
Medical Sciences, Ahvaz, Iran

Diagnostic Accuracy of Ultrasound Findings in Patients with Carpal Tunnel Syndrome

¹Hamid Dehdashti Shahrokh, ²Davood Kashipazha,
³Fakher Rahim, ¹Masoud Cina, ¹Mina Eslami-Moayed,
¹Seyed Ali Alboshokeh, ⁵Marieh Eslami-Moayed and ⁴Arash Forouzan

Carpal Tunnel Syndrome (CTS) is a common problem that is caused by pressure on a nerve in the wrist and is associated with various factors. We compared Cross-Sectional Area (CSA) of the inlet and outlet in CTS patients and healthy controls and define the best cut off point of CSA and assess the utility of US in the diagnosis of CTS patients as well. This cross-sectional, age-group-matched case-control study was performed on 39 patients aged 42-65 years with electro-physiologically confirmed idiopathic CTS and 35 healthy controls from Golestan Hospital, Ahvaz, Iran from Jan 2013 to Feb 2014. Neurological and electro-diagnostic tests for patients were performed by an expert neurologist as the gold standard diagnostic test for CTS cases. Hundred wrists were evaluated. Electromyography (EMG) showed that 16 (32%) cases were mild, 17 (34%) were moderate and 17 (34%) were severe. The results showed that the CSA of carpal tunnel inlet, carpal tunnel outlet and AP diameter were significantly different between the two groups ($p < 0.001$, $p = 0.009$, respectively). The sensitivity and specificity of carpal tunnel inlet were 92 and 96%, for carpal tunnel outlet were 92 and 92%, for AP diameter were 64 and 58%. Longitudinal evaluations are necessary to better know the utility of ultrasound for diagnosing CTS. The accuracy of diagnosis increases in parallel with the increase in the stages and severity of CTS. Therefore, patients with severe CTS would not need the more uncomfortable, costly and invasive techniques.

Key words: Median nerve, carpal tunnel syndrome, diagnostics, ultrasound

¹Department of Radiology, Atherosclerosis Research Center, Ahvaz Jundishapur University of Medical Sciences, Ahvaz, Iran

²Department of Neurology, Ahvaz Jundishapur University of Medical Sciences, Ahvaz, Iran

³Hearing Research Center, Ahvaz Jundishapur University of Medical Sciences, Ahvaz, Iran

⁴Department of Emergency Medicine, Imam Khomeini Hospital, Ahvaz Jundishapur University of Medical Sciences, Ahvaz, Iran

⁵Neurologist, Emam Hossein Hospital, Tehran, Iran

INTRODUCTION

Carpal Tunnel Syndrome (CTS) is a common problem that is caused by pressure on a nerve in the wrist and is associated with various factors (Aboonq, 2015; Uchiyama *et al.*, 2010). Fractures, dislocations, tumors, some chronic diseases, such as diabetes or thyroid disorders and repetitive movements of the wrist, are conditions that cause pressure on the median nerve at the wrist and ultimately cause CTS (De-La-Llave-Rincon *et al.*, 2012). This syndrome is the most common entrapment neuropathy, which can cause varying degrees of disability (Cutts, 2007). The prevalence of CTS was 2.7 cases per 1000 person in the general population (Atroshi *et al.*, 1999; De Krom *et al.*, 1992) and 2.3 cases per 1000 person in the US working population (Dale *et al.*, 2013).

The overall prevalence of this disorder in the general population of Sweden was reported from 2.7-4% (Borg and Lindblom, 2000) and in Italy 329 cases per 100,000 people per year have been reported (Mattioli *et al.*, 2009; Rosecrance *et al.*, 2013). The prevalence of CTS in Iran was 16.7% among dentists (Haghighat *et al.*, 2012) and in pregnant and non-pregnant Iranian women was 3.4 and 2.3%, respectively (Yazdanpanah *et al.*, 2012).

Though physiologic and clinical information have been considered as acceptable tools for CTS diagnosis, due to the low sensitivity, specificity and diagnostic accuracy, these methods are not completely reliable; thus, in case of clinical susceptibility for definitive diagnosis, it is recommended to use Electro-Diagnostic Sensitivity (EDS) methods (De Krom *et al.*, 1990; El Miedany *et al.*, 2008; Macfarlane and Williams, 1990). Ultrasound (US) is an available, non-invasive, cost effective and easy imaging technique that almost has no harm to the body and could be applied for CTS diagnosis (Tai *et al.*, 2012). However, US could be an alternative imaging technique for the diagnosis of CTS, but due to low sensitivity and specificity as well as a relatively high rate of false negative and false positive results, the precise diagnostic value of this method is controversial (Mondelli *et al.*, 2008; Tai *et al.*, 2012).

Thus, aimed to compare Cross-Sectional Area (CSA) of the inlet and outlet in CTS patients and healthy controls and define the best cut off point of CSA and assess the utility of US in the diagnosis of CTS patients as well.

MATERIALS AND METHODS

Study design and population: This cross-sectional, age-group-matched case-control study was performed on 39 patients aged 42-65 years with electro-physiologically confirmed idiopathic CTS and 35 healthy controls from Golestan Hospital, Ahvaz, Iran from Jan, 2013 to Feb,

2014. The study was approved by Ahvaz Jundishapur University of Medical Sciences Ethical Committee and all patients were signed the inform consent prior to enrollment.

Inclusion criteria: All clinically suspected CTS aged 42-65 years who had symptoms such as paresthesia and painful hands, particularly at night, were enrolled.

Exclusion criteria: Pregnant patients and those, who have any signs of systemic diseases such as rheumatoid arthritis, diabetes mellitus, acromegaly and hypothyroidism as well as pathological conditions, such as polyneuropathy radiculopathy weakness and muscle atrophy or have surgery, trauma or fracture of the wrist, were excluded.

Methods: After explaining the study process personal information including gender, age, height and weight were recorded. Physical examination and diagnostic tests for CTS was performed for all patients. Neurological and electro-diagnostic tests for patients treated were performed by an expert neurologist as the gold standard diagnostic test for CTS cases. The work was done at room temperature and skin surface temperature controlled at 32-34°C was maintained. The positive findings for the diagnosis of CTS include: Sensory Nerve Conduction Velocity (SNCV) average of less than 45 m per second, Distal Motorischen Latenz (DML) more than 2.4 m sec and Sensory Nerve Action Potential (SNAP) less than 15 microvolt. Based on these tests, patients are divided into four groups: Normal, all tests normal: Mild, slowing in SNCV and normal DML; moderate, slowing in SNCV and prolonged DML and severe, no sensory response and prolonged DML. We only considered last three groups of patients are considered.

Ultrasound: Ultrasound was performed using a linear-frequency probe (GE Voluson). Patient was positioned in the sitting position and the forearm was placed supine. Wrist was located in a resting and neutral position and the fingers are placed in the semi-flex condition. The CSA was calculated for carpal tunnel inlet and outlet. Each measurement was repeated twice and the mean value was considered. Ultimately, the ultrasound findings in the case and control groups were compared.

Statistical analysis: Data was analyzed by SPSS 17.0 (SPSS Inc., Chicago, IL, USA), presented as Mean±SD. For comparing continuous variables the Kruskal-Wallis test was applied. The ROC curve was used to determine optimal cut-off values of the median nerve inlet and outlet CSA. Area Under the Curve (AUC) was calculated. The p-value<0.05 was considered statistically significant.

RESULTS

By comparing the two groups, the only difference in terms of Body Mass Index (BMI) values was statistically significant ($p = 0.001$) (Table 1).

Hundred wrists were evaluated. Electromyography (EMG) showed that 16 (32%) cases were mild, 17 (34%) were moderate and 17 (34%) were severe (Table 2).

The results showed that the CSA of carpal tunnel inlet, carpal tunnel outlet and AP diameter were significantly different between the two groups (Table 3). With a cutoff point of 11.11 mm² for the median nerve CSA at the carpal tunnel inlet (Table 4), the sensitivity and specificity of ultrasound were 92 and 96%, respectively (area under the curve = 0.93, $p < 0.001$) (Table 5). With a cutoff point of 10.81 mm² for the median nerve CSA at the carpal tunnel outlet, the sensitivity and specificity of ultrasound examination were 92 and 92%, respectively (area under the curve = 0.94, $p < 0.001$).

In ROC curve analysis, the area under the curve was significant for mild, moderate and server CTS (Table 4). The ROC curve analysis was also performed to assess the utility of ultrasound examination in prediction of CTS (Fig. 1).

DISCUSSION

We found that the median nerve cross-section at the carpal tunnel inlet and outlet significantly differed between patients with CTS and normal individuals. Electro-Diagnostic Studies (EDS) provide valuable information about median nerve transfer and reduce both sensory and motor conduction speed in patients with CTS. Although, the physiological information is considered as the gold standard for the diagnosis of CTS, the sensitivity has been reported in the range of 49-86% and false negative in the range of 16-34% (Al-Hashel *et al.*, 2014; Jablecki *et al.*, 1993; Witt *et al.*, 2004). Ultrasound has been introduced as an alternative method of diagnosis of CTS in comparison with EDS (Kamolz *et al.*, 2001), due to many advantages, including low cost, safety,

mobility and ease of use. The diagnostic accuracy of ultrasonography for the diagnosis of CTS has been investigated in many studies and different cut off points for the CSA has been reported (Kerasnoudis, 2013; Tai *et al.*, 2012, 2013). This difference may be due to difference in the sample size, study design and patient's characteristics. In most previous studies, concordance of NCS and ultrasound findings in defining the severity of CTS has been reported (De Krom *et al.*, 2009; Mohammadi *et al.*, 2010; Moran *et al.*, 2009; Pazzaglia and Padua, 2010).

In our study, the sensitivity and specificity of carpal tunnel inlet were 92 and 96%, while different studies have been reported the sensitivity and specificity of carpal tunnel inlet, ranging from 42-98 and 51-100% (Sarraf *et al.*, 2014). Thus ultrasound has an acceptable accuracy in the diagnosis of patient with CTS and may help in the detection of severity and stage of disorder progression. Recently, Chiavaras *et al.* (2014) reviewed a number of diagnostic pitfalls related to ultrasound evaluation of the hand and wrist in which these pitfalls relate to evaluation of some disorders, such as

Table 1: Baseline characteristics of the case and control group

Parameters	Patients	Normal	p-value
Age	53.70±6.96	50.28±6.95	0.061
BMI*	29.84±3.34	27.90±2.50	0.001
Gender			
Female	26 (52%)	27 (54%)	0.840
Male	24 (48%)	23 (46%)	

*Body mass index (BMI)

Table 2: The results of Electromyography (EMG)

Parameters	Frequency	Percent
Mild	16	32.0
Moderate	17	34.0
Severe	17	34.0
Total	50	100.0

Table 3: CSA of carpal tunnel inlet, carpal tunnel outlet and AP diameter between the two groups

Parameters	Patients	Normal	p-value
CAS1	11.92±0.99	9.40±0.83	<0.001
CAS2	11.94±1.01	9.35±0.85	<0.001
AP diameter of carpal tunnel	1.04±0.089	1.01±0.052	0.009

Table 4: Cut off point and area under the curve for the carpal tunnel inlet, carpal tunnel outlet and AP diameter

Parameters	Cut off value (mm ²)	Area under the curve	Asymptotic 95% confidence interval		p-value
			A	B	
CAS1	11.115	0.93	0.878	0.987	<0.001
CAS2	10.815	0.94	0.894	0.99	<0.001
AP diameter of carpal tunnel	0.995	0.63	0.51	0.74	0.03

Table 5: Sensitivity, specificity, positive predictive value, negative predictive value and accuracy for ultrasound

Parameters	Sensitivity (%)	Specificity (%)	Positive predictive value (%)	Negative predictive value (%)	Accuracy (%)
CAS1	92	96	95.83	92.31	94
CAS2	92	92	92.00	92.00	92
AP diameter	64	58	60.38	61.70	61

CSA1: Carpal tunnel inlet, CSA2: Carpal tunnel outlet

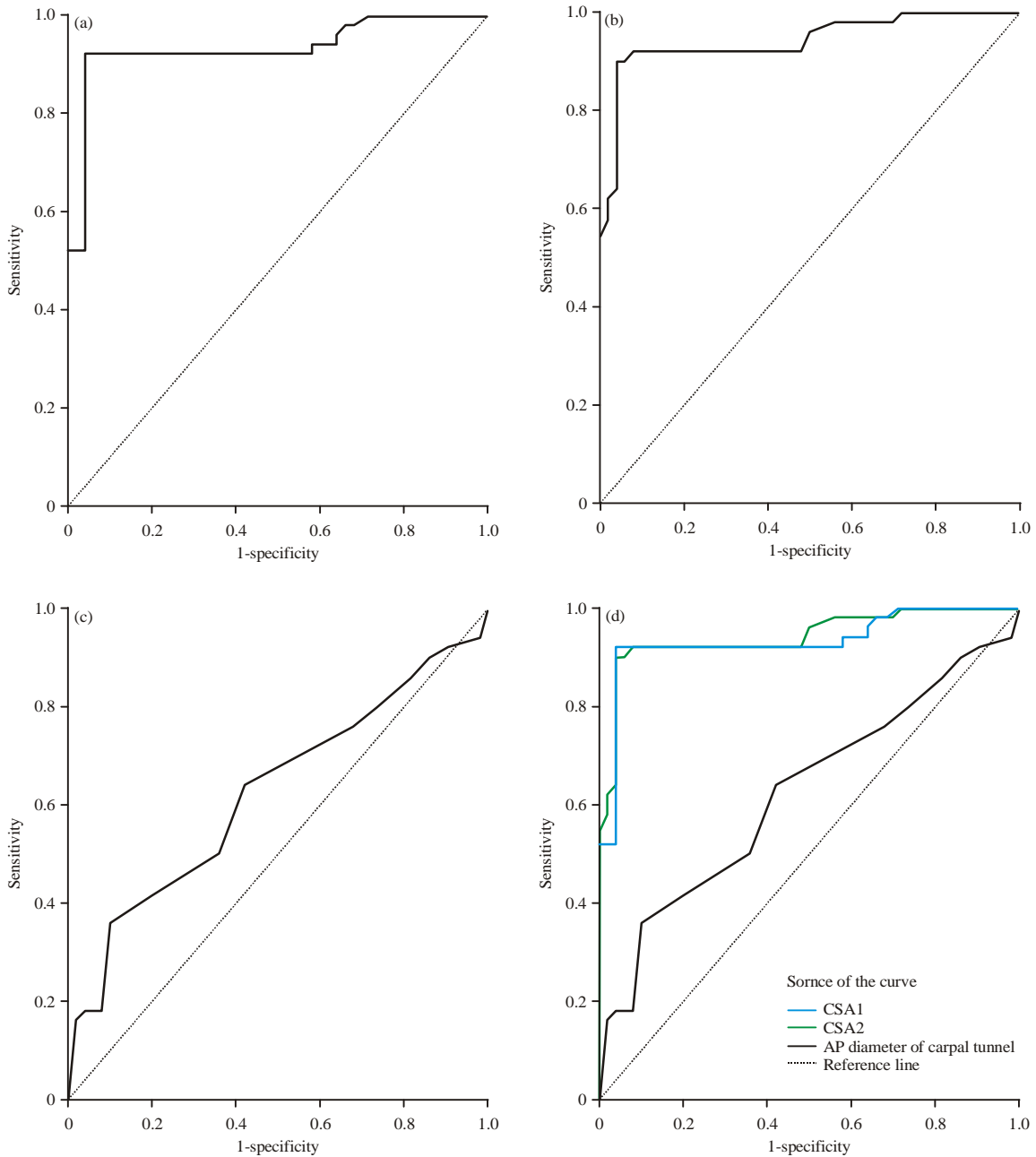


Fig. 1(a-d): Receiver Operating Characteristic curve (ROC) for median nerve cross-section at the three levels, Carpal Tunnel Syndrome (CTS) (a) CSA1, (b) CSA2, (c) AP diameter and (d) Overall

inflammatory arthritis, CTS, ulnar collateral ligament of the thumb and muscle variants (Chiavaras *et al.*, 2014). Thus, ultrasound has been shown to be a relatively valuable imaging method for CTS, knowledge of potential pitfalls makes this procedure somehow controversial due to the possibility of misdiagnosis and achieving high diagnostic accuracy is uncertain as well.

CONCLUSION

Continued studies and longitudinal evaluations are necessary to better know the utility of ultrasound for diagnosing CTS. Moreover, Small bodies of research evidences for the independent use of ultrasound for diagnosis of CTS are existed, but ultrasound assessment of the median nerve may consider as a screening tool in

the first step of subjects with suspected CTS. The accuracy of diagnosis increases in parallel with the increase in the stages and severity of CTS. Therefore, patients with severe CTS would not need the more uncomfortable, costly and invasive techniques. Further researches are essential to find the best combination of ultrasound and other imaging techniques for screening and diagnostic CTS as well as compare the results with using ultrasound individually.

REFERENCES

- Aboonq, M.S., 2015. Pathophysiology of carpal tunnel syndrome. *Neurosciences*, 20: 4-9.
- Al-Hashel, J.Y, H.M. Rashad, M.R. Nouh, H.A. Amro and A.J. Khuraibet *et al.*, 2014. Sonography in carpal tunnel syndrome with normal nerve conduction studies. *Muscle Nerve*, 51: 592-597.
- Atroshi, I., C. Gummesson, R. Johnsson, E. Ornstein, J. Ranstam and I. Rosen, 1999. Prevalence of carpal tunnel syndrome in a general population. *J. Am. Med. Assoc.*, 282: 153-158.
- Borg, K. and U. Lindblom, 2000. Prevalence of carpal tunnel syndrome has not been changed during a 20-year period. *Lakartidningen*, 97: 4634-4634.
- Chiavaras, M.M., J.A. Jacoson, C.M. Yablon, M.K. Brigido and G. Girish, 2014. Pitfalls in wrist and hand ultrasound. *Am. J. Roentgenol.*, 203: 531-540.
- Cutts, S., 2007. Cubital tunnel syndrome. *Postgraduate Med. J.*, 83: 28-31.
- Dale, A.M., C. Harris-Adamson, D. Rempel, F. Gerr and K. Hegmann *et al.*, 2013. Prevalence and incidence of carpal tunnel syndrome in US working populations: Pooled analysis of six prospective studies. *Scand. J. Work Environ. Health*, 39: 495-505.
- De Krom, M.C.T.F.M., P.G. Knipschild, F. Spaans and A.D.M. Kester, 1990. Efficacy of provocative tests for diagnosis of carpal tunnel syndrome. *Lancet*, 335: 393-395.
- De Krom, M.C.T.F.M., P.G. Knipschild, A.D.M. Kester, C.T. Thijs, P.F. Boekkooi and F. Spaans, 1992. Carpal tunnel syndrome: Prevalence in the general population. *J. Clin. Epidemiol.*, 45: 373-376.
- De Krom, M.C., C.J. de Krom and F. Spaans, 2009. Carpal tunnel syndrome: Diagnosis, treatment, prevention and its relevance to dentistry. *Nederlands Tijdschrift Tandheelkunde*, 116: 97-101.
- De-La-Llave-Rincon, A.I., E.J. Puentedura and C. Fernandez-De-Las-Penas, 2012. New advances in the mechanisms and etiology of carpal tunnel syndrome. *Discovery Med.*, 13: 343-348.
- El Miedany, Y., S. Ashour, S. Youssef, A. Mehanna and F.A. Meky, 2008. Clinical diagnosis of carpal tunnel syndrome: Old tests-new concepts. *Joint Bone Spine*, 75: 451-457.
- Haghighat, A., S. Khosrawi, A. Kelishadi, S. Sajadieh and H. Badrian, 2012. Prevalence of clinical findings of carpal tunnel syndrome in Isfahanian dentists. *Adv. Biomed. Res.*, Vol. 1. 10.4103/2277-9175.96069
- Jablecki, C.K., C.M.T. Andary, Y.T. So, D.E. Wilkins and F.H. Williams, 1993. Literature review of the usefulness of nerve conduction studies and electromyography for the evaluation of patients with carpal tunnel syndrome. *Muscle Nerve*, 16: 1392-1414.
- Kamolz, L.P., K.F. Schrogendorfer, M. Rab, W. Girsch, H. Gruber and M. Frey, 2001. The precision of ultrasound imaging and its relevance for carpal tunnel syndrome. *Surgical Radiol. Anatomy*, 23: 117-121.
- Kerasnoudis, A., 2013. Re: Ultrasonography for diagnosing carpal tunnel syndrome: A meta-analysis of diagnostic test accuracy. *Ultrasound Med. Biol.*, 39: 1129-1129.
- Macfarlane, D.G. and T.G. Williams, 1990. Efficacy of provocative tests for diagnosis of carpal tunnel syndrome. *Lancet*, 335: 727-727.
- Mattioli, S., A. Baldasseroni, S. Curti, R.M. Cooke and A. Mandes *et al.*, 2009. Incidence rates of surgically treated idiopathic carpal tunnel syndrome in blue-and white-collar workers and housewives in Tuscany, Italy. *Occup. Environ. Med.*, 66: 299-304.
- Mohammadi, A., A. Afshar, A. Etemadi, S. Masoudi and A. Baghizadeh, 2010. Diagnostic value of cross-sectional area of median nerve in grading severity of carpal tunnel syndrome. *Arch. Iran. Med.*, 13: 516-521.
- Mondelli, M., G. Filippou, A. Gallo and B. Frediani, 2008. Diagnostic utility of ultrasonography versus nerve conduction studies in mild carpal tunnel syndrome. *Arthritis Rheumatism*, 59: 357-366.
- Moran, L., M. Perez, A. Esteban, J. Bellon, B. Arranz and M. del Cerro, 2009. Sonographic measurement of cross-sectional area of the median nerve in the diagnosis of carpal tunnel syndrome: Correlation with nerve conduction studies. *J. Clin. Ultrasound.*, 37: 125-131.
- Pazzaglia, C. and L. Padua, 2010. Re: Sonographic measurement of cross-sectional area of the median nerve in the diagnosis of carpal tunnel syndrome: Correlation with nerve conduction studies. *J. Clin. Ultrasound*, 38: 145-146.
- Rosecrance, J., T. Marras, L. Murgia, R. Tartaglia and A. Baldasseroni, 2013. Carpal tunnel syndrome among ewe dairy farmers in Sardinia, Italy. *Am. J. Ind. Med.*, 56: 889-896.

- Sarraf, P., M. Malek, M. Ghajarzadeh, S. Miri, E. Parhizgar and S.Z. Emami-Razavi, 2014. The best cutoff point for median nerve cross sectional area at the level of carpal tunnel inlet. *Acta Medica Iranica*, 52: 613-618.
- Tai, T.W., C.Y. Wu, F.C. Su, T.C. Chern and I.M. Jou, 2012. Ultrasonography for diagnosing carpal tunnel syndrome: A meta-analysis of diagnostic test accuracy. *Ultrasound Med. Biol.*, 38: 1121-1128.
- Tai, T.W., C.Y. Wu, F.C. Su, T.C. Chern and I.M. Jou, 2013. Reply to letter to the editor re: Ultrasonography for diagnosing carpal tunnel syndrome: A meta-analysis of diagnostic test accuracy. *Ultrasound Med. Biol.*, 39: 1129-1130.
- Uchiyama, S., T. Itsubo, K. Nakamura, H. Kato, T. Yasutomi and T. Momose, 2010. Current concepts of carpal tunnel syndrome: Pathophysiology, treatment and evaluation. *J. Orthopaedic Sci.*, 15: 1-13.
- Witt, J.C., J.G. Hentz and J.C. Stevens, 2004. Carpal tunnel syndrome with normal nerve conduction studies. *Muscle Nerve*, 29: 515-522.
- Yazdanpanah, P., S. Aramesh, A. Mousavizadeh, P. Ghaffari, Z. Khosravi and A. Khademi, 2012. Prevalence and severity of carpal tunnel syndrome in women. *Iranian J. Public Health*, 41: 105-110.