

<http://www.pjbs.org>

PJBS

ISSN 1028-8880

**Pakistan
Journal of Biological Sciences**

ANSI*net*

Asian Network for Scientific Information
308 Lasani Town, Sargodha Road, Faisalabad - Pakistan

Adrenergic and Cholinergic Innervation of the Pheasant Spleen

Katarína Schmidtová, Monika Kočíšová, Maria Širotáková, František Dorko and Ildiko Škardová
Medical Faculty of University P.J. Šafarik, Košice, Slovak Republik,
University of Veterinary, Kosice, Slovak Republik

Abstract: The localization and distribution of the adrenergic and acetylcholinesterase (AChE)- positive nerve fibres innervating the spleen was studied in pheasant by using histochemical methods. Both visualized nerve fibres entered the pheasant spleen at its hilum in the vicinity of the splenic artery branches and they were gradually distributed into the parenchyma along large arterial branches. The greatest number and density of adrenergic and cholinergic nerve fibres were associated with the central artery of the white pulp, and from this localization entered to the periarterial lymphatic sheath. Some of these nerve profiles extended to the red pulp and reached the splenic capsule. The adrenergic nerve fibres were found in the wall of large and small branches of the splenic veins, but no cholinergic nerve fibres were found there. The abundant occurrence of adrenergic and cholinergic nerve fibres in several parts of the pheasant spleen suggest about their participation on modulation of splenic functions.

Key words: Spleen, pheasant, innervation, adrenergic, cholinergic Innervation of pheasant spleen

Introduction

The spleen is encapsulated secondary lymphopoietic organ having several functions and playing important role in immune reactions. Extensive evidence accumulated over past decade from the fields of psychology, neurobiology and immunology indicates that the nervous system can modulate the activities of the immune system through both neuroendocrine and autonomic outflow (Bellinger *et al.*, 1993). Altered immune function has been induced by classical behavioral conditioning, by stressful stimuli, and by other psychological paradigms (Ader *et al.*, 1990). Lesions in specific regions of the brain, particularly in the hypothalamus and limbic-related areas, lead to transient or even permanently altered immunity in the periphery (Carlson and Felten, 1989). Noradrenergic innervation of specific regions of primary and secondary lymphoid organs, including parenchymal zones, has established links necessary for neural modulation of immunity (Bullock, 1985).

While the species-specific differences of innervation in the mammalian spleen are well documented by several authors (Bellinger *et al.*, 1989; Fillenz, 1970; Reilly, 1985), little attention has been paid to study of splenic innervation in the lower vertebrates (Hodges, 1974; Schmidtova *et al.*, 1995).

The present study was performed to demonstrate in particular adrenergic and AChE-positive neurons innervating the pheasant spleen.

Materials and Methods

The experiments in the present study were performed on 20 male and female pheasants in the period of 1-5 weeks after birth. The animals were anesthetized with sodium pentobarbital (40 mg/kg, i.p.) The spleen was removed after laparotomy and individual spleen samples were taken for both histological examinations. Sections of 20 μ m thickness were prepared using a freezing microtome. The observation of the adrenergic nerve structures were visualized by a modified fluorescent histochemical method, using glyoxilic acid, that was developed by Shvaley and Zhuckova (1987). The specific fluorescence of adrenergic nerve fibres was studied in incident ultraviolet light (epiluminiscence) using a microscope Jenalumar 2 (Zeiss, Jena). The presence of acetylcholinesterase in splenic neural structures was determined by the direct thiocholine method modified by El-Badawi and Schenk (1967). After incubation, the individual sections were mounted on slides and examined under a light microscope Jenalumar 2.

Results

Adrenergic innervation of the pheasant spleen: The spleen in the pheasant is a small round-shaped organ of brownish-red color and it lies against the dorsal surface of the right lobe of the liver. Structurally and functionally the spleen belongs to the blood-forming organs but it is also important as a secondary lymphopoietic organ.

Adrenergic nerve fibres were observed in the pheasant spleen in several localizations in the white pulp, the red pulp and in the splenic capsule. The system of fibrous trabeculae of the pheasant spleen is very poorly developed.

Fluorescent histochemistry demonstrated adrenergic nerve fibres entering the spleen at its hilum in the vicinity of the splenic artery branches. The visualized nerve fibres ran along the arterial branches in periarterial topography as a longitudinal nerves or they formed fine periarterial plexuses and gradually proceeded into the splenic parenchyma (Fig. 1). The greatest number and density of these nerve fibres were associated with the central artery. Some of nerve fibres, detached from periarterial course were distributed into the parenchyma of the periarterial lymphatic sheath (PALS) and also were scattered in the marginal zone encircling the germinal centre. Solitary nerve fibres were noted in the red pulp (Fig. 2). In greater number the fluorescent nerve fibres were seen in subcapsular region and from this localization they entered the splenic capsule (Fig. 3), however these nerve profiles did not form any nervous plexus here. It is notable that intensive fluorescent nerve profiles were found in the wall of the large splenic veins (Fig. 4). The thickness and density of these nerve fibres were obvious smaller than in their periarterial localization.

Cholinergic Innervation of the pheasant spleen:

Acetylcholinesterase staining in the pheasant spleen was present in neural elements and were visualized in several localization of the spleen, like in the adrenergic nerve fibres. AChE-positive nerve bundles were observed traveling along the splenic artery branches near the point of entry into the spleen (Fig. 5). Nerve fibres from these bundles traced branching of the splenic artery and in such a way also accompanied the central artery. Some of these nerve profiles, separated from their periarterial localization, continued to propagate in the direction of the PALS, and the marginal zone of the lymphatic follicle encircling the germinal centre (Fig. 6). The AChE-positive nerve fibres in periarterial course reached subcapsular region and entered into the splenic capsule (Fig. 7). They were not found in the wall of the splenic veins.

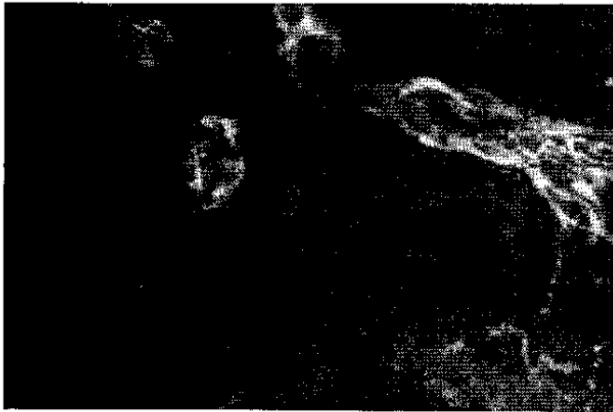

Fig. 1: Fluorescent adrenergic nerve fibres are visible in periarterial location as a longitudinal nerves and forming the adventitial nervous plexus in wall of detaching arterial branch

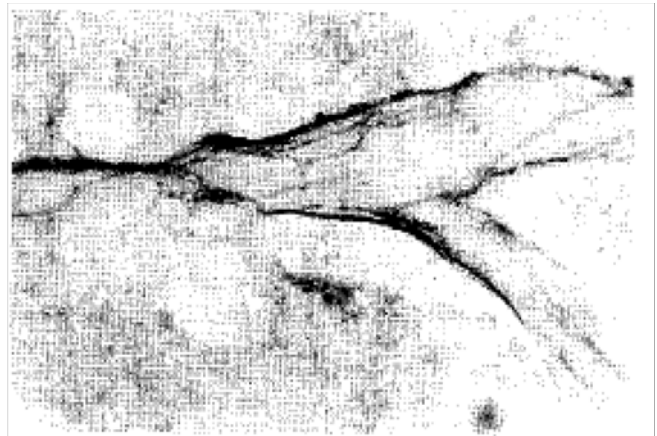


Fig. 4: Cross section through hilar splenic arterial branches and splenic veins. Abundant presence of adrenergic nerve fibres in wall of the arteries (A) and smaller density in wall of the vein (V)



Fig. 2: Rich adventitial nervous plexus of the central artery and detaching nerve fibres into the PALS encircling the marginal zone. Numerous nerve fibres are presented in the red pulp

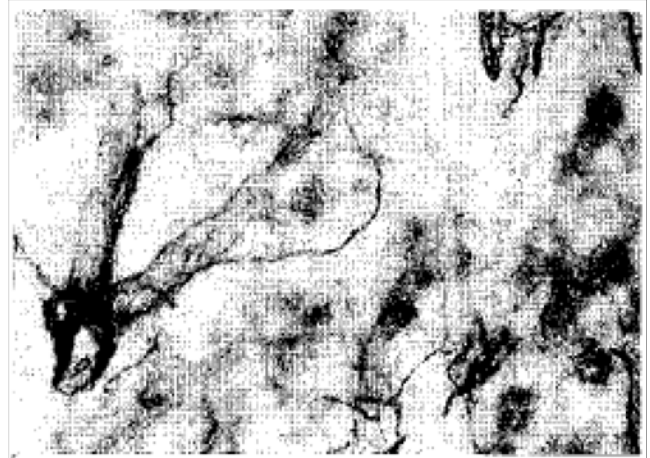

Fig. 5: Thick nerve bundles in periarterial course and fine adventitial plexus of AChE-positive nerve fibres associated with the splenic artery (A)

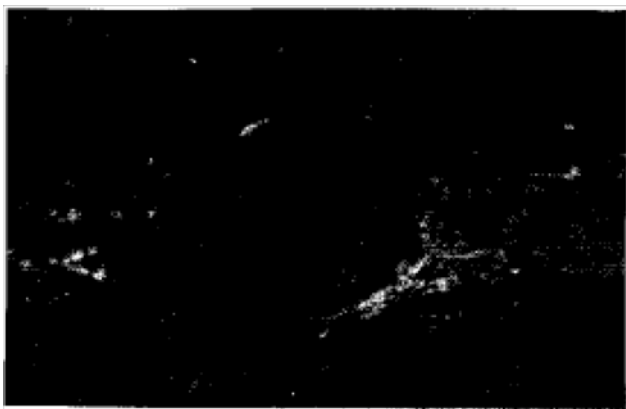


Fig. 3: Adrenergic nerve fibres around arterioles in subcapsular region and longitudinal fibre in the splenic capsule (C)

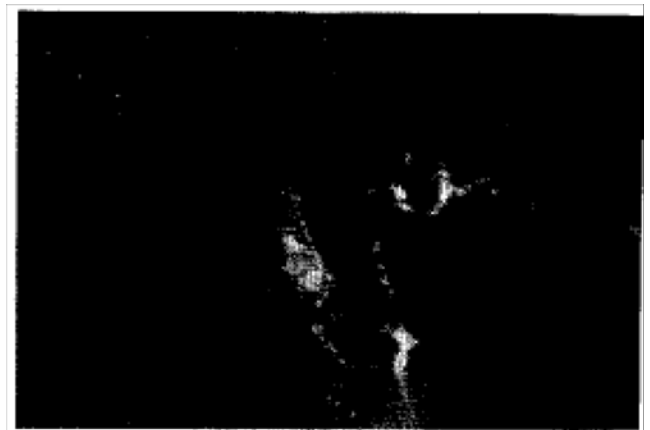

Fig. 6: Some of nerve fibres detached from nervous plexus of the central artery run to the PALS and the marginal zone of the lymphatic follicle



Fig. 7: Abundant occurrence of the AChE-positive nerve fibres in the red pulp, subcapsular region and in the splenic capsule (C)

Discussion

In the present study we report the presence and distribution of the adrenergic and acetylcholinesterase positive nerve structures in the pheasant spleen in their specialities. We found both adrenergic and AChE-positive nerve fibres in the pheasant spleen. Visible nerve fibres entered the spleen near its hilum in the vicinity of the splenic artery branches. The spleen of the pheasant has no system of fibrous trabeculae so nerve fibres are distributed into the parenchyma in periarterial course. The adrenergic and AChE-positive nerve fibres were presented in the white pulp, red pulp and in the splenic capsule. Similar findings were recorded by Schmidtova *et al.* (1995) during an investigation of development of the AChE-positive nerve structures in the chicken spleen. Fillenz (1970) in the cat and Reilly (1985) in the mouse were unable to trace AChE-positive nerve fibres into the parenchyma of the spleen and describe only a small density of AChE-positive nerves. Bellinger *et al.* (1993) in rat observed the presence of AChE-positive nerve fibres in the white pulp around the central artery, in the PALS, and in the marginal zone, but did not find their presence in the red pulp. Hodges (1974) reported only the presence of sympathetic nerves in the chicken spleen without detailed description. In the mouse, rat and rabbit the spleen is richly innervated by sympathetic nerve fibres. These nerve fibres extend to the border of the white and the red pulp but not enter the red pulp (Felten *et al.*, 1987; Bellinger *et al.*, 1989). We did not find any adrenergic nerve cells in the pheasant spleen and the nerve cells were not found in the mammalian spleen at all (Bulloch, 1985).

The findings of the adrenergic and AChE-positive nerve fibres in several localizations of the pheasant spleen lead to assume a possible effect of these nerves not only the vessels mentioned but also in terms of their direct effect on the spleen cells and the splenic capsule. The presence of both demonstrated nerve fibres in

the periarterial lymphatic sheath indicate that adrenergic and cholinergic innervation participates in modulation of the immune responses. Although there appears to be an immunoregulatory relationship between splenic immune function and the autonomic nervous system, definitive evidence has yet to be provided.

The present results support the concept that the autonomic nervous system is a fundamental mediator of neuro-immune interactions.

References

- Ader, R., D. Felten and N. Cohen, 1990. Interactions between the brain and the immune system. *Ann. Rev. Pharmacol. Toxicol.*, 30: 561-602.
- Bellinger, D.L., D. Lorton, R.W. Hamill, S.Y. Felten and D.L. Felten, 1993. Acetylcholinesterase staining and choline acetyltransferase activity in the young adult rat spleen: Lack of evidence for cholinergic innervation. *Brain Behav. Immun.*, 7: 191-204.
- Bellinger, D.L., S.Y. Felten, D. Lorton and D.L. Felten, 1989. Origin of noradrenergic innervation of the spleen in rats. *Brain Behav. Immun.*, 3: 291-311.
- Bulloch, K., 1985. *Neuroanatomy of Lymphoid Tissue: A Review*. In: *Neural Modulation of Immunity*, Guillemin, R., M. Cohn and T. Melnechuk (Eds.). Raven Press, New York, pp: 111-141.
- Carlson, S.L. and D.L. Felten, 1989. Involvement of Hypothalamic and Limbic Structures in Neural-Immune Communication. In: *Neuroimmune Networks: Physiology and Diseases*, Goetz, E.J. and N.H. Spector (Eds.). Liss, New York, pp: 219-226.
- El-Badawi, A. and E.A. Schenk, 1967. Histochemical methods for separate, consecutive and simultaneous demonstration of acetylcholinesterase and norepinephrine in cryostat sections. *J. Histochem. Cytochem.*, 15: 580-588.
- Felten, D.L., S.Y. Felten, D.L. Bellinger, S.L. Carlson and K.D. Ackerman *et al.*, 1987. Noradrenergic sympathetic neural interactions with the immune system: Structure and function. *Immunol. Rev.*, 100: 225-260.
- Fillenz, M., 1970. The innervation of the cat spleen. *Proc. Royal Soc. London B: Biol. Sci.*, 174: 459-468.
- Hodges, R.D., 1974. *The Histology of the Fowl*. Academic Press, London, Pages: 649.
- Reilly, F.D., 1985. Innervation and vascular pharmacodynamics of the mammalian spleen. *Experientia*, 41: 187-192.
- Schmidtova, K., E. Banovska and M. Miklosova, 1995. Development and distribution of acetylcholinesterase (ACHE)-positive nerve fibres in the spleen of rats and chicken. *Folia Vet.*, 39: 75-77.
- Shvalev, V.N. and N. Zhuckova, 1987. An improvement in histochemical findings in adrenergic nerve elements in glyoxylic acid solution with the aid of dimethylsulphoxide (DMSO). *Arkh. Anat.*, 93: 91-92.