

<http://www.pjbs.org>

PJBS

ISSN 1028-8880

Pakistan Journal of Biological Sciences

ANSI*net*

Asian Network for Scientific Information
308 Lasani Town, Sargodha Road, Faisalabad - Pakistan

Faecal Moisture Content, Intestinal Length and Organ Weight of Rats Fed on Faba Bean Seeds

M.G. Mortuza and N. Newaz

Department of Biochemistry, Bangladesh Agricultural University, Mymensingh, Bangladesh

Abstract: The comparative nutritional performance study of two varieties of faba beans (*Vicia faba* L.), Kalimatar and white faba bean was carried out in young rats (*Rattus norvegicus*) fed *ad libitum* on 10% protein source for 21 days. Effect of faba bean diets on faecal moisture content, intestinal length and dry weight of different organs of rats (g/100 g) were studied. The dry weight of liver of rats of experimental groups decreased and that of pancreas, colon and small intestine increased as compared to control group. Intestinal length and faecal moisture content of rats fed on locally grown faba bean were the highest among all groups under tested while the moisture content of faeces of rats fed on exotic faba bean diet was the lowest. The study also revealed a differential nutritional response of rats to two varieties of faba beans and is apparent that locally grown Kalimatar is nutritionally better than exotic white faba bean.

Key words: *Vicia faba*, rats and organ, nutritional performance, kalimatar

Introduction

Bangladesh like many other developing countries of the third world is confronted with serious problems of protein-calorie-malnutrition. The increasing demand for protein for human and animal consumption and the high price of animal sources such as meat and fish have resulted in increased demand of legumes as a source of dietary protein and calorie. But the conventional legumes grown in our country (lentil, khesari, mung, pea, blackgram, horsegram etc.) can only supply the fraction of the requirements of protein. Because, their seed size is very small and yield/ha is quite low. In this regard we have to select some other legume which should be of large size and high yield. From this view point faba bean (*Vicia faba*), locally called kalimatar which is somewhat different from exotic variety in respect of seed size and seed colour, may occupy the important position.

Since this kalimatar contains a substantial amount of protein ranging from 23 to 27 percent (Mortuza *et al.*, 2000; Newaz and Newaz, 1986 a and b), therefore this crop would undoubtedly play an important role in protein supplementation and crop diversification programme in Bangladesh. Studies on protein nutritive value and haemato-biochemical changes in rats fed on raw kalimatar seeds have already been carried out (Mortuza *et al.*, 1997, 2000). However, the consumption of legume seeds in raw form can produce serious physiological alterations, usually accompanied by impairment of growth (Larraide, 1982). As the nutritional data of this legume (kalimatar) are lacking, present work was designed to observe the effect of this raw seeds ingestion on different organ of rats and their faecal moisture content as compared to that of its exotic counterpart.

Materials and Methods

Seeds of two varieties of faba bean were obtained from experimental field laboratory of Genetics and Plant Breeding Department of Bangladesh Agricultural University, Mymensingh on May, 1999. Fifty days old Long-Evans male young rats were obtained from animal unit of ICDDR,B, Dhaka and randomly divided into three groups, each containing four. Cotyledon was separated manually and ground and diets were formulated to contain 10% protein. Groups of rats in two replications were fed the experimental or control diet (standard skimmed-milk protein) *ad libitum* for 21 days. The animals were housed in a Perspex cages with aluminum rod on the bottom fixed 1 inch apart to facilitate the faeces and spillage

in a room maintaining 23 ± 1 °C. Rats were adapted for 7 days before commencement of animal trial giving standard rat-pelletate. Faecal samples were collected daily and stored at 20°C until required. Faecal samples were oven-dried and moisture percentage was calculated.

At the end of 21 days feeding rats were fasted overnight and killed by ether anaesthesia overdose. Most of the organs and tissues to be examined were excised, rinsed in distilled water, blotted dry and frozen. The gastrointestinal tract was separated into its constituent parts, food and faecal residues were washed out with water and tissues were then blotted dry, weighed and immediately frozen.

All the organs and tissues and the remaining carcass were then oven dried (70 °C) and weighed again to estimate the proportional weight of organs/100g dry body weight for individual rats.

Statistical analysis were done by ANOVA using Minitab statistical software package (Minitab, Inc., 3081 Enterprise Drive, State College, PA 16801, USA). When P values were <0.05, the significance of difference between groups were calculated by student's t-test.

Results and Discussion

The dry weight of the small intestine increased in rats fed on cotyledon obtained from both white and black cultivars compared to that of control rats (Table 1). This increase suggested deposition of some materials on or into this tissue. Pusztai *et al.* (1986) suggested that plant lectins, particularly those noted for their resistance to proteolytic breakdown in the gut are known to react with both the luminal content and epithelial cells. They induced a two-fold increase in small intestinal mass within 10 days, which was due to increased mucinous secretion and cellular hyperplasia (Greer *et al.*, 1985). Although, the real mechanism of this increase could not be explained from the present experiments, infiltration of proliferative lymphocytes in the lamina propria of the gut may give a possible explanation for the dry weight increase of the intestine.

Alternatively, an increase in polyamine such as putrescine, spermidine and spermine (Siedel *et al.*, 1984) and dimethylamine (Dembinski *et al.*, 1984) may have acted as stimulants to cause gut growth in the rats fed on experimental diets. It was suggested that there was a linear relationship between availability of amines and overgrowth of microflora in the gut. Freed and Buckley (1978) proposed that lectin,

Mortuza and Newaz: *Vicia faba*, rats and organ

Table 1: Effect of cotyledon of local and exotic genotype of faba beans on different organs (g/100g dry weight) in rats

Organs	SMP	KMC	VFWC
Liver	3.05±0.10	2.68±0.29*	2.73±0.25*
Kidney	0.73±0.10	0.77±0.04	0.81±0.08
Thymus	0.17±0.03	0.17±0.01	0.16±0.01
Spleen/plea	0.17±0.01	0.18±0.02	0.18±0.01
Stomach	0.26±0.01	0.29±0.03	0.29±0.02
Lungs	0.59±0.01	0.55±0.10	0.57±0.15
Heart	0.27±0.02	0.27±0.09	0.29±0.02
Colon	0.48±0.02	0.61±0.02*	0.64±0.05*
Caecum	0.61±0.05	0.52±0.10	0.55±0.07
Pancreas	0.55±0.02	0.95±0.08*	0.73±0.17*
Intestine	2.83±0.12	2.91±0.14*	3.05±0.18*

* = Significant at 5% level of significance

Note : SMP = Standard skimmed-milk protein (control group)
KMC = 'Kalimatar' cotyledons
VFWC = *Vicia faba* white cotyledons

such as concanavalin A, caused hypersecretion of rat jejunal mucosa. Pusztai and Greer (1984) found that there was an increase of 30-40% in DNA content in rats fed on raw kidney bean, indicating mitogenic stimulation of the enterocytes by the phytohaemagglutinin (lectin) obtained from *Phaseolus vulgaris* (PHA).

An increase in colonic dry weight was observed in rats fed on cotyledon of both cultivars as compared to those obtained from the milk casein protein fed group. These results are in agreement with Goodlad *et al.* (1990), suggesting that dietary fibre can stimulate epithelial cell proliferation in the colon and to a lesser extent in the small intestine through production of short chain fatty acid (SCFA) as in ruminants. Zucoloto *et al.* (1988) demonstrated that epithelial hyperplasia is the result of increased cell production. Some fibre types such as wheat bran, pectin and guar gum induce high crypt cell production per crypt (CCPC) in rats (Jacobs and Lupton, 1984). The mechanism responsible for this effect is not clear. However, it has been demonstrated that the chronic use of wheat bran in the diet, increased the mass of the distal colonic mucosa that appears to be due to the epithelial hyperplasia of the mucosa (Jacobs and White, 1983). The dry weight of liver of rats of experimental groups decreased as compared to that of control rats whereas the dry weight of kidney, thymus, spleen, stomach, lungs, heart and caecum remain unchanged.

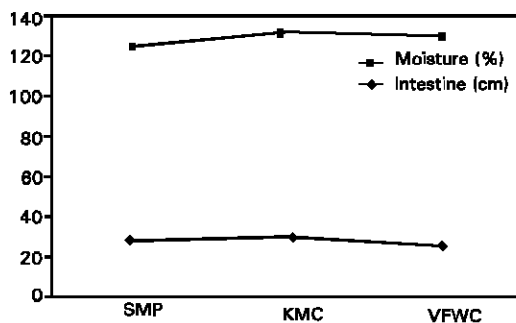


Fig. 1: Effect of cotyledon of local and exotic genotype of faba beans on faecal moisture content and intestinal length of rats

Note: SMP = Standard skimmed-milk protein
KMC = Kalimatar cotyledons
VFWC = *Vicia faba* white cotyledons

Faecal moisture content and intestinal length of rats of experimental as well as control group are summarized in (Fig. 1). The moisture content of rats fed on raw kalimatar cotyledon was the highest among all groups while that of rats fed on white faba bean cotyledon was the lowest. This result indicates that kalimatar cotyledon contains higher amount of fibre which passes through intestine in an undigested form and stores at caecum to increase the bulk volume of faeces containing more water. Intestine of rats of both experimental groups increased in length compared to that of control group. From this feeding trail it seems that locally grown kalimatar is nutritionally superior to its exotic counterpart.

References

- Dembinski, A.B., T. Vamaguchi and L.R. Johnson, 1984. Stimulation of mucosal growth by a dietary amine. *Am. J. Physiol.*, 247: G352-G356.
- Freed, D.L.J. and C.H. Buckley, 1978. Mucottractive effect of lectin. *Lancet* I: 585-586.
- Goodlad, R.A., B. Ratcliffe, J.P. Fordham and N.A. Wright, 1990. Fibre and intestinal cell proliferation in dietary fibre. In "Chemical and Biological aspects". Eds: Southgate, D.A.T., Waldran, K., Johnson, I.T., Royal Soc. Chem., Cambridge, pp: 173-177.
- Greer, F., A.C. Brewer and A. Pusztai, 1985. Effect of kidney bean (*Phaseolus vulgaris*) toxin on tissue weight and composition and some metabolic functions of rats. *Brit. J. Nutr.*, 54: 95-103.
- Jacobs, L.R. and F.A. White, 1983. Modulation of mucosal cell proliferation in the intestine of rats fed a wheat bran diet. *Am. J. Clin. Pathol.*, 37: 945-953.
- Jacobs, L.R. and J.R. Lupton, 1984. Effect of dietary fibers on rat large bowel mucosal growth and cell proliferation. *Am. J. Physiol.*, 9: G378-G385.
- Laralde, J., 1982. Estudio de algunos trastornos que se presentan en los animales por ingestion de *Vicia faba*. *Revista Espanola de Fisiologia*, 38: 345-348.
- Mortuza, M.G., N. Newaz, M.A. Islam and P.K. Roy, 1997. Haemato-biochemical parameters of rats fed on faba bean (*Vicia faba* L.). *Prog. Agric.*, 8: 5-8.
- Mortuza, M.G., N. Newaz, A. Hossain and M.H. Rahman, 2000. Nutritional response of rats to faba beans (*Vicia faba* L. minor black "Kalimatar") and its fractions. *Int. J. Food Sci. Nut.*, 51: 5-9.
- Mosley, G. and D.D. Griffiths, 1979. Varietal variation in antinutritive effects of field beans (*Vicia faba*) when fed to rats. *J. Sci. Food Agric.*, 30: 772-778.
- Newaz, N. and M.A. Newaz, 1986a. Functional properties of faba bean seed flour. *FABIS (ICARDA, Syria)* 15: 55-56.
- Newaz, N. and M.A. Newaz, 1986b. Chemical composition of faba bean seed and the effect of cooking on major nutrients. *Bangla. Hort.*, 14: 44-46.
- Pusztai, A. and F. Greer, 1984. Effects of dietary legume proteins on the morphology and secretory responses of the rat small intestine. *Protides of the Biol. Fluids.*, 32: 347-350.
- Pusztai, A., G. Grant and J.T.A. de Olivera, 1986. Local (gut) and systemic responses to dietary lectins. *IRCS. Med. Sci.*, 14: 205-208.
- Sedel, E.R., M.K. Haddox and L.R. Johnson, 1984. Polyamine in the response to intestinal obstruction. *Am. J. Physiol.*, 246: G649-G653.
- Zucoloto, S., J.A. Diaz, J.S.M. Oliveira, G. Muccilo, V.N. Sales-Neto and J.K. Kajiwara 1988. Effect of chemical ablation of myenteric neurons on intestinal cell proliferation. *Cell and Tissue Kinetics*, 21: 213-219.