

<http://www.pjbs.org>

PJBS

ISSN 1028-8880

**Pakistan
Journal of Biological Sciences**

ANSI*net*

Asian Network for Scientific Information
308 Lasani Town, Sargodha Road, Faisalabad - Pakistan

Immuno Histochemistry of Cholesterol Cleft Granulomas in Non-specific Interstitial Pneumonia

¹Abolfazl Barkhordari, ²R.W. Stoddart, ²Sheena F. McClure and ²John McClure

¹Department of Occupational Health, Faculty of Health,

Shaheed Sadoughi University of Medical Sciences, Yazd, Iran

²The Medical School, Department of the Laboratory Medicine Academic Group,
The University of Manchester, UK

Abstract: This study aimed to define the cell populations involved in the granulomas. The granulomas of 16 patients with cryptogenic fibrosing alveolitis (five cases with the histological features of Non-specific Interstitial Pneumonia (NSIP), five with those of UIP and six cases of respiratory bronchiolitis) were examined histologically and by the use of immunohistochemical markers. Granulomas were discrete, compact and present only in alveolar spaces. The granulomas contained central clefts surrounded by mononuclear and multinucleated giant cells, both of which were CD68 positive. The cells outside the granulomas and those lining the adjacent alveolar walls were AE1/AE3 and CAM5.2 positive and CD68 negative. Our observations indicate that cholesterol cleft granulomas occur with high frequency in NSIP, are present within alveolar spaces which are lined exclusively by type II pneumocytes and that external to this the interstitium is fibrotic with accumulations of mast cells. It is our speculation that these are linked in a pathogenetic mechanism related to the progression of NSIP. The results also suggest that the mononuclear and multinucleated cells of cholesterol cleft granulomas are derived from the macrophage-mononuclear cell lineage. The alveolar lining cells are type II pneumocytes which do not contribute to the granuloma cell population. The alveolar lining cells are type II pneumocytes which do not contribute to the granuloma cell population.

Key words: Cholesterol-cleft granuloma, immunohistochemistry, NSIP

INTRODUCTION

The pathological classification of Idiopathic Pulmonary Fibrosis (IPF) - also known as Cryptogenic Fibrosing Alveolitis (CFA) - has been a matter of difficulty and controversy for histopathologists^[1-5]. A recent classification by Katzenstein and Myers^[6] includes Usual Interstitial Pneumonia (UIP), Desquamative Interstitial Pneumonia (DIP)/Respiratory Bronchiolitis Interstitial Lung Disease (RBILD), Acute Interstitial Pneumonia (AIP, Hamman-Rich disease) and Non-specific Interstitial Pneumonia (NSIP). This last was defined by Katzenstein and Fiorelli^[7] as an idiopathic interstitial pneumonia with a pathological pattern distinct from UIP, DIP and AIP, although cases were first recognised because they could not be included in the first three categories.

In a systematic evaluation of the histopathological features of a series of IPF it is noted that half the cases of NSIP contained large numbers of discrete cholesterol cleft granulomas. Examination of the available literature

revealed few references to these entities in NSIP. In two of the original series (n= 64) of Katzenstein and Fiorelli^[7], loosely formed granulomas, one containing cholesterol clefts, were described. In 12 cases described by Cottin *et al.*^[8] six had small, loosely formed granulomas consisting of a cluster of epithelioid cells, giant cells and cholesterol clefts. Finally, Katzenstein and Myers^[6] refer to rare, focal, poorly formed, non-necrotising granulomas. We were, therefore, prompted to examine the granulomas in our series in detail and to consider their pathogenesis and possible significance.

MATERIALS AND METHODS

Nine formalin-fixed, paraffin-embedded blocks from six cases of NSIP were obtained from the histopathology archive of the Wythenshawe Hospital Manchester. Paraffin-embedded sections (5 µm), cut as near serially as possible, were dewaxed, blocked for endogenous peroxidase, rehydrated and immunostained with the

monoclonal antibodies AE1/AE3, CAM5.2, anti-CD68 and anti-mast cell tryptase as detailed in Table 1. Sections were pre-treated with 0.03% (w/v) trypsin (type II, porcine, Sigma) stained directly with anti-CD68 and indirectly with AE1/AE3, CAM5.2 and anti-tryptase using the avidin-biotin method^[9] with 3-3-diaminobenzidine tetrahydrochloride as the substrate and Mayer's haematoxylin as the counterstain.

RESULTS AND DISCUSSION

Half of the cases studied exhibited the presence of numerous dispersed cholesterol cleft granulomas. These were discrete, compact, uniform in size and present mostly in areas of alveolar wall thickening. The granulomas were universally present in alveolar spaces. They were never observed within alveolar walls nor in relationship to blood vessels. Typically the granulomas contained central clefts (mean length 52.6 µm, range 18.0-109.3 µm) surrounded by mono- and multinucleated cells which were CD68 positive, whereas the cells outside the granulomas and lining the alveolar walls were negative with this antibody (Fig. 1). In contrast these latter cells were both AE1/AE3 and CAM5.2 positive (Fig. 2). Elsewhere, in alveolar spaces not containing granulomas, there were occasional small populations of alveolar macrophages also showing CD68 positivity.

Anti-mast cell tryptase positive cells were present in the alveolar wall interstitium, frequently close to the lining cells, but never within the alveolar space nor in intimate relationship to the granulomas.

The most characteristic feature of NSIP is that the lesions are temporally uniform^[6], in distinction to the temporal heterogeneity of UIP. NSIP was originally defined by the exclusion of cases that could not be placed in the other well-defined categories of IPF. The presence of cholesterol cleft granulomas was a distinctive feature of half of total cases of NSIP. The granulomas were well defined with central clefts surrounded by macrophages and macrophage polykaryons. The granulomas were compact and confined to spaces lined clearly and separately from the cells of the granuloma, by a complete

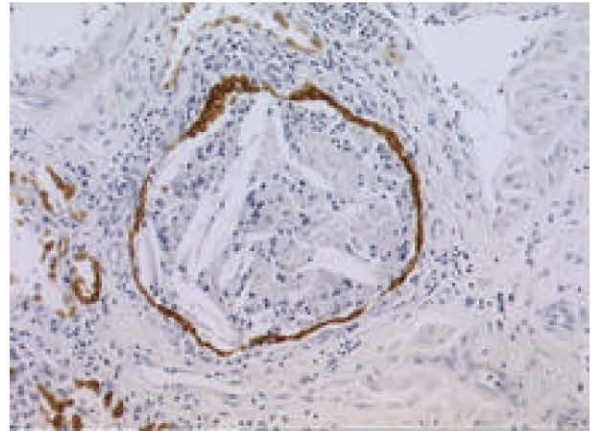


Fig. 1: Strong staining of type II pneumocytes (T2) and cholesterol cleft granuloma Lining Cells (LC) with CAM5.2

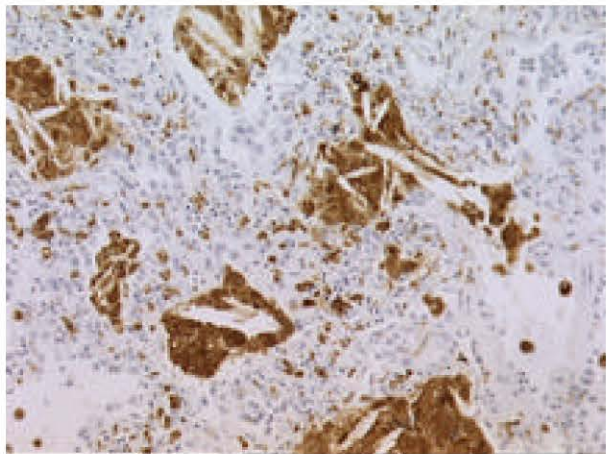


Fig. 2: Strong staining of mono- and multinucleated giant cells with anti-CD68

single layer of type II pneumocytes. Outside this, the interstitium was fibrotic and contained a population of mast cells demonstrable by anti-tryptase immunostaining. Immunopositive material had apparently diffused outside the cell boundaries suggesting tryptase release. Mast cells were never seen within the granulomas although an occasional cell was present in the type II pneumocyte lining and in the space between this lining and the cells of the granuloma.

Granulomatous inflammation to cholesterol crystal clefts has been described in a number of pulmonary disorders including idiopathic cholesterol pneumonitis^[10-12] and as a secondary phenomenon in bronchiectasis, chronic lung abscess and tuberculosis^[13-15]. The source of the cholesterol is likely to be pulmonary surfactant. In an electron microscopical

Table 1: The names and details of the antibodies

Antibody	Dilution	Reactivity	Control tissue	Source
AE1/AE3	1:50	Human epidermal keratin	Skin	Dako
CAM5.2	Neat	Cytokeratins 8,18,19	Tonsil	BD Biosciences
Anti CD68 (EBM11)	Neat	Macrophages	Tonsil	Dako
Anti mast cell tryptase (AA1)	1:100	Mast cells	Tonsil	Novocastra Laboratories Ltd.

study of lung tissue from heavy cigarette smokers Corrin and Soliman^[16] found cholesterol crystal clefts in the cytoplasm of type II pneumocytes. Lipid extracts of bovine pulmonary surfactant contained 3% neutral lipid mainly as cholesterol and diacylglycerol and 97% phospholipids^[17]. The giant cells commonly seen in granulomas are considered to be macrophage polykaryons formed by the fusion of alveolar macrophages attached to the same endocytic material^[18].

Whilst exogenous cytokines are influential in granuloma formation and activity, endogenous production of cytokines also occurs. Human non-caseating pulmonary tuberculous granulomas contain CD68 positive macrophage-like cells which produce mRNA for TNF- α , IFN- γ and IL-4 and these are likely to have functional significance^[19]. Currently there are no available data on cytokine elaboration by pulmonary cholesterol cleft granulomas.

This immunohistochemical study confirmed that the intra-alveolar cell populations in NSIP were composed predominantly of CD68 positive cells. It showed that the giant cells were also CD68 positive, but were cytokeratin negative. In contrast, the cells lining the alveolar spaces containing granulomas were cytokeratin positive (AE1/AE3 and CAM5.2), indicating that these were type II pneumocytes and showing that these cells had completely replaced type I cells at these loci. In addition, it is known that macrophages and macrophage polykaryons have distinctive glycoprofiles and that pneumocytes types I and II can be distinguished by their profiles^[20-22].

In summary, present observations indicate that cholesterol cleft granulomas occur with high frequency in NSIP, are present within alveolar spaces which are lined exclusively by type II pneumocytes and that external to this the interstitium is fibrotic with accumulations of mast cells. It is our speculation that these are linked in a pathogenetic mechanism related to the progression of NSIP. The results also suggest that the mononuclear and multinucleated cells of cholesterol cleft granulomas are derived from the macrophage-mononuclear cell lineage. The alveolar lining cells are type II pneumocytes which do not contribute to the granuloma cell population.

ACKNOWLEDGMENTS

This study supported by the Iranian Ministry of Health and Medical Education and performed in the Department of the Laboratory Medicine Academic Group, The Medical School, The University of Manchester, UK

REFERENCES

1. Maheshwari, U., D. Gupta, A.N. Aggarwal and S.K. Jindal, 2004. Spectrum and diagnosis of idiopathic pulmonary fibrosis. *Indian. J. Chest. Dis. Allied Sci.*, 46: 23-26.
2. Selman, M., V.J. Thannickal, A. Pardo, D.A. Zisman, F.J. Martinez and J.P. Lynch, 2004. III: Idiopathic pulmonary fibrosis: Pathogenesis and therapeutic approaches. *Drugs*, 64: 405-430.
3. Williams, K., D. Malarkey, L. Cohn, D. Patrick, J. Dye and G. Toews, 2004. Identification of spontaneous feline idiopathic pulmonary fibrosis: Morphology and ultrastructural evidence for a type II pneumocyte defect. *Chest*, 125: 2278-2288.
4. Flaherty, K.R., W.D. Travis, T.V. Colby, G.B. Toews, E.A. Kazerooni and B.H. Gross *et al.*, 2001. Histopathologic variability in usual and nonspecific interstitial pneumonias. *Am. J. Respir. Crit. Care. Med.*, 164: 1722-1727.
5. Takahashi, H., T. Fujishima, H. Koba, S. Murakami, K. Kurokawa and Y. Shibuya *et al.*, 2000. Serum surfactant proteins A and D as prognostic factors in idiopathic pulmonary fibrosis and their relationship to disease extent. *Am. J. Respir. Crit. Care. Med.*, 162: 1109-1114.
6. Katzenstein, A.L.A. and J.L. Myers, 1998. Idiopathic pulmonary fibrosis: Clinical relevance of pathologic classification. *Am. J. Respir. Crit. Care. Med.*, 157: 1301-1315.
7. Katzenstein, A.L.A. and R.F. Fiorelli, 1994. Nonspecific interstitial pneumonia/fibrosis: Histological features and clinical significance. *Am. J. Surg. Pathol.*, 18: 136-147.
8. Cottin, V., A.V. Donsbeck, D. Revel, J.F. Loire and J.F. Cordier, 1998. Non-specific interstitial pneumonia: individualization of a clinicopathologic entity in a series of 12 patients. *Am. J. Respir. Crit. Care. Med.*, 158: 1286-1293.
9. Guesdon, J.L., T. Ternynck and S. Avrameas, 1979. The use of avidin-biotin interaction in immunoenzymatic techniques. *J. Histochem. Cytochem.*, 27: 1131-1139.
10. Waddell, W.R., R.C. Sniffen, and L.L. Whytehead, 1949. Chronic pneumonitis: Its clinical and pathological importance. *J. Thorac. Surg.*, 28: 134-144.
11. De Navasquez, S. and G.A.D. Haslewood, 1954. Endogenous lipid pneumonia with special reference to carcinoma of the lung. *Thorax*, 9: 35-37.
12. Reid, J.D., A.P. Oliver and P.C. Cairney, 1961. Cholesterol pneumonitis. *N.Z. Med. J.*, 60: 134-143.

13. Corrin, B. and S.S. Soliman, 1973. Cholesterol in the lungs of heavy cigarette smokers. *Thorax*, 33: 565-568.
14. Yu, S., P.G. Harding, N. Smith and F. Possmayer, 1983. Bovine pulmonary surfactant: Chemical composition and physical properties. *Lipids*, 18: 522-529.
15. Chambers, T.J. and W.G. Spector, 1982. Inflammatory giant cells. *Immunobiology*, 161: 283-289.
16. Warfel, A.H. and J.W. Hadden, 1978. Macrophage fusion factor elicited from BCG-sensitized lymphocytes. *Am. J. Pathol.*, 93: 753-770.
17. McNally, A.K. and J.M. Anderson, 1995. Interleukin-4 induces foreign body giant cells from human monocytes/macrophages: Differential lymphokine regulation of macrophage fusion leads to morphological variants of multinucleated giant cells. *Am. J. Pathol.*, 147: 1487-1499.
18. DeFife K.M., C.R. Jenney, A.K. McNally, E. Colton and J.M. Anderson, 1997. Interleukin-13 induces human monocyte/macrophage fusion and macrophage mannose receptor expression. *J. Immunol.*, 158: 3385-3390.
19. Fenhalls, G. *et al.*, 2000. In situ production of gamma interferon, interleukin-4 and tumor necrosis factor alpha mRNA in human lung tuberculous granulomas. *Infect. Immun.*, 68: 2827-2836.
20. Barkhordari, A., R.W. Stoddart, S.F. McClure and J. McClure, 1999. Cellular glycotypes in pulmonary sarcoidosis. *J. Pathol.*, 189: 24A.
21. Barkhordari, A., R.W. Stoddart, S.F. McClure and J. McClure, 2000. Lectin binding profiles of pneumocytes in normal human lung. *J. Pathol.*, 190: 54A.
22. Barkhordari, A., R.W. Stoddart, S.F. McClure and J. McClure, 2004. Lectin histochemistry of normal human lung. *J. Mol. Histol.*, 35: 147-156.