

<http://www.pjbs.org>

**PJBS**

ISSN 1028-8880

**Pakistan  
Journal of Biological Sciences**

**ANSI***net*

Asian Network for Scientific Information  
308 Lasani Town, Sargodha Road, Faisalabad - Pakistan

## Adenomatous Lesion in a Pneumonic Lung of a Local Indigenous Saudi Goat

F.A. Al-Hizab and E.B. Abdelsalam

Department of Pathology, College of Veterinary Medicine and Animal Resources, King Faisal University,  
P.O. Box 1757, Al-Ahsa, 31982, Kingdom of Saudi Arabia

**Abstract:** Multiple foci of adenomatous proliferations of the bronchiolo-alveolar epithelium were incidentally detected in the lung of a relatively old female goat of a local breed suffering from acute fibrinous pleuropneumonia. The adenomatous foci were randomly embedded within the pneumonic portions of the lung without clear demarcation from the surrounding tissues. The alveoli in these foci were lined by proliferating cuboidal cells forming irregular folds and papillary projections resembling those observed in ovine pulmonary adenomatosis or jaagsiekete. However, this particular lesion was not grossly detected and apparently masked by focal adhesions with extensive consolidation and necrotic alterations on the lung parenchyma. Although pulmonary adenomatosis has not yet been reported in the Saudi Kingdom but the present observation may well provide a preliminary view on the possible existence of the disease.

**Key words:** Adenomatosis, adenocarcinoma, jaagsiekete, lung, goats

### INTRODUCTION

Neoplastic transformation of the bronchiolo-alveolar epithelium is a distinctive feature of a slow-developing respiratory viral disease of adult sheep known as Ovine Pulmonary Adenomatosis (OPA). This disease has long been recognized in South Africa by the local name of Jaagsiekete which literary means drive sickness<sup>[1]</sup>. However, the disease was later on found to have a world-wide distribution<sup>[2-6]</sup>. The aetiological agent of the disease is well established to be an oncogenic type D-related retrovirus designated as Jaagsiekete Sheep Retrovirus (JSRV)<sup>[7,8]</sup>. This virus is highly specific for sheep although goats are also affected in some occasions<sup>[9]</sup>. The incidence of ovine pulmonary adenomatosis does not seem to be so far documented in the Arabian Peninsula despite the significant role of sheep and goats in the routine life of various nomadic tribes in the area. Nevertheless, the present report describes an incidental observation of multiple foci of adenomatous proliferations of the bronchiolo-alveolar epithelium in the right lung of a local Saudi goat severely affected with fibrinous pleuropneumonia. The morphological features of these foci were closely similar to those consistently observed in natural and experimental cases of ovine pulmonary adenomatosis.

### MATERIALS AND METHODS

The material of this report comprises an ordinary necropsy case submitted for routine post-mortem examination at the Department of Pathology, College of Veterinary Medicine, King Faisal University. The case was a relatively old (4 years) female goat of a local breed (Ardi) with a clinical history of fever, anorexia and persistent respiratory distress accompanied by intermittent cough and copious nasal discharge. The attached clinical diagnosis indicated acute bronchopneumonia that did not respond to heavy antibiotic treatment. A detailed post-mortem examination was carried out with more emphasis on the respiratory system. The lungs, heart and trachea were removed and carefully examined. The significant gross lesions were well described and recorded. Representative samples of the lung tissue were immediately collected and fixed in 10% formalin solution for routine histological processing and staining with Haematoxylin and Eosin (H&E) as described by Drury and Wallington<sup>[9]</sup>.

### RESULTS

**Gross pathology:** Examination of the chest revealed moderate amount of a straw-coloured fluid in the thoracic

**Corresponding Author:** Dr. F.A. Al-Hizab, Department of Pathology, College of Veterinary Medicine and Animal Resources, King Faisal University, P.O. Box 1757, Al-Ahsa 31982, Kingdom of Saudi Arabi  
E-mail: alhizab@hotmail.com

and pericardial cavities. The pleural and pericardial surfaces were considerably thickened and covered with gelatinous fibrinous exudate forming focal adhesions with the thoracic wall. The right lung was extensively involved particularly, the entire apical lobe, intermediate and almost half of the diaphragmatic lobe. The affected parts of the lung were remarkably consolidated, grey-brown in colour and covered with tangled masses of fibrinous strands. The cut surface was extremely firm in consistency and contained scattered areas of coagulative necrosis. The left lung was, on the other hand, diffusely congested and oedematous with a limited portion of dark-grey consolidation on the ventral part of the apical lobe. The mediastinal and bronchial lymph nodes were very much enlarged, congested, oedematous and occasionally haemorrhagic.

**Histopathology:** The histological examination of selected sections of the affected lung tissue showed typical alterations of acute fibrinous bronchopneumonia with fibrinous pleurisy (pleuropneumonia). The pleural surface was considerably thickened with abundant fibrinous deposits and heavy infiltration of inflammatory cells, mainly neutrophils (Fig. 1). The alveoli were also stuffed with fibrinous exudate and inflammatory cells (Fig. 2). The bronchi and bronchioles were occasionally involved with severe inflammatory alterations manifested by fibrinous exudation, cellular infiltration and hyperplasia of peribronchial lymphoid cells. In addition, discrete areas of coagulative necrosis surrounded by dense cellular infiltration were also observed. These inflammatory alterations were further accompanied with severe vascular reactions dominated by widespread capillary congestion,

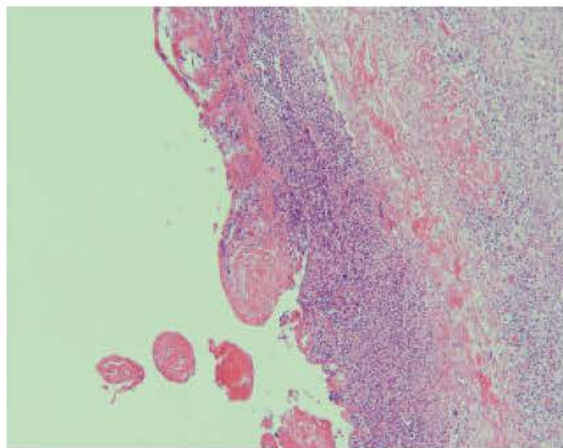


Fig. 1: Thickening of pleural surface with fibrinous exudate and inflammatory cells mainly neutrophils (H&EX150)

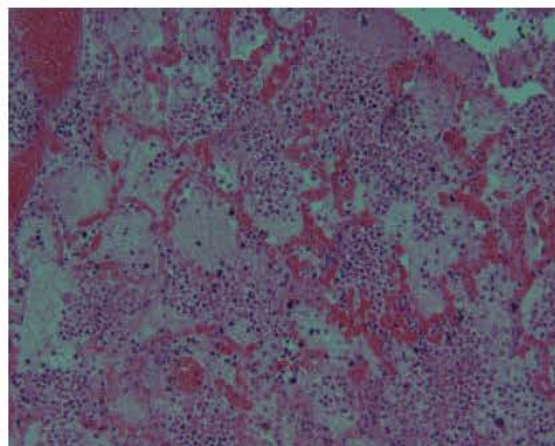


Fig. 2: Fibrinous pneumonia. The alveoli are stuffed with fibrin and inflammatory cells (H&E X 250)

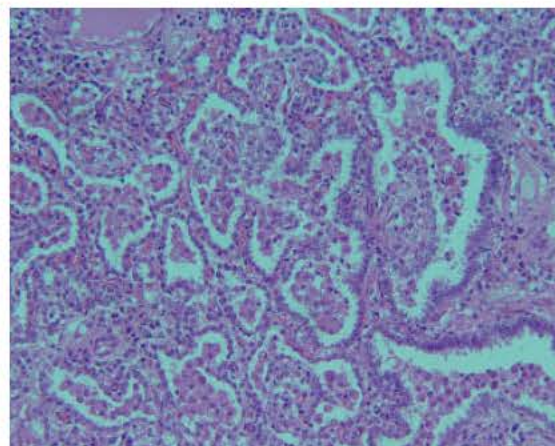


Fig. 3: Adenomatous proliferation of the alveolar epithelium. Note the presence of large number of foamy macrophages (H&E X 205)

haemorrhage and thrombosis of blood vessels and lymphatics. However, an interesting finding was the presence of multiple foci of adenomatous proliferations of the alveolar epithelium embedded within the pneumonic parts of the lung tissue. The affected alveoli in these areas were lined by proliferating cuboidal cells forming irregular folds and papillary projections (Fig. 3 and 4). Some of these projections tend to partially, or completely occlude the lumen of many alveoli. In addition, variable numbers of closely packed foamy macrophages were present inside the affected alveoli. The bronchi and bronchioles were less affected and only showed mild hypertrophy and hyperplasia of the lining epithelium (Fig. 5). Other alterations comprised chronic inflammatory reactions dominated by diffuse fibroplasia together with scattered

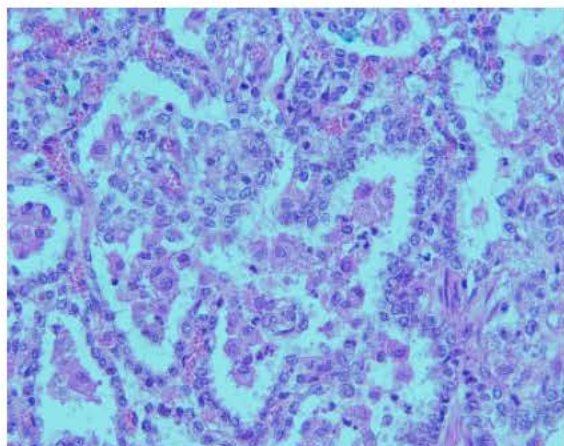


Fig. 4: Higher magnification of Fig. 3. The alveoli are lined with cuboidal cells forming papillary projections (H&E X 400)

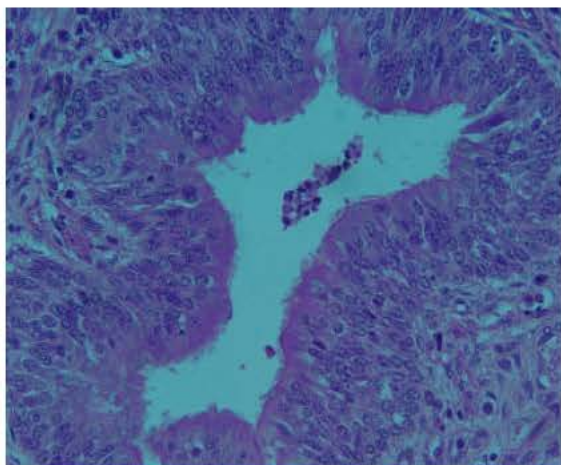


Fig. 5: Mild hypertrophy and hyperplasia of the bronchial epithelium (H&E X 500)

myxomatous changes and mononuclear cellular infiltration on the interstitial tissue.

#### DISCUSSION

In the present communication, multiple foci of adenomatous proliferations of the bronchiolo-alveolar epithelium were detected in the lung of an old female goat suffering from acute fibrinous pleuropneumonia. The histopathological alterations of these foci were characterized by cuboidal transformation and papillomatous proliferation of the alveolar epithelium in such a manner typically resembling those observed in ovine pulmonary adenomatosis<sup>[4,10,11]</sup>. Other parts of the affected lung showed classical inflammatory changes

indicative of acute fibrinous bronchopneumonia with fibrinous pleurisy. However, these adenomatous foci were not detected grossly because they were deeply embedded within the pneumonic portion of the lung which was severely consolidated and covered with fibrinous strands and focal adhesions with the thoracic wall. The present case thus represents a complicated condition of caprine pleuropneumonia combined with multifocal adenomatous proliferation of the bronchiolo-alveolar epithelium. The presence of these proliferative foci in the lung tissue is highly indicative of pulmonary adenomatosis despite the lack of reliable information on the incidence of this particular disease in Saudi Arabia. It has been observed that pulmonary adenomatosis may not necessarily occur as a single non-complicated disease entity and the coexistence of the disease with other types respiratory tract infections in the same animal has repeatedly been reported<sup>[2,13]</sup>.

Details of histopathological features of ovine pulmonary adenomatosis have been extensively described in natural and experimental situations<sup>[5,10,14,15]</sup>. The major alterations in the affected lungs were dominated by neoplastic proliferation of type II pneumocytes and nonciliated bronchiolar epithelial cells (Clara cells). In fact, the neoplastic nature of this disease has long been confirmed on molecular and morphological basis and also by frequent local metastasis to the bronchial and mediastinal lymph nodes<sup>[6]</sup>. Furthermore, the disease was recently proposed to have the name of ovine pulmonary adenocarcinoma<sup>[7]</sup>. It is worth mentioning that ovine pulmonary adenomatosis is the only infectious carcinoma, so far, recognized in domestic animals. This unique ovine tumour was found to have a remarkable morphological resemblance with an analogous pulmonary tumour in humans known as bronchioalveolar carcinoma (BAC)<sup>[8-20]</sup>. The aetiological agent of the human bronchioalveolar carcinoma was also suggested to be a retrovirus closely related to JSRV<sup>[20]</sup>.

It is therefore concluded that the present observation provides a preliminary histological evidence of the possible existence of pulmonary adenomatosis in Saudi Arabia. The disease might well be present and misdiagnosed due to the limited laboratory facilities in the remote sheep and goat raising areas across the extended arid land in the Saudi Kingdom.

#### ACKNOWLEDGMENT

We are very much grateful to our senior technician Mr. Mufleh Al Shahrani for his skilful technical assistance in histopathology.

**REFERENCES**

1. Cowdry, E.V., 1925. Studies on the aetiology of jaagsiekte. *J. Exp. Med.*, 42 : 323-345
2. Cutlip, R.C. and S.Young, 1982. Sheep Pulmonary Adenomatosis (Jaagsiekte ) in the United States. *Am. J. Vet. Res.*, 43: 2108-2113.
3. Hunter, A.R. and R. Munro, 1983. The diagnosis, occurrence and distribution of sheep pulmonary adenomatosis in Scotland 1975 to 1981. *Br. Vet. J.*, 139: 153-164.
4. Ali, O.A. and E.B. Abdelsalam, 1999. Sheep Pulmonary adenomatosis (jaagsiekte) in Libya: Gross and histopathological evidence. *Revue Elev. Med. Vet. Pays. Trop.*, 52: 181-183.
5. Sharp, J.M. and J.C. DeMartini, 2003. Natural history of JSRV in sheep. *Curr. Top. Microbiol. Immunol.*, 275: 55-79.
6. Uzal, F.A., G. Delhon, P.R. Muricia, M. Delas Heras, L. Lujan, M.E. Fernandez Miyakawa, W.E. Morris and M.J. Gonzalez, 2004. Ovine pulmonary adenomatosis in Patagonia, Argentina. *Vet. Res. Commun.*, 28: 159-170.
7. York, D.F., R. Vigne, D.W. Verwoerd and G. Querat, 1991. Isolation, identification and partial DNA cloning of genomic RNA of jaagsiekte retrovirus, the aetiological agent of sheep pulmonary adenomatosis. *J. Virol.*, 65: 5061-5067.
8. Palmarini, M. and H. Fan, 2001. Retrovirus-induced ovine pulmonary adenocarcinoma, an animal model for lung cancer. *J. Natl. Cancer Inst.*, 39: 1603-1614.
9. Drury, R.A.B. and E.A. Wallington, 1980. Carleton's Histological Technique. 5th Edn., Oxford University Press.
10. Sharp, J.M., 1987. Sheep pulmonary adenomatosis: A contagious tumour and its causes. *Cancer Surv.*, 6: 73-83.
11. Rosadio, R.H., J.M. Sharp, M.D. Lairamore, J.E. Dahalberg and J.C. DeMartini, 1988. Lesions and retroviruses associated with naturally occurring ovine pulmonary carcinoma (sheep pulmonary adenomatosis ).*Vet. Pathol.*, 25: 58-66.
12. Snyder, S.P., J.C. De Martini, E. Ameghino and E. Calitte, 1983. Coexistence of pulmonary adenomatosis and progressive pneumonia in sheep in central Sierra of Peru. *Am. J. Vet. Res.*, 44: 1334-1338.
13. DeMartini, J.C., R.H. Rosadio, J.M. Sharp, H.I. Russell and M.D. Laimore., 1987. Experimental coinduction of type D retrovirus-associated pulmonary carcinoma and lentivirus-associated lymphoid interstitial pneumonia in lambs. *J. Natl. Cancer Inst.*, 79: 167-177.
14. Garcia-Goti, M., L.Gonzalez, C. Cousens, N. Cortabarría, A.B. Extramiana, E. Minguijón, A. Ortíz, M. Delas Heras and J.M. Sharp., 2000. Sheep pulmonary adenomatosis: characterization of two pathological forms associated with jaagsiekte retrovirus. *J. Comp. Pathol.*, 122: 55-65.
15. Delas Heras, M., L. Gonzalez and J.M. Sharp, 2003. Pathology of ovine pulmonary adenomatosis. *Curr. Top. Microbiol. Immunol.*, 275: 25-54.
16. Cheville, N.F., 1983. *Cell Pathology*. 2nd Edn., Iowa State University Press, pp: 407.
17. York, D.F. and G. Querat, 2003. A history of ovine pulmonary adenocarcinoma (Jaagsiekte) and experiments leading to the deduction of the JSRV nucleotide sequence. *Curr. Top. Microbiol. Immunol.*, 275: 1-23.
18. Perk, K. and I. Hud, 1982. Sheep lung carcinoma: An endemic analogue of a sporadic human neoplasm. *J. Natl. Cancer Inst.*, 69: 747-749.
19. Palmarini, M., J.M. Sharp, M. Delas Heras and H. Fan, 1999. Jaagsiekte sheep retrovirus is necessary and sufficient to induce a contagious lung cancer in sheep. *J. Virol.*, 73: 6964-6972.
20. Mornex, J.F., F. Thivolet, M. Delas Heras and C. Leroux, 2003. Pathology of human bronchioalveolar carcinoma and its relationship to the ovine disease. *Curr. Top. Microbiol. Immunol.*, 275: 225-248.