

<http://www.pjbs.org>

**PJBS**

ISSN 1028-8880

# **Pakistan Journal of Biological Sciences**

**ANSI***net*

Asian Network for Scientific Information  
308 Lasani Town, Sargodha Road, Faisalabad - Pakistan

## Morphometric Changes of Rat Testis after Subchronic Oral Lead Intoxication and D-Penicillamine Treatment

Danial Roshandel, Gholamreza Roshandel and Mohammad Jafar Golalipour  
Department of Histology and Embryology, Gorgan University of Medical Sciences,  
Gorgan, Islamic Republic of Iran

**Abstract:** Lead poisoning is a worldwide health problem and its treatment is under investigation. The aim of this study was to assess the efficacy of D-Penicillamine in reducing lead induced morphometric changes in rat testis. Male adult rats were exposed to 0.4% lead acetate in drinking water for 8 weeks. After this period 6 rats were sacrificed and testes were removed to evaluate the effects of lead intoxication. The remained lead exposed rats were divided into two groups, one group received distilled water and the other group received oral D-P treatment for six weeks, after one week of recovery. Testis morphometric changes were studied in H and E stained sections. After 8 weeks, width of germinal epithelium and number of sertoli cells in test group were decreased compared with negative and positive control rats ( $p < 0.05$ ), while no changes were observed in the number of spermatogonia or primary spermatocytes. After recovery or treatment, germinal epithelium and sertoli cells were still significantly lower than control group ( $p < 0.05$ ). Primary spermatocytes and spermatogonia were decreased after both recovery and treatment periods which was not significant. This study showed that subchronic oral lead intoxication induces some changes in adult testis which are not reversible even after D-P administration.

**Key words:** Lead toxicity, D-Penicillamine, recovery, testis, rat

### INTRODUCTION

Lead is one of the oldest known and most important environmental pollutions which is toxic to many organ systems (Todd, 1994; Gidlow, 2004; Tuormaa, 1995). Lead poisoning may affect body organs for several years even in the absence of continued exposure (Vig and Hu, 2000; Han *et al.*, 1997).

Many studies have shown that reproductive toxicity is an important feature of lead toxicity (Adhikari *et al.*, 2001; Batra *et al.*, 2001; Boscolo *et al.*, 1988). During lead exposure, it accumulates in testis tissue in a dose-dependent manner (Adhikari *et al.*, 2001; Batra *et al.*, 2001). Lead toxicity induces a significant increase in apoptotic cell death in the seminiferous tubules of young growing rats (Adhikari *et al.*, 2001). It is also associated with disruption of spermatogenesis and histoarchitecture and lowered enzyme activities in testis (Batra *et al.*, 2001).

D-Penicillamine is a chelator agent which is used to treat lead toxicity for several years (Hoffman and Segewitz, 1975; Burns and Currie, 1995). D-P administration can increase urinary excretion of lead (Lyle, 1981) and so it seems to be an efficient treatment for chronic lead toxicity in adults (Gonzalez-Ramirez *et al.*, 1990). However, because D-P treatment should be done in

a long period and it is associated with some side effects (Shannon *et al.*, 1988; Shannon and Townsend, 2000) its use in the treatment of lead poisoning is complicated.

This study was conducted to examine the effects of subchronic oral lead intoxication on the testis of adult rats and its reversibility in the presence or absence of D-Penicillamine administration.

### MATERIALS AND METHODS

**Animals:** Thirty six male adult 6-8 weeks albino wistar rats were purchased from pasture institute (Tehran, Iran) and transferred to animal laboratory at Gorgan University of Medical Sciences (GOUMS). They were kept under constant temperature ( $22 \pm 1^\circ\text{C}$ ), humidity (50%) and 12/12 cycle of light and darkness with ad libitum access to food and drinking water. All experiments were conducted in accordance with accepted standards of animals care.

**Experimental protocols:** This study consists of two protocols.

**Protocol I:** After one week of adaptation, animals were divided randomly into three groups as follow: 12 negative control, 6 positive control and 18 test rats and distilled

water, acetic acid (0.13% V/V) and lead acetate dissolved in distilled water (0.4% W/V) were administered for them respectively as daily water supply for 8 weeks. A subsequent amount of 5 N HCL was added to lead acetate solution to preclude the precipitation of lead salts (Ronis *et al.*, 2001). The pH of the solutions was 5.5-6 and they were made fresh daily. At the end of 8th week, treatments were discontinued; Then six rats were selected from each group (all positive control rats) and sacrificed after anesthesia.

**Protocol II:** The remained six negative control and 12 test rats enrolled in the second study. Test rats were divided into two groups of six animals. Distilled water was administered for six Pb exposed rats for seven weeks (Recovery group), as well as control group. The other group of six test rats was given distilled water for one week followed by a six week period of 25-35 mg kg<sup>-1</sup> b wt/day of oral D-Penicillamine treatment. D-P was purchased as 250 mg capsules (RUBIÓ, Spain). The content of each capsule was powdered completely and given to rats through their mouth every day at one dose and one time (~1:00 pm) with empty stomach (2 h before and 1 h after administration). Then D-P treatment was discontinued and all rats were sacrificed after anesthesia.

**Testis morphometry and cell counts:** In each case, right testis was removed and wet weight was measured. Testes were placed in a subsequent amount of Bouin's fluid in order to fixation. After processing, tissues were paraffin embedded and cut into 5-6 micrometer sections on a microtome and stained with H and E method. Slides were viewed and photographed by a video microscope (Olympus, BX51) at 40X, 100X and 400X magnifications for morphometric study.

Random fields from each animal were selected for differential cell counts of seminiferous tubules (Batra *et al.*, 2004). For each rat, 30 round or nearly round seminiferous tubules were selected randomly and germinal epithelial width and number of germinal cells were measured for each tubule (*Olysia bioreport*).

Tubules were selected at 40X magnification while stages were not considered and then measurements were done at 400X magnification. Germinal epithelium was assumed from basement membrane to the latest stage of germinal cells (spermatids) and presented at micrometers. Sertoli cells, spermatogonia and primary spermatocytes were counted in each tubule according to the shape of their nuclei and cytoplasm, shown in Bloom (Fawcett and Raviola, 1994).

**Assessment of lead level:** Sodium Rhodizonate staining method was applied for estimating the level of lead in the testis tissues. For each rat, a number of sections were selected randomly (10-15 sections per testis) and stained with standard method (Bancroft and Stevens, 1990). Red or dark granules in light green background were considered as lead granules. Slides were viewed by light microscope at 400 and 1000X magnifications. Severity of the accumulation of lead granules in sections was used to compare the amount of lead in tissues.

**Statistical analysis:** Data are presented at mean±SD. Mean of values were measured by student's t- test and compared by ANOVA test followed by Tuckey HSD post hoc analysis. p-values were used and those less than 0.05 were considered to be significant.

## RESULTS

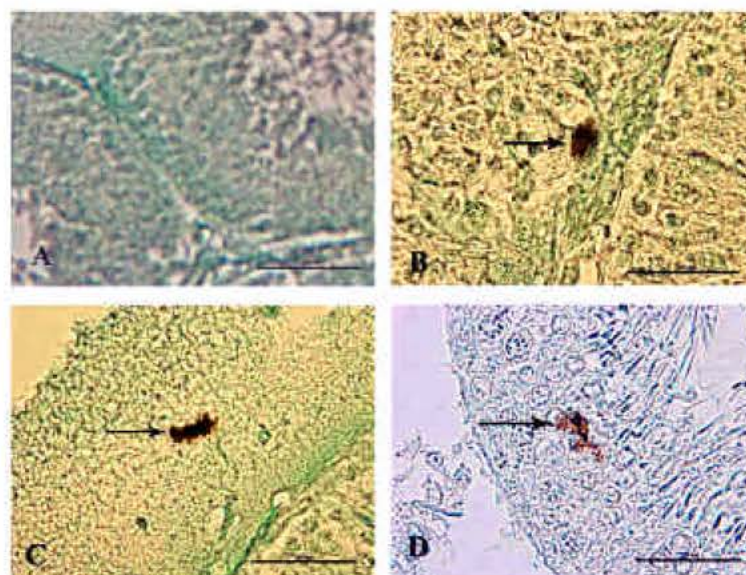
Rhodizonate staining revealed that lead had accumulated in testes of lead exposed rats with the highest accumulation near the basement membrane. Severe accumulation of lead granules was observed in almost all sections in rats exposed to lead acetate for 8 weeks. There were no granulations of lead in control rats. In recovered and D-P treated rats, most of sections were observed with very low or moderate accumulation, but it was severe in some instances in both groups (Fig. 1).

Body weight gain was reduced after 8 weeks of lead exposure (p<0.05). After D-P treatment, weight gain was almost equal with control group, but in recovery group it was lower than the two groups which was not significant. There was no significant difference in testis weight between control and test groups (data not shown).

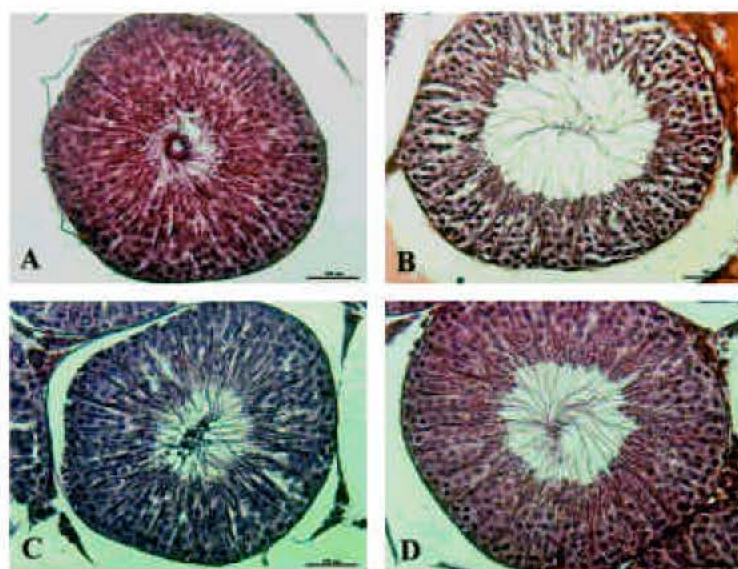
Width of germinal epithelium was decreased significantly in lead exposed rats compared with negative and positive control groups (p<0.05) (Fig. 2). Also a significant decrease in the number of sertoli cells was observed in lead treated rats compared with negative and positive control groups (p<0.05) (Table 1).

There was no significant improvement in the epithelial width and number of sertoli cells after recovery or treatment (Table 1).

The number of spermatogonia and primary spermatocytes were not affected after lead intoxication and they were almost equal in all of negative and positive control and lead exposed rats. After 7 weeks, both were increased in control rats. But in lead exposed animals, they did not increase after recovery or D-P treatment. So there was a 12 and 10% reduction in spermatogonia in recovered and D-P treated rats and 8.5% reduction in primary spermatocytes in both groups compared with control group. These differences were not significant (Table 1).



**Fig. 1:** Accumulation of lead granules in testis tissue of exposed and unexposed rats A: A picture showing no granulations of lead salts in an unexposed rat. B and C: Severe accumulation of lead granules which was seen in lead exposed rats and occasionally in recovered and D-P treated animals. D: Lead salts with a moderate accumulation in a recovered rat. Such granulations were seen in recovered and D-P treated animals. Sodium rhodizonate staining, 100X magnification. Scale bars, 200  $\mu$ m



**Fig. 2:** Germinal epithelium in negative control, lead exposed, recovery and D-P treated rats. A: A seminiferous tubule in negative control rat showing normal germinal epithelium. B: Loss of germinal epithelium after 8 weeks of lead exposure in a lead exposed rat. C: Germinal epithelium after lead intoxication followed by 7 weeks of recovery period. D: Germinal epithelium after lead exposure followed by D-P treatment which seems to be close to normal as well as recovered rats. H and E stain, 400X magnification. Scale bars, 100  $\mu$ m

Table 1: Morphometric parameters including epithelial width, number of sertoli cells, spermatogonia and primary spermatocyte per seminiferous tubule in all groups (n = 6)

| Group             | Width of germinal epithelium ( $\mu\text{m}$ ) | Sertoli cells      | Spermatogonia     | Primary spermatocytes |
|-------------------|--|--------------------|-------------------|-----------------------|
| Negative control  | 117.6 $\pm$ 23.3                               | 14.2 $\pm$ 4.37    | 31.2 $\pm$ 10.0   | 41.8 $\pm$ 10.4       |
| Positive control  | 112.8 $\pm$ 21.6                               | 13.0 $\pm$ 3.80\$  | 30.7 $\pm$ 10.9\$ | 40.8 $\pm$ 11.0       |
| Lead intoxication | 85.9 $\pm$ 16.2*§§                             | 10.6 $\pm$ 4.21*§§ | 31.4 $\pm$ 11.4   | 41.7 $\pm$ 13.3       |
| Control           | 118.3 $\pm$ 27.0                               | 15.4 $\pm$ 4.83    | 33.4 $\pm$ 4.1    | 46.4 $\pm$ 12.3       |
| Recovery          | 92.0 $\pm$ 19.1*§§                             | 11.1 $\pm$ 3.55*§§ | 29.4 $\pm$ 13.7   | 42.6 $\pm$ 11.5       |
| D-P treatment     | 99.4 $\pm$ 22.3*§§†                            | 11.8 $\pm$ 3.33*\$ | 30.2 $\pm$ 9.67   | 42.7 $\pm$ 9.3        |

\* = Significant compared with negative control group,  $p < 0.05$ , § = Significant compared with positive control group,  $p < 0.05$ , \$ = Significant compared with control group,  $p < 0.05$ , † = Significant compared with lead intoxication group,  $p < 0.05$

## DISCUSSION

The present study demonstrated that lead intoxication, induced significant reductions in body weight gain, width of germinal epithelium and number of sertoli cells in lead exposed animals. Also number of primary spermatocytes and spermatogonia were decreased after recovery or treatment, although they were close to normal after lead intoxication. These findings showed that lead induced morphometric changes were not reversible and some parameters were affected even after discontinuation of the exposure.

Many studies have shown that weight gain is reduced in lead exposed rats which is in agreement with our study (Falke and Zwennis, 1990; Wadi and Amad, 1999). The lowered weight gain in lead exposed rats, maybe due to impaired intestinal absorption of some essential trace elements (Antonowicz *et al.*, 1991; Morawiec, 1991). Also loss of appetite maybe another probable mechanism for weight gain reduction in lead poisoning.

A previous study showed reversibility of weight gain reduction after a recovery period (Falke and Zwennis, 1990) that it was not observed in this study. After D-P administration, body weight gain was close to normal which might be due to improved appetite or intestinal absorption of the trace elements.

Reduced width of germinal epithelium which was seen in our study seems to be due to damage of germinal cells that it was reported previously by other researchers (Batra *et al.*, 2001, 2004). Since the number of spermatogonia and primary spermatocytes was almost intact in lead exposed animals, so this reduction may be mainly due to decrease of the number of spermatids (Batra *et al.*, 2004).

Lead induced apoptosis of the germinal cells which was reported by Adhikari *et al.* (2001) is a possible mechanism for loss of germinal epithelium (Adhikari *et al.*, 2001). Also Batra *et al.* (2001) observed a dose dependent reduction in the activity of two major enzymes in the testis, alkaline phosphatase and Na-K ATPase, in lead exposed animals which is another probable mechanism of lead induced reproductive toxicity (Batra *et al.*, 2001).

There is evidence about toxic effects of lead on sertoli germ cell culture (Adhikari *et al.*, 2000) that it may be the reason of significant reduction of the number of these cells in this study. Also increased size of vacuoles and lysosomes of the sertoli cells was seen in previous studies (Boscolo *et al.*, 1988; Murthey *et al.*, 1991), but another study showed that sertoli cells are intact in lead exposed rats (Batra *et al.*, 2004).

We did not observe a statistical difference in the number of spermatogonia or primary spermatocytes between control and test groups. Batra *et al.* (2004), observed significant reduction in type A spermatogonia after lead toxicity associated with decrease of other germ cell populations. In other study, completely arrest of spermatogenesis was seen in lead treated rats (Boscolo *et al.*, 1988).

There is not much evidence about the reversibility of the effects of lead on germinal tissue. However a previous study showed that lead induced reproductive toxicity, is reversible in prepubertal (27 days old) rats but not in adult (pubertal, 52 days old) animals (Sokol, 1989).

According to our findings, there was a very slight reversibility in the reduction of germinal epithelial width and number of sertoli cells. Also we observed that the number of spermatogonia and primary spermatocytes was lower than control in both of recovered and D-P treated rats. This can uphold the proposed idea, that lead can affect body organs even in the absence of continued exposure (Han *et al.*, 1997).

Review of literatures revealed no studies about effects of D-Penicillamine treatment for lead toxicity on reproductive system including testis. In our study, after 6 weeks of oral D-P treatment, there were no significant differences between recovery and treatment groups.

In Sodium Rhodizonate staining, instances of severe accumulations of lead granules were observed in testis of D-P treated rats as well as recovered animals. Also significant decrease of germinal epithelial width and sertoli cells were seen in these groups compared with control group. These findings showed that D-P administration in the present dose and period had no effect on lead induced morphometric changes of testis.

## CONCLUSION

This study has shown that subchronic oral lead intoxication causes some morphometric changes in adult rat testis that these changes seem not to be reversible after discontinuation of lead exposure. Also D-Penicillamine administration can not improve lead induced changes may be because of irreversibility of these effects.

## ACKNOWLEDGMENTS

The authors wish to thank Dr. MS Asghari, Mrs. Ghafari and Mr. Gharavi for their full scientific and sincere cooperation.

## REFERENCES

- Adhikari, N., N. Sinh and D.K. Saxena, 2000. Effect of lead on sertoli-germ cell coculture of rat. *Toxicol. Lett.*, 116: 45-49.
- Adhikari, N., N. Sinha, R. Narayan and D.K. Saxena, 2001. Lead-induced cell death in testes of young rats. *J. Applied Toxicol.*, 21: 275-277.
- Antonowicz, J., R. Andrzejczak, K. Kuliczowski and R. Smolik, 1991. Levels of trace elements in the serum and erythrocytes and some parameters of erythrocyte heme metabolism (FEP, ALA-D, ALA-U) in copper foundry workers. *Pol. J. Occup. Med. Environ. Health*, 4: 339-347.
- Bancroft, J.D. and A. Stevens, 1990. *Theory and Practice of Histologic Techniques*. 2nd Edn., UK, Longman Group, pp: 264.
- Batra, N., B. Nehru and M.P. Bansal, 2001. Influence of lead and zinc on rat male reproduction at biochemical and histopathological levels. *J. Applied Toxicol.*, 21: 507-512.
- Batra, N., B. Nehru and M.P. Bansal, 2004. Reproductive potential of male portan rats exposed to various levels of lead with regard to Zinc status. *Br. J. Nutr.*, 91: 1887-1891.
- Boscolo, P., M. Carmignani, G. Sacchettoni-Logroscino, F.O. Ranelletti, L. Artese and P. Preziosi, 1988. Ultrastructure of the testis in rats with blood hypertension induced by long term lead exposure. *Toxicol. Lett.*, 41: 129-137.
- Burns, C.B. and B. Currie, 1995. The efficacy of chelation therapy and factors influencing mortality in lead intoxicated petrol sniffers. *Aust. N. Z. J. Med.*, 25: 197-203.
- Falke, H.E. and W.C. Zwennis, 1990. Toxicity of lead acetate to female rabbits after chronic subcutaneous administration. 1. Biochemical and clinical effects. *Arch. Toxicol.*, 64: 522-529.
- Fawcett, D.W. and E. Raviola, 1994. *Bloom and Fawcett, a Textbook of Histology*. 12th Edn., New York, Chapman and Hall.
- Gidlow, D.A., 2004. Lead toxicity. *Occup. Med. (Lond.)*, 54: 76-81.
- Gonzalez-Ramirez, D., M. Zuniga-Charles and A. Narro-Juarez, 1990. Mobilization of lead in patients with chronic poisoning by that metal. *Oral penicillamine. Arch. Invest. Med. (Mex.)*, 21: 279-283.
- Han, S., X. Qiao, F.W. Kemp and J.D. Bogden, 1997. Lead exposure at an early age substantially increased lead retention in the rat. *Environ. Health. Prospect.*, 105: 412-417.
- Hoffman, U. and G. Segewitz, 1975. Influence of chelation therapy on acute lead intoxication in rats. *Arch. Toxicol.*, 20: 34: 213-25.
- Lyle, W.H., 1981. Penicillamine in metal poisoning. *J. Rheumatol. Suppl.*, 7: 96-99.
- Morawiec, M., 1991. Effects of harmful trace elements on iron zinc and copper: Their interactions in animals and humans. II. Lead. *Rocz. Panstw. Zakl. Hig.*, 42: 121-126.
- Murthey, R.C., D.K. Saxena, S.K. Gupta and S.V. Chandra, 1991. Lead induced ultrastructural changes in testis of rats. *Exp. Pathol.*, 42: 95-100.
- Ronis, M.J., J. Aronson and G.G. Gao *et al.*, 2001. Skeletal effects of developmental lead exposure in rats. *Toxicol. Sci.*, 62: 321-329.
- Shannon, M., J. Graef and F.H. Lovejoy Jr., 1988. Efficacy and toxicity of D-penicillamine in low-level lead poisoning. *J. Pediatr.*, 112: 799-804.
- Shannon, M.W. and M.K. Townsend, 2000. Adverse effects of reduced-dose D-Penicillamine in children with mild-to-moderate lead poisoning. *Ann. Pharmacother.*, 34: 15-18.
- Sokol, R.Z., 1989. Reversibility of the toxic effect of lead on the male reproductive axis. *Reprod. Toxicol.*, 3: 175-180.
- Todd, A.C., 1994. Lead poisoning. *West. J. Med.*, 161: 187-190.
- Tuomaa, T.E., 1995. The adverse effects of lead. *J. Orthomol. Med.*, 10: 149-164.
- Vig, E.K. and H. Hu, 2000. Lead toxicity in older adults. *J. Am. Geriatr. Soc.*, 48: 1501-1506.
- Wadi, S.A. and G. Amad, 1999. Effects of lead on the male reproductive system in mice. *J. Toxicol. Environ. Health A.*, 56970: 513-521.