

<http://www.pjbs.org>

PJBS

ISSN 1028-8880

**Pakistan
Journal of Biological Sciences**

ANSI*net*

Asian Network for Scientific Information
308 Lasani Town, Sargodha Road, Faisalabad - Pakistan

First Report of Pulmonary *Nocardia transvalensis* Infection from Turkey

¹Ozlem Menteş, ²Yasemin Zer, ¹İclal Balcı and ³Mehmet Ozaşlan

¹Department of Microbiology and Clinical Microbiology,

²Microbiology Laboratory, Sahinbey Medical Center,

³Department of Biology, University of Gaziantep, 27310 Gaziantep, Turkey

Abstract: Infections caused by *Nocardia* species have been reporting frequently in recent years. Nocardiosis usually occurs in patients who have either impaired local pulmonary defenses or systemic immuno-suppression. A 57 years old male patient with hemoptysis admitted to our hospital. Bronchoalveolar lavage and sputum specimen examined for mycobacteriae. BAL and sputum samples taken from the patient, the causal agent of this event isolated and determined as *Nocardia transvalensis*. An antimicrobial therapy with trimethoprim-sulfamethoxazole (TMP-SXT) 4 g/day started. At the end of the treatment clinic, radiologic and bacteriologic cure observed. This is the first report of pulmonary *N. transvalensis* infection from Turkey.

Key words: *Nocardia*, Bronchoalveolar lavage, bronchiectasis, lobar cavitation

INTRODUCTION

Nocardia firstly described by Edmund Nocard in 1888 (Lederman *et al.*, 2004). Members of the genus *Nocardia* are aerobic actinomycetes that are ubiquitous saprophytes in soil, decaying organic matter and water (Karaaslan, 1999; Matulionyte *et al.*, 2004; Carriere *et al.*, 1999; Dikensoy *et al.*, 2004). When observed microscopically, either gram stains of clinical specimens, cultures or when histopathologically in tissues *Nocardia* are branching, beaded, filamentous, gram positive bacteria and are usually weakly acid-fast (Karaaslan, 1999; Saubolle and Sussland, 2003). *Nocardia* species are responsible for a wide spectrum of disease in patients with both normal and abnormal immune systems (Lederman *et al.*, 2004). In general, nocardiosis is a disease that affects primarily the cell-or humorally immuno-compromised population: transplant recipients, patients on high dose steroid and patients with cancer, AIDS or other leucocyte deficiencies, diabetes mellitus, SLE, sarcoidosis, cystic fibrosis, emphysema, asthma, bronchiectasis, tuberculosis and alveolar proteinosis (Lederman *et al.*, 2004; Saubolle and Sussland, 2003; Menendez *et al.*, 1997). The authors estimate that less than 10% of patients with nocardiosis have no definable underlying predisposing factors (Saubolle and Sussland, 2003). Most infections in humans are due to *N. asteroides* group (Lederman *et al.*, 2004; Beaman and Beaman, 1994). Species like *N. brasiliensis*, *N. nova*, *N. farcinica*, *N. transvalensis*, *N. africana* are also isolating in growing frequencies (Saubolle and Sussland, 2003). *N. asteroides*

usually causes pulmonary infections. The form in the lung is developing because of inhalation of spores. (Menendez *et al.*, 1997). *N. transvalensis*, a rare nocardia species previously been recognized as cause of actinomycotic mycetoma (MC Neil *et al.*, 1992; Lopez *et al.*, 2003). Nocardiosis is the most commonly seen in the age group 20-60 and affects men and women equally (Philip *et al.*, 1996). Nocardial infections are not thought to be transmitted from person to person and are usually acquired nosocomically (Saubolle and Sussland, 2003; Menendez *et al.*, 1997). A sharp increase in nocardiosis infections are reported from throughout the world since 1960 (Menendez *et al.*, 1997). We exactly do not know reasons for this, but the idea, related to the development of new diagnostic methods, prevalence of transplantation applications and immuno-suppressive treatment usage. Earlier reports estimated that 500 to 1000 cases/year occur in USA and probably 150-250 in France (Matulionyte *et al.*, 2004; Menendez *et al.*, 1997).

Case report: A 57 years old male patient admitted to Gaziantep University Hospital Cardio-vascular surgery department because of complaint of hemoptysis for 7 months and 3 times a day for last ten days. Patient used to smoke one pocket of cigarette per day over twenty years. Physical examination of the chest common rates observed. Examination of the other systems was unremarkable. Admission in laboratory values were as follows: WBC $6.98 \times 10^3 \mu\text{L}^{-1}$, hemoglobin 15.3 g dL^{-1} , hematocrit 45.2%, erythrocyte sedimentation rate 33 mm h^{-1} , BUN 56 mg dL^{-1} (normal range $10\text{-}50 \text{ mg dL}^{-1}$),

glucose 70 mg dL⁻¹ (normal range 70-110 mg dL⁻¹), albumin 4.8 g dL⁻¹ (normal range 3.4-5.5 g dL⁻¹), CRP 6.1 mg dL⁻¹ (normal range 0-5 mg dL⁻¹). In CT examination of lungs, chronic infiltrations, fibrotic changes and bronchiectasis observed. In the left lung, lower lobar cavitations with 30 mm in diameter and fibrotic sequel in the two upper both of lobar also observed. Diagnostic bronchoscopy applied to patient and bronchoalveolar lavage taken and sent to our laboratory for mycobacterial culture.

MATERIALS AND METHODS

After the decontamination and homogenization of the sample (BAL), in EZN stain, acid-fast bacteria observed. Sample inoculated onto BACTEC (Becton Dickinson, USA) middlebrook 7H12 medium test tubes for mycobacterial culture. After no increase in growth index observed for 10 days, the BAL sample inoculated to SDA and 5% sheep blood agar medium from test tubes. After incubation for 72 h in blood agar medium white, R type, harsh, embedded to medium, velvety colonies produced (Fig. 1). Gram stain performed to colonies and gram

positive, filamentous, branching bacteria observed. Modified EZN stain (decolorized by 1% sulfuric acid instead of acid-alcohol) applied to colonies and acid-fast bacteria observed. Urea test was positive, so, isolate evaluated as *Nocardia* sp. BAL and sputum samples taken from the same patient after 15 days of first isolation. The same bacterium determined again. Isolated bacteria sent to reference laboratory (Faculte De Pharmacie, Laboratoire De Mycologie, Lyon, France) by Turkish Microbiology Society Nocardiosis Work Group for further tests on identifying species and antibiotic sensitivity.

RESULTS

The isolate identified as *Nocardia transvalensis*. As the antibiotic test results: the isolate susceptible to cefotaxime, ceftriaxone, cefepime, amikacin, minocyclin, amoxicillin clavulanic acid, TMP-SXT, it was intermediately susceptible to amoxicillin, piperacillin-tazobactam and imipenem and resistant to ampicillin, ticarcillin, piperacillin, gentamycin, tobramycin, erythromycin, vancomycin, trimethoprim and rifampicin. Therapy with TMP-SXT (4 g/day) started for six months. After 4 weeks in the first control, there was no complaint about hemoptysis but radiological findings still were visible. The work on the mycobacteriae through the bronchoalveolar lavage which taken in the beginning continued till 6 weeks then the results was negative against to mycobacteriae. It indicated that the causal organism of the patient is not related with tuberculosis.

DISCUSSION

Nocardiosis is usually an opportunistic infection and most commonly presents as pulmonary disease (Saubolle and Sussland, 2003). The majority of patients with clinically recognized disease have underlying debilitating factors. Depressed immune system especially T cells and macrophages is an important predisposing factor in nocardia infections. T cells and macrophages kill the bacteria and prevent dissemination (Matulionyte *et al.*, 2004; Menendez *et al.*, 1997; Beaman and Beaman, 1994). So observing opportunistic infections in immunosuppressive patients is not a surprise. Hui *et al.* (2003) have retrospectively reviewed 35 patients with pulmonary nocardiosis. They reported that the majority (63%) of them have had an underlying respiratory disorder ranging from common conditions such as chronic obstructive lung disease (26%), asthma and bronchiectasis (20%), to less common ones such as previous tuberculosis and cystic fibrosis (5.7%). Non-respiratory disorders were comprised of patients with

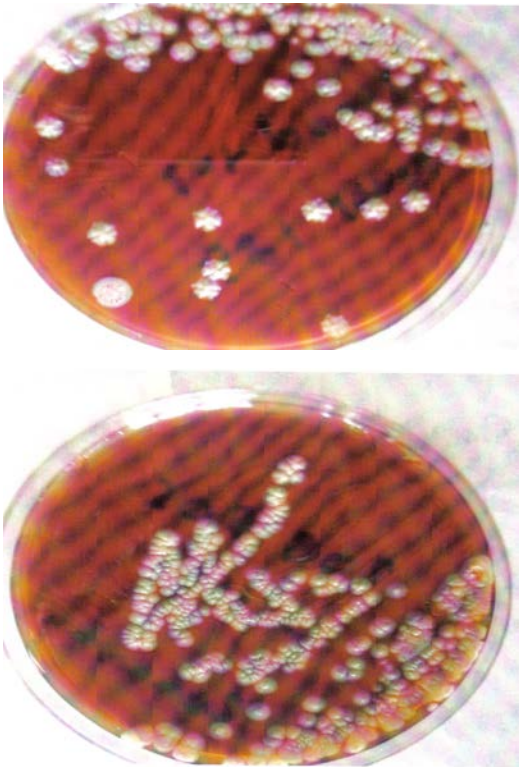


Fig. 1: *Nocardia transvalensis* bacterial growth in blood agar medium

underlying malignancies (20%), organ transplantation (8.6%), autoimmune disorders (5.7%) and HIV (5.7%). Pulmonary nocardiosis clinically causes cough (with or without hemoptysis), anorexia, fever, weight loss and dyspnea (Philip, 1996). Radiological signs are not specific too. Serologic diagnosis is unreliable and serologic tests are not available commercially. Gram staining is the most sensitive method by which to visualize and recognize nocardia in clinical specimens (Saubolle and Sussland, 2003).

Nocardia normally appears with 2 to 7 days on most routine bacteriologic media such as sheep blood agar, chocolate agar and BACTEC blood culture broth media. *Nocardia* are rarely seen as contaminants in the laboratory and each isolate must be carefully evaluated as to its clinical significance (Saubolle and Sussland, 2003). Clinically, it may mimic a carcinoma, tuberculosis or other granulomatous diseases of the lung (Singh *et al.*, 2000).

In this case, hemoptysis was the only symptom. There was no history of drug usage, which could depress the immune system. Nonetheless, it is a great possibility that bronchiectasis may be the underlying factor for pulmonary nocardiosis (Hui *et al.*, 2003). TMP-SXT was used for 6 months. After treatment sputum sample was taken from patient but no pathogen was grown on culture. Then the control CT taken and it is revealed that no more cavitation present in lung.

As a conclusion of this study work, the tests for identification of bacteria, in particular *Nocardia* spp. must not be neglected in the risk group of pulmonary or systemic diseases

REFERENCES

- Beaman, B.L. and L. Beaman, 1994. *Nocardia* sp.: Host-parasite relationships. Clin. Mic. Rev., 7: 213-264.
- Carriere, C., H. Marchandin, J.M. Andrieu, A. Vandome and C. Perez, 1999. Nocardia thyroiditis: Unusual location of infection. J. Clin. Microbiol., 37: 2323-2325.
- Dikensoy, O., A. Filiz, N. Bayram, I. Balci, Y. Zer, G. Celik and E. Ekinçi, 2004. First report of pulmonary *Nocardia otitidiscaviarum* infection in an immunocompetent patient from Turkey. Intl. J. Clin. Practice, 58: 210-213.
- Hui, C.H., V.W. Au, K. Rowland, J.P. Slavotinek and D.L. Gordan, 2003. Pulmonary nocardiosis revisited: Experience of 35 patients at diagnosis. Respir. Med., 97: 709-717.
- Karaaslan, A., 1999. Nocardia. In: Temel ve Klinik Mikrobiyoloji (Eds. Ustaçelebi, Ş) Güneş kitapevi Ltd. Şti., Ankara, pp: 463-469.
- Lederman, E.R., M.C. Nancy, F. Crum and N.R.A., 2004. Case series and focused review of nocardiosis. Clin. Microbiol. Aspects. Med., 83: 300-313.
- Lopez, F.A., F. Johnson, D.M. Novasad, B.L. Beaman and M. Holodniy, 2003. Successful management of disseminated *Nocardia transvalensis* infection in a heart transplant recipient after development sulfonamid resistance: Case report and review. J. Heart Lung Transplant, 4: 492-497.
- Matulionyte, R., P. Rohner, I. Uçkay, D. Lew and J. Garbino, 2004. Secular trends of nocardia infection over 15 years in a tertiary care hospital. J. Clin. Pathol., 57: 807-812.
- Mc Neil, M.M., J.M. Brown, P.R. Georghiou, A.M. Allworth and Z.M. Blacklock, 1992. Infections due to *Nocardia transvalensis*: Clinical spectrum and antimicrobial therapy. Clin. Infect. Dis., 15: 453-63.
- Menendez, R., P.J. Cordero, M. Santos, M. Gobernado and V. Marco, 1997. Pulmonary infection with *Nocardia* species: A report of 10 cases. Eur. Respir. J., 10: 1542-1546.
- Philip, L., 1996. Nocardiosis, Clin. Inf. Dis., 22: 891-905.
- Saubolle, M.A. and D. Sussland, 2003. Nocardiosis: Review of clinical and laboratory experience. J. Clin. Microbiol., 41: 4497-4501.
- Singh, M., R.S. Sandhu, H.S. Randhawa and B.M.K., 2000. Prevalence of pulmonary Nocardiosis in a Tuberculosis Amritsar, Punjab. Ind. J. Chest Dis. Allied Sci., 42.