

<http://www.pjbs.org>

PJBS

ISSN 1028-8880

**Pakistan
Journal of Biological Sciences**

ANSI*net*

Asian Network for Scientific Information
308 Lasani Town, Sargodha Road, Faisalabad - Pakistan

Cleft Palate in a Male Water Buffalo Calf

¹Y. Mazaheri, ¹R. Ranjbar, ²A.R. Ghadiri, ²F. Saberi Afsahr, ²S. Goorani Nejad,
¹M. Khaksary Mahabady, ³M. Afrough, ³R. Karampoor and ³A. Tavakoli
¹Department of Basic Sciences, ²Department of Clinical Sciences,
³Faculty of Veterinary, Shahid Chamran University of Ahvaz, Ahvaz, Iran

Abstract: Congenital palatal defects are common in animals but there is only one report of water buffalo has been recorded in Iran. One died male water buffalo calf was examined after hysterotomy operation. At necropsy findings, brachygnathia, palate cleft and small lungs were diagnosed. It is the second report of water buffalo cleft palate in Iran.

Key words: Cleft palate, brachygnathia, male calf, water buffalo, small lungs

INTRODUCTION

Congenital palatal defects are not uncommon in animals (Noden and DeLahunta, 1985; Stanley, 1993). Soft palate cleft may or may not include the hard palate and can be unilateral, bilateral, or medially located. The soft palate may be hypoplastic as well, usually retaining a medial aspect often describe as a pseudo uvula or uvula like process (Jason and Jonathan, 2004). Heredity and environmental factors such as poisonous plants, some drugs, viruses, may cause these defects (Khaksary-Mahabady *et al.*, 2006; Noden and DeLahunta 1985; Stanley, 1993). First report of the cleft palate of water buffalo was published by Batavani (2005) in Iran. Some reports about palate cleft in animals are: foal (Riley *et al.*, 1991), dog (Bauer *et al.*, 1988), cat (Jason and Jonathan, 2004), cow (Griffith *et al.*, 1987), goat (Sasani and Emami, 2002), sheep (Shojaei *et al.*, 2005) and mice (Khaksary-Mahabady *et al.*, 2006).

MATERIALS AND METHODS

One died male water buffalo calf with extremely flexed limbs and head deviation with brachygnathia defect was delivered through caesarean section in Veterinary Hospital, Shahid Chamran University of Ahvaz in November 2005. The calf was of particular interest to the Department of Anatomy and Embryology. Gross examination and radiographic procedures were done.

RESULTS

Gross examination revealed normally proportioned maxillary features and brachygnathia inferior (Fig. 1).

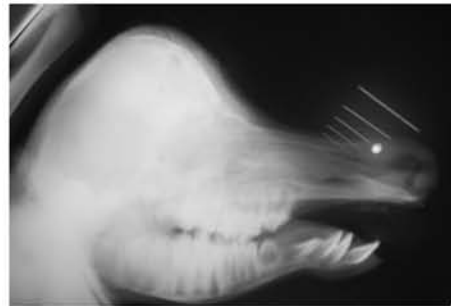

Fig. 1: Lateral view of head male water buffalo calf. Brachygnathia is obvious

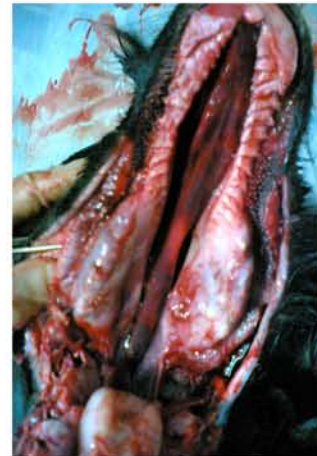

Fig. 2: Median cleft palate is obvious both in hard and soft palate

Closure of the mouth left exposed approximately 4 cm of the upper mouth. The large cleft in the palate (Fig. 2, 3)

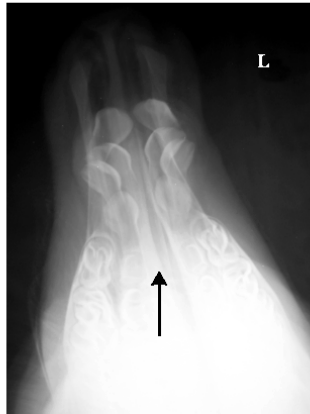


Fig. 3: Dorsoventral view of the head. Brachygnathia and Median cleft palate (Black arrow) are obvious

was 17 cm long, 2.3 cm at its widest point and extended from nasopharynx to the incisive papilla of the dental pad. Left and right bodies of the mandible were same size without oligodontia. The cleft was located medially, extended bilaterally to soft palate too. Testes were small and located in abdominal cavity. There were very small lungs around the heart that located near thoracic inlet.

DISCUSSION

The palate serves as a barrier between the oropharynx and nasopharynx. A defect that causes a loss of this barrier allows open communication between these two cavities, resulting in an animal that can not control the correct passage of food and liquid from the mouth to the esophagus. Animals with these defects present for coughing, sneezing, poor growth, chronic rhinitis and possibly aspiration pneumonia. This deformity is most likely a congenital defect and is often a result of the failure of the proper mesenchyma to grow laterally to medially. It is likely that this occurs late in development if no other organ systems are involved (Jason and Jonathan, 2004).

Cleft palate occurs in dogs more than cats and the presence of cleft palate appears to be much higher in brachycephalic dogs and Abyssinian cats, although many other breeds are affected (Noden and DeLahunta, 1985).

Surgical attempts for reconstruction of cleft palate have been described (Bauer *et al.*, 1988; Bowman *et al.*, 1982; Kirkham and Vasey, 2002). Jason and Jonathan (2004) performed a novel surgical technique to reconstruct the soft palate of a cat utilizing both hard palate derived mucoperiosteal flaps combined with two pharyngeal walls derived, random pattern mucosal flaps.

Cleft palate is common in cow and may be occurred as a single deformation. Griffith *et al.* (1987) reported the cleft palate, brachygnathia inferior and mandibular oligodontia in a Holstein calf but we didn't observe any

oligodontia in our study. This is less common in sheep and goat than cow (Sasani and Emami, 2002; Shojaei *et al.*, 2005). Sasani and Emami (2002) observed a case of cleft palate in goat (7 days old) with aspiration pneumonia. Shojaei *et al.* (2005) reported a cleft palate with maxillary oligodontia and craniofacial defects in a sheep. Batavani (2005) observed cleft palate in a live female buffalo calf with aspiration pneumonia.

This is the second report of cleft palate in buffalo and the first ones in male buffalo cleft palate.

REFERENCES

- Batavani, R.A., 2005. Cleft palate in buffalo calf (a case report). *J. Fac. Vet. Med. Univ. Tehran*, 60(3): 303-304.
- Bauer, M.S., J.W. Levitt-Pharr, J.D. Fowler and A.W.P. Basher, 1988. Unsuccessful surgical repair of a short soft palate in dog. *J. Am. Vet. Med. Assoc.*, 193(12): 1551-1552.
- Bowman, K.F., L.P.J.R. Tate, L.H. Evans and W.J. Dowick, 1982. Complications of cleft palate repair in large animals. *Y. Am. Vet. Med.*, 180: 625-670.
- Griffith, J.W., B.A. Hobbs and E.K. Manders, 1987. Cleft palate, brachygnathia inferior and mandibular oligodontia in a Holstein calf. *J. Comp. Pathol.*, 97(1): 95-99.
- Jason, F.H. and F.M. Jonathan, 2004. Reconstruction of a bilateral hypoplastic soft palate in a cat. *J. Am. Anim. Hospital Assoc.*, 40: 86-90.
- Khaksary-Mahabady, M., R. Ranjbar, A. Arzi, A.A. Papahn and H. Najafzadeh, 2006. A comparison study of effects of Echinacea extract and levamisole on phenytoin-induced cleft palate in mice. *Regul. Toxicol. Pharmacol.*, 46: 163-166.
- Kirkham, L.E. and J.R. Vasey, 2002. Surgical cleft palate repair in a foal. *Aust. Vet. J.*, 80: 143-146.
- Noden, D.M. and A. DeLahunta, 1985. Embryology of Domestic Animals. Developmental Mechanisms and Malformations. Baltimore: Williams and Wilkins, pp: 156-195
- Riley, C.B., J.V. Yovich and J.R. Bolton, 1991. Bilateral hypoplasia of the soft palate in a foal. *Aust. Vet. J.*, 68(5): 178-179.
- Sasani, F. and S.A. Emami, 2002. Cleft palate in goat (a case report). *J. Fac. Vet. Med. Univ. Tehran*, 57 (3): 13-14.
- Shojaei, B., A. Ahmadi and S. Khadivi Sohrabi, 2005. Cleft palate, maxillary oligodontia and craniofacial defects in a sheep (a case report). *J. Fac. Vet. Med. Univ. Tehran*, 60(2): 203-204.
- Stanley, M.D., 1993. Congenital abnormalities the veterinary clinics of North America food animal practice.