

<http://www.pjbs.org>

PJBS

ISSN 1028-8880

**Pakistan
Journal of Biological Sciences**

ANSI*net*

Asian Network for Scientific Information
308 Lasani Town, Sargodha Road, Faisalabad - Pakistan

Prevention of CCl₄-Induced Liver Damage by Ginger, Garlic and Vitamin E

K.C. Patrick-Iwuanyanwu, M.O. Wegwu and E.O. Ayalogu
Department of Biochemistry, Toxicological Unit, University of Port Harcourt,
P.M.B. 5323, Choba, Port Harcourt, Rivers State, Nigeria

Abstract: The hepatoprotective effects of garlic (*Allium sativum*), ginger (*Zingiber officinale*) and vitamin E pre-treatment against carbon tetrachloride (CCl₄)-induced liver damage in male wistar albino rats were investigated. Carbon tetrachloride (0.5 mL kg⁻¹ body weight) was administered after 28 days of feeding animals with diets containing ginger, garlic, vitamin E and various mixtures of ginger and garlic. Serum alanine amino transferase, aspartate amino transferase and alkaline phosphatase levels, 24 h after CCl₄ administration, decreased significantly ($p \leq 0.05$) in rats pre-treated with garlic, ginger, vitamin E and various mixtures of garlic and ginger than in CCl₄-treated rats only. Lipid peroxidation expressed by serum malondialdehyde (MDA) concentration was assayed to assess the extent of liver damage by CCl₄; including the extent of hepatoprotection by garlic, ginger and vitamin E. MDA concentration was significantly decreased ($p \leq 0.05$) in rats pretreated with garlic, ginger, vitamin E and various mixtures of garlic and ginger than in rats administered CCl₄-alone. Histological examination of the liver revealed severe infiltration of inflammatory cells in rats treated with CCl₄ alone. However, the observed alteration in the normal architecture of the hepatic cells decreased remarkably in pre-treated rats.

Key words: Pre-treatment, carbon tetrachloride, malondialdehyde, biochemical parameters, histological examination, lipid peroxidation

INTRODUCTION

Carbon tetrachloride (CCl₄) is a highly toxic chemical agent. The toxic effects of CCl₄ on the liver have been known for years and studied extensively (Recknagel, 1967; Dianzani, 1991). The effects of CCl₄ on hepatocytes, depending on dose and exposure time, are manifested histologically as hepatic steatosis (e.g., fatty infiltration), centrilobular necrosis and ultimately cirrhosis (Junnila *et al.*, 2000). The damage or death of tissue usually results in the leakage of the enzymes in the affected tissue(s) into the blood stream (Siegers *et al.*, 1985; Obi *et al.*, 2001).

Serum or plasma enzyme levels have been used as markers for monitoring chemically induced tissue damages (Lin and Wang, 1986; Ngaha *et al.*, 1989; Hukkeri *et al.*, 2002). The enzymes L-alanine aminotransferase (L-ALT) (E.C. 2.6.1.2), L-aspartate amino transferase (L-AST) (E.C.2.6.1.1) and alkaline phosphatase (ALP) (E.C. 3.1.3.1) are important enzymes that are often employed in assessing liver injury (Ngaha *et al.*, 1989; Obi *et al.*, 1998; Hukkeri *et al.*, 2002).

The biotransformation of CCl₄ to metabolites is a cytochrome P450 mediated reaction that initiate lipid

peroxidation and attendant tissue damage. The metabolic effects of CCl₄ inside mitochondria have been described (Brattin *et al.*, 1984) and it has been found that damage to the calcium pump in mitochondria (Albano *et al.*, 1985) is dependent upon haloalkylation. However, the profound accumulation of fat following CCl₄ poisoning is considered to be independent of mitochondrial damage (Artizzu and Dianzani, 1962; Reynolds *et al.*, 1962). The fatty infiltration of the liver is thought to develop as a result of the action of free alkyl radicals on biomembranes that in turn cause halo alkylation-dependent blocking at the exit of the lipoprotein micelles from the golgi apparatus (Poli *et al.*, 1987).

Some plants have been shown to have protective antioxidant effects and are therefore hepatoprotective. Such plants would include *H. rosasinensis* (Obi *et al.*, 1998), *Celosia argentea* (Koji *et al.*, 1996), *Ginkgo biloba* (Shenoy *et al.*, 2001) among others. A combination of garlic and ginger has been reported by Ahmed and Sharma (1997) to be much more effective in reducing blood glucose and serum lipids while Mustafa and Srivastava (1990) have shown that administration of ginger may exert abortive and prophylactic effects in migraine headache without any side effects.

This study was therefore designed to evaluate the anti-oxidant protective effects of *Allium sativum*, *zingiber officinale* and vitamin E in rats exposed to carbon tetrachloride (CCl₄).

MATERIALS AND METHODS

Plant material: Ginger (*Zingiber officinale*) and garlic (*Allium sativum*) were purchased from Fruit Garden Market D/Line, Port Harcourt, Nigeria.

Preparation of ginger and garlic: The samples were sun-dried for 4 days, ground into powdery form using an electric blender (Moulinex) and stored in air-tight containers.

Animals: Forty five adult male wister albino rats (150-170 g) used in this study were obtained from the Animal House, Department of Biochemistry, University of Port Harcourt, Port Harcourt, Nigeria. They were housed in standard cages (Griffin and George Modular Cage System) and left to acclimatize for 7 days to laboratory conditions before the commencement of the experiment. During the acclimatization, the animals were fed with pelleted rat chew and water *ad libitum*.

The forty five rats were arranged into nine groups of 5 animals each.

- Group 1:** This group was given normal feed and CCl₄
- Group 2:** Received feed, ginger and 0.5 mL CCl₄/kg BW
- Group 3:** Received feed, garlic and 0.5 mL CCl₄/kg BW
- Group 4:** Received feed, vitamin E and 0.5 mL CCl₄/kg BW
- Group 5:** Feed, garlic: ginger (1:1) and 0.5 mL CCl₄/kg BW
- Group 6:** Received feed, garlic: ginger (2:1) and 0.5 mL CCl₄/kg BW
- Group 7:** Received feed, garlic: ginger (1:2) and 0.5 mL CCl₄/kg BW
- Group 8:** Served as control I
- Group 9:** Served as control II

Induction of hepatic injury: Carbon tetrachloride (CCl₄) induced liver damage was achieved by injecting 0.5 mL kg⁻¹ CCl₄ intraperitoneally after 28 days of feeding animals of groups 1-7 with commercial feed, ginger, garlic and vitamin E as stated above.

Preparation of samples: Twenty four hour after the administration of CCl₄, the rats were anaesthetized in a chloroform-saturated chamber. The animals were sacrificed by cervical dislocation and blood was collected

by cardiac puncture using a 5 mL hypodermic syringe and needle and introduced into an anticoagulant free bottle. Serum was separated by centrifugation and stored in a refrigerator. The measurement of different biochemical parameters (L-AST, L-ALT and ALP) was performed using the Humazym M UV-text kits. The liver was excised and fixed in formalin for histological assessment of hepatic damage. Lipid peroxidation was also determined by estimating the malondialdehyde levels, using the method of Hunter *et al.* (1963) modified by Gutteridge and Wilkins (1980).

Analysis of data: The mean values of the control and test serum activities of a given enzyme were compared using the student's t-test (Zar, 1984). The significance level was set at p ≤ 0.05.

RESULTS

Figure 1a-d indicate that treatment of rats with single dose of CCl₄ (0.5 mL kg⁻¹ body wt.) led to the development of severe hepatic injuries as compared to rats pretreated with garlic, ginger, vitamin E; including various mixtures of the drugs. As shown in the figures, marked increase in the concentrations of ALT, AST, ALP and MDA were evident in CCl₄-treated rats alone when compared with those that were pre-treated with ginger, garlic and the control (1). In order words the rats in groups 2 to 9 showed significant improvement in the altered AST, ALT, ALP levels and lipid peroxides. The rats fed with a combination of garlic and ginger (1:1) alone (control II) did not show toxicity in the liver tissue as levels of the biochemical parameters and lipid peroxides gave values that were close to those of control 1 (Group 8). Histopathological examinations (Fig. 2a-c) revealed defects ranging from congested central vein, centrilobular necrosis, fatty degeneration and infiltration by inflammatory cells in rats treated with CCl₄ alone. However, reductions in the observed defects were evident in the pretreated rats.

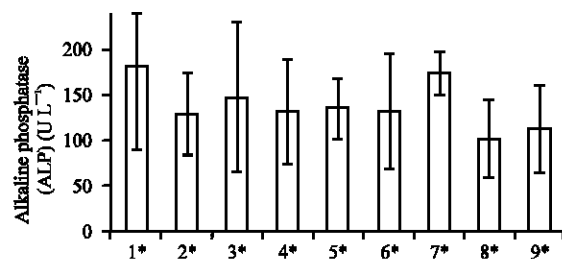


Fig. 1a: Influence of ginger, garlic and vit. E on serum ALP level in CCl₄-hepatotoxicity

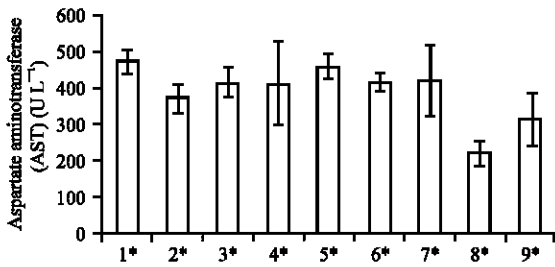


Fig. 1b: Influence of ginger, garlic and vit. E on serum AST level in CCl₄-hepatotoxicity

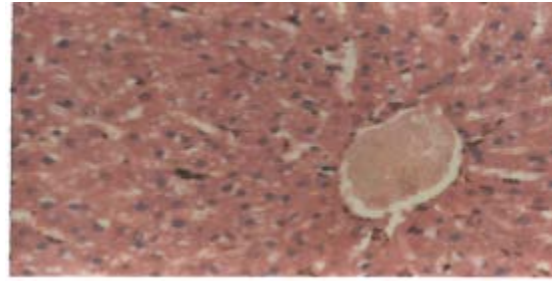


Fig. 2a: A section of rat liver showing normal architecture

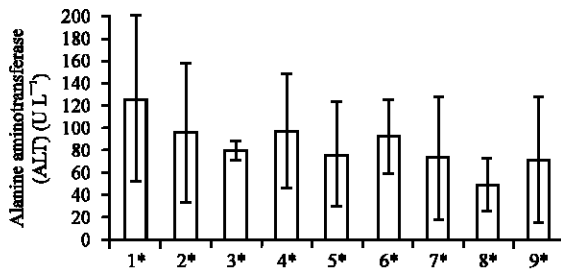


Fig. 1c: Influence of ginger, garlic and vit. E on serum ALT level in CCl₄-hepatotoxicity

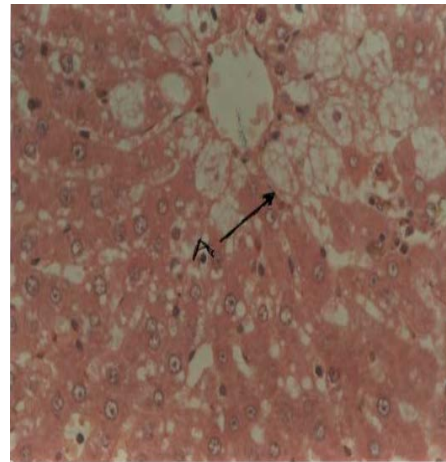


Fig. 2b: A section of rat liver treated with CCl₄ only, showing vacuolar degeneration of centrilobular hepatocytes and infiltration by mixed inflammatory cells

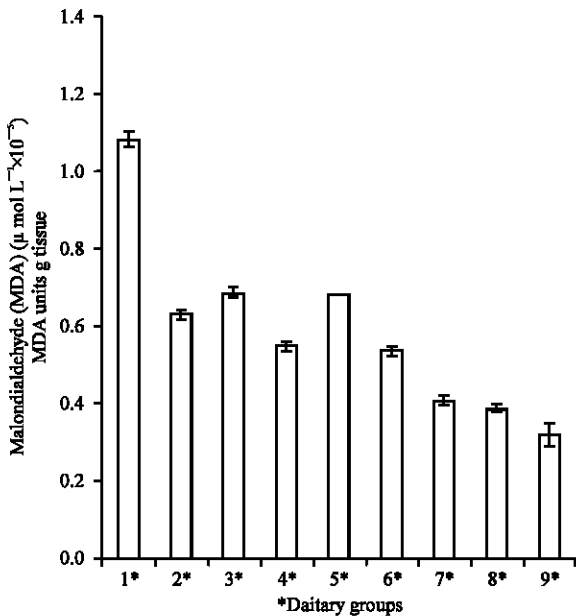


Fig. 1d: The Malondialdehyde (MDA) concentration of liver homogenate in CCl₄ hepatotoxicity. 1 = Feed + CCl₄; 2 = Feed + Ginger + CCl₄; 3 = Feed + garlic + CCl₄; 4 = Feed + Vit. E + CCl₄; 5 = Feed + Garlic + Ginger (1:1) + CCl₄; 6 = Feed + Garlic + Ginger (2:1) + CCl₄; 7 = Feed + Garlic + Ginger (1:2) + CCl₄; 8 = Feed only (Control 1); 9 = Feed + Garlic + Ginger (1:1) (Control II)

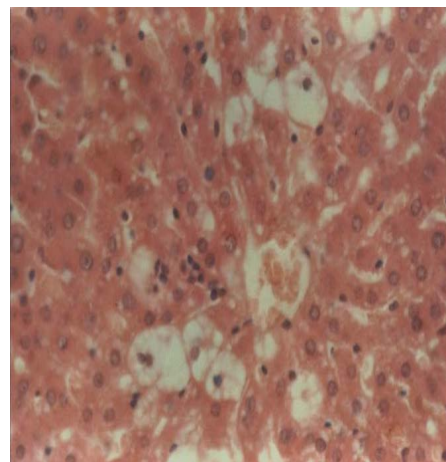


Fig. 2c: A section of rat liver pre-treated with drugs prior to CCl₄ administration showing a pattern of reduced inflammatory infiltration

DISCUSSION

Carbon tetrachloride (CCl₄) is one common hepatotoxin used in the experimental study of liver diseases (Koji *et al.*, 1996; Obi *et al.*, 1998; Shenoy *et al.*, 2001).

The serum levels of these marker enzymes: AST, ALT and ALP reflect the physiological state of the liver. The levels of these enzymes change according to distortion of the liver, resulting from cellular injury of the organ caused by toxic metabolites and diseases.

The efficacy of any hepatoprotective drug is essentially dependent on its capability of either reducing the harmful effects or in maintaining the normal hepatic physiological mechanism which have been altered by a hepatotoxin (Raghavendran *et al.*, 2003).

The results in this study indicate that CCl₄ caused an increase in the serum levels of marker enzymes (AST, ALT and ALP) in group 1 rats that received CCl₄ alone. Such elevation is indicative of liver injury, especially the rise in L-ALT level (Lin and Wang, 1986). The toxicity of CCl₄ to the liver of mammals is largely as a result of the active metabolite, trichloromethyl radical (Johnson and Kruening, 1988). The trichloromethyl radical binds to tissue macromolecule and thus induce peroxidative degradation of membrane lipids of the endoplasmic reticulum which are rich in polyunsaturated fatty acids. Shenoy *et al.* (2001) postulated that such development would ultimately lead to the formation of lipid peroxides that in turn yield other products, among which is malondialdehyde (MDA).

The increased enzyme levels in the plasma of CCl₄-treated rats suggests the toxicant was able to reach the liver and induce a detectable damage within 24 h.

The result in this study suggest that feeding rats with vitamin E, garlic (*Allium sativum*) and ginger (*Zingiber officinale*), singly or as mixtures in different ratios prior to CCl₄ administration caused a decline in hepatotoxicity of rats treated with CCl₄. This is evidenced in the marked decrease in serum L-AST and L-ALT level relative to the group treated with CCl₄ alone. Comparatively, ginger appear to exhibit higher protection of liver than garlic and vitamin E as the levels of all the enzymes studied were lower in rats treated with ginger only than those treated with garlic and vitamin E. The decrease in enzyme level in rats treated with ginger, garlic, combination of garlic and ginger and vitamin E suggest that garlic and ginger contain antioxidant properties with ginger having greater active constituent.

Hukkeri *et al.* (2002) reported that the elevation in the plasma level of cytoplasmic and mitochondrial enzymes accurately reflects liver injury induced by CCl₄. This

increase in the levels of the enzymes (i.e., ALT, AST and ALP) under the influence of CCl₄ has been attributed to the damaged structural integrity of the liver. Significant decrease in the CCl₄-Induced elevation of ALT, AST and ALP level by ginger, garlic and vitamin E is almost definitely suggestive of protection of the structural integrity of the hepatocyte membrane or regeneration of damaged liver cells by test samples. The histopathological observations as well have demonstrated the protective action of the drugs against CCl₄ induced liver damage. Thus, from the result of the current investigation it may be inferred that ginger and garlic possess potent hepatoprotective activity.

ACKNOWLEDGMENTS

The authors are grateful to Dr. S.O. Nwosu (Pathology Department, UPTH) for his assistance in carrying out histological studies. Mr Uche Ezeigbo and Miss Ezinne Nwoke (NNPC Medical Clinic) for their timely assistance in carrying out the biochemical parameters.

REFERENCES

- Ahmed, R.S. and S.B. Sharma, 1997. Biochemical studies on combined effects of garlic (*Allium sativum* Linn) and ginger (*Zingiber officinale* Rosc) in albino rats. Indian J. Exp. Biol. 35: 841-843.
- Albano, E., G. Bellorno, R. Carini, F. Biasi, G. Poli and M.U. Dianzani, 1985. Mechanisms responsible for carbon tetrachloride-induced perturbation of mitochondrial calcium homeostasis. FEBS Lett., 192: 184-188.
- Artizzu, M. and M.U. Dianzani, 1962. The changes in the mitochondria lysosomes in the fatty livers of rats fed with carbon tetrachloride and their independence of ribonuclease activation. Biochem. Biophys. Acta, 63: 453-464.
- Brattin, W.J., S.D. Pencil, R.L. Waller, E.A. Glende and O. Recknagel, 1984. Assessment of the role of calcium ion in halocarbon hepatotoxicity. Environ. Health Perspect, 57: 321-323.
- Dianzani, M.U., 1991. Biochemical Aspects of Fatty Liver. In: Hepatotoxicology. Meeks, R.G., S.D. Harrison and R.J. Bull (Eds.), CRC Press, Boca Raton, FL, pp: 327-399.
- Gutteridge, J.M.C. and C. Wilkins, 1980. Copper dependent hydroxyl radical damage to ascorbic acid formation of a thiobarbituric acid reactive products. FEBS. Lett., 137: 327-340.

- Hukkeri, V.I., B. Jaiprakash, M.S. Lavhale, R.V. Karadi and I.J. Kuppast, 2002. Hepatoprotective activity of *Anthus excelsa* Roxb. leaf extracts on experimental liver damage in rats. J. Pharmacogn., 11: 120-128.
- Hunter, F.E., J.M. Gebicki, P.E. Hoffstein, J. Weinstein and A. Scott, 1963. Swelling and lysis of rats liver mitochondria induced by ferrous ions. J. Biol. Chem., 238: 828-835.
- Johnson, D.E. and C. Kroening, 1998. Ethanol feeding stimulates trichloromethyl radical formation from CCL₄ in cultural rat hepatocytes. Pharmacol. Toxicol., 83: 231-239.
- Junnala, M., T. Rahko, A. Sukura and L.A. Lindberg, 2000. Reduction of carbon tetrachloride induced hepatotoxic effects by oral administration of betaine in male Hans-Wistar rats: A morphometric Histological study. Vet. Pathol., 37: 231-238.
- Koji, H., K. Shigotoghi, B. Purusotam and N. Tsuneo, 1966. Hepatoprotective effectes of traditional medicines isolation of the active constituent from seeds of *C. argentea*. Psychother. Res., 10: 387-382.
- Lin, J.K. and C.J. Wang, 1986. Protection of Crocin dyes in the acute hepatic damage induced by Aflatoxin B and dimethylnitrosamine in rats. Carcinogenesis, 7: 595-599.
- Mustafa, T. and K.C. Srivastava, 1990. Ginger (*Zingiber officinale*) in Migraine headache. J. Ethnopharmacol., 29: 267-273.
- Ngaha, E.O., Akanji, M.A. and M.A. Madusolumuo, 1989. Studies on correlation between chloroquine-induced tissue damage and serum enzyme changes in the rat. Experientia, 45: 143-146.
- Obi, F.O., I.A. Usenu and J.O. Osayande, 1998. Prevention of carbon tetrachloride-induced hepatotoxicity in the rat by *H. rosasinensis* anthocyanin extract administered methanol. J. Toxicol., 131: 93-98
- Obi, F.O., L.A. Omogbai, O.S.J. Oriafio, O.D. Ovat, 2001. Effect of a short time post carbon tetrachloride treatment interval on rat plasma enzyme levels and percentage mortality. J. Applied Sci. Environ. Mgt., 5: 5-8.
- Poli, G., E. Albano and M.U. Dianzani, 1987. The role of lipid peroxidation in liver damage. Chem. Phys. Lipids, 45: 117-142.
- Raghavendran, B.R.H., A. Sathivel and T. Devaki, 2003. Hepatoprotective Nature of seaweed alcoholic extract on Acetaminophen induced oxidative stress. J. Health Sci., 50: 42-46.
- Recknagel, R.O., 1967. Carbon tetrachloride hepatotoxicity. Pharmacol. Rev., 19: 145-208.
- Reynolds, E.S., R.E. Thiers and B.L. Vallee, 1962. Mitochondrial function and metal content in carbontetrachloride poisoning. J. Biol. Chem., 237: 3546-3551.
- Shenoy, K.A., S.N. Somayaji and K.L. Bairy, 2001. Hepatoprotective effects of *Ginkgo biloba* against CCL₄-induced hepatic injury in rats. Indian J. Pharmacol., 33: 260-266.
- Siegers, C.P., W. Horn and M. Younes, 1985. Effect of hypoxia on the metabolism and hepatotoxicity of carbon tetrachloride and vinylidene chloride in rats. Acta Pharmacol. Toxicol., 56: 81-86.
- Zar, J.H., 1984. Biostatistical analysis. Prentice Hall. Englewood Cliffs, N.J. USA.