

<http://www.pjbs.org>

**PJBS**

ISSN 1028-8880

**Pakistan  
Journal of Biological Sciences**

**ANSI***net*

Asian Network for Scientific Information  
308 Lasani Town, Sargodha Road, Faisalabad - Pakistan

## A 64 Years Old Man with Multiple Myeloma and Low HDL

Eeisa Bilehjani, Seyed Hadi Hakim, Azin Alizadeh Asl,

Samad Shams Vahdati and Gader Shahmohammadi

Cardiovascular Research Center, Tabriz University of Medical Sciences, Tabriz, Iran

**Abstract:** In a 64 year old man with dyspnea and palpitation and fatigue and non angina chest pain, we found all the Para clinics perfect but only it showed low HDL and a normocytic, normochromic anemia. In searching about cause of anemia, in bone marrow biopsy showed Paraproteinemia. Therefore false low HDL because of paraproteinemia, leads to miss-diagnosis of cardiovascular disease.

**Key words:** Paraproteinemia, chest pain, cardiovascular disease

### CASE STUDY

A 64-year-old man was referred to our hospital's clinic (16 April 2007; Madani Heart Center, Tabriz, Iran) because of dyspnea and palpitation and fatigue and non angina chest pain with function class II to III. He had history of anemia in several work ups and lab tests such as Hemoglobin (Hb) is  $8.2 \text{ g dL}^{-1}$ , White blood cell Count is  $3900 \text{ m}^{-3}$  and Platelet Count is  $117000 \text{ m}^{-3}$  (in lab report of last month). Before the current evaluation, he began to have abdominal discomfort after eating in last 3 month; he reported that he had not fever, chills, diarrhea, cough, anorexia, weight loss, or rash and that he had been exposed to ill persons.

On physical examination at this hospital, the heart rate was 105 and the systolic blood pressure was 120 mm Hg. He seems to be pale, but doesn't have icterus. There was a hyper dynamic heart. Examination of the abdomen revealed no abnormalities; abdomen was soft, with normal bowel sounds with no organomegaly. No peripheral edema was seen. No rash, petechiae, ecchymoses, oral lesions, or lymphadenopathy was found. The arms revealed no abnormalities and legs were normal. Neurological examination was normal too.

He had drug history of using Ferrous sulfate, Isordil, Alprazolam and Ranitidine. We changed his drugs to Gemfibrozil (due to low HDL) and Alprazolam and stopped all other drugs.

The level of glucose, urea nitrogen, creatinine, calcium, phosphorus and magnesium were normal, also the levels of total bilirubin, aminotransferase and alkaline phosphatase were normal, but the 2 series of lab tests showed low Hb and slowly progressive normocytic,

normochromic anemia associated with a gradual decline in the total white-cell and platelet counts and a decline in the serum level of HDL cholesterol. Some laboratory data are shown in Table 1. Stool exam for occult blood was negative.

We measured the HDL level directly by liquid-based HDL-cholesterol assay and the value of the LDL comes from  $(\text{Total-HDL}-\text{TAG}/5 = \text{LDL})$ .

In the transthoracic cardiac echocardiography we found: left ventricular ejection fraction = 60%, no regional wall motion abnormality, normal four cardiac chambers size, diastolic dysfunction (grade II), mild Mitral valve regurgitation, mild to moderate Tricuspid regurgitation (low pressure) and no pericardial effusion.

Chest X ray was normal.

Table 1: Hematological Laboratory data

Hb ( $\text{g dL}^{-1}$ )	8.6
White blood cell count ( $\text{m}^{-3}$ )	3200
Neutrophils (%)	86
Lymphocytes (%)	10
Monocytes (%)	2
Eosinophils (%)	2
Platelet count ( $\text{m}^{-3}$ )	76000
Reticulocyte count	1.9
Iron ( $\mu\text{g dL}^{-1}$ )	72
Total Iron-binding capacity ( $\mu\text{g dL}^{-1}$ )	340
Ferritin ( $\mu\text{g L}^{-1}$ )	92
Prothrombin time (sec)	13
Partial thromboplastin time (sec)	33
Triglyceride ( $\text{mg dL}^{-1}$ )	140
Low density lipoprotein ( $\text{mg dL}^{-1}$ )	164
High density lipoprotein ( $\text{mg dL}^{-1}$ )	9
Total cholesterol ( $\text{mg dL}^{-1}$ )	201
Serum albumin ( $\text{g dL}^{-1}$ )	4.4
Serum glutamic oxaloacetic transaminase ( $\text{U L}^{-1}$ )	32
Serum glutamic pyruvic transaminase ( $\text{U L}^{-1}$ )	30
Bilirubin total ( $\text{mg dL}^{-1}$ )	0.9
Erythrocyte sedimentation rate ( $\text{mm h}^{-1}$ )	45

In the abdominal sonography, we haven't detected any abnormal finding

**Corresponding Author:** Dr. A. Alizadeh Asl, Department of Cardiology, Madani Heart Hospital, Tabriz, Iran

Tel: +98 (411) 3363880

## DISCUSSION

We are aware of the diagnosis in this case. This patient is pale and has a sign of chronic anemia and the lab test showed low Hb and had persistent and slowly progressive normocytic, normochromic anemia associated with a gradual decline in the total white-cell and platelet counts and a decline in the serum level of HDL cholesterol. The key to the diagnosis of this indolent illness is to identify the relationship between the hematologic abnormality and the causes of the low HDL cholesterol level (Bladé, 2006).

**Causes of anemia:** The three most common causes are nutritional deficiencies (iron, vitamin B<sub>12</sub>, or folate), anemia of chronic inflammation (formerly known as anemia of chronic disease) and neoplasms such as myelodysplastic syndromes, myelomas and hematologic or solid tumors. Peripheral red-cell sequestration and hemolysis can be ruled out in this patient; since he has not splenomegaly and his reticulocyte production index (RPI) was 0.9. (The RPI is the reticulocyte count  $\times$  [the patient's hematocrit  $\div$  a normal hematocrit]  $\times$  [1  $\div$  the red-cell maturation time, in days]; in this case the RPI is  $1.9 \times [25.8 \div 45] \times [1 \div 1.5]$ , or 0.73) (Ganz, 2002). The normal RPI range is 1.0 to 2.0. Values above 2.0 suggest an adequate marrow response, whereas values below 1.0 (as in this case) indicate an inadequate marrow response. Furthermore, no abnormality of red-cell morphology was noted (Guralnik *et al.*, 2004). Thus, this patient's normocytic, normochromic anemia was due to bone marrow failure (Kyle, 1993).

**Bone marrow failure:** Bone marrow failure can be caused by intrinsic diseases that adversely affect the development and maturation of bone marrow progenitor cells or disorders that involve infiltration of the marrow and disturb hematopoiesis (primary bone marrow failure). Bone marrow failure can also be caused by deficiencies of minerals and vitamins that are critical for hematopoietic cell maturation or by toxins, cytokines, or hormones that interfere with the normal marrow kinetics (secondary bone marrow failure) (Kyle *et al.*, 1981). In this patient, the anemia predated the diagnosis of gastroesophageal reflux disease and chemical gastritis; the serum iron level, total iron-binding capacity and ferritin level were normal and the stool tests for occult blood were negative - a combination of findings that rules out iron deficiency caused by gastrointestinal blood loss. The normocytic, normochromic anemia, with normal iron measurements and vitamin B<sub>12</sub> levels, argues against the diagnosis of a megaloblastic anemia (Kyle and Rajkumar, 1999).

In anemia of chronic illness, the serum iron level is decreased despite adequate or increased iron stores.

This is because of the presence of proinflammatory cytokines that induce hepatic synthesis of hepcidin, a peptide hormone that decreases both intestinal iron absorption and the release of iron from macrophages. In this case, the absence of clinical and biochemical features of chronic inflammation, renal and hepatic failure and hypothyroidism rules out secondary causes of normocytic, normochromic anemia, leading to a consideration of causes of primary marrow failure (Kyle and Rajkumar, 1999).

**Monoclonal gammopathy:** Monoclonal gammopathy (or paraproteinemia) refers to the presence of homogeneous (monoclonal) immunoglobulin or fragments of immunoglobulin proteins, often referred to as M protein, in the blood (Merlini *et al.*, 1986). Multiple myeloma and lymphoplasmacytic lymphoma (Waldenström's macroglobulinemia) may be manifested as normocytic, normochromic anemia in the absence of other symptoms. Serum protein electrophoresis and immunofixation electrophoresis are thus indicated in this patient.

**Low HDL cholesterol:** Even if the anemia was the result of a monoclonal gammopathy, the shift in the ratio of cholesterol to HDL in this patient needs to be addressed, having an alarming 9.2 at 6 weeks and a reassuring 9.8 at 2 weeks before the diagnostic workup at this hospital. The alteration in the ratio is predominantly caused by a marked decrease in HDL cholesterol levels (from 54 to 10 mg dL<sup>-1</sup>) as compared with a modest decrease in serum cholesterol levels. A decrease in the HDL cholesterol level may be primary (genetic) or secondary to other diseases or drugs (Nemeth *et al.*, 2004). Many genetic disorders associated with low HDL cholesterol have been described, but they are very rare and in all such cases, the serum HDL cholesterol level is approximately 5 to 10 mg dL<sup>-1</sup>.

The secondary causes of low HDL cholesterol levels are androgens, progestins, cigarette smoking, obesity, a low-fat diet and drugs such as probucol and beta-blockers. None of these appear to explain the low HDL cholesterol levels in this patient. This leads to a consideration of a less well-known but well-documented phenomenon-the fact that monoclonal gammopathies have unusual specificity for various antigens, including actin, double-stranded DNA, thyroglobulin, insulin and apolipoprotein. In addition, paraproteins may interfere with the measurement of HDL cholesterol and other analytes in some automated analyzers (Smogorzewska *et al.*, 2004). Thus, a monoclonal gammopathy in this patient could explain the low HDL cholesterol level.

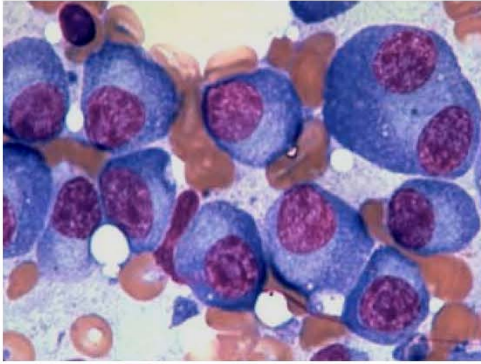


Fig. 1: The bone marrow of patient

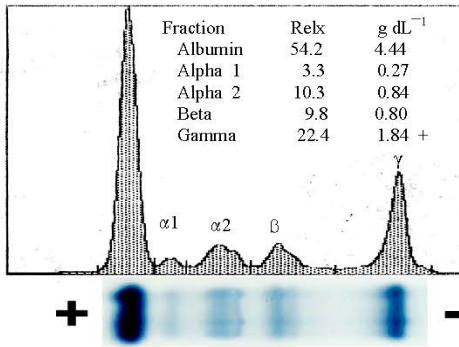


Fig. 2: Electrophoresis of patient's serum's protein

### DIAGNOSIS

Pathologic study of bone marrow biopsy shows multiple myeloma (Fig. 1, 2).

Our patient had bone marrow transplantation.

### SUMMARY AND RECOMMENDATIONS

The sign of cardiovascular diseases can depend on anemia and low HDL can show the relation of the

paraproteinemia and low HDL, thus in patient with chronic anemia and low HDL we must think about bone marrow problem specially paraproteinemia. Lymphoplasmacytic lymphoma with Waldenström's macroglobulinemia and biconal gammopathy. Falsely low serum HDL cholesterol test result due to the presence of the paraprotein.

### REFERENCES

- Bladé, J., 2006. Monoclonal gammopathy of undetermined significance. *N. Engl. J. Med.*, 355: 2765-2770.
- Ganz, T., 2002. The role of hepcidin in iron sequestration during infections and in the pathogenesis of anemia of chronic disease. *Israel Med. Assoc. J.*, 4: 1043-1045.
- Guralnik, J.M., R.S. Eisenstaedt, L. Ferrucci, H.G. Klein and R.C. Woodman, 2004. Prevalence of anemia in persons 65 years and older in the United States: Evidence for a high rate of unexplained anemia. *Blood*, 104: 2263-2268.
- Kyle, R.A., R.A. Robinson and J.A. Katzmann, 1981. The clinical aspects of biconal gammopathies: Review of 57 cases. *Am. J. Med.*, 71: 999-1008.
- Kyle, R.A., 1993. Benign monoclonal gammopathy-after 20 to 35 years of follow-up. *Mayo. Clin. Proc.*, 68: 26-36.
- Kyle, R.A. and S.V. Rajkumar, 1999. Monoclonal gammopathies of undetermined significance. *Hematol. Oncol. Clin. North Am.*, 13: 1181-1202.
- Merlini, G., M. Farhangi and E.F. Osseman, 1986. Monoclonal immunoglobulins with antibody activity in myeloma, macroglobulinemia and related plasma cell dyscrasias. *Semin. Oncol.*, 13: 350-365.
- Nemeth, E., S. Rivera and V. Gabayan *et al.*, 2004. IL-6 mediates hypoferrremia of inflammation by inducing the synthesis of the iron regulatory hormone hepcidin. *J. Clin. Invest.*, 113: 1271-1276.
- Smogorzewska, A., J.G. Flood, W.H. Long and A.S. Dighe, 2004. Paraprotein interference in automated chemistry analyzers. *Clin. Chem.*, 50: 1691-1693.