

<http://www.pjbs.org>

**PJBS**

ISSN 1028-8880

**Pakistan  
Journal of Biological Sciences**

**ANSI***net*

Asian Network for Scientific Information  
308 Lasani Town, Sargodha Road, Faisalabad - Pakistan

## Lymphoma in Syrian Hamster

<sup>1</sup>M. Hosseininejad, <sup>2</sup>O. Dezfoolian, <sup>1</sup>F. Hosseini and <sup>3</sup>F.R. Kabir  
<sup>1</sup>Faculty of Veterinary Medicine, University of Shahrekord, Shahrekord, Iran  
<sup>2</sup>Faculty of Veterinary Medicine, University of Lorestan, Khorramabad, Iran  
<sup>3</sup>Islamic Azad University, Science and Research Branch, Tehran, Iran

**Abstract:** This study describes clinical and pathologic findings in a naturally occurring lymphoma in a Syrian hamster. Lymphoma; the most common tumor of hamster is viral induced tumor with veterinary importance. Clinical signs include emaciation, weakness, lethargy, diarrhea and some rectal bleeding. The present study describes clinical and pathologic findings of lymphoma in Syrian hamster. The disease is naturally occurred.

**Key words:** Lymphoma, Syrian hamster, histopathology

### INTRODUCTION

Hamsters are increasingly being used as a popular pet animal in the world. Relatively high population of these animals in our country requires a good veterinary care of these animals.

Among hamsters diseases, lymphoma is the most common tumour. *Hamster papilloma virus* (HaPV) is seem to be the cause of this tumour. This virus belongs to the subgroup Papovaviridea and also causes keratinizing skin tumours of hair follicle origin. Lymphomas are usually arise in the mesentery, but can originate in the axillary and cervical lymph nodes. the tumours are frequently lymphoid but in older hamsters lymphomas are the most commonly observed neoplasms of haematopoietic system (Meredith, 2006).

### CASE HISTORY

A 2.5 years old male Syrian hamster was referred to us with the history of history of emaciation, weakness, lethargy, diarrhea and some rectal bleeding. Palpation showed the presence of a great mass in the abdomen.

Radiography was performed and the mass was defined with a high density in abdominal cavity.

As the owner requested, the hamster was euthanized using Sodium Thiopental. in necropsy there was a huge mass filled approximately all of the abdomen. It seemed to be originated from mesentery. the mass involved the gastrointestinal wall and lymph nodes. Kidneys, liver, gonads and spleen were seemed normal. Dissected mass showed that the centre was necrotized and surrounded with a layer of approximately 2.5 cm tissue. Tissue samples were obtained from the mass and other organs and were fixed in 10% neutral buffered formalin, embedded in paraffin, sectioned and stained with hematoxylin and eosin.

In light microscope examination solid sheets of lymphoid cells were interspersed with variable numbers of other lymphoid types like immunoblast. They had a high mitotic index. reticular cells and macrophages scattered between lymphoid cells (Fig. 1, 2).

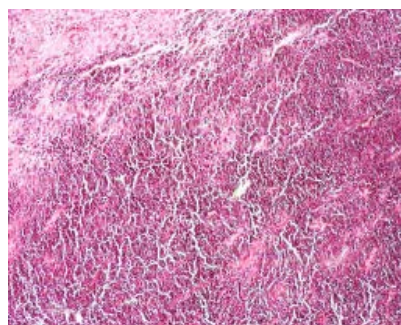


Fig. 1: The photo micrograph showing malignant melanoma with sheets of large numbers of neoplastic cells (H and E x400)

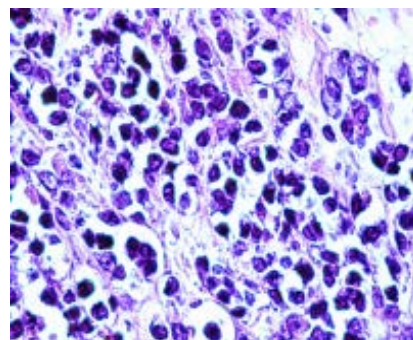


Fig. 2: Mitotic figures, Hyperchromasia and Bizarre cells and some neoplastic cells inside capillaries (arrows) indicating Metastasis (H and E x1000)

## **RESULTS AND DISCUSSION**

Regarding clinical, radiologic and histopathologic findings, lymphoma was confirmed to be the problem. Just like most lymphomas, it was arisen in the large and small intestine and mesenteric nodes.

Other affected organs, in approximate descending order of frequency, include liver, kidneys, thymus, cervical lymph nodes, perirenal lymph nodes, stomach, eye and inguinal lymph nodes. Most lymphomas are of B-cell origin, although some are T-cell and most are composed of immature lymphoid cells, with rare to frequent mitotic figures.

In one study leukemia, lymphoma and osteogenic and anaplastic sarcomas develop in Syrian golden hamsters inoculated intravenously at 3 weeks of age with simian virus 40, which is a papova virus (Diamandopoulos, 1972). In another study, DNA isolated from skin epitheliomas containing papovavirus induced lymphomas within four to eight weeks in 40 to 50% of

newborn Syrian hamsters injected ( Graffi *et al.*, 1969). Lymphoma should be suspected when any abnormal abdominal mass was seen. Clinical signs related to gastro intestinal system were seem to be related with the pressure caused from huge abdominal mass.

## **REFERENCES**

- Diamandopoulos, G.T., 1972. Leukemia, lymphoma and osteosarcoma induced in the Syrian golden hamster by simian virus. *Science*, 176: 173-175.
- Graffi, A., E. Bender, T. Schramm, W. Kuhn and F. Schneiders, 1969. Induction of transmissible lymphomas in Syrian hamsters by application of DNA from viral hamster papova virus-induced tumors and by cell-free filtrates from human tumors. *Proc. Nat. Acad. Sci. USA.*, 64: 1172-1175.
- Meredith, A., 2006. *BSAVA manual of exotic pets*. British Small Animal Association.