

<http://www.pjbs.org>

PJBS

ISSN 1028-8880

**Pakistan
Journal of Biological Sciences**

ANSI*net*

Asian Network for Scientific Information
308 Lasani Town, Sargodha Road, Faisalabad - Pakistan

Toxicological Screening of Lyophilized Extract of Some Nigerian Wild Mushrooms in Mice

¹S.F. Ambali, ¹M. Mamman, ¹A.O. Aduadi, ²K.A.N. Esievo, ²N.D.G. Ibrahim and ³M.S. Abubakar

¹Department of Veterinary Physiology and Pharmacology,

²Department of Veterinary Pathology and Microbiology,

³Department of Pharmacognosy and Drug Development, Ahmadu Bello University, Zaria, Nigeria

Abstract: Mushrooms are macrofungi widely consumed as food. However, many mushrooms rot away in the wild because of fear of toxicity. Therefore, lyophilized aqueous extracts of 6 mushroom species collected from Zaria, Nigeria and taxonomically identified as *Chlorophyllum molybdites*, *Panaeolus subalteatus*, *Macrolepiota procera*, *Leucopaxillus albissimus*, *Hygrophoropsis aurantiacus* and *Pholiota aurea* were screened for toxicity in mice. Lyophilized aqueous extract of each of these mushrooms was administered to three groups of 3 mice intraperitoneally (i.p.) at doses of 100, 1000 and 10,000 mg kg⁻¹, respectively. Another group of three mice given distilled water served as control. The mice were examined for clinical signs of toxicity over a period of 72 h and pathological examinations conducted on dead animals. The severity of clinical signs, onset of death and pathological lesions were dose dependent. Death occurred within 10 min in all the mice dosed at 10,000 mg kg⁻¹ with the lyophilized extracts of all the mushrooms screened, with the exception of that of *H. aurantiacus*, which produced death 21-23 h post administration. This result showed that all the screened mushrooms, including the popular edible *M. procera* were found toxic. Therefore, since all the mushrooms screened were found toxic, it is recommended that extreme caution should be exercised in their consumption. Furthermore, in view of the regional differences in the toxicity of mushrooms, there is the need to screen more wild mushrooms found in Nigeria for toxicity. This will boost mushroom mycophagy, reduce poisoning incidence and reduce wastage of edible mushrooms in the wild.

Key words: Wild mushrooms, toxicity screening, signs, lesions, mice

INTRODUCTION

Mushrooms are macrofungi widely consumed as food throughout the world. Many mushrooms are rich in essential nutrients such as proteins, minerals and vitamins (Lincoff and Mitchel, 1977; Spoerke, 1994). In addition, some mushrooms promote good health and vitality and have been tried with some success in the therapy of cancer, viral diseases, diabetes, hypercholesterolemia, impaired blood platelet aggregation and hypertension (Wang *et al.*, 1996; Waiser and Weis, 1999). In spite of its benefits, wild mushrooms have bad reputation for causing ill health. Long after the first clinical documentation of mushroom poisoning in literature about 3000 years ago, increasing cases of mushroom poisoning continue to be reported in both man and animals throughout the world, with some cases ending fatally (Spoerke, 1994). Clinical characteristics of mushroom poisoning are diverse and depend mostly on the causal pathogenic group (Masson and del Cerro, 2004). Because of the potential hazard of poisoning, many edible mushroom species are not utilized as food but are simply allowed to rot away in the wild.

Regional differences in the edibility of some wild mushrooms are well established. For example, *Pholiota aurea* found to be non-poisonous in Europe was reported to be poisonous in Alaska, USA (Smith, 1994). The regional differences in the edibility of this and many other mushroom species has been attributed to chemical differences in the concentration of some critical compounds, cell mutation and hybridization (Spoerke, 1994). In addition, differences in climate and soil constituents between regions, among others may also contribute to the regional variations.

In Nigeria, proper documentation of mushroom toxicity are rare, as most reports of toxicity and death in humans associated with consumption of mushrooms were often on the pages of newspaper. Therefore, in view of possible regional differences in the edibility of some wild mushrooms, the need for toxicological screening becomes pertinent. This is to ascertain the edibility or toxicity of some of the indigenous mushrooms and stem the tide of wastage of some of the edible nutritious mushrooms which abound in the wild. Besides, several new syndromes are being described in mushroom poisoning

(Diaz, 2005; Philippe and Vincent, 2006), which calls for their continuous toxicological evaluation. Therefore, the objective of this study is to screen some mushroom species collected from Zaria for their toxicity in mice.

MATERIALS AND METHODS

Mushroom collection, identification and extraction: Six mushroom species were collected from the wild in Zaria, Northern Nigeria, between June and October 2001. We carried out the identification of these mushrooms using the macroscopic and microscopic features as described by Zoberi (1972) and voucher specimen deposited in the veterinary toxicology laboratory, Ahmadu Bello University, Zaria, Nigeria (No. ABU/VPP/01/21). Confirmation of identification was done at the Department of Botany and Microbiology, University of Ibadan, Nigeria.

The mushrooms were air dried for 3-5 h and subsequently in the oven at 38-45°C for 24-36 h and then powdered. The powdered mushrooms were macerated in distilled water and kept overnight. The extracts were filtered and lyophilized to amorphous powders referred to as extract and then subsequently stored at 4°C prior to use.

Experimental animals: Swiss albino mice used for this study were locally bred and housed in the Animal room of the Department of Veterinary Physiology and Pharmacology, Ahmadu Bello University, Zaria, Nigeria under standard condition. The mice were fed on standard mice pellets and water was provided *ad libitum*. The mice were allowed to acclimatize for at least seven days prior to their use for the experiment. The experiment was performed as stipulated in the guidelines on animal research of the Animal Research and Ethic Committee of the Ahmadu Bello University, Zaria and in accordance with the Helsinki declaration.

Screening mushrooms for acute toxicity: The lyophilized extract of each of the mushrooms was screened for acute toxicity. Swiss albino mice four to six weeks old and weighing 19-26 g were used. For each of the mushroom extracts, nine mice divided at random into three groups of 3 mice each were used to screen for toxicity (Lorke, 1983). Extracts were reconstituted in distilled water to obtain appropriate stock dilutions. The different dilutions of the reconstituted extracts were given to mice i.p.

Mice in groups I-III were administrated with the reconstituted extract of each mushroom i.p. at 100, 1000 and 10,000 mg kg⁻¹, respectively. A control fourth group consisting of three mice received distilled water i.p. All the animals were monitored for signs of toxicity and/or death

over a period of 72 h. Animals that survived this initial time period were then subjected to periodic examination for clinical signs of toxicity and/or death over a period of two weeks post administration. Post mortem gross examination was conducted on the any dead animal during the study, while those that survived the experiment were euthanized in a chloroform chamber and similarly examined. Tissues samples of the lungs, heart, brain, stomach, intestines, kidneys, liver, heart and spleen were obtained from dead or euthanized animals for histopathological processing and examination. These tissues were fixed in 10% buffered neutral formalin, trimmed and processed in a tissue maton embedded in paraffin. It was cut at 5 µ, mounted on slides and stained with hematoxylin and eosin (Luna, 1960). The slides were then examined under a light microscope.

RESULTS

The lyophilized extract of the mushrooms taxonomically identified as *Chlorophyllum molybdites*, *Panaeolus subalteatus*, *Macrolepiota procera*, *Leucopaxillus albissmus*, *Hygrophoropsis aurantiacus* and *Pholiota aurea* induced varying degrees of toxic signs (Table 1). However, the severity of clinical signs and lesions and the time of onset of death were dose dependent.

The dose-response relationship in the pattern of lethality in mice given different doses of the various mushroom extracts is shown in Table 2. Death occurred in

Table 1: Clinical signs observed in mice administered with lyophilized extract of all the screened mushrooms

Mushrooms	Clinical signs
<i>C. molybdites</i>	Peritoneal irritation, abdominal pains, rapid abdominal contractions, muscle spasm photophobia, depression, excitements, convulsion, respiratory distress and death.
<i>P. subalteatus</i>	Excitement, ataxia, anorexia, jumping, intermittent, then sustained convulsion, respiratory difficulty and death.
<i>M. procera</i>	Excitement, depression, anorexia, convulsion, respiratory difficulty and death.
<i>L. albissmus</i>	Restlessness, tachypnea, depression, convulsion and death.
<i>H. aurantiacus</i>	Depression, anorexia and death.
<i>P. aurea</i>	Depression, restlessness, ataxia, convulsion, respiratory distress and death.

Table 2: Lethality in mice administered intraperitoneally with different doses lyophilized extract of all the screened mushrooms

Mushrooms	Extract doses (mg kg ⁻¹ i.p.)		
	10,000	1,000	100
<i>P. subalteatus</i>	3/3	3/3	0/3
<i>M. procera</i>	3/3	3/3	0/3
<i>L. albissmus</i>	3/3	0/3	0/3
<i>H. aurantiacus</i>	3/3	0/3	0/3
<i>P. aurea</i>	3/3	1/3	0/3
Control (Physiological saline solution)	No death occurred		

Values given as No. of dead mice/No. of doses

Table 3: Post mortem gross lesions observed in mice treated with different doses of lyophilized extract of all the screened mushrooms

Mushrooms	Lesions in various organs							
	Stomach	Intestine	Lung	Liver	Heart	Spleen	Kidney	Brain
<i>C. molybdites</i>	-	Enteritis	-	Enlargement, congestion	-	Congestion	Congestion	Congestion
<i>P. subalpestris</i>	-	Enteritis	Congestion	Enlargement, congestion	-	-	Congestion	-
<i>M. procera</i>	-	Enteritis	-	Congestion	-	-	Congestion, bladder filled with urine	-
<i>L. albissimus</i>	-	Enteritis	-	Congestion	-	Congestion enlargement	-	-
<i>H. aurantiacus</i>	-	-	Hemothorax	Paleness	-	-	-	-
<i>P. aurea</i>	-	-	Congestion	Congestion	-	Enlargement	-	-

-: No lesion found

Table 4: Histopathological findings in mice poisoned with lyophilized extract of all the screened mushrooms

Mushrooms	Lesions in various organs							
	Stomach	Intestine	Lung	Liver	Heart	Spleen	Kidney	
<i>C. molybdites</i>	Necrosis	-	-	Necrosis, fatty degeneration	Necrosis	Congestion	Glomerular and tubular necrosis	
<i>P. subalpestris</i>	-	Necrosis of villi	Congestion, thickened interalveolar septa	Necrosis and congestion	Necrosis	-	Glomerular and tubular necrosis	
<i>M. procera</i>	-	-	-	Necrosis	Necrosis	Congestion, hemorrhage	-	
<i>L. albissimus</i>	-	-	-	Necrosis	Necrosis	-	-	
<i>H. aurantiacus</i>	-	-	-	Necrosis	-	Congestion	Obiteration of capsular space	
<i>P. aurea</i>	-	-	-	Necrosis, congestion	Congestion	-	Glomerular congestion and tubular necrosis	

-: No lesion found

less than 10 min in all mice dosed at 10,000 mg kg⁻¹ with the extract of various mushrooms except for *H. aurantiacus* where death was observed 21-23 h post-administration. Death occurred in only one of the mice treated with *C. molybdites* extract at 100 mg kg⁻¹, although mild signs of toxicity were seen in mice given the extracts of the various mushrooms at this dose. Death did not occur in mice from the control group given only distilled water.

The post mortem gross findings observed in mice given the various mushroom extracts are shown in Table 3. The severity of gross lesions was dose dependent. Enteritis and congested liver were common findings in mice dosed with the extract of most mushrooms screened. There was congestion of the blood vessel of the brain in all the mice administered with 10,000 mg kg⁻¹ of the extract of *C. molybdites*. The bladder of all the mice given 10,000 mg kg⁻¹ of the extract of *M. procera* was filled with urine. Hemothorax was observed in mice given 10,000 mg kg⁻¹ of the lyophilized extract of *H. aurantiacus*.

Necrosis of the liver was a consistent histological finding in all the mice administered with lyophilized extract of all the mushrooms screened (Fig. 1 and Table 4). In addition, necrosis of the heart (Fig. 2) and kidneys were common findings in most of the mushrooms screened. The lung of mice given the extract of *P. subalpestris* showed thickened inter-alveolar septum with mononuclear cellular infiltration.

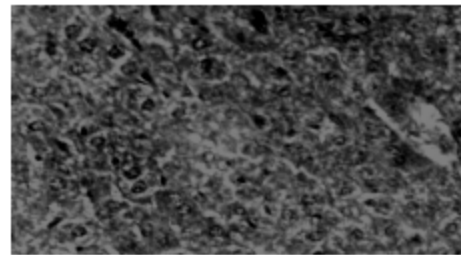


Fig 1: Histopathological section of liver of mouse experimentally dosed i.p. with lyophilized extract of *Chlorophyllum molybdites* showing disorganized hepatic architecture, fatty degeneration and diffuse necrosis of hepatocytes. H and E x400

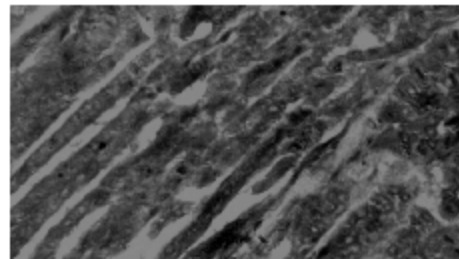


Fig 2: Histopathological section of heart of mouse experimentally dosed i.p. with lyophilized extract of *Panaeolus subalpestris* showing diffuse necrosis of the cardiac cells H and E x400

DISCUSSION

The use of laboratory animals in evaluating the toxicity of mushrooms in humans has been largely controversial, since many of the mushroom toxins do not produce any toxic sign or pathology when administered orally (Parish and Doering, 1986). However, many authorities believed that from result of previous studies, laboratory animals can make good experimental models, as signs and lesions similar to those observed in humans can be produced when mushroom extracts are administered parenterally (Choppin and Desplaces, 1978; Parish and Doering, 1986).

In the present study, the six mushrooms identified as *Chlorophyllum molybdites*, *Panaeolus subalteatus*, *Macrolepiota procera*, *Leucopaxillus albissimus*, *Hygrophoropsis aurantiacus* and *Pholiota aurea* were found to exhibit various degree of toxicity in mice. The severity of clinical signs and onset of death in the mice, induced by all the mushrooms were also dose dependent. The rapid onset of death in mice administered with the highest dose (10,000 mg kg⁻¹) of virtually all the various mushroom extracts indicate that the active ingredients of these mushrooms are rapidly absorbed with fast onset of action.

Chlorophyllum molybdites, a commonly reported poisonous mushroom, was shown to be toxic to mice in this study. The toxic principle in this mushroom may be lethal in mice, as death occurred at even a low dose (100 mg kg⁻¹) of administration of the extract. Depression, tremor and abdominal contraction observed in this study were consistent with findings from an earlier study (Eilers and Nelson, 1974). Miosis, contraction of abdominal muscles and tremors observed in this study were consistent with those found in an earlier study, which were attributed to the cholinergic effect of the toxin (Torrelío and Izquierdo, 1970). However, atropine has been found not to ameliorate these toxic signs (Ambali, 2004). The irritant nature of the toxin was responsible for the peritoneal irritation, abdominal pain and enteritis observed in this study while the gastrointestinal hemorrhage may be associated with coagulopathic syndrome (Levitan *et al.*, 1981). Photophobia shown by these animals has also been reported in man (Smith, 1980). Convulsion, which preceded death of the mice in this study, has also been observed in a child that died following the ingestion of this mushroom (Chestnut, 1900; Augenstein, 1994). Necrosis of the heart observed in poisoned mice may be consistent with electrocardiographic changes reported in some poisoned human patients (Southcott, 1974). Other signs of poisoning seen in man following ingestion of *C. molybdites* including nausea, vomiting and copious watery diarrhea (which may be bloody or mucoid) were not observed in this study, perhaps due to the route of

administration. A high molecular weight polymeric protein of about 400 KDa that can be destroyed by digestive juices such as acid and pepsin was reported to be the toxic principle in *C. molybdites* (Eilers and Nelson, 1974). The destruction of the toxin by digestive juices coupled with its large molecular weight may be responsible for limited absorption and fatalities following the consumption of this mushroom by man (Eilers and Nelson, 1974). In humans, only one fatality involving a child has been associated with the consumption of this mushroom in history (Chestnut, 1900), although, the mushroom is capable of causing severe morbidity (Stenklyt and Augenstein, 1990; Augenstein, 1994). In addition to the large protein toxin, an alkaloid, lepotin B (Oht *et al.*, 1998) and two cytotoxic steroidal derivatives, (22E, 24R)-3 α -ureido-ergosta-4, 6, 8(14), 22-tetraene (1) and (22E, 24R)-5 α , 8 α -epidioxyergosta-6, 9, 22-triene-3 β -ol 3-O- β -D-glucopyranoside (2) have been isolated from the mushroom (Yoshikawa *et al.*, 2001). However, the contribution of these chemical constituents to the toxicity of *C. molybdites* has not been elucidated.

Panaeolus subalteatus, a mushroom found in the early rainy season and used for recreational purposes (like many other *Panaeolus* sp.) was found toxic in this study. Although poisonous, low doses (100 mg kg⁻¹) of the lyophilized extract of this mushroom produce only mild symptoms of toxicity. This suggests that the mushroom though toxic is not highly lethal. Marked excitement seen following its administration in mice may be related to its euphoric and hallucinogenic principles (Watt and Breyer-Brandwijk, 1962; Verdcourt and Trump, 1969). Many hallucinogenic *Panaeolus* sp. contain psilocybin and psilocin, in addition to some other hallucinogenic compounds. However, *P. subalteatus* does not contain psilocin but have been found to contain other hallucinogenic principles such as psilocybin, serotonin, baeocystin and norbaeocystin (Lincoff and Mitchell, 1977; Repke *et al.*, 1977; Beug and Bigwood, 1982). Psilocybin is used as a recreational drug in many parts of the world (Allen, 1993). Variation exists in the level of psilocybin found in *P. subalteatus* from various geographic and climatic zones. The psilocybin content of the American variety ranges between 1.6-6.5 mg kg⁻¹ (Beug and Bigwood, 1982), while that of Europe is 0.8-1.4 mg g⁻¹ dry weight (Stijve and Kuyper, 1985). *P. subalteatus* is found in grassy lawns in Zaria as one of the earliest mushroom sprout during the rainy season. Therefore, its abundance in this environment makes it a potential tool for abuse by individuals seeking psychedelic experience. However, to our knowledge there has been no report of deliberate use of this mushroom for recreational purposes in Nigeria.

Macrolepiota procera, an edible mushroom was found toxic in the present study. This demonstrates the presence of some toxic principles, which may be detrimental to health. Pathologic changes observed in the

liver, heart, kidneys and spleen suggest a wide range of toxic effects. High doses of this mushroom may induce paralyzing effect on the bladder as observed in mice dosed at 10,000 mg kg⁻¹, which have their bladder filled with urine. Toxicity is not usually seen in humans probably because the toxin is heat labile and must have been destroyed during the cooking process, or may be destroyed by gastric juices and proteolytic enzymes in the gastrointestinal tract or may not even be absorbed when ingested, perhaps due to its size.

Leucopaxillus albissimus has been demonstrated in the present study to be mildly toxic since death was not observed in any of the animals given lower doses of the extract (1000 and 100 mg kg⁻¹) but only at higher dose (10,000 mg kg⁻¹). However, pathological changes observed in the liver and heart of treated animal showed that this mushroom may not be entirely safe for consumption, besides its disagreeable taste which makes it inedible (Smith, 1971). To our knowledge, there has been no report of toxicity of this mushroom in literature.

Hygrophoropsis aurantiacus also known as false chanterelle, because of its resemblance to the edible choice mushroom *Chantarellus cibarius* was shown to be lethal to mice at the highest dose of 10,000 mg kg⁻¹. This mushroom is known to cause gastrointestinal problems in man (Jordan, 1999). However, some people have eaten the mushroom without any harmful symptom (Gillman, 1978). Evidence from the histopathological changes observed in this study showed that toxin found in this mushroom caused damage to the kidneys.

Pholiota aurea has been reported to be of variable toxicity. The European variety is edible while the variety found in Alaska (USA) causes mild poisoning (Smith, 1994). *P. aurea* is said to be associated with gastrointestinal upset, indigestion and general malaise. It also causes allergic reaction in some individuals (Lincoff and Mitchel, 1977). Histopathologic findings from this study revealed that the mushroom toxin is capable of causing damages to the liver and the kidneys. Therefore, this mushroom has the potential of causing toxicity when consumed at a high dose.

Although the toxic principles responsible for poisoning in many of these mushrooms are unknown, studies have shown that some of them do accumulate heavy metals (Falandysz and Chwir, 1997; Garcia *et al.*, 1998; Kalac *et al.*, 1996; Svoboda *et al.*, 2000) and even hydrogen cyanide (Stijve and de Meijer, 1999), which might further potentiate their toxicity.

In conclusion, this study has demonstrated the toxicity of all the screened mushrooms, although the degree of their toxicity differs in different species. Therefore, in view of the toxicity observed in mice administered with all these mushrooms including the widely consumed *M. procera* and the regional differences in the edibility of some wild mushrooms, there is the need

to further evaluate the toxicity of other indigenous mushroom species found in Nigeria. This type of study will further improve mushroom mycophagy, reduce wastage of edible wild mushrooms and decrease the incidence of poisoning as a result of consumption of indigenous wild mushrooms. It is recommended that extreme caution should be exercised in the consumption of wild mushrooms, even when one is sure of their edibility, since many other extraneous factors such as the presence of some heavy metals and hydrogen cyanide can precipitate their toxicity.

ACKNOWLEDGMENTS

The authors wish to acknowledge Prof Nwankwo Nwude (late) who stimulated our interest in toxicology of mushrooms. We appreciate Dr. S.G. Jonathan of the Department of Botany and Microbiology, University of Ibadan for taxonomic identification of the mushrooms. We also thank the Ahmadu Bello University Board of Research for providing part of the fund used for this study.

REFERENCES

- Allen, J.W., 1993. *Coopelandia* and other psychoactive fungi in Hawaii. *Psychedel. Illum.*, 4: 61.
- Ambali, S.F., 2004. Toxicity studies of some mushrooms indigenous to Zaria in mice. M.Sc. Thesis, Ahmadu Bello University, Zaria, Nigeria.
- Augenstein, W.L., 1994. *Chlorophyllum molybdites*. In: Handbook of Mushroom Poisoning: Diagnosis and Treatment. Spoerke, D.G. and B.H. Rumack (Eds.), CRC Press, London, pp: 325-338.
- Beug, M.W. and J. Bigwood, 1982. Psilocybin and psilocin levels in twenty species from seven genera of wild mushrooms in the Pacific North West, USA. *J. Ethnopharmacol.*, 5: 271.
- Chestnut, V.K., 1900. Poisonous Properties of Green-Spored *Lepiota*. *Asa Gray Bull.*, 8: 87-93.
- Choppin, J. and A. Desplaces, 1978. The effect of silybin on experimental phalloidine poisoning. *Arzneim Forsch.*, 25: 89-96.
- Diaz, J.H., 2005. Syndromic diagnosis and management of confirmed mushroom poisonings. *Cri. Care Med.*, 33: 427-436.
- Eilers, F.I. and L.R. Nelson, 1974. Characterization and partial purification of the toxin of *Lepiota morgani*. *Toxicon*, 12: 557-563.
- Falandysz, J. and A. Chwir, 1997. The concentrations and bioconcentration factors of mercury in mushrooms from the Mierzeja Wiślana sand-bar, Northern Poland. *Sci. Total Environ.*, 203: 221-228.

- García, M.A., J. Alonso, M.I. Fernández and M.J. Melgar, 1998. Lead content in edible wild mushrooms in Northwest Spain as indicator of environmental contamination. *Arch. Environ. Contam. Toxicol.*, 34: 330-335.
- Gillman, L., 1978. Identification of Common Poisonous Mushrooms. In: *B. Mushroom Poisoning: Diagnosis and Treatment*. Rumack, H. and E. Salzman (Eds.), CRC Press, Florida, pp: 25-57.
- Jordan, P., 1999. *Mushroom Identifiers*. Lorenz Books, London.
- Kalac, P., M. Nižnanská, D. Bevilacqua and I. Stásková, 1996. Concentrations of mercury, copper, cadmium and lead in fruiting bodies of edible mushrooms in the vicinity of a mercury smelter and a copper smelter. *Sci. Total Environ.*, 177: 251-258.
- Levitan, D., J.I. Macy and J. Weisseman, 1981. Mechanism of gastrointestinal hemorrhage in a case of mushroom poisoning by *Chlorophyllum molybdites*. *Toxicol.*, 19: 179-180.
- Lincoff, G. and D.H. Mitchell, 1977. *Toxic and Hallucinogenic Mushroom Poisoning*. Van Nostrand, Reinhold Publisher, New York.
- Lorke, D., 1983. A new approach to practical acute toxicity testing. *Arch. Toxicol.*, 54: 275-287.
- Luna, G.H., 1960. *Manual of Histologic Staining Method of the Armed Forces Institute of Pathology*. 35th Edn., McGraw-Hill Book Company, New York.
- Masson, L. and E. del Cerro, 2004. Mushroom poisoning in dogs and cats. *Summa*, 21: 19-22.
- Oht, A.T., H. Inoue, O.G. Kusan and Y. Oshima, 1998. Lepiotin A and B, new alkaloids from the mushrooms *Macrolepiota neomastoidea* and *Chlorophyllum molybdites*. *Heterocycles*, 47: 883-891.
- Parish, R.C. and P.L. Doering, 1986. Treatment of *Amanita* mushroom poisoning: A review. *Vet. Hum. Toxicol.*, 28: 318-322.
- Philippe, S. and D. Vincent, 2006. New syndromes in mushroom poisoning. *Toxicol. Rev.*, 25: 199-209.
- Repke, O.B., D.T. Leslie and G. Guzman, 1977. Baeocystin in *Psilocybe*, *Conocybe* and *Panaeolus*. *Lloydia*, 40: 566.
- Smith, A.H., 1971. *The Mushroom Hunter's Field Guide*. University of Michigan Press, Ann Arbor.
- Smith, A.H., 1994. Poisonous Mushrooms: Their Habitats, Geographic Distribution and Physiologic Variation Within Species. In: *Handbook of Mushroom Poisoning: Diagnosis and Treatment*. Spoerke, D.G. and B.H. Rumack (Eds.), CRC Press, London, pp: 39-45.
- Smith, C.W., 1980. Mushroom poisoning by *Chlorophyllum molybdites* in Hawaii. *Hawaii Med. J.*, 39: 13-14.
- Southcott, R.V., 1974. Notes on some poisonings and other clinical effects following ingestion of Australian fungi. *S. Aust. Clin.*, 6: 458-459.
- Spoerke, D., 2001. Mushroom Exposure. In: *Small Animal Toxicology*. WB Saunders, Pennsylvania, pp: 571-592.
- Spoerke, D.G., 1994. Introduction to Identification and Toxicology, pp: 1-7. In: *Handbook of Mushroom Poisoning: Diagnosis and Treatment*. Spoerke, D.G. and B.H. Rumack (Eds.), CRC Press, London, pp: 39-45.
- Stenklyt, P.H. and W.L. Augenstein, 1990. *Chlorophyllum molybdites*. Severe mushroom poisoning in a child. *Clin. Toxicol.*, 28: 159-168.
- Stijve, T. and T.W. Kuyper, 1985. Occurrence of psilocybin in various higher fungi from several European countries. *Planta Med.*, pp: 385-386.
- Stijve, T. and A.A.R. de Meijer, 1999. Hydrocyanic acid in mushrooms, with special reference to wild-growing and cultivated edible species. *Deutsche Lebensm. Rundschau*, 95: 366-372.
- Stijve, T. and D. Andrey, 2002. *Phaeolepiota aurea*. A beautiful and mysterious mushroom. *Aust. Mycologist*, 21: 24-28.
- Svoboda, L., K. Zimmermannová and P. Kalac, 2000. Concentrations of mercury, cadmium, lead and copper in fruiting bodies of edible mushrooms in an emission area of a copper smelter and a mercury smelter. *Sci. Total Environ.*, 246: 61-67.
- Torrelio, M. and J.A. Izquierdo, 1970. Cholinergic-like effects of *Chlorophyllum molybdites*. *Arch. Int. Pharmacodyn.*, 185: 185-190.
- Verdcourt, B. and E.C. Truemp, 1969. *Common Poisonous Plants of East Africa*. Collins and Clear, Glasgow.
- Waiser, S.P. and A.L. Weis, 1999. Therapeutic effects of substances occurring in higher basidiomycetes mushrooms: A modern perspective. *Crit. Rev. Immunol.*, 19: 65-96.
- Wang, H.X., V.E.C. Ooi, T.B. Ng, K.W. Chiu and S.T. Chang, 1996. Hypotensive and vasorelaxing activities of a lectin from the edible mushroom *Tricholoma mongolicum*. *Pharmacol. Toxicol.*, 79: 318-323.
- Watt, J.M. and M.G. Breyer-Brandwijk, 1962. *The Medicinal and Poisonous Plants of Southern and Eastern Africa*. 2nd Edn., E and S Livingstone, Edinburgh.
- Yoshikawa, K., M. Ikuta, S. Arihara, E. Matsumura and S. Katayama, 2001. Two new steroidal derivatives from the fruit body of *Chlorophyllum molybdites*. *Chem. Pharm. Bull.*, 29: 1030-1032.
- Zoberi, M.H., 1972. *Tropical Macrofungi*. Macmillan Press, London.