

<http://www.pjbs.org>

PJBS

ISSN 1028-8880

Pakistan Journal of Biological Sciences

ANSI*net*

Asian Network for Scientific Information
308 Lasani Town, Sargodha Road, Faisalabad - Pakistan

Evaluation of Characteristics of Patients with Pilomatricoma in Mazandaran Province, 1996-2006

Masoud Golpour

Department of Dermatology, Mazandaran University of Medical Sciences, Boo-Ali-Sina Hospital, Pasdaran Boulevard, P.O. Box 48158-38477, Sari, Iran

Abstract: The aim of this study was to evaluate characteristics of patients with pilomatricoma in Mazandaran Province, 1996-2006. In this study 46 case of pilomatricoma, with asymptomatic, single and firm nodule referred to dermatology clinic of Boo-Ali Sina Hospital in Sari (1996-2006). A Biopsy was taken from suspicious lesions and histopathology assessments were done for cases with pilomatricoma impression. 69.56% patients were female. Mean age of the patients was 20.1 years. The most frequent sites of the tumor were the forearm (41.30%). It can be concluded, because the pilomatricoma is a benign cutaneous neoplasm with differentiation toward hair matrix, so that it is not seen in palm or plantar surface, but could present in any other area. Since, few of pilomatricoma lesions converted to malignant, so that it is better we resects total lesion by surgical excision.

Key words: Pilomatricoma, skin disease, benign cutaneous neoplasm, biopsy

INTRODUCTION

Pilomatricoma, also known as calcifying epithelioma of Malherbe is an uncommon benign cutaneous neoplasm with differentiation toward hair matrix that occurs frequently in children (Kaddu *et al.*, 1994; Holme *et al.*, 2001; Kaveri and Punnya, 2008). Pilomatricoma usually manifests as a solitary, asymptomatic and firm nodule, but some reported pain during episodes of inflammation (Rao and Lin, 2006). Histologically, a pilomatricoma is an encapsulated lesion composed of solid small basophilic cells and eosinophilic ghost cells. There is a gradual transition from the basophilic cells, located at the perimeter of the lesion, to the more centrally located ghost cells. Calcification usually takes place producing solid purple amorphous masses. Ossification, melanin deposition and foreign body giant cells also may be present (Farmer and Hood, 2000). Globally, 15 patients with pilomatricoma were seen in a pediatric surgery clinic in Turkey from 1984-1994 (Demircan and Balik, 1997). Cigliano presents 83 patients with pilomatricoma during a 7 years period (1996-2002) at the Departments of Pediatrics, University Hospital Federico II, Naples, Italy (Cigliano *et al.*, 2005). Kaddu *et al.* (1994) studied 118 patients admitted at Department of Dermatology in Australia between 1980-1990. Diagnosis of pilomatricoma is difficult and the final confirmation is by histological examination (Punia *et al.*, 2001). Because preoperative diagnosis of pilomatricoma is usually incorrect, careful

clinical examination and a high index of suspicion would result in a more accurate diagnosis (Lan *et al.*, 2003). This study presents 46 cases of pilomatricoma. Principle characteristic clinical presentations of this tumor are discussed.

MATERIALS AND METHODS

In this descriptive study, patients with asymptomatic, single and firm nodule referred to dermatology clinic of Boo-Ali Sina Hospital in Sari, Iran (1996-2006) were assessed. Biopsy was taken from suspicious lesions and histopathology assessments were done for cases with pilomatricoma impression (Fig. 1, 2).

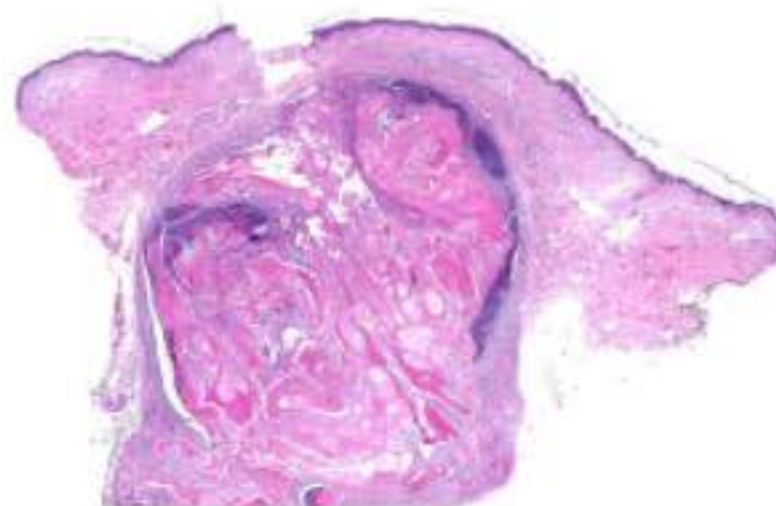


Fig. 1: Very low power view (direct scan of glass slide). Multiple types of keratinization plus a mixture of epithelial elements produce a swirled or geographic appearance at this power

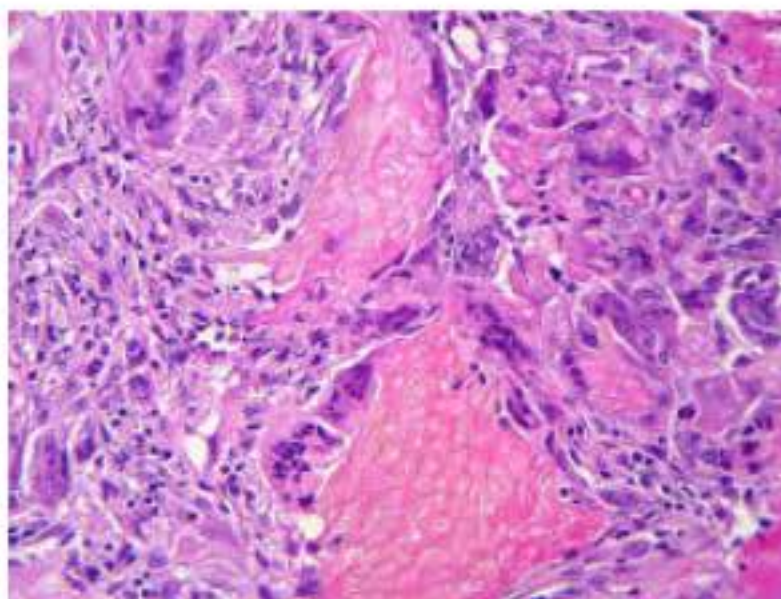


Fig. 2: High powers view. Ghost cells (shadow cells) are associated with a granulomatous reaction. The ghost cells have a yellowish cast and this is common in this type of keratin

Demographic data, clinical finding, the site, size, color, and malignant deformity of lesions were evaluated. The results were descriptively analyzed using χ^2 test with SPSS11.

RESULTS AND DISCUSSION

In this study we presented 46 cases of pilomatricoma. These cases were recognized from a total of 2470 dermal biopsies taken in dermatology ward of Boo-Ali Sina Hospital Sari, Iran from 1996-2006. Thirty two (69.56%) patients were female and 14 (30.44%) male. Mean age of the patients was 20.1 years (range 2- 68 years). The most common age group was 11-20 years. The most frequent sites of the tumor were the forearm (41.30%) arm (17.39%)(Table 1).

The color of lesions was cream 12 (26.08%) (Fig. 3), brown 6 (13.04), light cream 9 (19.56%), gray 9 (19.56%); skin color 4 (8.6%), light red 1(2.1%), brown 1 (2.1%) and white 1 (2.1%).

The size of most of the lesions was 0.85 cm, the largest size was 4 cm and the smallest was 0.1 cm seen in scalp and arm, respectively. In biopsy study, 22 cases had calcification. None of the cases had malignancy.

Pilomatricoma is a skin appendage tumor that frequently involves the skin of the head, neck and upper extremities in young children (Demircan and Balik, 1997). In a study by Cigliano *et al.* (2005) female/male ratio was 2: 1 and in Jjaggi's review study, the female to male ratio in 209 cases was 1.5: 1 (Demircan and Balik, 1997), but Lan *et al.* (2003) reported 0.97:1. In this study this ratio was 2.5 pilomatricoma can occur at any age (Lan *et al.*, 2003). However, most reported cases have occurred in children (Kaddu *et al.*, 1994; Demircan and Balik, 1997) and it is a rather uncommon neoplasm in

Table 1: Frequency distribution of the location in 46 cases with pilomatricoma referred to Boo-Ali-Sina hospital

Location	Frequency
Forearm	19(41.3%)
Arm	8(17.39%)
Neck	4(8.69%)
Eyelid	2(4.34%)
Face	2(4.34%)
Leg	2(4.34%)
thigh	2(4.34%)
Scalp	1(2.17)
Others	4(8.69%)

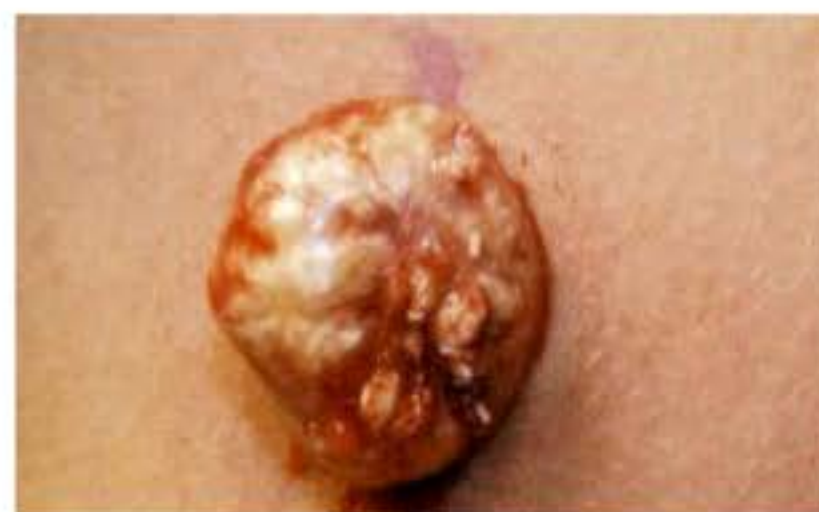

Fig. 3: The most common lesions color was cream

middle- age and old patients (Behnke *et al.*, 1998). Mean age in this study was 20.1 years (range: 2- 68 years). The most common age group was 11- 20 years. Jaggi found a bidominal pattern for age presentation: the first peak beings at 5-15 years and the second beings at 50-65 years (Kaddu *et al.*, 1994; Rao and Lin, 2006). Based on the literature the tumors occur mainly on the head and neck regions (Pulvermacker *et al.*, 2006; Pirouzmanesh *et al.*, 2005; Rao and Lin, 2006; Darwish *et al.*, 2001; Punia *et al.*, 2001) which is similar to our results. Head and neck were the most common location of the tumor reported by Kumaran *et al.* (2006) 73.31% and Cigliano *et al.* (2005) 56.5%. In another study, the sites affected most commonly were periorbital, periauricular and upper cervical regions, in a descending order (Al-Khateeb and Hamasha, 2007). In this study the most common site was upper limb though (58.69%).

The lesions have usually normal skin color but reddish purple lesions were observed (probably resulting from hemorrhage) (Rao and Lin, 2006). In this study the cream was the most common color (26%).

In several studies, tumor size ranged between 3-43 mm (Kumaran *et al.*, 2006; Lan *et al.*, 2003; Darwish *et al.*, 2001; Rao and Lin, 2006), we obtained a result varying amount of calcification was recorded in other studies (Darwish *et al.*, 2001). The percentage of pilomatricoma with calcification was shown in earlier series to range from 63 to 75% (Lan *et al.*, 2003). Demircan claimed that all cases had calcification in histopathology examination (Demircan and Balik, 1997)

but Kumaran and Jjaggy reported 91 and 75%, respectively of (Kumaran *et al.*, 2006; Rao and Lin, 2006). In the subjects this study was 49%. Pilomatrical carcinoma is uncommon (Rao and Lin, 2006). No invasive or malignancy lesion was observed by light microscopy (Demircan and Balik, 1997).

In this study, no malignancy observed too. Because preoperative diagnosis of pilomatricoma is usually difficult, careful clinical examination and a high index of suspicion would result in a more accurate diagnosis. Complete surgical excision is the treatment of choice.

REFERENCES

- Behnke, N., K. Schulte, T. Ruzicka and M. Megahed, 1998. Case report pilomatricoma in elderly individuals. *Dermatology*, 197: 391-393.
- Cigliano, B., N. Baltogiannis, M. De Marco, E. Faviou, A. Settimi and S. Tilemis *et al.*, 2005. Pilomatricoma in childhood: A retrospective study from three European pediatric centres. *Eur. J. Pediatr.*, 164: 673-677.
- Darwish, A.H., E.K. Al-Jalahema, A.K. Dhiman and K.A. Al-Khalifa, 2001. Clinicopathological study of pilomatricoma. *Saudi Med. J.*, 22: 268-271.
- Demircan, M. and E. Balik, 1997. Pilomatricoma in children: A prospective study. *Pediatr. Dermatol.*, 14: 430-432.
- Holme, S.A., S. Varma and P.J. Holt, 2001. The first case of exophytic pilomatricoma in an Asian male. *Pediatr. Dermatol.*, 18: 498-500.
- Kaddu, S., H.P. Soyer, L. Cerroni, W. Salmhofer and S. Hodl, 1994. Clinical and histopathologic spectrum of pilomatricomas in adul. *Int. J. Dermatol.*, 33: 705-708.
- Kumaran, N., A. Azmy, R. Carachi, P.A. Raine, J.H. Macfarlane and A.G. Howatson, 2006. Pilomatrixoma: Accuracy of clinical diagnosis. *J. Pediatr. Surg.*, 41: 1755-1758.
- Lan, M.Y., M.C. Lan, C.Y. Ho, W.Y. Li and C.Z. Lin, 2003. Pilomatricoma of the head and neck: A retrospective review of 179 cases. *Arch. Otolaryngol. Head Neck Surg.*, 129: 1327-1330.
- Pirouzmanesh, A., J.F. Reinisch, I. Gonzalez-Gomez, E.M. Smith and J.G. Meara, 2005. Pilomatrixoma: A review of 346 cases. *Plast. Reconstr. Surg.*, 112: 1784-1789.
- Pulvermacker, B., D. Seroussi, R. Haddad and M. Mitrofanoff, 2006. Pilomatricoma or calcifying epithelioma of Malherbe. A pediatric review of 89 cases. *Ann. Chir. Plast. Esthet.*
- Punia, R.P., A. Palta, A.J. Kanwar, G.P. Thami, R. Nada and H. Mohan, 2001. Pilomatricoma-a reprehensive analysis of 18 cases. *Ind. J. Pathol. Microbiol.*, 44: 321-324.
- Rao, J. and L. Lin, 2006. Pilomatrixoma. *Health on the Net Foundation*, pp: 1-10.