

<http://www.pjbs.org>

PJBS

ISSN 1028-8880

**Pakistan
Journal of Biological Sciences**

ANSI*net*

Asian Network for Scientific Information
308 Lasani Town, Sargodha Road, Faisalabad - Pakistan

Diagnostic Accuracy of Doppler Ultrasonography in Differentiation between Malignant and Benign Cervical Lymphadenopathies in Pediatric Age Group

¹M. Nemati, ²S. Aslanabadi, ¹A.S. Babil, ³D. Diaz, ¹H. Naziff, ⁴A. Rezamand, ⁵K. Ghabili and ¹N. Behravan

¹Department of Radiology, Tabriz University of Medical Sciences, Tabriz, Iran

²Division of Pediatric Surgery, Research Center of Children's Hospital,
Tabriz University of Medical Sciences, Tabriz, Iran

³Department of Surgery, Zanjan University of Medical Sciences, Zanjan, Iran

⁴Department of Pediatrics, Children's Hospital, Tabriz University of Medical Sciences, Tabriz, Iran

⁵Tuberculosis and Lung Disease Research Center, Tabriz University of Medical Sciences, Tabriz, Iran

Abstract: Cervical lymphadenopathy is a relatively common finding in pediatric age group and is caused by a wide spectrum of diseases from transient infections to malignancies especially lymphomas. The present study was aimed at evaluating the diagnostic performance of grey-scale ultrasonography, color Doppler ultrasonography and power Doppler ultrasonography in differentiation of reactively and metastatically enlarged cervical lymph nodes in pediatric age group. Fifty children with cervical lymphadenopathies were assessed by ultrasonographic methods. In each patient, the longest (L) and transverse (T) diameters, L/T ratio and presence or absence of the normal hilar pattern were checked by grey-scale ultrasonography. Spectral parameters (resistive and pulsatility indices) and vascular distribution pattern of nodes were recorded by color and power Doppler ultrasonography, respectively. Following the ultrasonographic evaluations, biopsy and/or clinical follow up was applied for six months, based on the clinical and paraclinical findings. Statistical analyses were performed by chi-square test, independent t-test and receiver operator characteristic curves. The mean age of patients was 12.42 ± 2.42 years. Twenty eight patients (56%) had malignant enlargement of lymph nodes. The mean value of L/T ratio in malignant group was 1.70 ± 0.22 and 2.40 ± 0.38 in non-malignant nodes ($p < 0.001$). Sensitivity, specificity and accuracy of combined grey-scale and power Doppler ultrasonography were 70, 86 and 81%, respectively. Combination of grey-scale and power Doppler ultrasonography is recommended for the differentiation between the malignant and benign lymphadenopathies in children. Moreover, our findings revealed no diagnostic role of color Doppler ultrasonography in the selection of malignant cervical lymph nodes in children.

Key words: Head and neck neoplasm, lymphadenitis, diagnosis, grey-scale ultrasonography, color Doppler ultrasonography, power Doppler ultrasonography

INTRODUCTION

Cervical lymphadenopathy is a common finding in children, since it can be the result of a wide variety of diseases from local and systemic infections to malignancies (Leung and Robson, 2004). As lymph node enlargement may be a part of clinical presentation of malignant process, detection of lymphadenopathy and differentiating the inflammatory lymphadenopathies (lymphadenitis) from the malignant involvements is clinically of utmost importance (Niedzielska *et al.*, 2007).

Although not satisfactory, clinical findings including size, tenderness and consistency of nodes are useful parameters in distinguishing between the malignant and

benign lymphadenopathies (Jordan and Tyrrell, 2004; Peters and Edwards, 2000). Sonographic studies including gray-scale (GSUS), color Doppler (CDUS) and power Doppler (PDUS) are complementary methods in detection and prediction of nature of the cervical nodes (Chan *et al.*, 2007). On gray-scale study, normal and reactive nodes are usually hypoechoic compared with the adjacent muscles and oval shaped (short to long axis of less than 0.5) (Chan *et al.*, 2007; Esen, 2006). In addition, benign nodes usually have a prominent echogenic hilum with regular border (Chan *et al.*, 2007; Esen, 2006; Ahuja and Ying, 2005). In contrast, malignant lymph nodes are larger, i.e. short axis of nodes is more than 9 mm, round shaped and usually hypoechoic (Chan *et al.*, 2007; Ahuja and Ying,

2005). Moreover, the normal echo pattern of hilum may be disturbed and distorted in malignancies and hilar echo may be absent or slit like. Besides, the margin of the nodes can be irregular, nodular and echo-free in malignancies, particularly in metastatic nodes from squamous cell carcinoma (Esen, 2006). CDUS using semi-quantitative indices including Resistive Index (RI) and Pulsatility Index (PI) can determine any changes in resistance of the vessels throughout the body including the intranodal vessels (Ying and Ahuja, 2003; Ghabili *et al.*, 2009). In PDUS, the vascular pattern of lymph nodes can be determined as avascular, hilar (single central artery with small and rare side branches), activated hilar and peripheral types (Ying *et al.*, 2000).

Since the causes of lymphadenopathies in children are different from those in adults along with the technical differences between children and adults, we performed this study to determine the accuracy of GSUS, CDUS and PDUS in distinguishing the malignant cervical lymph node enlargements from the benign lymphadenopathies in pediatric age group.

MATERIALS AND METHODS

In an analytic-descriptive cross sectional study from May 2007 to December 2008 at the university-affiliated Children's Hospital, fifty children with cervical lymphadenopathies were enrolled to be assessed by ultrasonographic methods. In each patient, at first the largest node was detected by GSUS, then the longest and transverse diameters of the node, L/T ratio and also presence or absence of the normal hilar pattern were checked. These were followed by color Doppler study, using adjusted parameters for detection of low velocity and low volume flows. The pulse repetition frequency (PRF) and the wall filter were set up at 500-750 and 50 Hz, respectively. Resistive Index (RI) and pulsatility index (PI) were measured at the biggest artery of the largest node. Finally the largest node was studied by power Doppler. Vascular distribution pattern of nodes were classified as: normal hilar pattern (avascular or only a delicate central artery with small and rare side branches), activated hilar pattern (a large central artery with multiple and large side branches) and peripheral pattern (multiple subcapsular arteries entering the periphery of the nodes). All the indicated ultrasonographic indices were measured by three radiologists (M.N., A.S., H.N.) without prior knowledge of any information concerning the pathology of the patient's lymphadenopathy. An Ultrasonix XP machine with a 10-14 MHz multi-frequency linear array transducer was employed for gray scale, color Doppler and power Doppler evaluations of the nodes. Following

the ultrasonographic evaluations, biopsy and/or clinical follow up was applied for six months, based on the clinical and paraclinical findings. Sonographic findings were compared with the histological and follow up results of the patients. The research deputy and ethics committee approved this study. An informed consent was obtained from the parents before the study.

Data were presented as Mean±SD. Statistical analysis was performed with SPSS for windows version 13.0 using Chi-square test, Fisher's exact test and Independent-Samples t-test, whenever appropriate. Receiver operator characteristic (ROC) curves were used to set the assessment point for L/T ratio, RI and PI. A p-value less than 0.05 was considered statistically significant.

RESULTS

Fifty children with cervical lymphadenopathy enrolled in the present study. The mean age of patients was 12.42±2.42 years and 32 patients (64%) were male and 18 (36%) were female. Based on the biopsy results and clinical outcomes, 28 patients (56%) had malignant enlargement of cervical lymph nodes and the final diagnosis in the remaining 22 patients (44%) was lymphadenitis. In malignant group, the cause of lymphadenopathy was lymphoma in 26 patients (92.9%) and metastasis in 2 patients (7.1%). The mean value of L/T ratio in malignant group was 1.70±0.22 and 2.40±0.38 in non-malignant nodes (p<0.001, Independent-Samples t-test, Table 1). Characteristics of both the malignant and benign lymph nodes are shown in Table 1.

Based on the ROC curve, the cutoff point for L/T ratio was 1.92 with sensitivity of 100% and specificity of 78.6% (p<0.001, Fig. 1). In GSUS assessment of the nodes, no margin irregularity, intranodal necrosis and microcalcification was detected. In evaluation of cervical lymphadenopathies, GSUS and PDUS had overall sensitivity of 70.2%, specificity of 86.7%, positive predictive value of 81.2%, negative predictive value of 78.5% and accuracy of 81%. Diagnostic values of GSUS and PDUS in differentiation between malignant and benign cervical lymph nodes are listed in Table 2.

Table 1: Characteristics of examined lymph nodes

Characteristics	Malignant lymph nodes (n = 28)	Benign lymph nodes (n = 22)	p-value
Gender (male:female)	16:12	16:6	0.254 ^a
Age (years)	12.29±2.89	12.59±1.68	0.662 ^b
Largest diameter (cm)	1.90±0.62	1.70±0.63	0.250 ^b
L/T ratio	1.70±0.22	2.40±0.38	<0.001 ^{b*}
RI	0.60±0.02	0.59±0.02	0.164 ^b
PI	0.96±0.03	0.95±0.03	0.824 ^b

L/T: Longitudinal-to-transverse; RI: Resistive index; PI: Pulsatility index.
^aStatistically significant (p<0.05), ^bChi-square test or Fisher's exact test, ^bIndependent-Samples t-test

Table 2: Diagnostic value of GSUS and PDUS in differentiation between malignant and benign cervical lymph nodes[†]

Ultrasonography modes	Sensitivity	Specificity	Positive predictive value	Negative predictive value	Accuracy
GSUS (L/T ratio)	68.2 (45-86)	78.6 (59-92)	71.4 (48-89)	75.9 (56-89)	74
GSUS (hilar echogenic pattern)	59.1 (36-79)	89.2 (72-98)	81.3 (54-96)	73.5 (56-87)	76
PDUS	68.2 (45-86)	85.7 (67-96)	79 (54-94)	77.4 (59-90)	78
US (overall)	70.2 (44-88)	86.7 (52-96)	81.2 (54-94)	78.5 (59-92)	81

GSUS, Gray-scale ultrasonography; L/T, longitudinal-to-transverse; PDUS, power Doppler ultrasonography; US, ultrasonography; [†]Numbers in parentheses are 95% confidence intervals

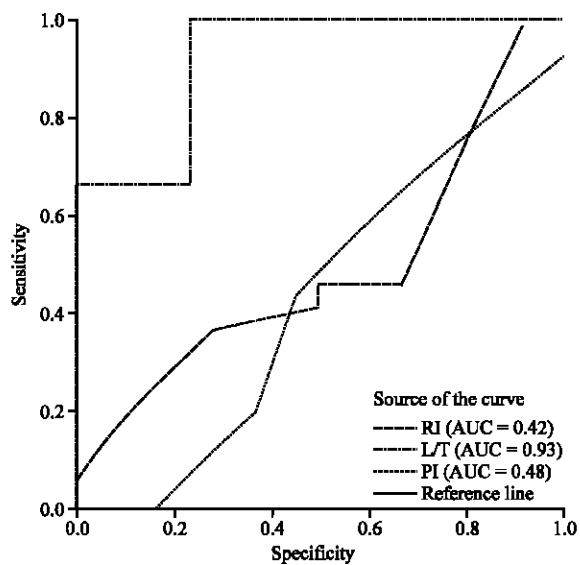


Fig. 1: Receiver operating characteristic curve for L/T ratio, RI and PI. AUC, area under the curve; L/T, longitudinal-to-transverse; RI, resistive index; PI, pulsatility index

DISCUSSION

Ultrasonography is now widely used for diagnosis of numerous pediatric diseases (Cina *et al.*, 2009; Nemati *et al.*, 2009). Meanwhile, in evaluation of the cervical masses, ultrasonography not only is able to distinguish the lymph nodes from other solid and cystic masses, but also differentiates between malignant and benign nodes with an acceptable accuracy in adults (Castelijns and van den Brekel, 2002). In malignancies, the nodes are larger, L/T ratio is lower and hilar echogenic focus is absent or slit like (Chan *et al.*, 2007; Esen, 2006; Ahuja and Ying, 2005). Different values of nodal size ranging from 7-10 mm have been recommended as indicator of malignancy for cervical lymph nodes (Peters and Edwards, 2000). In the current study, malignant lymph nodes far exceeded this range; however this was not significantly different from that of reactive nodes. This finding reveals the limited value of the nodal size in differentiation between the malignant and benign cervical lymphadenopathies in children. Although Esen (2006) regarded L/T ratio among the less valuable determinants

in the evaluation of lymph nodes, a low L/T ratio was the only predicting parameter of the malignancy in our investigation. Furthermore, the cutoff point of L/T ratio in the present study was highly similar to that of the previous studies (1.92 vs. <2) with high sensitivity and specificity (Krishna *et al.*, 2008; Asai *et al.*, 2001).

Although vascular resistance is believed to be increased in metastasis, some investigations have failed to indicate RI and PI as differentiating indices in metastatic lymph nodes (Adibelli *et al.*, 1998; Ahuja and Ying, 2003a; Esen *et al.*, 2005). Likewise, CDUS was not useful in contrasting between the malignant and nonmalignant nodes in our study; no significant increase in nodal resistance was detected in malignant lymph nodes. We believe that different etiologies of malignant nodal involvement in children and adults (lymphoma vs. metastasis) may give rise to such discordance. Therefore, the authors do not recommend the spectral parameters (RI and PI) for predicting the malignancy of cervical lymph nodes in children.

Using power Doppler, normal and inflammatory nodes are avascular or have only a delicate central artery without prominent side branches (Castelijns and van den Brekel, 2002). In metastasis, peripheral neovascularization occurs and therefore the vascular pattern of nodes would be peripheral type (Ariji *et al.*, 1998). In our study, PDUS had high specificity but low sensitivity, similar to those reported by Lyshechik *et al.* (2007). In contrast, Ahuja and Ying (2003b) indicated high sensitivity and specificity of PDUS in distinguishing metastatic from reactive nodes. Although PDUS showed higher sensitivity and specificity compared to GSUS, we believe that the value of PDUS cannot compete with that of biopsy in the diagnosis of metastatic lymphadenopathy. Similarly, despite the high accuracy (~80%) of the combination of PDUS and GSUS, biopsy is recommended in suspicious conditions.

In conclusion, combination of GSUS and PDUS is recommended for the differentiation between the malignant and benign enlargement of cervical lymph nodes in pediatric age group. Nonetheless, the diagnostic cytology should not be replaced by any imaging modalities due to their suboptimal efficacy. On the other hand, our findings do not indicate the diagnostic role of CDUS (RI and PI) in the selection of suspicious neck lymph nodes in children.

ACKNOWLEDGMENT

This study was financially supported by a grant from vice chancellor for research, Tabriz University of Medical Sciences, Iran.

REFERENCES

- Adibelli, Z.H., G. Unal, E. Gul, F. Uslu, U. Koçak and Y. Abali, 1998. Differentiation of benign and malignant cervical lymph nodes: Value of B-mode and color Doppler sonography. *Eur. J. Radiol.*, 28: 230-234.
- Ahuja, A. and M. Ying, 2003a. Sonographic evaluation of cervical lymphadenopathy: Is power Doppler sonography routinely indicated. *Ultrasound Med. Biol.*, 29: 353-359.
- Ahuja, A. and M. Ying, 2003b. Sonography of neck lymph nodes. Part II: Abnormal lymph nodes. *Clin. Radiol.*, 58: 359-366.
- Ahuja, A.T. and M. Ying, 2005. Sonographic evaluation of cervical lymph nodes. *Am. J. Roentgenol.*, 184: 1691-1699.
- Ariji, Y., Y. Kimura, N. Hayashi, T. Onitsuka and K. Yonetsu *et al.*, 1998. Power Doppler sonography of cervical lymph nodes in patients with head and neck cancer. *AJNR Am. J. Neuroradiol.*, 19: 303-307.
- Asai, S., H. Miyachi, S. Oshima, C. Kawakami, M. Kubota and Y. Ando, 2001. A scoring system for ultrasonographic differentiation between cervical malignant lymphoma and benign lymphadenitis. *Rinsho. Byori.*, 49: 613-619.
- Castelijns, J.A. and M.W. van den Brekel, 2002. Imaging of lymphadenopathy in the neck. *Eur. Radiol.*, 12: 727-738.
- Chan, J.M., L.K. Shin and R.B. Jeffrey, 2007. Ultrasonography of abnormal neck lymph nodes. *Ultrasound Q.*, 23: 47-54.
- Cina, M., F. Rahim and M. Davudi, 2009. The accuracy of ultrasonography technique in detection of the intussusception. *J. Applied Sci.*, 9: 3922-3926.
- Esen, G., 2006. Ultrasound of superficial lymph nodes. *Eur. J. Radiol.*, 58: 345-359.
- Esen, G., B. Gurses, M.H. Yilmaz, S. Ilvan and S. Ulus *et al.*, 2005. Gray scale and power Doppler US in the preoperative evaluation of axillary metastases in breast cancer patients with no palpable lymph nodes. *Eur. Radiol.*, 15: 1215-1223.
- Ghabili, K., H.T. Khosroshahi, A. Shakeri, R.S. Tubbs, A. Bahluli and M.M. Shoja, 2009. Can Doppler ultrasonographic indices of the renal artery predict the presence of supernumerary renal arteries? *Transplant. Proc.*, 41: 2731-2733.
- Jordan, N. and J. Tyrrell, 2004. Management of enlarged cervical lymph nodes. *Curr. Paediatr.*, 14: 154-159.
- Krishna, R.P., S.C. Sistla, R. Smile and R. Krishnan, 2008. Sonography: An underutilized diagnostic tool in the assessment of metastatic groin nodes. *J. Clin. Ultrasound*, 36: 212-217.
- Leung, A.K. and W.L. Robson, 2004. Childhood cervical lymphadenopathy. *J. Pediatr. Health Care*, 18: 3-7.
- Lyshchik, A., T. Higashi, R. Asato, S. Tanaka and J. Ito *et al.*, 2007. Cervical lymph node metastases: Diagnosis at sonoelastography-initial experience. *Radiology*, 243: 258-267.
- Nemati, M., M. Rafeey and A.B. Shakeri, 2009. Ultrasound findings in biliary atresia: The role of triangular cord sign. *Pak. J. Biol. Sci.*, 12: 95-97.
- Niedzielska, G., M. Kotowski, A. Niedzielski, E. Dybiec and P. Wieczorek, 2007. Cervical lymphadenopathy in children-incidence and diagnostic management. *Int. J. Pediatr. Otorhinolaryngol.*, 71: 51-56.
- Peters, T.R. and K.M. Edwards, 2000. Cervical lymphadenopathy and adenitis. *Pediatr. Rev.*, 21: 399-405.
- Ying, M., A. Ahuja, F. Brook and C. Metreweli, 2000. Power Doppler sonography of normal cervical lymph nodes. *J. Ultrasound Med.*, 19: 511-517.
- Ying, M. and A. Ahuja, 2003. Sonography of neck lymph nodes. Part I: Normal lymph nodes. *Clin. Radiol.*, 58: 351-358.