

<http://www.pjbs.org>

PJBS

ISSN 1028-8880

**Pakistan
Journal of Biological Sciences**

ANSI*net*

Asian Network for Scientific Information
308 Lasani Town, Sargodha Road, Faisalabad - Pakistan

Chemopreventive Potential of 18 β -glycyrrhetic Acid: An Active Constituent of Liquorice, in 7,12-dimethylbenz(a)anthracene Induced Hamster Buccal Pouch Carcinogenesis

¹R. Kowsalya, ²P. Vishwanathan and ¹S. Manoharan

¹Department of Biochemistry and Biotechnology, Faculty of Science, Annamalai University, Annamalainagar-608 002, Tamil Nadu, India

²Department of Pathology, Faculty of Medicine, Annamalai University, Annamalainagar-608 002, Tamil Nadu, India

Abstract: Chemoprevention, a useful and attractive approach in experimental oncology, helps to investigate the cancer preventive potential of natural products and synthetic entities. Present study evaluated the chemopreventive potential of glycyrrhetic acid in 7,12-dimethylbenz(a)anthracene (DMBA) induced hamster buccal pouch carcinogenesis. Oral tumor was developed in the buccal pouch of golden Syrian hamsters by painting with DMBA three times a week for 14 weeks. The tumor incidence and the status of phase I and phase II detoxification enzymes were assessed in hamsters treated with DMBA alone and DMBA+glycyrrhetic acid treated hamsters. One hundred percent tumor formations, which were histopathologically confirmed as well-differentiated squamous cell carcinoma, were observed in hamsters treated with DMBA alone. Also, the status of detoxification enzymes were markedly altered in the liver and buccal mucosa of hamsters treated with DMBA alone. Oral administration of glycyrrhetic acid at a dose of 45 mg kg⁻¹ body weight to hamsters treated with DMBA completely prevented the tumor formation as well as restored the status of detoxification enzymes. Present study thus demonstrated the chemopreventive potential of glycyrrhetic acid in DMBA induced oral carcinogenesis.

Key words: Oral cancer, glycyrrhetic acid, hamsters, detoxification enzymes, chemoprevention, DMBA

INTRODUCTION

Oral cancers are the world's 5th most frequent neoplasm and accounts for 3-4% in Western countries and 40-50% in developing countries including India (Chatterjee, 2011). Oral cancers are cancers that develop at the lips, tongue, salivary glands, gingival, floor of the mouth, oropharynx, buccal surfaces and other intra-oral locations. Squamous cell carcinoma accounts for 90% of the cancers of oral cavity (Tsantouils *et al.*, 2007). Tobacco chewing, tobacco smoking, betel quid chewing and alcohol consumption contribute mainly to the pathogenesis of oral cancer (Wen *et al.*, 2010). Despite recent efforts to improve the treatment and overall outcomes of oral cancer, 5 year survival rates have not changed drastically during the last three to four decades. Late diagnosis and poor response of advanced cancerous lesions to chemotherapy are responsible for the low 5 year survival rate of oral cancer patients (Pereira *et al.*, 2007). Oral carcinogenesis is preceded by premalignant lesions, leukoplakia, erythroplakia and oral submucous fibrosis and these precancerous lesions succumb to oral cancer in one third of the patients (Gatoo *et al.*, 2011).

Golden Syrian hamsters are one of the best characterized animal models for oral carcinogenesis on account of its pocket like anatomical (buccal pouch) features. DMBA-induced hamster buccal pouch carcinogenesis mimics the sequential common events involved in the development of premalignant and malignant human oral cancers. Also, the histological, morphological, biochemical and molecular changes observed in hamster buccal pouch carcinogenesis closely resembles the features of human oral tumor (Manoharan *et al.*, 2010). 7,12-dimethylbenz(a)anthracene, a potent procarcinogen, on metabolic activation in the liver is converted into its active ultimate carcinogenic metabolite dihydrodiol epoxide, which subsequently form DNA adducts with adenine and guanine residues (Weimer *et al.*, 2000). Several molecular markers including p53 and bcl-2 were over expressed in DMBA induced hamster buccal pouch carcinogenesis (Panjamurthy *et al.*, 2009).

Liver phase I (Cytochrome P₄₅₀, cytochrome b₅) and phase II (glutathione-S-transferase, oxidized glutathione, reduced glutathione, DT-diaphorase) detoxification agents play a crucial role in the metabolic activation and

detoxification of xenobiotics including DMBA (Pugalendhi and Manoharan, 2010; Renju *et al.*, 2007). Glutathione-S-transferase and glutathione reductase play vital role in the detoxification of carcinogenic metabolites. Measurement of these agents in the liver should therefore be helpful to assess the antitumor initiating and antitumor promoting effects of natural products and synthetic entities (Senthil *et al.*, 2007; Suresh *et al.*, 2006).

18 β -glycyrrhetic acid, a pentacyclic triterpenoid derivative and the active aglycone of Glycyrrizin, is present in the herb liquorice. It is used in flavoring and has the property to mask the bitter taste of drugs like aloe and quinine. Diverse pharmacological effects, of glycyrrhetic acid have been reported, which include anti-ulcer, anti-inflammatory, antiviral, hepatoprotective antioxidant and anti-tussive properties (Wang *et al.*, 2011; Maitraie *et al.*, 2009). Nishino *et al.* (1986) reported that 18 β -glycyrrhetic acid significantly inhibited the growth of skin cancer cells under *in vitro* conditions. There were however no scientific studies on the potential of glycyrrhetic acid against DMBA-induced oral carcinogenesis. Agents that possess inhibitory effect on cell proliferation and modulating effect on phase I and phase II detoxification enzymes activities are considered as potent chemopreventive agent. The present study was therefore designed to investigate the chemopreventive potential of glycyrrhetic acid by analyzing the tumor incidence as well as by measuring the status of phase I and phase II detoxification enzymes in DMBA-induced hamster buccal pouch carcinogenesis.

MATERIALS AND METHODS

Chemicals: DMBA and Glycyrrhetic acid were obtained from Sigma-Aldrich Chemical Pvt. Ltd., Bangalore, India. All other chemicals used were of analytical grade, purchased from Hi-media Laboratories, Mumbai, India.

Animals and treatment: Male golden Syrian hamsters, aged 8-10 weeks, weighing 80-120 g, were purchased from the National Institute of Nutrition, Hyderabad, India and were maintained in the Central Animal House, Rajah Muthaiah Medical College and Hospital, Annamalai University. The animals were housed five in a polypropylene cage and provided with a standard pellet diet (Agro Corporation Pvt, Ltd., Bangalore, India) and water ad libitum. The animals were maintained under controlled conditions of temperature (27 \pm 2 $^{\circ}$ C) and humidity (55 \pm 5%) with a 12 h light/dark cycle.

The institutional Animal Ethics Committee (Reg. No. 160/1999/CPCSEA). Annamalai University, Annamalainagar, India approved the experimental design (Proposal No. 550: dated 20-03-2008). A total number of 40

hamsters were randomized into four groups and each group contained 10 hamsters. Group I animals served as the control and were treated with liquid paraffin (Vehicle) alone three times a week for 14 weeks on their left buccal pouches. Group II animals were treated with 0.5% DMBA in liquid paraffin three times a week for 14 weeks on their left buccal pouches. Group II animals received no other treatment. Group III animals were treated with DMBA as in group II, received in addition oral administration of glycyrrhetic acid (45 mg kg⁻¹ body weight/day), dissolved in 1 mL of water, starting 1 week before exposure to the carcinogen and continued on alternate days to DMBA painting until the animals were sacrificed. Group IV animals received oral administration of glycyrrhetic acid (45 mg kg⁻¹ body weight/day) alone, as in group III, throughout the experimental period. The experiment was terminated at the end of 16 weeks and all animals were sacrificed by cervical dislocation. Biochemical studies were conducted on the plasma, liver and buccal mucosa tissues. For histopathological examination, buccal mucosa tissues were fixed in 10% formalin and routinely processed and embedded with paraffin, 2-3 μ m sections were cut in a rotary microtome and stained with haematoxylin and eosin.

Induction of oral squamous cell carcinogenesis: Tumors were induced in each hamster's buccal pouch with topical application of 0.5% DMBA in liquid paraffin three times a week for 14 weeks. The total number of tumors in the hamster's buccal pouch was determined macroscopically at the time of sacrifice of animals.

Sample (Plasma and tissue preparation): Blood samples were collected into heparinized tubes. Plasma was separated by centrifugation at 1000x g for 15 min. Tissue sample from the animals were washed with ice cold saline and homogenized using an appropriate buffer (GST: 0.3 M phosphate buffer, pH 6.5; GR: 0.1 M phosphate buffer, pH 7.4; TBARS: 0.025 M Tris-HCL buffer, pH 7.5; GSH and GPX: 0.4 M phosphate buffer, pH 7.0; SOD: 0.025 M sodium pyrophosphate buffer pH 8.3; CAT: 0.01 M phosphate buffer, pH 7.0) in an all-glass homogenizer with a Teflon pestle and used for biochemical estimations.

Biochemical analysis: The activity of glutathione-S-transferase in liver and buccal mucosa tissue homogenate was assayed using the method employed by Habig *et al.* (1974). Glutathione reductase activity in liver tissue homogenate was assayed using the method employed by Carlberg and Mannervik, (1985). The levels of cytochrome P450 and b5 in the liver buccal mucosa were determined according to the method of Omura and Sato (1964). The activity of DT diaphorase in the liver was

estimated according to the method of Ernster (1967). The reduced glutathione levels in the buccal mucosa were determined by the method described by Beutler and Kelley (1963). The oxidised glutathione level in the buccal mucosa was determined by the method of Tietze (1969).

Protein determination: The protein content was determined by the method of Lowry *et al.* (1951).

Statistical analysis: The data is expressed as Mean±standard deviation (SD). Statistical comparisons for biochemical parameters were performed by one-way analysis of variance followed by Duncan's Multiple Range Test (DMRT). The tumor incidence was, however, statistically analyzed using Chi-Square (χ^2) test. The results were considered statistically significant if the p-values were less than 0.05.

RESULTS

Incidence of oral neoplasm: The incidence of oral neoplasm and histopathological abnormalities in control and experimental animals in each group are shown in Table 1. The tumor incidence was 100% in hamsters

treated with DMBA alone and tumors were histopathologically confirmed as well-differentiated squamous cell carcinoma. The total number of oral tumors in the buccal pouches was counted and the diameter of each tumor was measured with a vernier caliper. Oral administration of glycyrrhetic acid (45 mg kg^{-1} body weight/day), on alternate days to DMBA painting, to DMBA treated hamsters for 14 weeks completely prevented the formation of oral squamous cell carcinoma.

Histopathology: The histopathological features observed in the buccal mucosa of the control and experimental animals in each group are shown in Fig. 1. We observed severe hyperkeratosis, hyperplasia, dysplasia and well-differentiated squamous cell carcinoma in the buccal pouches of DMBA alone treated hamsters (Fig. 1b).

Although well-differentiated squamous cell carcinoma was not seen in the buccal pouches of DMBA+glycyrrhetic acid treated hamsters, mild hyperplasia, hyperkeratosis and dysplasia were noticed (Fig. 1c). Hamsters administered with glycyrrhetic acid alone showed well-defined and intact epithelial layers similar to that of the control hamsters (Fig. 1a, d).

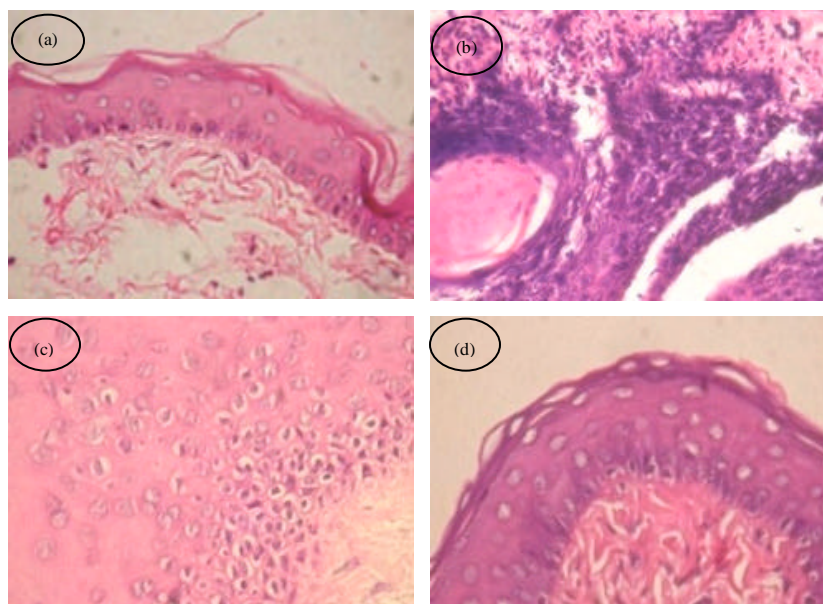


Fig. 1 (a-d): Histopathological features observed in the buccal mucosa of control and experimental animals in each group. (a and d) Photomicrographs showing well-defined buccal pouch epithelium from control and glycyrrhetic acid alone treated hamsters, respectively (H and E, 40X). (b) Photomicrograph showing well-differentiated squamous cell carcinoma with keratin pearls in hamsters treated with DMBA alone (H and E, 40X). (c) Photomicrograph showing moderate dysplastic epithelium in hamsters treated with DMBA+glycyrrhetic acid (H and E 40X)

Table 1: Incidence of oral neoplasm and histopathological changes in the buccal pouch of control and treated animals in each group (n = 10)

Parameter	Control	DMBA alone	DMBA+GA	GA alone
Tumor incidence (oral squamous cell carcinoma)	0%	100%	0%	0%
Total number of tumors /animals	0	36/(10)	0	0
Tumor multiplicity	0	3.6	0	0
Tumor frequency	0	36	0	0
Tumor volume (mm ³)/animals	0	397.59±32.10	0	0
Tumor burden (mm ³) / animals	0	1431.32±128.79	0	0
Hyperkeratosis	Absent	Severe	Absent	Absent
Hyperplasia	Absent	Severe	Absent	Absent
Dysplasia	Absent	Severe	Absent	Absent
Squamous cell carcinoma	Absent	Well differentiated	Absent	Absent

Tumor volume was measured using the formula, $v = (4/3)\pi[D_1/2][D_2/2][D_3/2]$, where D₁, D₂ and D₃ are the three diameter(mm) of the tumor. Tumor burden was calculated by multiplying tumor volume and the number of tumors/animal. Tumor multiplicity = average number of tumors per animal. Tumor frequency. No. of tumors per group. *Significantly different from group II by Chi-Square (χ^2) test. Values that do not share a common superscript in the same row differ significantly at p<0.05

Status of liver phase I and phase II detoxification agents:

The status of phase I (Cytochromes P450 and b5) and phase II (Reduced glutathione (GSH), Glutathione-S-Transferase (GST), Glutathione Reductase (GR) and DT-diaphorase) detoxification agents in the liver of control and experimental animals in each group are given in Fig. 2a. The status of phase I detoxification enzymes was significantly increased whereas phase II detoxification agents were decreased in the liver of DMBA treated animal (p<0.05) as compared to control animals. Oral administration of glycyrrhetic acid to DMBA-treated animals brought back the status of phase I and phase II detoxification agents to near normal range in the liver (p<0.05). Oral administration of glycyrrhetic acid alone showed no significant difference as compared to control animals.

Status of buccal mucosa phase I and phase II detoxification agents:

Figure 2b shows the status of phase I and phase II detoxification agents in the buccal mucosa of control and treated hamsters in each group. The status of phase I (Cytochrome P450 and b5) and phase II detoxification agents Glutathione-S-Transferase (GST) and reduced glutathione (GSH) were significantly increased whereas oxidised glutathione (GSSG) content was decreased in tumor bearing hamsters (p<0.05) as compared to control hamsters. Oral administration of glycyrrhetic acid to DMBA treated hamsters significantly brought back the status of GSH, GSSG and GST to near normal range (p<0.05). Hamsters treated with glycyrrhetic acid alone showed no significant difference in the status of GSH, GSSG and GST as compared to control hamsters.

DISCUSSION

Chemoprevention a novel, promising and appealing strategy in experimental oncology, deals with inhibition,

suppress or reversal of cancer, using natural products and synthetic agents. Profound studies documented the chemopreventive potential of medicinal plants and their active constituents (Senthil *et al.*, 2007; Sarwar *et al.*, 2011). Cancer of the oral cavity is the one among the few human cancers with the vast potential for prevention.

Aim of the present study was to focus the chemopreventive potential of glycyrrhetic acid in DMBA-induced hamster buccal pouch carcinogenesis. The antitumor efficacy of glycyrrhetic acid was assessed by monitoring the tumor incidence as well as by estimating the status of phase I and phase II detoxification enzymes in DMBA induced oral carcinogenesis. DMBA induced hamster buccal pouch carcinogenesis is preceded by a sequence of precancerous lesions such as hyperplasia, hyperkeratosis and dysplasia, which are quite similar to that of tumors that develop in oral cancer patients. In the present study, we noticed 100% tumor formation in hamsters treated with DMBA alone at the end of experimental period and the tumors were histopathologically confirmed as well-differentiated squamous cell carcinoma also, we noticed severe hyperplasia, hyperkeratosis and dysplasia at 8 to 10th week of DMBA treatment in hamsters treated with DMBA alone.

The pleomorphic hyperchromatic nucleus with epithelial pearl formation was observed in the tumor cells of tumor bearing hamsters. A well defined and intact epithelial layer was seen in control hamsters and hamsters treated with glycyrrhetic acid alone. In the present study, dose dependent effect of glycyrrhetic acid was studied to find out the optimum dose of glycyrrhetic acid for chemoprevention studies. Of three doses used (15, 30 and 45 mg kg⁻¹ body weight) the doses of 45 mg kg⁻¹ body weight completely prevented tumor formation in hamster treated with DMBA and thus the same dose was fixed for further chemoprevention studies. Oral administration of glycyrrhetic acid at a dose of

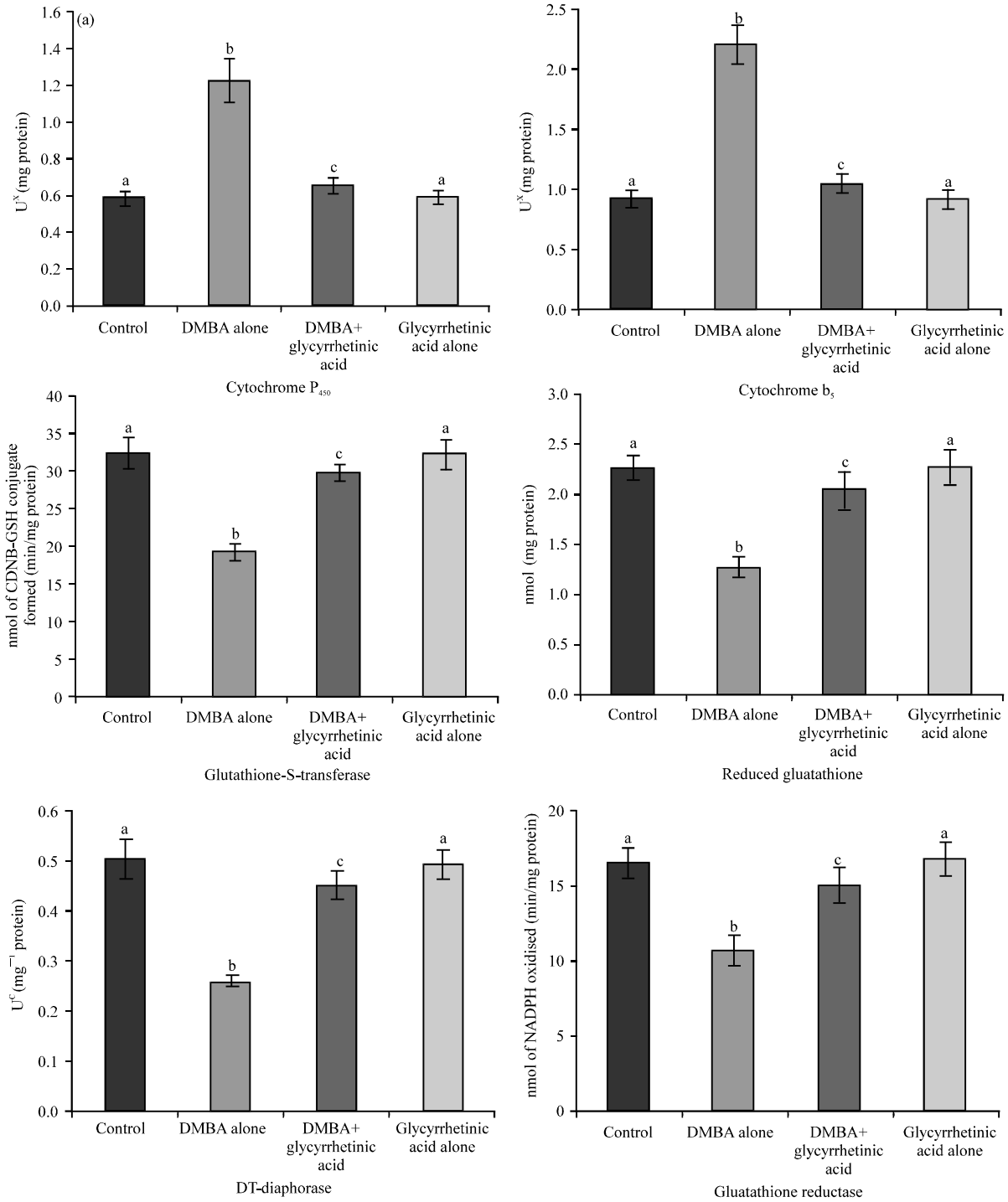


Fig. 2a: Status of Phase I detoxification agents in the liver and buccal mucosa, respectively of control and experimental animals in each group. Values are expressed as Mean±SD for 10 hamsters in each group. Values that do not share a common superscript in the same column differ significantly at $p < 0.05$ (DMRT). X-micromoles of cytochrome P₄₅₀; Y- micromoles of cytochrome b₅; C-micromoles of 2,6-dichlorophenol reduced per minute. A- micromoles of 1-chloro 2,4 dinitrobenzene (CDNB)/reduced glutathione conjugate formed per minute

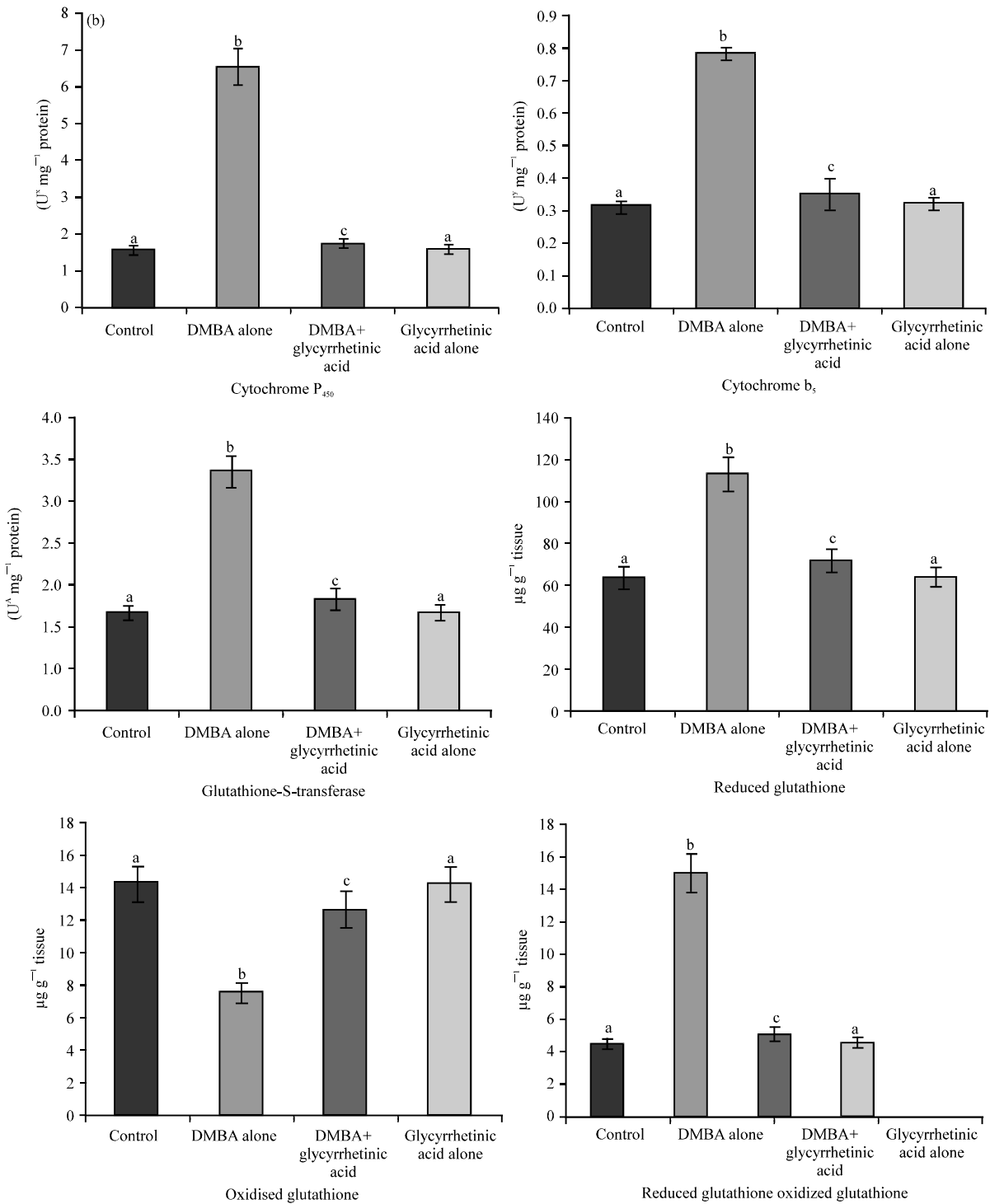


Fig. 2b: Status of Phase II detoxification agents in the liver and buccal mucosa, respectively of control and experimental animals in each group. Values are expressed as Mean±SD for 10 hamsters in each group. Values that do not share a common superscript in the same column differ significantly at p<0.05 (DMRT). X-micromoles of cytochrome P₄₅₀; Y- micromoles of cytochrome b₅; C-micromoles of 2,6-dichlorophenol reduced per minute. A- micromoles of 1-chloro 2,4 dinitrobenzene (CDNB)/reduced glutathione conjugate formed per minute

45 mg kg⁻¹ body weight to hamster treated with DMBA however resulted in mild hyperplasia and dysplasia, which may be due to repeated DMBA exposure to the buccal pouch of hamsters.

Present results thus suggest that glycyrrhetic acid exhibited significant chemopreventive potential by suppressing abnormal cell proliferation occurring during DMBA induced oral carcinogenesis. Liver, the primary site for the biotransformation of xenobiotics, plays significant role in the modulation of carcinogenic processes. Estimation of xenobiotic biotransformation enzymes such as cytochrome P₄₅₀, cytochrome b₅, glutathione-S-transferase, glutathione reductase and reduced glutathione in liver and buccal mucosa could provide valuable information about the chemopreventive potential of the test compound under evaluation (Pugalendhi and Manoharan, 2010; Aisha *et al.*, 2011). Our results support these findings. Profound scientific evidences suggest that substances that stimulated the activities of detoxification enzymes such as glutathione-S-transferase have promising chemopreventive potential (Coles and Kadlubar, 2003; Baskaran *et al.*, 2010). Our results support these findings. Phase II detoxification enzymes excrete carcinogenic metabolites either by conjugation with reduced glutathione or by destroying the reactive centres of carcinogens (Manoharan *et al.*, 2009; Kumar *et al.*, 2011). Accumulation of carcinogenic metabolite in the liver, due to elevated activities of phase I enzymes and decreased activities of phase II enzymes were reported in tumor bearing animals (Kavitha and Manoharan, 2006). Present results corroborate these findings. Increased activities of phase I and phase II detoxification enzymes in the buccal mucosa of tumor bearing hamsters are probably due to repeated DMBA exposure to the buccal mucosa, where these enzymes are stimulated to metabolically activate and detoxify the carcinogenic reagents. Altered activities of phase I and phase II detoxification enzymes were reported in the liver and buccal mucosa of hamsters treated with DMBA (Letchoumy *et al.*, 2006; Panjamurthy *et al.*, 2008). Our results support these findings. Oral administrations of glycyrrhetic acid at a dose of 45 mg kg⁻¹ body weight reversed the activities of phase I and phase II detoxification enzymes to near normal level in hamsters treated with DMBA. Present results suggest that glycyrrhetic acid might have inhibited the metabolic activation of DMBA or facilitated the excretion of carcinogenic metabolites during DMBA-induced oral carcinogenesis. Present study thus demonstrated that chemopreventive potential of glycyrrhetic acid in DMBA induced hamster buccal pouch carcinogenesis.

CONCLUSION

18β-glycyrrhetic acid, an active constituent of liquorice, significantly suppressed the formation of oral tumors in DMBA induced hamster buccal pouch carcinogenesis. The chemopreventive potential of glycyrrhetic acid is probably due to its anti-cell proliferative effect and modulating effect on detoxification enzymes during DMBA induced hamster buccal pouch carcinogenesis. In order to provide scientific validity to the chemopreventive potential of glycyrrhetic acid, further researches are warranted to study the effect of glycyrrhetic acid on the expression of molecular markers that are related to oral carcinogenesis.

ACKNOWLEDGMENTS

The authors gratefully acknowledge Mr. V. Vinoth Kumar and G. Sindhu for their valuable help during experimental studies.

REFERENCES

- Aisha, A.F.A., Z.D. Nassar, M.J. Siddiqui, K.M. Abu-Salah, S.A. Alrokayan, Z. Ismail and A.M.S. Abdul-Majid, 2011. Evaluation of antiangiogenic, cytotoxic and antioxidant effects of *Syzygium aromaticum* L. extracts. Asian J. Biol. Sci., 4: 282-290.
- Baskaran, N., S. Manoharan, S. Balakrishnan and P. Pugalendhi, 2010. Chemopreventive potential of ferulic acid in 7,12-dimethylbenz[a]anthracene-induced mammary carcinogenesis in Sprague-Dawley rats. Eur. J. Pharmacol., 637: 22-29.
- Beutler, E. and B.M. Kelley, 1963. The effect of sodium nitrite on red cell GSH. Experientia, 19: 96-97.
- Carlberg, I. and B. Mannervik, 1985. Glutathione reductase. Method Enzymol., 113: 484-490.
- Chatterjee, A., 2011. Study on the enraging severity of cancer in West Bengal, India from 2003 to 2010. Asia. J. Epidemiol, 4: 23-27.
- Coles, B.F. and F.F. Kadlubar, 2003. Detoxification of electrophilic compounds by glutathione S-transferase catalysis: Determinants of individual response to chemical carcinogens and chemotherapeutic drugs? Biofactors, 17: 115-130.
- Ernster, L., 1967. DT-diaphorase. Methods Enzymol., 10: 309-317.
- Gatoo, M.A., M. Siddiqui, A.K. Farhan, M.I. Kozgar and M. Owais, 2011. Oral cancer and gene polymorphisms: International status with special reference to India. Asian J. Biochem., 6: 113-121.

- Habig, W.H., M.J. Pabst and W.B. Jakoby, 1974. Glutathione-S-transferases. The first enzymatic step in mercapturic acid formation. *J. Biol. Chem.*, 249: 7130-7139.
- Kavitha, K. and S. Manoharan, 2006. Anticarcinogenic and antilipidperoxidative effects of *Tephrosia purpurea* (Linn.) Pers. in 7,12-dimethylbenz (a) anthracene (DMBA) induced hamster buccal pouch carcinoma. *Indian J. Pharmacol.*, 38: 185-189.
- Kumar, S.S., M.R.K. Rao and M.P. Balasubramanian, 2011. Anticarcinogenic effect of indigofera aspalathoides on 20-methylcholanthrene induced fibrosarcoma in rats. *Res. J. Med. Plant*, 5: 747-755.
- Letchoumy, P.V., K.V.C. Mohan, R. Kumaraguruparan, Y. Hara and S. Nagini, 2006. Black tea polyphenols protect against 7,12-dimethylbenz[a]anthracene-induced hamster buccal pouch carcinogenesis. *Oncol. Res.*, 16: 167-178.
- Lowry, O.H., N.J. Rosebrough, A.L. Farr and R.J. Randall, 1951. Protein measurement with Folin phenol reagent. *J. Biol. Chem.*, 193: 265-275.
- Maitraie, D., C.F. Hung, H.Y. Tu, Y.T. Liou and B.L. Wei, 2009. Synthesis, anti-inflammatory and antioxidant activities of 18beta-glycyrrhetic acid derivatives as chemical mediators and xanthine oxidase inhibitors. *Bioorg. Med. Chem.*, 17: 2785-2792.
- Manoharan, S., M.S.V. Selvan, S. Silvan, N. Baskaran, A.K. Singh and V.V. Kumar, 2010. Carnosic acid: A potent chemopreventive agent against oral carcinogenesis. *Chem. Biol. Interact.*, 188: 616-622.
- Manoharan, S., S. Balakrishnan, V.P. Menon, L.M. Alias and A.R. Reena, 2009. Chemopreventive efficacy of curcumin and piperine during 7,12-dimethylbenz[a]anthracene-induced hamster buccal pouch carcinogenesis. *Singapore Med. J.* 50: 139-146.
- Nishino, H., K. Yoshioka, A. Iwashima, H. Takizawa and S. Konishi *et al.*, 1986. Glycyrrhetic acid inhibits tumour promoting activity of teleocidin and 12-O-tetradecanoylphorbol-13-acetate in two stage mouse skin carcinogenesis. *Jpn. J. Cancer Res.*, 77: 33-38.
- Omura, T. and R. Sato, 1964. The carbon monoxide-binding pigment of liver microsomes. I. Evidence for its hemoprotein nature. *J. Biol. Chem.*, 239: 2370-2378.
- Panjamurthy, K., S. Manoharan, S. Balakrishnan, K. Suresh, M.R. Nirmal, N. Senthil and L.M. Alias, 2008. Protective effect of withaferin-A on micronucleus frequency and detoxication agents during experimental oral carcinogenesis. *Afr. J. Tradit. Complement Alternative Med.*, 6: 1-8.
- Panjamurthy, K., S. Manoharan, M.R. Nirmal and L. Vellaichamy, 2009. Protective role of withaferin-A on immunoexpression of p53 and bcl-2 in 7,12-dimethylbenz(a)anthracene-induced experimental oral carcinogenesis. *Invest. New. Drugs*, 27: 447-452.
- Pereira, M.C., D.T. Oliveira, G. Landman and L.P. Kowalski, 2007. Histologic subtypes of oral squamous cell carcinoma: Prognostic relevance. *J. Can. Dent. Assoc.*, 73: 339-344.
- Pugalendhi, P. and S. Manoharan, 2010. Chemopreventive potential of genistein and daidzein in combination during 7,12-dimethylbenz(a)anthracene (DMBA) induced mammary carcinogenesis in sprague-dawley rats. *Pak. J. Biol. Sci.*, 13: 279-286.
- Renju, G.L., S. Manoharan, S. Balakrishnan and N. Senthil, 2007. Chemopreventive and antilipid peroxidative potential of *Cleodendron inereme* (L) Gaertn in 7,12-dimethylbenz(a)anthracene induced skin carcinogenesis in Swiss albino mice. *Pak. J. Biol. Sci.*, 10: 1465-1470.
- Sarwar, M., I.H. Attitalla and M. Abdollahi, 2011. A review on the recent advances in pharmacological studies on medicinal plants: Animal studies are done but clinical studies needs completing. *Asian J. Anim. Veterinary Adv.*, 6: 867-883.
- Senthil, N., S. Manoharan, S. Balakrishnan, R. Ramachandran and C.R. Muralinaidu, 2007. Chemopreventive and antilipidperoxidative efficacy of *Piper longum* (Linn) on 7,12-dimethylbenz(a) anthracene (DMBA) induced hamster buccal pouch carcinogenesis. *J. Applied Sci.*, 7: 1036-1042.
- Suresh, K., S. Manoharan, K. Panjamurthy and K. Kavitha, 2006. Chemopreventive and antilipidperoxidative efficacy of *Annona squamosa* bark extracts in experimental oral carcinogenesis. *Pak. J. Biol. Sci.*, 9: 2600-2605.
- Tietze, F., 1969. Enzymic method for quantitative determination of nanogram amounts of total and oxidized glutathione: Applications to mammalian blood and other tissues. *Anal. Biochem.*, 27: 502-522.
- Tsantouils, P.K., N.G. Kastrinakis, A.D. Tourvas, G. Laskaris and V.G. Goryoulis, 2007. Advances in the biology of oral cancer. *Oral Oncol.*, 43: 523-534.
- Wang, C.Y., T.C. Kao, W.H. Lo and G.C. Yen, 2011. Glycyrrhizic acid and 18β-glycyrrhetic acid modulate lipopolysaccharide-induced inflammatory response by suppression of nf-κb through pi3k p110δ and p110β inhibitions. *J. Agric. Food. Chem.*, 59: 7726-7733.
- Weimer, T.L., A.P. Reddy, U. Harttig, D. Alexander and S.C. Stamm *et al.*, 2000. Influence of β-naphthoflavone on 7,12-dimethylbenz(a)anthracene metabolism, DNA adduction and tumorigenicity in rainbow trout. *Toxicol. Sci.*, 57: 217-228.
- Wen, C.P., M.K. Tsai, W.S. Chung, H.L. Hsu and Y.C. Chang *et al.*, 2010. Cancer risks from betel quid chewing beyond oral cancer: A multiple-site carcinogen when acting with smoking. *Cancer Causes Control*, 21: 1427-1435.