

<http://www.pjbs.org>

**PJBS**

ISSN 1028-8880

**Pakistan  
Journal of Biological Sciences**

**ANSI***net*

Asian Network for Scientific Information  
308 Lasani Town, Sargodha Road, Faisalabad - Pakistan

## Histopathological Effects of Short and Long Term Treatment of *Orchis antolica* Crude Root Extract on Female Albino Rats Fertility and Pregnancy

<sup>1</sup>Nabil, A. Khouri and <sup>2</sup>Haytham Daradka

<sup>1</sup>Department of Anatomy, Faculty of Medicine, Jordan University of Science and Technology, Jordan

<sup>2</sup>Department of Biological Sciences, Faculty of Science, Jerash University, Jordan

**Abstract:** The present study has investigated the effects of *Orchis antolica* (dose of 400 mg/kg/Body Weight) on female rats reproductive system for two time periods 4 and 12 weeks. Forty adult female Sprague-Dawley rats were divided into two treatment and two control groups of 10 rats each. The two treated groups received 400 mg/kg/body weight of *Orchis antolica* for two periods of 4 and 12 weeks. Female rats were allowed mating with untreated males when treatment ended. Pregnancy parameters such as: total number of pregnancy, body weight, reproductive organ weight, number of implantation sites, number of resorption sites and number of viable fetuses. The significance of these results was calculated using student's "t" and Chi-square tests. Treatment with *Orchis antolica* for 4 weeks did not have any significant effects on most parameters investigated except for a slight increase in the relative ovarian and embryo weights. *Orchis antolica* for 12 weeks induces a significant increase in the percentage of pregnancies and the number of implantation sites when compared with controls. Further, an increase in ovarian weights and in viable fetuses count was also observed. Histological sections of treated female ovaries were found to have an empty blood vessels within the cortical and modularly regions. We also noted an increase in the developing follicles at primary and secondary stages in addition to an absence of degenerative areas and increased cellularity in medulla. Long term treatment with *Orchis antolica* might lead to diversified positive effects on fertility and pregnancy in female rats.

**Key words:** *Orchis antolica*, female rats, fertility, pregnancy, reproductive organs

### INTRODUCTION

The ovarian Corpus Luteum (CL) is a temporary endocrine structure in mammals. Ovarian follicles generate the CL during the luteal phase of the estrous cycle. The CL also induces the production of both estrogen (E2) and progesterone (P4) when stimulated by pituitary gonadotropins. This stimulation is directed via both the Follicle Stimulating Hormone (FSH) and Luteinizing Hormone (LH) inducing endometrium development and maintains embryonic implantation of the uterine endometrium. If fertilization occurred, P4 plays a crucial role in maintaining the pregnancy after implantation (Findlay, 1986; Haas and Ramsey, 2009). It is well known that the P4 insufficiency causes spontaneous miscarriage and its supplementation could potentially maintain the pregnancy. However, there is no evidence to support the routine use of P4 to prevent miscarriage in early to mid-pregnancy (Sugino and Okuda, 2007).

Oxidative stress on the other hand, could be implicated in inducing an imbalance between Reactive

Oxygen Species (ROS) and the biological antioxidant systems that could lead to variety of oxidative modification including DNA, lipids and proteins alterations. It has been postulated that oxidative stress could play an important role in the normal function of the female reproductive system and in the pathogenesis of female infertility (Agarwal *et al.*, 2004). In addition, a delicate balance between ROS and antioxidant enzymes including several superoxide dismutase (SOD), catalase and glutathione peroxidases in the ovarian tissues might exist. Suzuki *et al.* (1999) reported that SOD was localized in human ovaries under the normal follicular cycling (Lagod *et al.*, 2001). It has been indicated that treatment with Orchis has an effect on the levels of some biochemical markers observed in renal injury like reduction of glutathione, glutathione S-Transferase and Superoxide dismutase (Gutierrez *et al.*, 2010). In addition it can reduce blood urea and serum creatinine concentrations and lipid peroxidation induced in diabetes and it can also be a potential source of natural nephro-protective source (Gutierrez *et al.*, 2010). Our preliminary

results indicated that when mice were treated with *Orchis anatolica*, a hypo-glycemic activity can be observed (Khoury *et al.*, 2006). In addition, our preliminary investigation indicate the presence of some compounds such as Flavonoids, Triallate, Theobromade and Tannins compounds which are considered to possess an antioxidant activities in addition to Testosterone.

Further, the antioxidant enzymes usually neutralize and protect the oocyte and embryo from excessive ROS. Simsek *et al.* (1998) reported that oxidative stress has been implicated in various levels producing recurrent loss of pregnancy (Simsek *et al.*, 1998). It was also observed that biochemical markers for ROS-induced membrane damage, such as lipid peroxidation products, reach their high levels immediately before miscarriage (Sane *et al.*, 1991). Furthermore, an oxidant/antioxidant imbalance has also been reported to be associated with miscarriage (Lagod *et al.*, 2001).

The objectives of this study were to investigate the effects of *O. anatolica* (400 mg kg<sup>-1</sup> b.wt.) on the reproductive system after administration to female Sprague-Dawley rats weighting 250-300 g for two time periods 4 and 12 weeks.

## MATERIALS AND METHODS

**Animals:** This study was approved by the Animals Ethics Committee at Jordan University of Science and Technology JUST. Adult female Sprague-Dawley rats (40) weighing 250-300 g were used in this study. Rats were raised in the animal house unit at JUST under a controlled temperature of 21±1.0°C and 12 h light/dark cycle. Animals were feed with regular diet (manufactured by the Faculty of Veterinary Medicine at JUST, according to standard recipes) and water was provided *ad libitum*.

**Treatment with *O. anatolica*:** Female rats were randomly divided into two treatment and control groups and the treatment group further subdivided into two subgroups; a short duration (4 weeks) and long duration (12 weeks) treatment groups. *O. anatolica* was dissolved in normal saline and the experimental rats receive treatment through an intra-gastric tube administration at a concentration of 400 mg kg<sup>-1</sup> b.wt. as one morning dose.

Experimental rats were divided into 4 groups:

- Group 1 consists of 10 female rats treated for a period of 4 weeks
- Group 2 consist of 10 female rats treated for a period of 12 weeks
- Group 3 and 4 consist of 20 female rats receive no treatment

All rats were allowed normal diet and access to drinking water during all experimental time periods.

**Fertility test:** Routine daily rats' observation treated with *O. anatolica* for clinical signs of toxicity was done. Treated female rats body weights were measured in weekly bases. After each treatment time period, treated and control groups of rats were divided randomly into subgroups. Each subgroup contains two female rats that were caged with a sexually active and mature male rat of the same strain for ten days and allowed mating. Male rats were left exposed to mate with female rats for sufficient period of time insuring that at least two estrous cycles have elapsed during this exposure time (Lane-Petter and Pearson, 1971). The occurrence of implantation was estimated in treated and the control female rats after the appropriate time of mating exposure.

After this mating time, treated and control counterparts female rats were weighted and sacrificed by cervical dislocation under light ether anesthesia. Autopsy was performed and the following parameters in both groups were recorded: the number of implantation sites, the number of viable fetuses and the number of resorption sites. Furthermore, uterus weights, ovary weight in addition to the embryo weights were recorded. Finally appropriate specimens of the uterus and ovaries were collected for histological studies.

**Histological studies:** The Bouin's fixed the excised of ovaries of females ingested the *O. anatolica* treatment, beside to their control were cut into small pieces and processed according to standard Eosin-Hematoxylin techniques. The paraffin embedding was followed by sectioning (5 um) and staining (Harris haematoxyline and eosin). Finally slides were studied under light microscopy and results concluded.

**Statistical analysis:** Data was expressed as Mean± Standard Deviation (SD). The differences between *Orchis anatolica* treated and controlled groups were analyzed using Student 't' test (Dixon and Massey, 1957).

## RESULTS

**Exposure toxicity of *O. anatolica*:** None of the treated female rats used in this experiment in both treatment periods showed any clinical signs of toxicity.

**The effects of *O. anatolica* on fertility:** Short term 4 weeks treatment with *O. anatolica* extract (group 1) revealed a slight but insignificant increase in the rate of impregnation, the number of implantation sites, as well as the number of viable fetuses when compared with

Table 1a: The effect of 4-week exposure to *O. antolica* on fertility of female rats

| Treatment          | No. of Pregnant females | No. of implantation | No. of viable Fetuses | Rats of resorption sites (%) | No of resorption sites /total No. of implantation sites (%) |
|--------------------|-------------------------|---------------------|-----------------------|------------------------------|---|
| Control            | 8/10                    | 9.01±1.35           | 8.86±2.17             | 5/10 (50)                    | 6/72 (8.33)   |
| <i>O. antolica</i> | 8/10                    | 9.22±2.87           | 8.91±0.33             | 4/10 (40)                    | 17/70 (6.84)  |

Results are expressed as Means±SEM. \*p<0.05: Significantly different from the control group (Student's t test). † p<0.05: significantly different from the control group (Fisher exact test)

Table 1b: The effect of 12-week exposure to *O. antolica* on fertility of female rats

| Treatment          | No. of pregnant females | No. of implantation | No. of Viable fetuses | Rats of resorption sites (%) | No of resorption sites /total No. of implantation sites (%) |
|--------------------|-------------------------|---------------------|-----------------------|------------------------------|---|
| Control            | 8/10                    | 9.01±1.35           | 8.86 ±2.17            | 5/10 (50)                    | 6/72 (8.33)   |
| <i>O. antolica</i> | 9/10 †                  | 9.45±2.11*          | 9.19±1.52*            | 3/10 (30)                    | 4/85 (4.70)   |

Results are expressed as Means±SEM. \*p<0.05: Significantly different from the control group (Student's t test). † p<0.05: significantly different from the control group (Fisher exact test)

controls (Table 1a). A slight but not significant decrease in the percentage rate of resorption site was observed in this group when compared with controls. Furthermore, the ratio between resorption and the total number of implantation observed also to be slightly decreased (Table 1a).

The effects of 12 weeks treatment with *O. antolica* (group 2) on fertility indicate that there is a significant increases in the percentage of impregnated when compared with controls (Table 1b). Moreover, table 1b also indicates that this long term treatment induces also an increase in both the number of implantation sites as well as the number of viable fetuses to a statistically significant level. Results also indicate that the percentage of resorption sites in treated female rats for this period is reduced, where the ratio between the resorption sites and the number of implantation was significantly increase (Table 1b).

**The effects of *O. antolica* on maternal and embryo weight:** Treatment with *O. antolica* for 4 weeks resulted in a slight but insignificant increase in female rat's total body as well as uterine weights (Table 2a). An significance increase in the relative ovarian and embryo weights in this group was observed when compared with control counterparts (Table 2a).

Furthermore, treatment with *O. antolica* for 12 weeks resulted in a significant increase in both the relative ovarian and the embryo weights when compared to control group (Table 2b). No differences were observed in the final body weigh or in the uterine weight in rats treated rats for 12 weeks when compared with controls but in contrary, a slight reduction can be noticed (Table 2b).

**Histological outcome:** All ovarian histological preparation obtained from females organs treated with *O. antolica* (Fig. 1, 2) indicate certain structural variation if compared with their control counterparts. Ovarian thin histological sections obtained from females treated with *Orchis antolica* for 12 weeks indicate the an initiation of corpus luteum regeneration

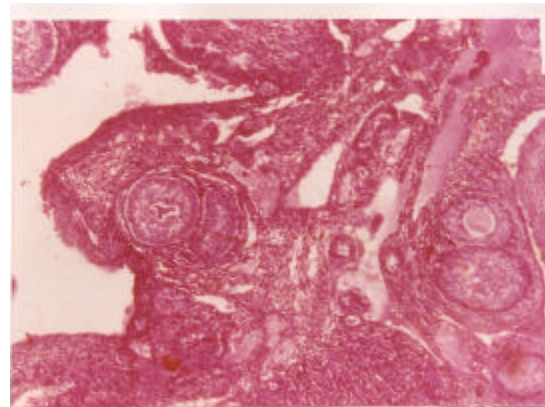


Fig. 1: Cross section (5 µm thick) of ovaries stained with hematoxyline and eosin. Ovary sections of adult female rats (control group) showing developing normally oocytes in different stages. A: Secondary follicle. B: Normal medullary structure

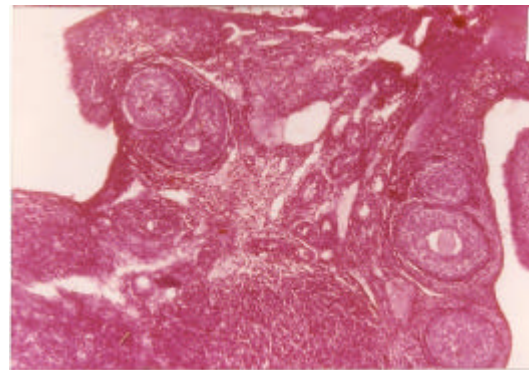


Fig. 2: Cross section (5 µm thick) of ovaries of treated female rats ovary stained with hematoxyline and eosin. Ovary sections showing more developing oocytes in different stages. A: Secodary follicle. B: increase medullary structure

represented by an active angiogenetic changes indicated by the presence of elevated congested blood vessels number. In exchange, a low congested blood vessels were observed surrounding the corpus luteum and in the medulla whereas, however, some section showed increased number of developing follicles. Normal fluid-filled cavities were present in most section and a thicker corpus luteum with significant number of developing follicles at primary, secondary and tertiary stages were instant feature.

### DISCUSSION

The animal model used in this work has been previously used by several other workers to assess the adverse effects of other extract obtained from medicinal plants on reproductive functions in rat males (Purohit and Daradka, 1999; Khouri *et al.*, 2007; Daradka, 2009; Allouh *et al.*, 2010).

This study was conducted to investigate the exposure effect of *O. antolica* on reproductive organ structure, fertility and the pregnancy outcome of adult female Sprague-Dawley rats. The dose of 400 mg kg<sup>-1</sup> of *O. antolica* was selected to obtain broader range of information on the effects of this plant on the reproduction parameters. Two different time periods were selected namely 4 and 12 weeks to evaluate long and short period treatment effects of this treatment. It is worthwhile to mention that to our knowledge, no work has been published in the literature that relates the effects of *O. antolica* to structure, fertility and pregnancy outcome. These findings are in accordance with our results which showed that the exposure of adult female rats to *O. antolica* for 4 weeks had neither toxic, nor significant effects on the rat's fertility parameters or structure of the reproductive system. However, a slight increase in the relative ovarian weights and a significant increase in the embryo weight in rats treated for 4 weeks were observed. On the other hand, an increase in the exposure period for 12 weeks using similar dose of this plant extract revealed a significant increase in both the relative ovarian and embryo weights when compared to controls.

Histological changes in ovaries of females treated with *O. antolica* extract provide a clear evidence of reproductive effect of *Orchis antolica* extract ingestion. Regeneration of corpus luteum stimulates pregnancy maintenance in cases of successive implantation. Also, the stimulate of developing follicles at primary and secondary stages with the presence of increased number of developing follicles at primary stage may result in elevation in the final number of mature graafian follicles produced. Furthermore, the presence of regeneration areas and hypocellularity in medulla may interfere with migration of developing follicles and motivate their future development.

Other important finding in this study is that the extract used could promote an increase in Sprague-Dawley female rats' fertility when intra-gastric administration for long period of time was applied. This was indicated by the increase in the reproductive organ weights observed in this group of rats. However, the weights of reproductive organs were markedly increased as shown in Table 2a and 2b which might be explained by the fact that the reproductive organ weights can be closely regulated by androgen hormones (Richard *et al.*, 2000). If so, we can hypothesises that this extract may act on the hypothalamic-pituitary ovarian axis which may lead to a decrease in the main hormones influencing oogenesis and subsequent pregnancy. The increase in the weight of reproductive organs can be explained by the possible increase in the level of androgen hormones that could be increased in the experimental group of rats. The unexplained increase in the ovarian weights in treated rats needs to be clarified through both hormonal and histological analysis. In addition, the future use of advanced molecular methodologies might elucidate the pathway through which this drug acts to decrease the weight of the ovaries observed in this study. These results, therefore, suggest that any disturbance of the reproductive endocrine functions may possibly and can go hand in hand with multiple sites of androgenic toxicity acting along the hypothalamic-pituitary-ovarian-uterine axis.

Other main finding of this current study was the significant increase in the occurrence of pregnancy in rats

Table 2a: The effect of 4 weeks exposure to *O. antolica* on maternal body, organ and embryo weights

| Treatment          | Final body weight (g) | Ovary weight (g) (mg/100 g b.wt.) | Uterus weight (g) (mg/100 g b.wt.) | Embryo weight (g) (mg/100 g b.wt.) |
|--------------------|-----------------------|-----------------------------------|------------------------------------|------------------------------------|
| Control            | 259±13.43             | 0.37±0.02                         | 0.53± 0.03                         | 0.34± 0.01                         |
| <i>O. antolica</i> | 266±11.67             | 0.39 ±0.05*                       | 0.57±0.07                          | 0.37±0.08                          |

† Results are expressed as Means±SEM. \* p<0.05, † p<0.01: Significantly different from the control group (Student's t test)

Table 2b: The effect of 12 weeks exposure to *O. antolica* on maternal body, organ and embryo weights

| Treatment          | Final body weight (g) | Ovary weight (g) (mg/100 g b.wt.) | Uterus weight (g) (mg/100 g b.wt.) | Embryo weight (g) (mg/100 g b.wt.) |
|--------------------|-----------------------|-----------------------------------|------------------------------------|------------------------------------|
| Control            | 259±13.43             | 0.37±0.02                         | 0.53±0.03                          | 0.34±0.01                          |
| <i>O. antolica</i> | 278±15.65             | 0.46±0.05*                        | 0.62±0.04                          | 0.44±0.21                          |

† Results are expressed as Means±SEM. \* p<0.05, † p<0.01: Significantly different from the control group (Student's t test)

exposed to *O. antolica* for 12 weeks. This increase may be due to long functional period of the endocrine functions that might lead to increased secretion of progesterone which is needed for endometrial alteration at the time of implantation and is necessary for successful impregnation (Choudhary and Steinberger, 1975; Agrawal *et al.*, 1986). This is in accordance with our results indicating the significant increase in the number of implantation sites which could lead to the increase in viable fetus's number. We are now conducting another study to investigate the effects of *O. antolica* exposure on serum progesterone levels. In conclusion, the results of the current study suggest that ingestion of *O. antolica* by adult female rats causes enhance effects on fertility and reproduction.

### REFERENCES

- Agarwal, A., S.S.R. Allamaneni and T.M. Said, 2004. Chemiluminescence technique for measuring reactive oxygen species. *Reprod. Biomed. Online*, 9: 466-468.
- Agrawal, S., S. Chauhan and R. Mathur, 1986. Antifertility effects of embelin in male rats. *Andrologia*, 18: 125-131.
- Allouh, M.Z., N.A. Khouri, H.M. Daradka and E.G. Kaddumi, 2010. *Orchis anatolica* root ingestion improves sexual motivation and performance in male rats. *J. Complementary Integr. Med.*, Vol. 7. 10.2202/1553-3840.1462
- Choudhary, A. and E. Steinberger, 1975. Effect of 5 $\alpha$ -reduced androgen on sex accessory organs, initiation and maintenance of spermatogenesis in the rat. *Biol. Reprod.*, 12: 609-617.
- Daradka, H.M., 2009. The effect of *Salvia fruticosa* ingestion on male rat sexual behavior. *Res. J. Biol. Sci.*, 4: 1288-1291.
- Dixon, W. and F.J. Massey, 1957. *Introduction of Statistical Analysis*. McGraw Hill Book Co., New York, Pages: 228.
- Findlay, J.K., 1986. Angiogenesis in reproductive tissues. *J. Endocrinol.*, 111: 357-366.
- Gutierrez, R.M., Y.G. Gomez and E.B. Ramirez, 2010. Nephroprotective activity of *Prosthechea michuacana* against cisplatin-induced acute renal failure in rats. *J. Med. Food*, 13: 911-916.
- Haas, D.M. and P.S. Ramsey, 2009. Progesterone for preventing miscarriage. *Cochrane Lib.*, 10.1002/14651858.CD003511.pub2
- Khouri, N.A., M. Nawasreh, S.M. Al-Hussain and A.S. Alkofahi, 2006. Effects of orchids (*Orchis anatolica*) on reproductive function and fertility in adult male mice. *Reprod. Med. Biol.*, 5: 269-276.
- Khouri, N.A., Z. El-Akawi and H. Daradka, 2007. The effect of short-term treatment with *Citrullus colocynthis* L. on the lipid profile and other blood biochemical parameters in albino rats. *Asian J. Chem.*, 19: 1468-1472.
- Lagod, L., T. Paszkowski, R. Sikorski and R. Rola, 2001. The antioxidant-prooxidant balance in pregnancy complicated by spontaneous abortion. *Ginekol Pol.*, 72: 1073-1078.
- Lane-Petter, W. and A.E.G. Pearson, 1971. *The Laboratory Animal Principles and Practice*. Academic Press Inc., London, Pages: 226.
- Purohit, A. and H.M.M. Daradka, 1999. Antiandrogenic efficacy of *Curcuma longa* (50% EtOH extract) with special emphasis on testicular cell population dynamics. *Indian Drugs*, 36: 142-143.
- Richard, A.F., R.E. Dewar, R.E. Schwartz and J. Ratsirarson, 2000. Mass change, environmental variability and female fertility in wild *Propithecus verreauxi*. *J. Hum. Evol.*, 39: 381-391.
- Sane, A.S., S.A. Chokshi, V.V. Mishra, D.P. Barad, V.C. Shah and S. Nagpal, 1991. Serum lipoperoxides in induced and spontaneous abortions. *Gynecol. Obstet. Invest.*, 31: 172-175.
- Simsek, M., M. Naziroglu, H. Simsek, M. Cay, M. Aksakal and S. Kumru, 1998. Blood plasma levels of lipoperoxides, glutathione peroxidase, beta carotene, vitamin A and E in women with habitual abortion. *Cell. Biochem. Funct.*, 16: 227-231.
- Sugino, N. and K. Okuda, 2007. Species-related differences in the mechanism of apoptosis during structural luteolysis. *J. Reprod. Dev.*, 53: 977-986.
- Suzuki, T., N. Sugino, T. Fukaya, S. Sugiyama and T. Uda *et al.*, 1999. Superoxide dismutase in normal cycling human ovaries: Immunohistochemical localization and characterization. *Fertil. Steril.*, 72: 720-726.