

<http://www.pjbs.org>

PJBS

ISSN 1028-8880

Pakistan Journal of Biological Sciences

ANSI*net*

Asian Network for Scientific Information
308 Lasani Town, Sargodha Road, Faisalabad - Pakistan

Using a Vascularized Bone Graft from the Distal Metaphysis of Radius in Treating Scaphoid Nonunion: First Report from a Developing Country

Jafar Ganjpour Sales, Mohamad Irajian, Asghar Elmi,
Jafar Soleimanpour Mokhtar Manand and Amin Moradi

Department of Orthopedics, Tabriz University of Medical Sciences, Shohada Hospital, Tabriz, Iran

Abstract: Scaphoid fractures are common and prone to nonunion if left untreated. In this study, the outcome of using a vascularized bone graft was investigated in scaphoid nonunion. Twenty patients with scaphoid nonunion were recruited from Shohada Hospital. A reverse-flow vascularized bone graft was obtained from the distal metaphysis of radius and inserted into the gap of scaphoid fracture. Long and short thumb spica casts were used for 1.5 and 2 months thereafter, respectively. Union, motion, pain and the patients' satisfaction rate were documented. Twenty patients, 19 males and 1 female, with a mean age of 25.15 ± 6.62 (range: 17-40) years were studied. The fractures were in the waist of the bone in 17 cases and in the proximal pole in 3 cases. Preoperative pain and pain plus compromised grip strength were reported in 11 and 9 patients, respectively. The rate of patients with pain decreased significantly after operation (100 to 25%; $p < 0.001$). Complications happened in 7 patients (35%) after operation including pin fracture ($n = 2$), change of occupation ($n = 2$), nonunion ($n = 1$), delayed union ($n = 1$) and irritation ($n = 1$). Union achieved after 10.71 ± 1.62 (range: 8-14) weeks in average, post-operation. Mayo wrist score improved significantly at the endpoint. The range of motion of the wrist did not change significantly after operation. Eighty percent of the patients rated the satisfaction rate as good to excellent. This study is the first one from a developing country indicating that the technique of using a reverse-flow vascularized bone graft in treating scaphoid nonunion is considerably successful and safe.

Key words: Scaphoid fracture, vascularized, bone graft, nonunion, mayo wrist score, patient's satisfaction rate

INTRODUCTION

The scaphoid fracture is one of the most common fractures in the wrist (Ong *et al.*, 2011). Despite a high frequency, almost 40% of the scaphoid fractures are missed during primary examination and consequently, nonunion and accompanying devastating complications are not rare (Raju and Kini, 2011).

Among these complications are disabling pain, gradually progressing anatomical changes in the wrist leading to its osteoarthritis and dysfunction and finally deterioration of routine activity and even job loss (Kuschner *et al.*, 1994).

The importance of the scaphoid bone is mainly associated with its pivotal contribution to the integrity of the anatomy of the wrist. It is shown that this bone almost always involves in any movement of the wrist. Thus, any abnormality in its shape and connections with its contiguous bony structures in the form of fracture, luxation/subluxation, or change in the peripheral supporting tendons and ligaments may cause a fundamental weakening of the affected wrist (An *et al.*, 1991).

The treatment of scaphoid nonunion is a great challenge even in the hands of adroit orthopedics surgeon. The rate of failure is about 22-50% in the cases undergoing open surgical repair of scaphoid nonunion (Slade and Gillon, 2008).

Although, there have been several methods of fixation of delayed scaphoid fracture (i.e., >4 weeks), a state-of-the-art technique has been introduced in these cases which is claimed to be very efficient and safe. In this technique, a reverse-flow pedicled Vascularized Bone Grafts (VBGs) is detached from the distal radius and interposed in the missed fracture of the scaphoid. It is estimated that this technique is successful in over 85% of the patients (Rafert and Long, 1991).

The high rate of success comparing with traditional methods is believed to be due to the tenuous blood supply to the scaphoid which leaves the fractures of this bone utterly vulnerable to nonunion and avascular necrosis (Chang *et al.*, 2006).

By using a vascularized bone graft, however, this imperfection is completely lifted, leading to better healing of the fracture with minimal rate of such complications (Sheetz *et al.*, 1995).

In this study, the results of treating the scaphoid nonunion with a reverse-flow pedicled VBG are reported for the first time from an orthopedics center in a developing country.

MATERIALS AND METHODS

In this quasi-experimental study, 20 patients with scaphoid nonunion were recruited from a teaching orthopedics center (Shohada Hospital) in Tabriz-Iran, from January 2009 to June 2012. Reverse-flow pedicle Vascularized Bone Grafts (VBGs) from the distal radius was employed to construct the fracture in all patients. This study was approved by the Ethics Committee of Tabriz University of Medical Sciences. An informed written concept was obtained from patients before operation.

Upon the admission, patient's previous medical history was inquired and all the patients were thoroughly examined by an experienced orthopedics surgeon in terms of the sensory and motor function of the involved and the contralateral intact limb.

Anteroposterior and lateral views of the scaphoid were obtained by X-ray radiography (Fig. 1). Magnetic Resonance Imaging (MRI) was employed to examine the vascular status of the involved area.

Surgical technique: The scaphoid bone, as well as the distal region of the radius was exposed after a curved incision was performed on the radial margin of the wrist on the affected side (Fig. 2).

Between the first and second compartments, the 1,2 intercompartmental supraretinacular artery (1,2 ICSRA)

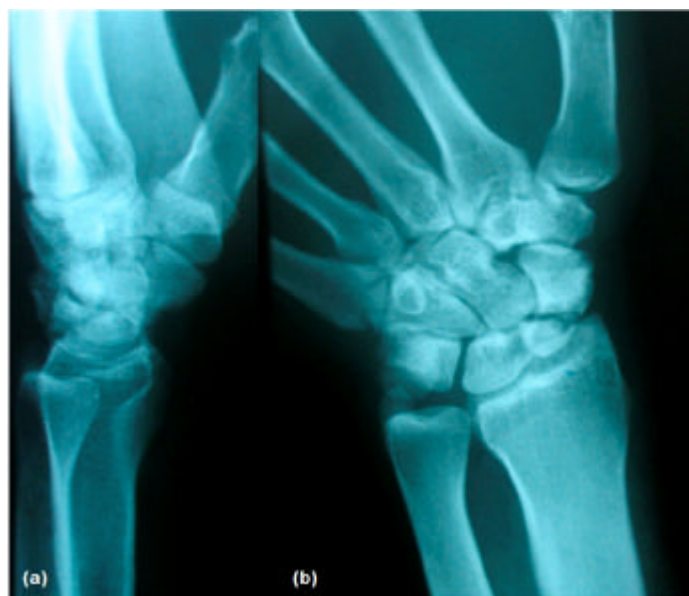

Fig. 1: (a) Lateral and (b) Anteroposterior views of the scaphoid fracture obtained by X-ray radiography

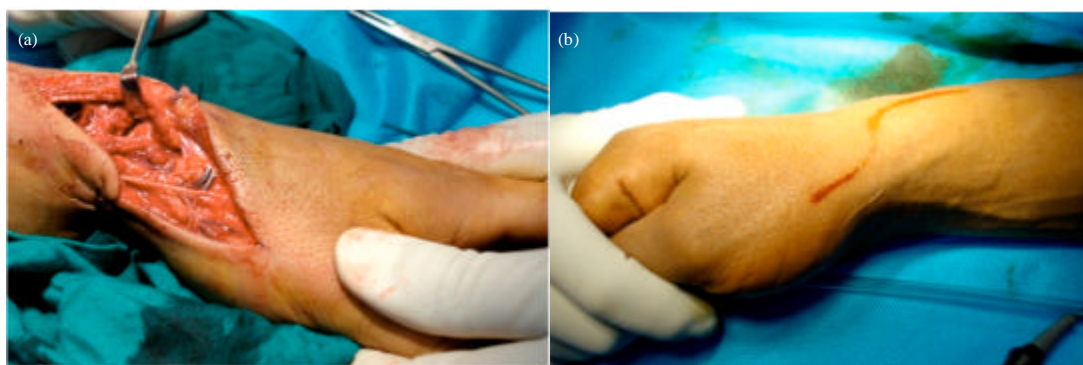


Fig. 2(a-b): Curved incision line on the radial margin of the wrist with fractured scaphoid

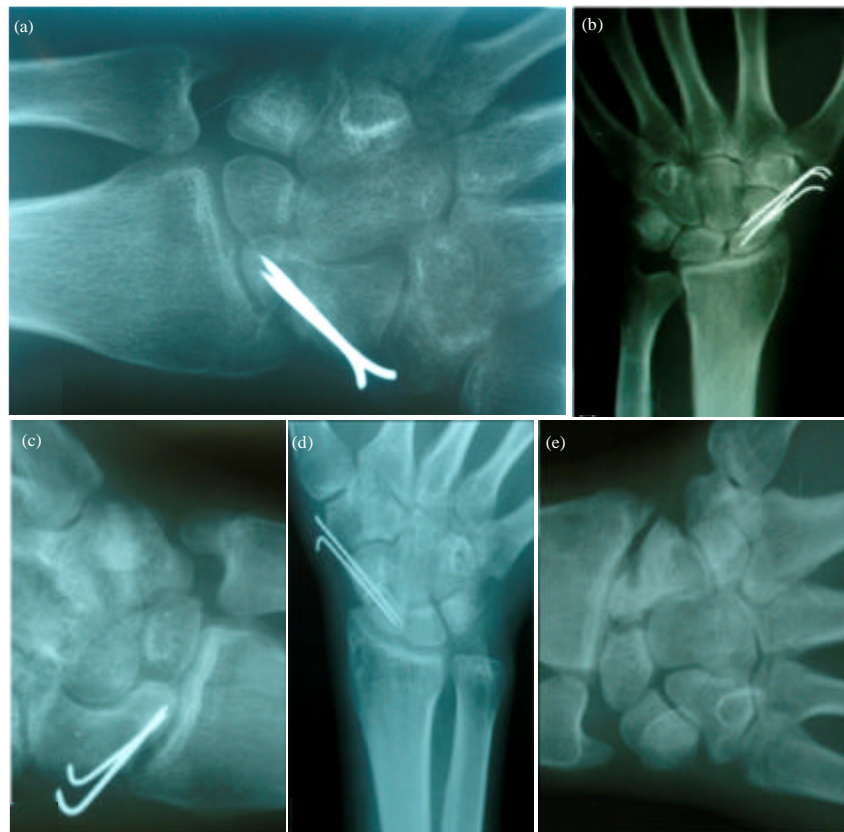

Fig. 3(a-e): X-rays of the operated scaphoid fracture (a) Immediately after operation and on (b) 1.5, (c) 3, (d) 4 and (e) 18 months post-operation

along with its veins and the attached bony segment was detached 1.5 centimeter off the radiocarpal joint. This graft was wedged between the previously prepared gap in the fractured scaphoid. Thereafter, internal fixation was assured using Kirschner wire. A long and short thumb spica cast was employed for 1.5 and 2 months after operation, respectively.

Follow-up: Patients were followed up radiographically immediately after operation, as well as on months 1.5 and 3 after the 4th month, Kirschner wire was extracted and radiologic evaluation of union was investigated (Fig. 3).

The inquired variables included patients' satisfaction, resolution of pain, the change of grip power, range of motion of the wrist, Mayo wrist score (Nydick *et al.*, 2012) before and after operation, complications/abnormal consequences and final outcome (the status of union) were documented.

Statistical analysis: Variables were shown as Mean±standard deviation or number (%). The SPSS

software for Windows (ver.15) was used for analysis. The Student/paired samples t test or the Contingency tables (Chi-square test or Fisher's Exact test where appropriate) were employed for analyzing the data. The $p = 0.05$ was considered statistically significant.

RESULTS

Twenty patients with scaphoid nonunion were enrolled in this study. The male to female ratio was 19 to 1 and mean age was 25.25 years at the time of admission. In majority of the cases, the dominant hand was injured ($n = 19$). At the time of admission, pain was reported in all patients, while in 9 patients, an abnormal grip was coexisted, as well. Magnetic Resonance Imaging (MRI) was used and accordingly, 11 cases with avascular necrosis were detected. Postoperative pain was mild in 3 patients and severe in 2 patients (total = 5).

The patients' characteristics, as well as the main variables at baseline are summarized in Table 1.

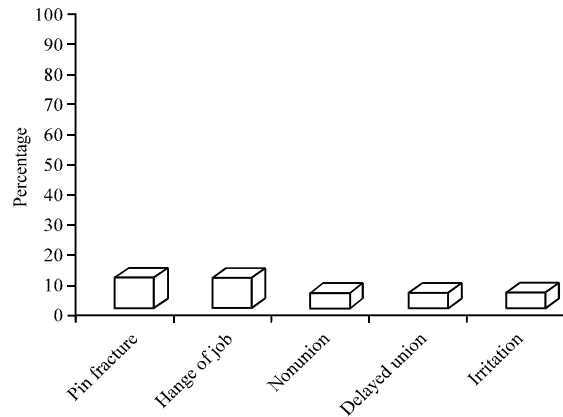


Fig. 4: Percentage of the postoperative complications/consequences in the patients with scaphoid nonunion

Table 1: The characteristic and general data of 20 patients with scaphoid nonunion

Variable	Values
Gender	
Male	19 (95)
Female	1 (5)
Age (year)	25.25±6.62 (17-40)
Time to operation (month)	28.03±41.22 (2-180)
Smoking	11 (55)
Mechanism of injury	
Falling	18 (90)
Traffic accident	2 (10)
Injured side	
Right	12 (60)
Left	8 (40)
Dominant hand	
Right	19 (95)
Left	1 (5)
Chief complaint	
Pain	11 (55)
Pain and abnormal grip	9 (45)
Previous treatment	
None	15 (75)
Casting	5 (25)
Dislocated fracture	18 (90)
Location of nonunion	
Waist	17 (85)
Proximal pole	3 (15)
Avascular necrosis	11 (55)
Styloidectomy	12 (60)
Postoperative pain	5 (25)

Values are Mean±SD, Range or frequency (%)

The sensory and motor examination of the forearm and hand, as well as the status of circulation in the affected upper extremity was flawless in all patients upon admission.

The postoperative complications/consequences were encountered in 7 patients (35%).

The most common consequences were pin fracture and abandoned previous occupation (each one in 2 patients, 10%), followed by nonunion, delayed union and irritation (each one in 1 patient, 5%) (Fig. 4).

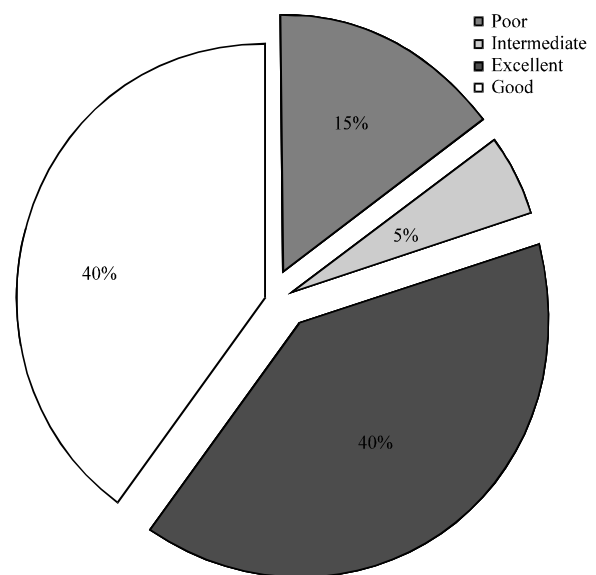


Fig. 5: Percentage of the final outcome (degree of union) in the patients with scaphoid nonunion

The mean gap between operation and union was 10.71 ± 1.62 (range: 8-14) weeks.

Final outcome of the operation (degree of union) was totally good/excellent in 16 patients (80%), comprising 8 patients (40%) with good grade and 8 patients (40%) with excellent grade. In the remaining cases, the results were poor/intermediate ($n = 4$, 20%) including poor grade in 3 patients (15%) and intermediate grade in 1 patient (5%). The percentage of each result is shown individually in Fig. 5.

Changes of the functional parameters before and after operation are summarized in Table 2.

Comparison between pre-and post-operative parameters:

The rate of postoperative pain significantly decreases from 100% preoperatively to 25% postoperatively ($p < 0.001$). The mean Mayo wrist score significantly increased from 44.8 ± 14.2 preoperatively to 88.0 ± 7.7 postoperatively ($p < 0.001$). Accordingly, the rate of the cases with mayo wrist score of good-excellent increased significantly from 0% preoperatively to 85% postoperatively ($p < 0.001$). The change of the ranges of flexion, extension, radial deviation, ulnar deviation and grip force were not statistically significant after operation in comparison with those at the baseline (Table 2).

Comparison of parameters between fractured and intact sides preoperatively:

The mean ranges of flexion, extension, radial deviation, ulnar deviation and grip force were all significantly higher on the intact side than those in the fractured side (Table 2).

Table 2: Functional parameters in the affected hand before and after operation in comparison with the intact hand

Parameter	Involved hand		Intact hand	p-value		
	Pre-operation	Post-operation		P ¹	P ²	P ³
Flexion (degree)	62.8±6.8	63.3±7.5	72.8±5.0	0.33	<0.001	<0.001
Extension (degree)	53.5±7.6	54.3±7.7	63.0±12.3	0.27	0.010	0.010
Ulnar deviation (degree)	31.0±5.8	31.8±5.7	39.3±6.7	0.33	<0.001	<0.001
Radial deviation (degree)	11.3±2.2	44.8±14.2	16.4±4.2	0.08	<0.001	0.001
Low grip force	9 (45)	4 (20)	0 (0)	0.91	-	-
Pain	20 (100)	5 (25)	0 (0)	<0.001	-	-
Mayo wrist score	44.8±14.2	88.0±7.7	-	<0.001	-	-
Mayo grades						
Poor	17 (85)	0 (0)	-	<0.001	-	-
Satisfactory	3 (15)	3 (15)	-			
Good	0 (0)	6 (30)	-			
Excellent	0 (0)	11 (55)	-			

Values are Mean±SD, Parenthesis values are percentage, p<0.05 is statistically significant, P¹: Preoperative vs. postoperative in the involved hand, P²: Preoperative involved hand vs. the intact hand, P³: Postoperative involved hand vs. the intact hand

Comparison of parameters between operated and intact sides: The mean ranges of flexion, extension, radial deviation, ulnar deviation and grip force were all again significantly higher on the intact side than those in the operated side (Table 2).

DISCUSSION

In the present study, the therapeutic outcome of using the reverse-flow pedicle Vascularized Bone Grafts (VBGs) from the distal radius was investigated in the cases with scaphoid nonunion. Accordingly, the union was achieved in 95% of the patients within a mean period of 10.71 weeks. There was only one case with delayed union (5%).

To the best of our knowledge, this is the first report from a developing country using this technique in the patients with scaphoid nonunion. Interestingly, the rate of success lies between the range reported from more experienced centers in western countries, which is between 68-100% (Malizos *et al.*, 2007; Dailiana *et al.*, 2006; Chang *et al.*, 2006; Sotereanos *et al.*, 2006; Chen *et al.*, 2006).

The mean gap time between operation and union was 4.3-19 weeks in the same reports, indicating again a very promising outcome in our series.

It should be born in mind that many factors may influence the outcome of this type of operation such as available facilities, experience of surgeons and technical characteristics of that report, particularly as to the quality of follow-up, as well as the factors being used for determining the outcome of operation.

For instance, Chang *et al.* (2006) showed that older age, female gender, presence of avascular necrosis of the proximal pole, humpback deformity, screw-free fixation and smoking are the potential risk factors connecting with mal-or nonunion.

In our study, however, the possible risk factors associated with nonunion were not investigated due to low number of such cases (only one patient). So, further studies may be helpful in this regard.

The range of motion of the affected limb of the studied patients improved after operation in an insignificant fashion.

In line with this finding, Steinmann *et al.* (2002) showed that this change is not statistically significant.

Small sample size is a major limitation of these two reports and ours, as well. Likewise, longer follow-ups may be helpful to elucidate this finding in future studies.

Due to some technical limitations, the assessment of the grip power was not feasible quantitatively in the present work. Thus, the related comparisons were made based only on the patients' statements. Accordingly, the grip power was enhanced in majority of patients post-operation. This finding is in conformity with other reports (Sotereanos *et al.*, 2006; Chen *et al.*, 2006).

On the other hand, the majority of patients reported significant pain alleviation after operation on the affected limb after operation. This is also compatible with other reports in patients underwent such operation in western countries (Dailiana *et al.*, 2004).

Employing the scoring system, we showed that about 80% of the patients were satisfied with the results of operation, rating it as "good" to "excellent".

This is almost similar to the rate which was reported by Malizos *et al.* (2007) around 77% and significantly more than that 64% reported by Steinmann *et al.* (2002).

As it is clear, the results of the present study are at least equal or even better than those reported from other similar studies in western countries. Returning to preinjury job was another outcome variable in the present study. Accordingly, this parameter was documented in 90% of the patients. There is no similar report in the literature in this regard.

This finding is of pivotal importance, because it practically shows the outcome of operation.

We also showed that the rate of the cases with good to excellent wrist score (based on the Mayo scoring system) increased significantly after operation. This finding is supported in another study by Malizos *et al.* (2007), as well.

CONCLUSION

This study confirmed that scaphoid nonunion may be effectively restored by employing reverse-flow vascularized bone graft from distal metaphysis of radius. This technique of operation is also safe and acceptable by the patients with this problem. Although, this is not the first study in this regard, the findings are very important because it is the first experience in a developing country, indicating that optimal results are not limited only to high-tech and sophisticated centers.

REFERENCES

- An, K.N., R.A. Berger and W.P. Cooney, 1991. Biomechanics of the Wrist Joint. 1st Edn., Springer-Verlag, New York, USA., ISBN-13: 978-3540976745, Pages: 174.
- Chang, M.A., A.T. Bishop, S.L. Moran and A.Y. Shin, 2006. The outcomes and complications of 1,2-intercompartmental supraretinacular artery pedicled vascularized bone grafting of scaphoid nonunions. *J. Hand. Surg. Am.*, 31: 387-396.
- Chen, A.C.Y., E.K. Chao, Y.K. Tu and S.W. Ueng, 2006. Scaphoid nonunion treated with vascular bone grafts pedicled on the dorsal supra-retinacular artery of the distal radius. *J. Trauma.*, 61: 1192-1197.
- Dailiana, Z.H., K.N. Malizos, V. Zachos, S.E. Varitimidis, M. Hantes and A. Karantanas, 2006. Vascularized bone grafts from the palmar radius for the treatment of waist nonunions of the scaphoid. *J. Hand. Surg.*, 31: 397-404.
- Dailiana, Z.H., V. Zachos, S. Varitimidis, P. Papanagiotou, A. Karantanas and K.N. Malizos, 2004. Scaphoid nonunions treated with vascularised bone grafts: MRI assessment. *Eur. J. Radiol.*, 50: 217-224.
- Kuschnier, S.H., C.S. Lane, W.W. Brien and H. Gellman, 1994. Scaphoid fractures and scaphoid nonunion: Diagnosis and treatment. *Orthop. Rev.*, 23: 861-871.
- Malizos, K.N., V. Zachos, Z.H. Dailiana, C. Zalavras, S. Varitimidis, M. Hantes and A. Karantanas, 2007. Scaphoid nonunions: Management with vascularized bone grafts from the distal radius: A clinical and functional outcome study. *Plast. Reconstr. Surg.*, 119: 1513-1525.
- Nydic, J.A., S.M. Greenberg, J.D. Stone, B. Williams, J.A. Polikandriotis and A.V. Hess, 2012. Clinical outcomes of total wrist arthroplasty. *J. Hand. Surg. Am.*, 37: 1580-1584.
- Ong, H.S., G. Tan and W.Y. Chew, 2011. Treatment of scaphoid non-union with 1,2 Intercompartmental Supraretinacular Artery (1,2 ICSRA) vascularised graft. *Singapore Med. J.*, 52: 658-661.
- Rafert, J.A. and B.W. Long, 1991. Technique for diagnosis of scaphoid fractures. *Radiol. Technol.*, 63: 16-20.
- Raju, P.K. and S.G. Kini, 2011. Fixation techniques for non-union of the scaphoid. *J. Orthop. Surg. (Hong Kong)*, 19: 80-84.
- Sheetz, K.K., A.T. Bishop and R.A. Berger, 1995. The arterial blood supply of the distal radius and ulna and its potential use in vascularized pedicled bone grafts. *J. Hand. Surg. Am.*, 20: 902-914.
- Slade, J.F. 3rd and T. Gillon, 2008. Retrospective review of 234 scaphoid fractures and nonunions treated with arthroscopy for union and complications. *Scand. J. Surg.*, 97: 280-289.
- Sotereanos, D.G., N.A. Darlis, Z.H. Dailiana, I.K. Sarris and K.N. Malizos, 2006. A capsular-based vascularized distal radius graft for proximal pole scaphoid pseudarthrosis. *J. Hand. Surg. Am.*, 31: 580-587.
- Steinmann, S.P., A.T. Bishop and R.A. Berger, 2002. Use of the 1,2 intercompartmental supraretinacular artery as a vascularized pedicle bone graft for difficult scaphoid nonunion. *J. Hand. Surg. Am.*, 27: 391-401.