

<http://www.pjbs.org>

PJBS

ISSN 1028-8880

**Pakistan
Journal of Biological Sciences**

ANSI*net*

Asian Network for Scientific Information
308 Lasani Town, Sargodha Road, Faisalabad - Pakistan

In Vitro* Effect of *Nigella sativa* Oil on Adult *Toxocara vitulorum

¹H.A. Shalaby and ^{1,2}F.M. El-Moghazy

¹Department of Parasitology and Animal Diseases,
National Research Center, P.O. Box 12622, Giza, Egypt

²Department of Biology, College of Science and Humanity Studies,
Salman Bin Abdul Aziz University, Kingdom of Saudi Arabia

Abstract: Since the integrity of *Toxocara vitulorum* cuticle is essential for the nutritive and protective functions, light and scanning electron microscopic studies were undertaken to assess, for the first time, whether the *Nigella sativa* oil (NSO) had any effect on the cuticle of adult *T. vitulorum* following incubation *in vitro*. Differences in response to NSO action were observed, depending on the used concentration. After 24 h incubation with 0.5 mg mL⁻¹ NSO, the cuticle of the anterior end of worms appeared to be slightly more swollen than normal. This swelling became pronounced and so severe, with lips showed wrinkled cuticular surface and deformed sensory papillae on increasing the concentration to 1.0 mg mL⁻¹. With the higher concentration of 1.5 mg mL⁻¹, extensive and severe disorganization of the cuticle and body musculature was observed. Structural alterations in the cuticle as observed in the present investigation were thus, clear indication of nematocidal activity of NSO that could offer a suitable and cheaper alternative for the more expensive anthelmintics.

Key words: *Toxocara vitulorum*, *Nigella sativa* oil, *in vitro* effect

INTRODUCTION

Toxocara vitulorum is a pathogenic gastrointestinal nematode of cattle and buffalo in tropical and subtropical regions and if not controlled, the prevalence can approach 100% (Rast *et al.*, 2013). Adult *T. vitulorum* are found in the intestines of young calves, but this calthood infection is acquired from the mother. Maternal infection occurs through ingestion of eggs containing infective larvae of *T. vitulorum*. These larvae remain in the tissues of the dam until just prior to parturition, at which time they begin to grow and migrate to the mammary gland and milk for subsequent ingestion by the calf (Singh *et al.*, 2008). The bulk of worms occur in the duodenum and their nutrient requirements retard the passage of food, impairing the assimilation of nutrients. Infected calves may develop diarrhoea or constipation, anorexia, loss of body condition, stunted growth, colic, loss of coat glossiness and skin tone with eczema and signs of dehydration. In severe infestations, intestinal obstruction, intussusceptions, volvulus and intestinal perforation can occur and cause mortalities, with losses of 30-80% estimated in 2-3 month-old calves (Rast *et al.*, 2013).

Control of this infection produces considerable economic benefits. Adult stage *T. vitulorum* can be effectively treated with piperazine, pyrantel, febantel, fenbendazole and oxfendazole. However, in developing

countries like Egypt, the farmers and herdsmen do not have an easy access to the professional veterinary personnel. In addition, despite availability of veterinarians, farmers usually rely on their personal knowledge for prevention and treatment of helminthiasis. This situation has led to the fact that medicinal plants are the only alternative to anthelmintic therapy (Shalaby *et al.*, 2012a). In this respect, *Nigella sativa*, commonly known as black seed or black cumin, has a great medicinal importance and is known to include many medicinal properties. In addition to its anti-inflammatory action (Majdalawieh *et al.*, 2010), it showed antimicrobial (Mashhadian and Rakhshandeh, 2005) and antiparasitic (Issa, 2003) effects. *N. sativa* has been reported to have antihelminthic and anticoccidial activities (Abu El-Ezz, 2005a, b). It prevents liver damage induced in murine schistosomiasis (Mahmoud *et al.*, 2000). In spite of the large number of studies carried out world wide on *N. sativa*, there is a need to investigate its antinematodal activity. Since the integrity of *Toxocara* cuticle is essential for the nutritive and protective functions as well as to maintain the shape and serve as an antagonistic system for the somatic muscles (Shalaby *et al.*, 2012a), light and scanning electron microscopic studies are undertaken to assess, for the first time, whether the *N. sativa* oil has any effect on the cuticle of adult *T. vitulorum* following incubation *in vitro*.

MATERIALS AND METHODS

Preparation of *N. sativa* oil extract: The dried seeds of *N. sativa* were purchased from a local market and authenticated at the Herbarium of National Research Center. The seeds were crushed and cold macerated in petroleum ether (40-60°C) for three days. After evaporation of petroleum ether, the extract was taken out and the oil was filtered. The extracted oil was kept in screw-capped tubes in the dark at -20°C until use (Mohamadin *et al.*, 2010).

Effect of *N. sativa* oil (NSO) extract on adult *T. vitulorum*: Adult worms of *T. vitulorum* were collected from the intestines of naturally infected buffalo calves slaughtered in a local abattoir in Cairo province, Egypt. After recovery, the worms were washed and transferred to Ringer solution, as recommended by Hanser *et al.* (2002), containing NSO at concentrations of 0.5, 1.0 and 1.5 mg mL⁻¹. The whole worms were incubated for 24 h at 37°C in an atmosphere of 5% CO₂. The NSO was initially prepared as a stock solution in DMSO and added to the culture medium to give a final solvent concentration of 0.01% (v/v). Solvent control worms were incubated for 24 h in Ringer solution containing 0.01% (v/v) DMSO. Other group was prepared by incubating worms in Ringer solution without oil extract or solvent; as normal control worms. Fresh control worms at 0 h were fixed immediately following the initial washing. Five worms were examined for each group.

Light microscopy: Following incubation, the adult worms were cut into small, 5 mm pieces before being fixed in 10% buffered formol saline (6.5 g of disodium phosphate and 4.0 g monosodium phosphate per liter of solution) and processed according to the method of Bancroft *et al.* (1996). The body wall of adult worms was studied and photographed using an Olympus CX41 microscope.

Scanning electron microscopy (SEM): Following incubation, the anterior end of adult worms of *T. vitulorum* was fixed intact for 12 h in a 3:1 mixture of 4% (w/v) glutaraldehyde in 0.12 m Millonig's buffer, pH 7.4 and 1% aqueous osmium tetroxide. After this, the specimens were processed for SEM following a method previously reported (Shalaby *et al.*, 2009).

RESULTS

The untreated *T. vitulorum* showed no loss of activity during the whole period of incubation (24 h)

however, NSO, even the lowest concentration of 0.5 mg mL⁻¹, induced complete stop of motility or death of the worms.

Microscopic observations of the body cover of untreated worms: The cuticular surface and its structure of normal adult *T. vitulorum* had been previously described (Shalaby *et al.*, 2012a). *T. vitulorum* worms, which had been incubated in medium without extract addition or DMSO did not show any signs of damage, even after light and scanning electron microscopic analysis of worms which had been incubated for 24 h. This was also observable in quantities DMSO which were necessary to dissolve the extract. The morphology of these DMSO-control *T. vitulorum* was similar to that known from the literature and from our previous analyses (Shalaby *et al.*, 2012a). Examples of intact structures could be seen in Fig. 1a, 2a and b showing that there were no significant differences were observed between fresh and control worms; neither on the cuticular surface nor on its structure. Therefore, the damage or structural changes observed after extract application were exclusively due to the extract used.

Light microscopic observations: At 0.5 mg mL⁻¹ NSO, only relatively slight swelling was observable in both outer cortical layer of the cuticle and hypodermis (Fig. 1b). This swelling increased at 1.0 mg mL⁻¹ NSO, accompanied with appearance of large vacuoles in the hypodermis (Fig. 1c) and became so severe on increasing the concentration to 1.5 mg mL⁻¹. At the later concentration, the hypodermis took the form of a swollen soft and vacuolated tissue. Areas of connection loss between the cuticle and hypodermis of adult worms could be detected and no cuticle boundaries had been observed. Additionally, the contractile and cytoplasmic portions of muscle cells were altered (Fig. 1d).

Scanning electron microscopic observations: After 24 h incubation with 0.5 mg mL⁻¹ NSO, the cuticle of the anterior end including the lips appeared to be slightly more swollen than normal and had a corrugated appearance (Fig. 2c). Some papillae were distorted, but their positions were still apparent (Fig. 2d). On increasing the concentration to 1.0 mg mL⁻¹ NSO, the cuticular swelling became pronounced so that the cervical alae were ill distinguished (Fig. 2e). The lips were distorted and showed wrinkled cuticular surface and deformed sensory papillae (Fig. 2f). With higher concentration of 1.5 mg mL⁻¹ NSO, the distortion of the cuticle was similar to that described for the previous concentration, except it was more extensive (Fig. 2g). Besides, the dorsal

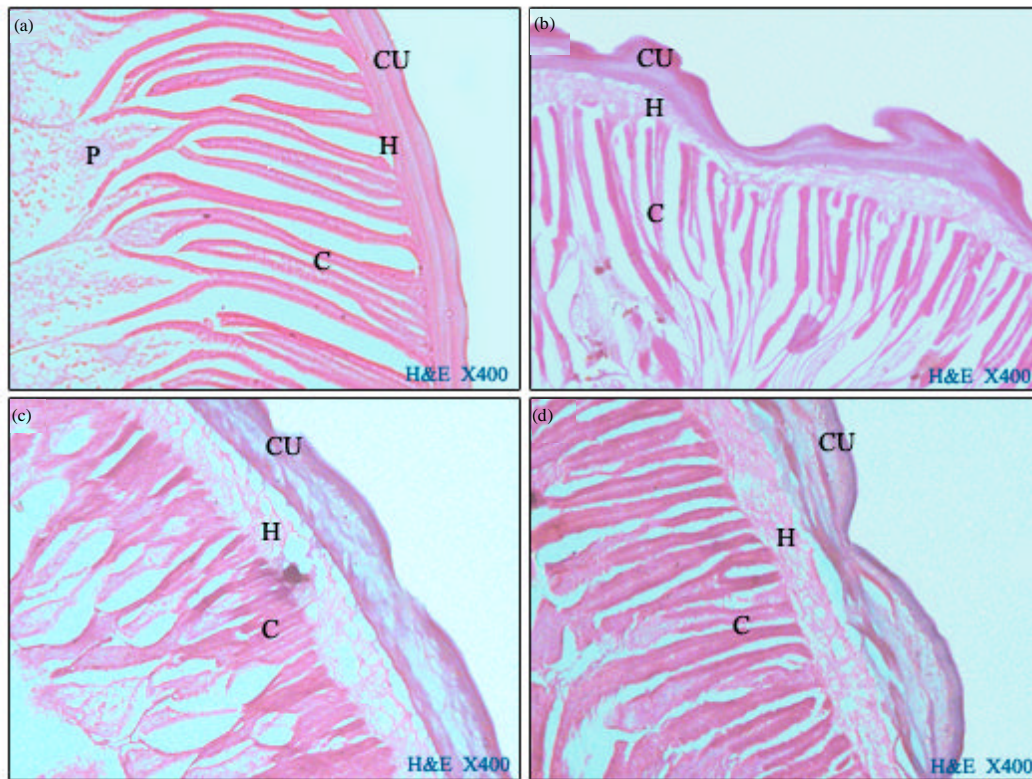


Fig. 1(a-d): Light micrographs of the body cover cross section of adult *T. vitulorum*. (a) Normal fresh worms, (b) Following 24 h incubation with 0.5 mg mL⁻¹ *N. sativa* oil (NSO). Note a swollen and wrinkled cuticle, (c) Following 24 h incubation with 1.0 mg mL⁻¹ NSO. The swelling becomes so severe; besides appearance of several large vacuoles in the hypodermis, (d) Following 24 h incubation with 1.5 mg mL⁻¹ NSO. Note areas of connection loss between the cuticle and hypodermis and no cuticle boundaries. CU: Cuticle, H: Hypodermis, C: Contractile part of the muscle cells, P: Cytoplasmic part of the muscle cells

lip was more affected than the ventro-lateral ones; it appeared more swollen so that the papillae could not be distinguished and most of its denticles were badly affected (Fig. 2h).

DISCUSSION

This study is the first to demonstrate the nematocidal activity of NSO on the adult *T. vitulorum*. During the whole period of the present experiments, the controls remained fully active and vital. However, when worms were incubated in NSO; even the lowest concentration of 0.5 mg mL⁻¹, resulted in an irreversible paralysis. Thus, NSO should lead to an *in vivo* expulsion of worms due to paralysis. Light and scanning electron microscopic observations could be used to determine the target of NSO as cuticular changes could be observed. Differences

in response to NSO action were observed, depending on the used concentration. After 24 h incubation with 0.5 mg mL⁻¹ NSO, the cuticle of the anterior end of worms appeared to be slightly more swollen than normal. This swelling became pronounced and so severe, with lips showed wrinkled cuticular surface and deformed sensory papillae on increasing the concentration to 1.0 mg mL⁻¹. With the higher concentration of 1.5 mg mL⁻¹, extensive and severe disorganization of the cuticle and body musculature was observed. These morphological alterations had also been observed in a recent study, which analyzed the effect of NSO on the cuticle of another nematode, namely *Haemonchus contortus* (Shalaby *et al.*, 2012b). *In vitro* studies showed similar cuticular deformity and severe vacuolization in adult *T. vitulorum* exposed to methanolic extract of *Balanites aegyptiaca* fruits and albendazole (Shalaby *et al.*, 2012a). Distortion of the

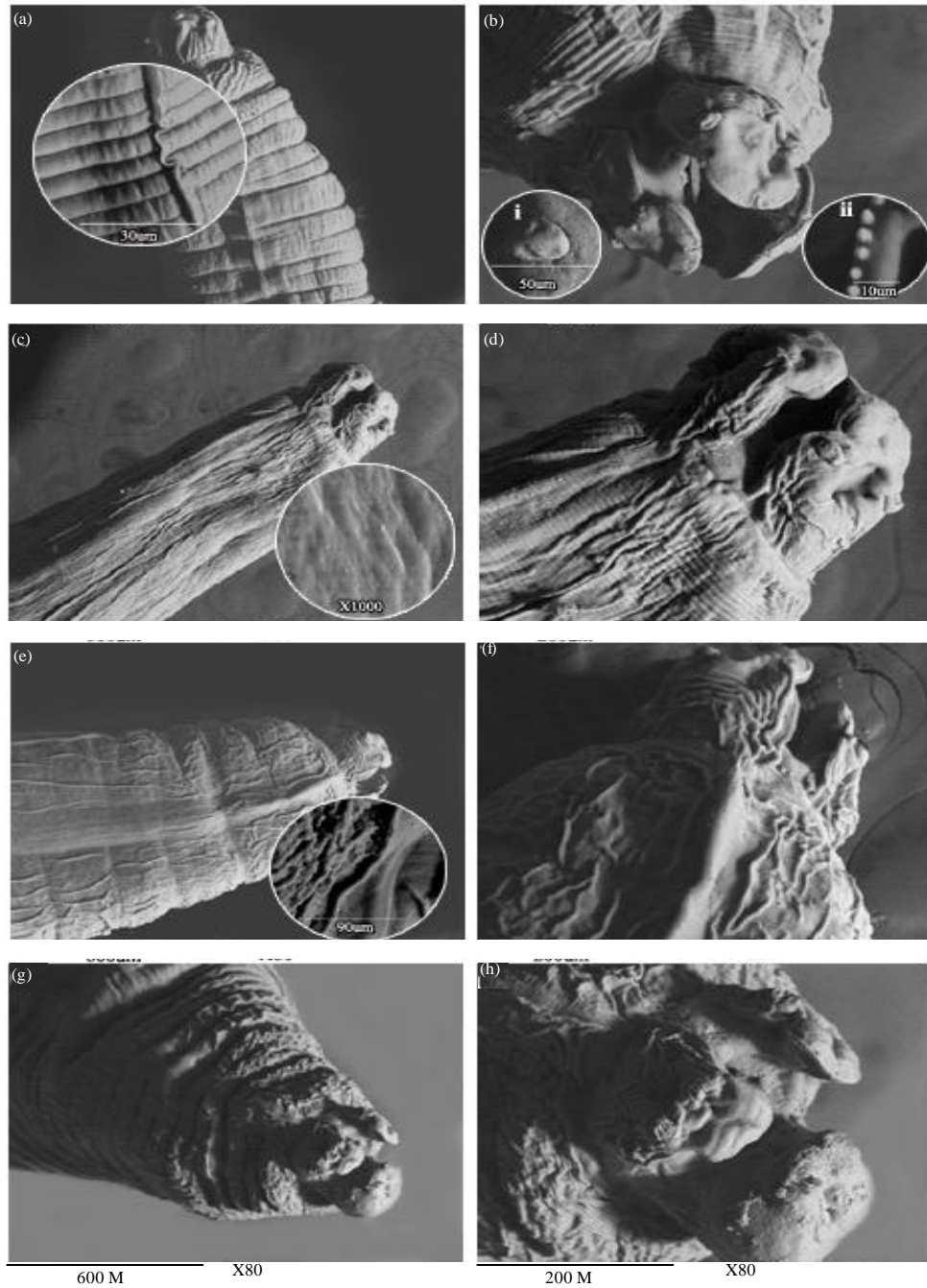


Fig. 2(a-h): Scanning electron micrographs (SEMs) of the anterior end of adult *T. vitulorum*. (a) SEM of normal fresh worm shows transverse striations of the cuticular surface and cervical ala which is reduced to a short lateral ridge (Inset). (b) SEM of normal fresh worm at en face position revealing three prominent lips. Each lip has a pair of sensory papillae (Inset i) and a dentigrous ridge (Inset ii). (c, d) Following 24 h incubation with 0.5 mg mL⁻¹ NSO. Note slightly more swollen cuticle than normal. (e, f) Following 24 h incubation with 1.0 mg mL⁻¹ NSO, showing pronounced cuticular swelling, wrinkled and corrugated cuticular surface and distorted lips. (g, h) Following 24 h incubation with 1.5 mg mL⁻¹ NSO, showing severe distortion of the cuticle

cuticular interface in, biologically related nematode, *Ascaris suum* had been reported with alcoholic extract of *Lysimachia ramosa in vitro* (Challam *et al.*, 2010).

The anthelmintic activities of NSO were studied by Agarwal *et al.* (1979) who reported that the essential oil from the seeds of *N. sativa* showed pronounced activity even in 1:100 dilutions against tapeworms and earthworms. Anticestodal effects of *N. sativa* seeds were studied in children infected naturally with the respective worms. A single oral administration of 40 mg kg⁻¹ of *N. sativa* ethanolic extract reduced the percentage of the fecal eggs without producing any adverse side effects (Akhtar and Riffat, 1991). When given orally to *Schistosoma mansoni*-infected mice, a 2-week treatment with NSO reduced the number of *S. mansoni* worms in the liver and decreased the total number of ova deposited in both the liver and the intestine (Mahmoud *et al.*, 2000).

The possible explanation of the mechanisms of action of NSO could be interpreted on the basis of the direct lethal effect on the worms due to its content of alkaloid nigellicine (El Shenawy *et al.*, 2008). The cuticle of nematodes is metabolically active and morphologically specialized for selective absorption of nutrients and osmoregulation. Thus, passive diffusion of anthelmintics through the cuticle (Alvarez *et al.*, 2007) would probably be responsible for destructive changes and deformation of the nematode body surface (Tippawangkosol *et al.*, 2004; Schmahl *et al.*, 2007). In the present study, the nematode body surface was observed to be affected and altered by NSO. Similar to the present observations, the surface cuticle was found to be a principal target site for different synthetic drugs and natural anthelmintic products as proved by histomorphological and ultrastructural studies (Martin *et al.*, 1997; Shalaby *et al.*, 2012a). Structural alterations in the cuticle as observed in the present investigation are thus, clear indication of nematocidal activity of NSO that could offer a suitable and cheaper alternative for the more expensive anthelmintics.

REFERENCES

- Abu El-Ezz, N.M., 2005a. Comparative efficacy of *Nigella sativa* seeds and diclazuril on coccidiosis in chickens. J. Egypt. Vet. Med. Assoc., 65: 137-147.
- Abu El-Ezz, N.M., 2005b. Effect of *Nigella sativa* and *Allium cepa* oils on *Trichinella spiralis* in experimentally infected rats. J. Egypt. Soc. Parasitol., 35: 511-523.
- Agarwal, R., M.D. Kharya and R. Shrivastava, 1979. Antimicrobial and anthelmintic activities of the essential oil of *Nigella sativa* Linn. Indian J. Exp. Biol., 17: 1264-1265.
- Akhtar, M.S. and S. Riffat, 1991. Field trial of *Saussurea lappa* roots against nematodes and *Nigella sativa* seeds against cestodes in children. J. Pak. Med. Assoc., 41: 185-187.
- Alvarez, L.I., M.L. Mottier and C.E. Lannsse, 2007. Drug transfer into target helminth parasites. Trends Parasitol., 23: 97-104.
- Bancroft, J.D., A. Stevens and D.R. Turner, 1996. Theory and Practice of Histological Techniques. 4th Edn., Churchill, Livingston, New York, London.
- Challam, M., B. Roy and V. Tandon, 2010. Effect of *Lysimachia ramosa* (Primulaceae) on helminth parasites: Motility, mortality and scanning electron microscopic observations on surface topography. Vet. Parasitol., 169: 214-218.
- El Shenawy, N.S., M.F. Soliman and S.I. Reyad, 2008. The effect of antioxidant properties of aqueous garlic extract and *Nigella sativa* as anti-schistosomiasis agents in mice. Rev. Inst. Med. Trop. Sao Paulo, 50: 29-36.
- Hanser, E., H. Mehlhorn, D. Hoeben and K. Vlaminck, 2002. *In vitro* studies on the effects of flubendazole against *Toxocara canis* and *Ascaris suum*. Parasitol. Res., 89: 63-74.
- Issa, R.M., 2003. Using *Nigella sativa* (Habbet El baraka) in treatment of some parasitic diseases. Egypt. J. Med. Sci., 24: 435-446.
- Mahmoud, M.R., H.S. Akber and S. Saleh, 2000. The effect of *N. sativa* oil against the liver damage induced by *Schistosoma mansoni* infection in mice. J. Ethnopharmacol., 79: 1-11.
- Majdalawieh, A.F., R. Hmaidan and R.I. Carr, 2010. *Nigella sativa* modulates splenocyte proliferation, Th1/Th2 cytokine profile, macrophage function and NK anti-tumor activity. J. Ethnopharmacol., 131: 268-275.
- Martin, R.J., A.P. Robertson and H. Bjorn, 1997. Target sites of anthelmintics. Parasitology, 114: 111-124.
- Mashhadian, N.V. and H. Rakhshandeh, 2005. Antibacterial and antifungal effects of *Nigella sativa* extracts against *S. aureus*, *P. aeruginosa* and *C. albicans*. Pak. J. Med. Sci., 21: 47-52.
- Mohamadin, A.M., S. Bassem, A.A. Abdel El-Aal, A.E. Ahmed and F.A. Al-Abbasi, 2010. Protective effects of *Nigella sativa* oil on propoxur-induced toxicity and oxidative stress in rat brain regions. Pesticide Biochem. Physiol., 98: 128-134.
- Rast, L., S. Lee, S. Nampanya, J.A.L.M.L. Toribio, S. Khounsy and P.A. Windsor, 2013. Prevalence and clinical impact of *Toxocara vitulorum* in cattle and buffalo calves in Northern Lao PDR. Trop. Anim. Health Prod., 45: 539-546.

- Schmahl, G., H. Mehlhorn, A. Harder, S. Klimpel and K.J. Krieger, 2007. Efficacy of a combination of imidacloprid plus moxidectin against larval and adult stages of nematodes (*Trichuris muris*, *Angiostrongylus cantonensis*) in rodents. *Parasitol. Res.*, 101: 85-92.
- Shalaby, H.A., A.H. El Namaky, F.A. Khalil and O.M. Kandil, 2012a. Efficacy of methanolic extract of *Balanites aegyptiaca* fruit on *Toxocara vitulorum*. *Vet. Parasitol.*, 183: 386-392.
- Shalaby, H.A., N.M.T. Abu El Ezz, T.K. Farag and H.A.A. Abou-Zeina, 2012b. *In vitro* efficacy of a combination of ivermectin and *Nigella sativa* oil against helminth parasites. *Global Veterinaria*, 9: 465-473.
- Shalaby, H.A., S. Abdel-Shafy, K.A. Abdel-Rahman and A.A. Derbala, 2009. Comparative *in vitro* effect of artemether and albendazole on adult *Toxocara canis*. *Parasitol. Res.*, 105: 967-976.
- Singh, K., S.K. Mishra and A.K. Pruthi, 2008. Pathology of parasitic infections in gastrointestinal tract in buffalo calves. *J. Vet. Parasitol.*, 22: 23-29.
- Tippawangkosol, P., W. Choochote, K. Na-Bangchang, A. Jitpakdi, B. Pitasawat and D. Riyong, 2004. The *in vitro* effect of albendazole, ivermectin, diethylcarbamazine and their combinations against infective third-stage larvae of nocturnally subperiodic *Brugia malayi* (Narathiwat strain): scanning electron microscopy. *J. Vector Ecol.*, 29: 101-108.