

<http://www.pjbs.org>

PJBS

ISSN 1028-8880

**Pakistan
Journal of Biological Sciences**

ANSI*net*

Asian Network for Scientific Information
308 Lasani Town, Sargodha Road, Faisalabad - Pakistan



Research Article

Diabetic Wound Healing in FGF Expression by Nano Herbal of *Rhodomirtus tomentosa* L. and *Zanthoxylum acanthopodium* Fruits

^{1,2}Risma D. Manurung, ²Syafruddin Ilyas, ²Salomo Hutahaean, ³Rosidah rosidah and ²Putri C. Situmorang

¹Poltekkes Kemenkes Medan, Indonesia

²Department of Biology, Faculty of Mathematics and Natural Sciences, Universitas Sumatera Utara, Medan, Indonesia

³Department of Pharmacology, Faculty of Pharmacy, Universitas Sumatera Utara, Medan, Indonesia

Abstract

Background and Objective: Increased glucose levels in diabetes mellitus patients affect angiogenesis which triggers the duration of the wound to heal. *Rhodomirtus tomentosa* leaves (haramonting) and *Zanthoxylum acanthopodium* fruits (andaliman) are an endemic plant with an antioxidant in Indonesia. This study was aimed to determine histology changes of diabetic wound healing in FGF expression by Nano herbal of haramonting and andaliman. **Materials and Methods:** This study consisted of 4 groups for each treatment, K₁: Negative control, K₂: MEBO, K₃: Nano herbal of andaliman and K₄: Nano herbal of haramonting. The treatments were observed on days 0, 4, 8, 12 and 16. Diabetic model rats with alloxan injection (120 mg kg⁻¹. IP) and rats were declared diabetes mellitus when blood glucose levels reached ≥ 200 mg dL⁻¹. The tissue was prepared on paraffin blocks and given Immunohistochemistry staining for FGF analysis. **Results:** There was a significant difference between all groups ($p < 0.001$) in FGF expression. The proliferation of fibroblasts and collagen was formed by administering nano herbal andaliman and haramonting in rat's skin. The proliferation of cells that occur in the injured skin layer indicates the compounds contained in the nano herbal haramonting and andaliman stimulate cell division and growth to form wound tissue. **Conclusion:** Nano herbal andaliman and haramonting can be developed into herbs that can be used to treat wounds in diabetes. Another molecular gene analysis is required to get higher yields to further study for diabetic wounds against these two herbs.

Key words: Diabetes mellitus, diabetic wounds, FGF, immunohistochemistry, nano herbal, *Rhodomirtus tomentosa*, *Zanthoxylum acanthopodium*

Citation: Manurung, R.D., S. Ilyas, S. Hutahaean, R. Rosidah and P.C. Situmorang, 2021. Diabetic wound healing in FGF expression by nano herbal of *Rhodomirtus tomentosa* L. and *Zanthoxylum acanthopodium* fruits. Pak. J. Biol. Sci., 24: 401-408.

Corresponding Author: Syafruddin Ilyas, Department of Biology, Faculty of Mathematics and Natural Sciences, Universitas Sumatera Utara, Medan, Indonesia

Copyright: © 2021 Risma D. Manurung *et al.* This is an open access article distributed under the terms of the creative commons attribution License, which permits unrestricted use, distribution and reproduction in any medium, provided the original author and source are credited.

Competing Interest: The authors have declared that no competing interest exists.

Data Availability: All relevant data are within the paper and its supporting information files.

INTRODUCTION

The wound causes the loss of the skin, bacterial, or fungal barrier to the tissue and puts it at risk of systemic infection¹. In diabetes mellitus patients, the duration of the wound healing process is thought to be due to prolonged hyperglycemia conditions and the formation of incomplete granulation tissue². Hyperglycemia causes damage or decreased production of cytokines, including growth factors and their receptors, thus disrupting the function of macrophage cells, the angiogenesis process, collagen production and the proliferation process³. Increased glucose levels in diabetes mellitus patients affect angiogenesis which triggers the duration of the wound to heal^{2,3}.

The keratinization process in epidermal cells freezes the bonds of cells, producing a barrier to prevent fluid loss, entry of unwanted molecules and harmful organisms^{3,4}. One of the immunogenic molecules is Fibroblast Growth Factor (FGF). Expression of FGF strengthens chemotaxis of fibroblasts and smooth muscle, modulates collagen and collagenase formation⁴. This process causes the deposition of new connective tissue into the wound site, which is known as the proliferation phase, the epithelialization process, granulation and neovascularization. FGF will be stimulated by endothelial cells to release plasminogen and procollagenase activators⁴. Plasminogen activator will convert plasminogen to plasmin and procollagenase into active collagenase which will then digest the basal membrane constituents^{4,5}. The fragmentation of the basal membrane will allow the formation of capillary shoots that migrate to the wound in response to FGF, VEGF and other angiogenesis factors that play a role in diabetic wound healing⁵.

Andaliman (*Zanthoxylum acanthopodium* DC.) is a shrub and member of the Rutaceae family. Several studies have shown that the andaliman contains alkaloids, flavonoids, triterpenoids, saponins and tannins found in andaliman extracts. The fruits have high antioxidants to increase HSP-70 expression and reduce Malondialdehyde (MDA)⁶. Nano herbal of andaliman has low toxicity and is safe in several organs so that it can be developed into medicine⁷. Nanoherbal of andaliman can also repair the liver, kidney and placenta in preeclamptic rats⁷⁻⁹. Haramonting leaves (*Rhodomlyrtus tomentosa*) is a wild plant as oral anti-diabetes medicine. Nanoherbal haramonting can also improve the histology of the placental organs, liver and kidney preeclampsia^{10,11}. Nanoherbal of haramonting can also affect testicular histology, abundance, kidneys, liver and lungs exposed to cigarette smoke¹²⁻¹⁷.

Changes in the nanoscale size provide a significant change in physicochemical properties and can increase the efficacy of the drug molecule. The size change in nano form is expected to be effective in medicine for maximum results¹⁸.

The aim of the study was diabetic wound healing by haramonting leaves and andaliman fruits in diabetic rats by FGF expressions.

MATERIALS AND METHODS

Study area: The research period was from May-November, 2020. This research was conducted in the Molecular Genetics Laboratory, Animal Physiology Laboratory of the Department of Biology, Faculty of Mathematics and Natural Sciences at Universitas Sumatera Utara, Laboratory of Anatomical Pathology, Faculty of Medicine and the Indonesian Institute of Sciences (LIPI) Jakarta, Indonesia.

Preparation of *Zanthoxylum acanthopodium* and *Rhodomlyrtus tomentosa*: Andaliman fruit is taken from andaliman fruit traders from Dairi, North Sumatera and the fresh green of haramonting leaves are obtained from Gunung Tua District, North Padang Lawas Regency. Haramonting and andaliman are used as nano herbal preparations. Haramonting herbal nano preparations in the form of Self Nano-Emulsifying Drug Delivery System (SNEDDS) using High Energy Milling (HEM) at Indonesian research institutes (LIPI, Jakarta)^{6,7}.

Animal handling: This study used 100 healthy and fertile rats (*Rattus norvegicus*) aged 8-11 weeks weighing 150-200 g. The rats were obtained from the Medan, North Sumatera, Animal Disease Investigation Center. Rats were fed and drank ad libitum. Rats cages are kept clean and set 12-12 hrs light-dark. Handling of experimental animals following the requirements of the applicable code of conduct. Before the research was conducted, an application was submitted to get ethical clearance to the Health Research Ethics Commission for the North Sumatera Region of Medan.

Study design: The research type is a true experiment with the randomized posttest only control group research design which was conducted in the laboratory. This study consisted of 4 groups for each treatment, K₁: Negative control, K₂: MEBO, K₃: Nanoherbal of andaliman fruits (100 mg kg⁻¹ b.wt.) and K₄: Nanoherbal of haramonting leaves (100 mg kg⁻¹ b.wt.). The treatments were observed on days 0, 4, 8, 12 and the 16th. Each group had 5 replications on every treatment day so that each group needed 20 rats. Diabetic model rats with alloxan

Injection (120 mg kg^{-1} .IP) in all groups intra-peritoneally in the abdominal area (stomach) and rats were declared diabetes mellitus when the blood glucose levels reached $\geq 200 \text{ mg dL}^{-1}$. Measurement of blood glucose levels was carried out from the tail blood vessels, namely the lateral veins using a glucometer glucoDR Bio-sensor. The MEBO (Moist Exposed Burn Ointment) Bioplacenton is also given to experimental diabetic wounds as a comparison¹⁹.

Experiment of diabetic wound rats: The hair of diabetic rats was shaved and then cleaned with alcohol in the lateral area of the back about 3 cm from below the ear. The rats were injected with Ketamine-HCl (dose 50 mg kg^{-1} b.wt.) intramuscularly in the femur area as an anesthetic to reduce pain. Making of diabetic wounds using an iron plate measuring $1.5 \times 1 \text{ cm}$. The iron plate was heated with blue fire until the iron was red for 3 min then the iron plate was placed on the skin of the mouse's back for 2 sec to make second-degree burns. The experimental animals were dissected by cervical dislocation on the 4, 8, 12 and 16th days.

Immunohistochemistry staining of FGF: FGF detection used Anti-fibroblast (FGF, Thy-1) monoclonal mouse. The tissue was cut using a microtome with a thickness of 4-6 microns. For pre-treatment, the tissue was heated in citrate buffer at pH 6.0 and 350 W. After washing with PBS, the tissue was incubated with FGF antibodies, respectively, at 37°C then washed again with PBS before applying Avidin-biotin peroxidase. Lastly, all sections were visualized using a chromogen DAB working solution followed by counterstained with Meyer's hematoxylin.

Data analysis: Research data using SPSS software version 23 using the ANOVA test at 5% level then continued with the Post Hoc-Duncan test. If the data are not normally distributed and/or the variance is not homogeneous, then we use the *Kruskal Wallis* test and then proceed with the Mann-whiney test.

RESULTS

Histology changes of the diabetic wound in FGF expression by moist exposed burn ointment: The healing process for diabetic wounds is shown in Fig. 1 starting from day 4-16. In untreated diabetic wounds (Fig. 1a), it is necessary to process the formation of blood vessels to supply nutrition to the damaged tissue. There were no histological changes on the 4th day on diabetic rats who were injured (Fig. 1b), when the

wound was left on the 8th day, there was no collagen connective tissue or cells that proliferated (Fig. 1c). There is no epithelial formation process in the epidermis, the basal membrane layer, large hollow thin fibers begin to form and few fibroblasts (Fig. 1d) and there was an increase in the wound tissue damage of rats diabetic (Fig. 1e). In the group given MEBO ointment, the wound tissue has repaired process was carried out. Histologically in healing, the wound is characterized by a thick, granular vascular tissue dominated by extensive fibroblasts and collagen (Fig. 1f). The epithelium has mostly covered the wound on the skin (Fig. 1g). Epithelial-filled skin tissue indicates the presence of epithelial cell proliferation (Fig. 1h). The thick basal membrane layer is neatly arranged and looks back to normal and a thin layer of collagen connective tissue covers the entire dermis (Fig. 1i). Likewise, many fibroblasts and collagen have formed. High fibroblasts indicate an ongoing proliferation phase and a shortening of the inflammatory phase (Fig. 1j). This proves the existence of cell proliferation that occurs in the injured skin layer.

Histology changes of the diabetic wound in FGF expression by nano herbal of Andaliman fruits and Haramonting leaves:

The proliferation of fibroblasts and collagen was formed on the administration of nano herbal andaliman (Fig. 2a). Epithelial formation begins in the epidermis and the initial stages of basal membrane formation are marked by the presence of a thin layer (Fig. 2b). The formation of the basal membrane is characterized by the presence of a moderate layer and the dermis layer is heavily filled with collagen connective tissue (Fig. 2c). The basal membrane layer is thick although still not neatly arranged and the infiltration of inflammatory cells is moderate (Fig. 2d). The wound healing results indicated that the epithelialization had covered the epidermis, thick basal membrane neatly arranged, there is dense collagen connective tissue filling the dermis and an increase in fibroblast cells (Fig. 2e). In immunologic processes, VEGF acts via at least two receptors and is expressed primarily on endothelial cells, along with other vascular cytokines such as Fibroblast Growth Factor (FGF) and angiopoietin to induce and maintain blood vessels.

Nano herbal haramonting can also as the healing process of diabetic wounds. The tissue looks damaged and there is no epithelial formation process in the epidermis (Fig. 2f). There were no histological changes on the 4th day on diabetic rats who were injured (Fig. 2g), when the wound was left on the 8th day, there was no collagen connective tissue or cells that proliferated (Fig. 2h). The formation of a structured epithelium, thick and already covers the surface of the epidermis (Fig. 2i).

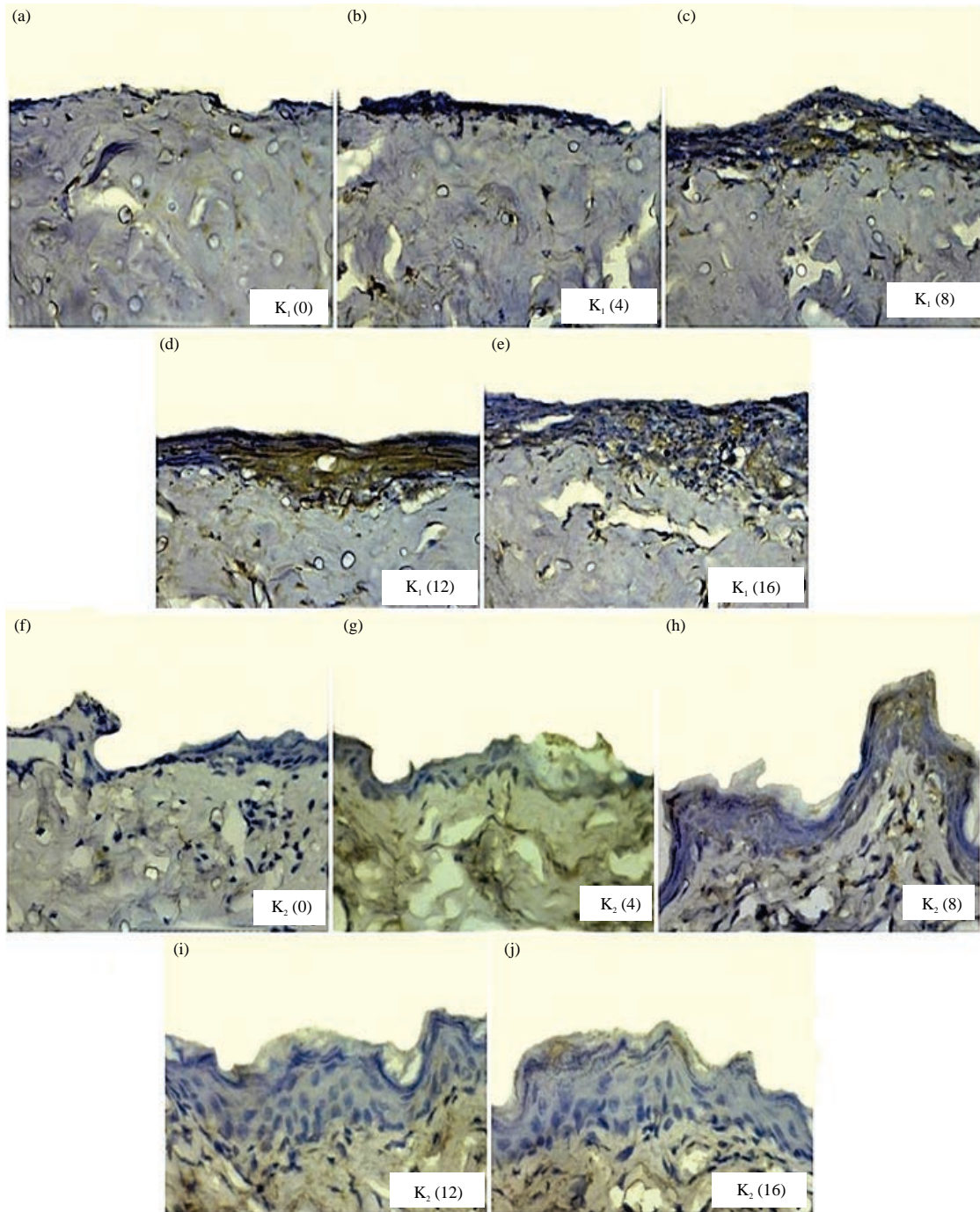


Fig.1(a-j): Expression of FGF in control negative and MEBO treatment for 16 days

(a-e) Are negative control (K1) and f-j are MEBO ointment (K2), (a) 0 day or first treatment, (b) Fourth day, (c) Eighth day, (d) Twelfth day, (e) Sixteenth day
 (f) 0 day or first treatment, (g) Fourth day, (h) Eighth day, (i) Twelfth day and (j) Sixteenth day

The thick basal membrane layer is neatly arranged and looks back to normal and a thin layer of collagen connective tissue covers the entire dermis. On the 16th day, optimal healing is characterized by epithelialization that has covered the epidermis and the absence of inflammatory cell infiltration

(Fig. 2j). FGF is very important in epithelialization and the production of collagen in wound healing. These proteins collectively are a member of the group of growth factors, cytokines and chemokines which are included in secretory proteins. Herbal medicines that can play a role in balancing




Fig. 2 a-j: Expression of FGF in nano herbal andaliman and haramonting treatments for 16 days

(a-e) Are nano herbal andaliman treatments (K_3), (a) 0 day or first treatment, (b) Fourth day, (c) Eighth day, (d) Twelfth day, (e) Sixteenth day, (f-j) are nano herbal haramonting treatments (K_4), (f) 0 day or first treatment, (g) Fourth day, (h) Eighth day, (i) Twelfth day, (j) Sixteenth day

FGF expression and stimulate the formation of new tissue in the skin are haramonting and andaliman.

Statistical analysis of diabetic wound healing in FGF expression: The administration of MEBO ointment, nano herbal andaliman and haramonting had the same effect in healing diabetic wounds on the skin of rats. There was a significant difference between all groups ($p < 0.001$) in FGF

expression (Fig. 3). This shows an increase in diabetic wound healing from the 1-16 days. The expression of FGF indicates a proinflammatory process triggered by the wound. Wounds cause excessive production of proinflammatory cytokines resulting in a prolonged inflammatory phase so that the wound will take a long time to heal. So it takes compounds/substances that act as immunoregulators and stimulate the formation of new tissue in the skin.

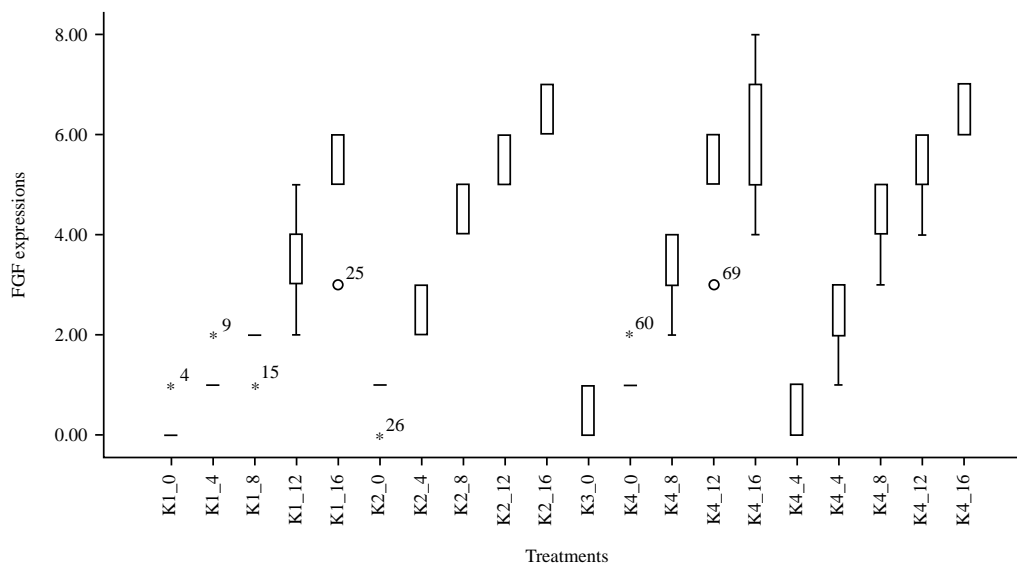


Fig. 3: Boxplot of FGF expression after various nano herbal treatments and wound healing time

K₁: Negative control, K₂: MEBO, K₃: Nano herbal of andaliman fruits (100 mg kg⁻¹ b.wt.) and K₄: Nano herbal of haramonting leaves (100 mg kg⁻¹ b.wt.). (0) day of first treatment, (4) Fourth day, (8) Eighth day, (12) Twelfth day, (16) Sixteenth day

DISCUSSION

The wound tissue requires energy intake and MEBO ointment has properties for wound healing. In the K-group (untreated diabetic wounds), it is necessary to process the formation of blood vessels to supply nutrition to the damaged tissue¹⁹. Diabetic wounds cause tissue damage and FGF is immediately released by macrophages and VEGF by hypoxic epidermal cells^{4,5}. The released proteolytic enzymes will destroy the extracellular matrix proteins and the resulting protein fragments will function to recruit monocytes to the site of tissue damage⁵, then the Monocytes will be activated and become Macrophages. Some of the cytokines produced by macrophages, such as FGF, will stimulate the endothelium to release tPA and then convert Plasminogen into Plasmin and Procollagenase which activate Polagenas²⁰. These two proteolytic enzymes will damage the basal membrane, thus allowing stimulated endothelial cells to move and form new blood vessels at the site of injury. The angiogenesis process will stop after the formation of granulation and a large number of new blood vessels, disintegrating due to apoptosis, with the end of this stage, the healing process is continued by the remodeling phase²¹.

The proliferation of cells in the injured skin layer indicates that several compounds contained in the nano herbal haramonting and andaliman stimulate cell division and growth to form wound tissue such as flavonoids, steroids, saponins and tannins²². In immunologic processes, VEGF acts

via at least two receptors and is expressed primarily on endothelial cells, along with other vascular cytokines such as Fibroblast Growth Factor (FGF) and angiopoietin to induce and maintain blood vessels²¹. The recombinant human-VEGF (rh-VEGF) gene carrying the plasmid, VEGF165, has been used in patients with diabetic and ischemic wounds²³. Transfer of the VEGF165 intramuscular gene to patients with ischemic ulcers and/or rest pain due to peripheral artery disease resulting in loss of feeling in the limb significantly reduces rest pain²⁴.

Monocytes in the tissues undergo activation and differentiate into mature tissue macrophages after leaving the blood vessels, followed by changes in gene expression²⁵. This process is influenced by various mediators found in the microenvironment around the wound which causes macrophage cells to change their properties according to the needs at the wound site^{20,25}. Macrophages act as antigen and phagocytic presenting cells during the wound healing process, play a role in the healing process through the synthesis of various important growth factors such as FGF which will increase cell proliferation and synthesis of extracellular matrices by skin cells^{21,25}.

FGF will stimulate endothelial cells to release plasminogen and procollagenase activators. New blood vessels deposit a matrix containing fibronectin and proteoglycans, then stimulate endothelial cell proliferation which results in the continuous addition of endothelial cells to form capillary extensions, then finally forming a mature

vascular basal membrane. then the extracellular matrix replaces with collagen-rich scar tissue as new blood vessels regenerate by apoptosis²⁵.

Saponins play a role in wound healing because they can stimulate fibronectin synthesis by fibroblasts and change the expression of the FGF- β receptor²⁶. Haramonting leaves and andaliman fruit also have saponins and several other studies have also found hepatoprotective, antibacterial, antioxidant and gastroprotective benefits^{22,27}. The histology of skin tissue is almost the same in rats as in MEBO administration. Therefore, Nanoherbal andaliman and haramonting can be developed into herbs that can be used to treat wounds in diabetes.

CONCLUSION

There was a significant difference between all groups ($p < 0.001$) in FGF expression in the rat's skin tissue. The wound healing results indicated that the epithelialization had covered the epidermis, thick basal membrane neatly arranged, there is dense collagen connective tissue filling the dermis and an increase in fibroblast cells. The proliferation of cells in the injured skin layer shows that the compounds contained in nano herbal of haramonting and andaliman roles in cell division and growth to form wound tissue.

SIGNIFICANCE STATEMENT

This study discovers that nano herbal of andaliman fruits and haramonting leaves acts as herbal for diabetic wounds. This study will help the researcher to uncover the role of nano herbal of andaliman and haramonting in molecular signaling of other target genes for drug development in diabetic wound healing. Thus, a new theory on the role of nano herbal in the FGF expression in diabetic wounds may be arrived at.

ACKNOWLEDGMENTS

This study acknowledges grant support from the Deputy for Strengthening Research and Development, Ministry of Research and Technology/National Research and Innovation Agency in Doctoral Dissertation Research grant Number:28/UN.5.2.3.1/PPM/KP-DRPP/2020.

REFERENCES

1. Wada, J. and H. Makino, 2016. Innate immunity in diabetes and diabetic nephropathy. *Nat. Rev. Nephrol.*, 12: 13-26.

2. Sami, D.G. and A. Abdellati, 2020. Histological and clinical evaluation of wound healing in pressure ulcers: a novel animal model. *J. Wound Care*, 29: 632-641.

3. Sanchez, M.C., S. Lancel, E. Boulanger and R. Neviere, 2018. Targeting oxidative stress and mitochondrial dysfunction in the treatment of impaired wound healing: A systematic review. *Antioxidants*, Vol. 7.10.3390/antiox7080098.

4. Puspasari, A., K. Harijanti, B. Soebadi, H.T. Hendarti, D. Radithia and D.S. Ernawati, 2018. Effects of topical application of propolis extract on fibroblast growth factor-2 and fibroblast expression in the traumatic ulcers of diabetic *Rattus norvegicus*. *J. Oral Maxillofac. Pathol.*, 22: 54-58.

5. Yan, D., S. Liu, X. Zhao, H. Bian and X. Yao *et al.*, 2017. Recombinant human granulocyte macrophage colony stimulating factor in deep second-degree burn wound healing. *Medicine*, Vol. 96. 10.1097/MD.0000000000006881.

6. Situmorang, P.C., S. Ilyas and S. Hutahaeen, 2019. Study of combination of nanoherbal andaliman (*Zanthoxylum acanthopodium*) and Extra Virgin Olive Oil (EVOO) effects in the expression of Malondialdehyde (MDA), Heat Shock Protein-70 (HSP70) and placental histology of preeclamptic rats. *Pharm. Sci.*, 25: 205-220.

7. Situmorang, P.C., S. Ilyas, S. Hutahaeen, R. Rosidah and R.D. Manurung, 2020. Acute toxicity test and histological description of organs after giving nano herbal andaliman (*Zanthoxylum acanthopodium*). *Rasayan J. Chem.*, 13: 780-788.

8. Situmorang, P.C., S. Ilyas and S. Hutahaeen, 2019. Effect of Combination of Nano Herbal Andaliman (*Zanthoxylum acanthopodium* DC.) and Extra Virgin Olive Oil (EVOO) to Kidney Histology of Preeclampsia Rats. *IOP Conference Series: Earth and Environmental Science*, 8-9 December, 2018, IOP Publishing Ltd., 1-6.

9. Situmorang, P.C., S. Ilyas, S. Hutahaeen and R. Rosidah, 2019. Effect of nanoherbal andaliman (*Zanthoxylum acanthopodium*) and extra virgin olive oil combination on preeclamptic rats liver histology. *Open Access Macedonian J. Med. Sci.*, 7: 2226-2231.

10. Irianti, E., S. Ilyas, S. Hutahaeen, Rosidah and P.C. Situmorang, 2020. Placental histological on preeclamptic rats (*rattus norvegicus*) after administration of nanoherbal haramonting (*Rhodomyrtus tomentosa*). *Res. J. Pharm. Technol.*, 13: 3879-3882 10.5958/0974-360x.2020.00686.1.

11. Ilyas, S., S. Hutahaeen, R. Rosidah and P.C. Situmorang, 2020. Effects of nanoherbal haramonting (*Rhodomyrtus tomentosa*) and extra virgin olive oil on histology of liver and kidney of preeclamptic rats. *Pak. J. Biol. Sci.*, 23: 1629-1635.

12. Ilyas, S., F. Murdela, S. Hutahaeen and P.C. Situmorang, 2019. The effect of haramonting leaf ethanol extract (*Rhodomyrtus tomentosa* (Aiton) Hassk.) on the number of leukocyte type and histology of mice pulmo (*Mus musculus* L.) exposed to electronic cigarette. *Open Access Maced. J. Med. Sci.*, 7: 1750-1756.

13. Ilyas, S., 2019. Description of kidney histology of mus musculus after giving nano herbal *Rhodomyrtus tomentosa* (haramounting). Int. J. Ecophysiol., 1: 26-33.
14. Ilyas, S., 2019. Effect of nano herbal haramounting (*Rhodomyrtus tomentosa*) in histology of heart mus musculus. Int. J. Ecophysiology, 1: 101-106.
15. Ilyas, S., 2020. Effect of nanoherbal haramounting (*Rhodomyrtus tomentosa*) on lungs histology. Int. J. Ecophysiol., 2: 43-47.
16. Ilyas, S., 2020. Histology of spleen after induction nanoherbal *Rhodomyrtus tomentosa*. Int. J. Ecophysiol., 2: 70-74.
17. Situmorang, P.C. and S. Ilyas, 2018. Description of testis histology of mus musculus after giving nano herbal *Rhodomyrtus tomentosa* (Haramounting). Asian J. Pharm. Clin. Res., 11: 460-463.
18. Basumatary, S. and N. Changmai, 2018. Biological materials assisted synthesis of silver nanoparticles and potential applications: A review. Res. J. Pharm. Technol., 11: 2681-2694.
19. Fu, H.D., S. Wang, B. Ge, L.Q. Li, H.M. Zeng, Q.F. Shu and Y. Zhou, 2018. Nerve growth factor and substance P may be involved in moist exposed burn ointment-mediated chronic refractory wound healing. Exp. Ther. Med., 16: 1987-1993.
20. Hui, Q., Z. Jin, X. Li, C. Liu and X. Wang, 2018. FGF family: From drug development to clinical application. Int. J. Mol. Sci., Vol. 19. 10.3390/ijms19071875.
21. Kinoda, J., M. Ishihara, S. Nakamura, M. Fujita, K. Fukuda, Y. Sato and H. Yokoe, 2018. Protective effect of FGF-2 and low-molecular-weight heparin/protamine nanoparticles on radiation-induced healing-impaired wound repair in rats. J. Radiat. Res., 59: 27-34.
22. Wijaya, C.H., F.I. Napitupulu, V. Karnady and S. Indariani, 2018. A review of the bioactivity and flavor properties of the exotic spice "andaliman" (*Zanthoxylum acanthopodium* DC.). Food Rev. Int., 35: 1-19.
23. Barć, P., M. Antkiewicz, B. Śliwa, D. Baczyńska, W. Witkiewicz and J.P. Skóra, 2019. Treatment of critical limb ischemia by pIRES/VEGF165/HGF administration. Ann. Vasc. Surg., 60: 346-354.
24. Krishnasamy, K., A. Limbourg, T. Kapanadze, J. Gamrekelashvili and C. Beger *et al.*, 2017. Blood vessel control of macrophage maturation promotes arteriogenesis in ischemia. Nat. Commun., Vol. 8. 10.1038/s41467-017-00953-2.
25. Firoozi, N. and Y. Kang, 2020. Immobilization of FGF on poly(xylitol dodecanedioic acid) polymer for tissue regeneration. Sci. Rep., Vol. 10. 10.1038/s41598-020-67261-6.
26. Ago, M. and D. Adifa, 2020. Benefits of gotu kola leaf in responding to prevent the form of keloid in the wound. Indonesian J. Global Health Res., 2: 23-28.
27. Zhao, Z., L. Wu, J. Xie, Y. Feng and J. Tian *et al.*, 2020. *Rhodomyrtus tomentosa* (Aiton.): A review of phytochemistry, pharmacology and industrial applications research progress. Food Chem., Vol. 309. 10.1016/j.foodchem. 2019.125715.